



UNIVERSITY OF LEEDS

This is a repository copy of *Dental Management of a Patient with Multiple Idiopathic Cervical Root Resorption*.

White Rose Research Online URL for this paper:

<https://eprints.whiterose.ac.uk/91936/>

Version: Accepted Version

Article:

Ali, R, Fayle, S, Langley, D et al. (2 more authors) (2015) Dental Management of a Patient with Multiple Idiopathic Cervical Root Resorption. *Dental Update*, 42 (7). 667 - 672. ISSN 0305-5000

<https://doi.org/10.12968/denu.2015.42.7.667>

Reuse

Items deposited in White Rose Research Online are protected by copyright, with all rights reserved unless indicated otherwise. They may be downloaded and/or printed for private study, or other acts as permitted by national copyright laws. The publisher or other rights holders may allow further reproduction and re-use of the full text version. This is indicated by the licence information on the White Rose Research Online record for the item.

Takedown

If you consider content in White Rose Research Online to be in breach of UK law, please notify us by emailing eprints@whiterose.ac.uk including the URL of the record and the reason for the withdrawal request.



eprints@whiterose.ac.uk
<https://eprints.whiterose.ac.uk/>

Restorative Dentistry

Dental Management of a Patient with Multiple Idiopathic Cervical Root Resorption

Rahat Ali*,

Specialist Registrar in Restorative Dentistry,

BSc(Hons), BDS, MSc, MFGDP (UK), MFDS RCS, PGC (HE),

Stephen Fayle*,

Consultant in Paediatric Dentistry,

BDS, MDS, FDSRCS MRCD(C)

David Langley*,

Chief Dental Technician in Conservative Dentistry,

Asmaa Altaie*,

Postgraduate PhD Student in Restorative Dentistry

BDS, MSc

Brian Nattress*,

Senior Lecturer/ Honorary Consultant in Restorative Dentistry,

BChD, FDS RCS, MRD RCS, PhD.

*Leeds Dental Institute, Clarendon Way, Leeds, LS2 9LU

Dental Management of a Patient with Multiple Idiopathic Cervical Root Resorption

Clinical Relevance

Clinicians need to be aware that multiple idiopathic cervical root resorption is a rare condition. Suspected patients may require specialist, multidisciplinary care and require referral to an appropriate secondary care unit for treatment planning and potential oral rehabilitation.

Objective

To highlight potential short, medium and long-term dental treatment options for patients presenting with multiple idiopathic cervical root resorption.

Abstract

Multiple Idiopathic Cervical Root Resorption (MICRR) is a rare condition. It initiates at the cement-enamel junction of multiple teeth. The lesions continue to grow until they unite, thereby undermining the entire coronal structure of the affected teeth. Its distribution can vary from a single region to the entire dentition and the number of teeth affected by resorption tends to increase as the condition is followed over time. The teeth themselves appear clinically normal.

The aetiology of MICRR is unknown and it is considered to be a diagnosis of exclusion. The condition tends to be progressive. Consequently, root treatments/surgical curettage and restoration of the lesions have been

unsuccessful at arresting the condition. Affected teeth are often extracted in anticipation of catastrophic fracture and have been replaced with partial or complete dentures. In this case report, we describe how a young female patient was dentally managed over 10 years and ultimately rehabilitated with dental implants

Introduction

Multiple Idiopathic Cervical Root Resorption (MICRR) is an uncommon condition with less than 30 cases having been reported worldwide.¹ It was first reported by Mueller and Moody² and is thought to have a predilection for affecting younger female patients³. Most case reports have identified MICRR in the permanent dentition, however there have isolated cases of the condition affecting the primary dentition as well⁴. Radiologically it initiates at the cement-enamel junction (CEJ) of multiple teeth. The lesions continue to grow until they unite, thereby undermining the entire coronal structure of the affected teeth. It is thought to have a predilection for affecting younger female patients³.

A Systematic Review⁵ has suggested it tends to be an incidental finding on routine clinical/radiological examination with no apparent correlation between any other medical or dental condition. Some patients have reported an increase in tooth mobility but it is an asymptomatic condition. The cases included in the systematic review also suggested that the number of teeth affected ranged from 5 to 24 (per patient) with no predilection for any particular dental site, side or tooth. The distribution of MICRR can vary from a single region to the entire dentition¹ and the number of teeth affected by resorption tends to increase as the condition is followed over time⁵. It is unknown whether there is a genetic predisposition to MICRR. Given that the condition has been identified in both patients and their offspring⁶, a familial pattern of inheritance is likely.

Patients with MICRR tend to have normal alveolar bone levels and blood chemistry values⁷. There tends to be an absence of systemic disease and the resorption itself tends to occur circumferentially on vital teeth. The teeth themselves appear clinically normal. Histological examination of the resorptive sites has revealed the presence of multinucleated giant cells which are indicative of osteoclastic activity⁸.

The aetiology of MICRR is unclear and it is generally considered to be a diagnosis of exclusion.⁹ It has been suggested that the condition is associated with exposure to the feline herpes virus FEHV1^{10,11}. However this link is tenuous and requires further investigation.

Dental management of MICRR is difficult. The condition can spontaneously arrest. However it can equally progress to the point that the affected teeth are so undermined that they effectively decoronate themselves⁵. Currently it is not possible to predict whether MICRR will arrest or progress in any given patient. If the condition is progressive, root treatments/surgical curettage and restoration of the lesions have been unsuccessful at arresting the condition¹². Affected teeth are often extracted in anticipation of catastrophic fracture and have been replaced with dentures¹⁴.

In this case report, we describe how a young female patient was dentally managed over a decade and ultimately rehabilitated with dental implants.

Clinical Report

A 12 year old patient started fixed orthodontic treatment in 2002 (Figure 1). 2 years later she was referred to the Leeds Dental Institute (by her orthodontist) just before her maxillary and mandibular fixed appliances were due to be removed. A dental panoramic tomogram (DPT) revealed that the LL3, LL4, LL5, LL6, UL6, UR3, UR4, UR5 and UR6 had evidence of cervical resorption associated with them (Figure 2).

Clinically the patient's plaque control was very good with minimal bleeding on probing. There was no periodontal pocketing associated with any tooth in the patient's dentition or any obvious pathology (Figure 3). At consultation, the patient's family enquired whether the condition was related to the fixed appliance orthodontic treatment. It is possible for apical resorption to affect teeth undergoing orthodontic tooth movement (due to excessive torquing forces). However, it is unlikely that the multiple cervical lesions in this patient were due to the orthodontic treatment as MICRR has been known to also affect unerupted permanent teeth ¹. Therefore exposure to the oral cavity and some form of environmental insult/trauma does not appear to be a pre-requisite for the condition.

The crowns of the LL3, LL4, LL5 and LL6 spontaneously decoronated but the roots were left in situ to preserve bone. The remaining resorptive lesions were accessed surgically, any granulation tissue was removed and the defects were restored with glass-ionomer cement by the Paediatric Team.

Over the next 2 years, resorptive defects occurred (and re-occurred) on the UR2, UR3, UR4, UR5, UR6, UL2, UL3, UL4, UL5 and LL2 teeth. On multiple occasions, buccal flaps were raised, the resorptive defects curetted and any granulation tissue/coronal tooth structure was sent for further investigation. The UL4, LL3 and UR4 teeth were unrestorable and required extraction. The UR2, UR3, UR5, UR6, UL2, UL3, UL5 and LL2 teeth all required root canal therapy (RCT) as the resorptive defect extended into pulp. The lesions were restored with Calcium Hydroxide and Fugix IX Glass Ionomer Cement (GIC) by the Paediatric team (Figure 4).

Histological examination of the granulation tissue revealed that the lesions were consistent with tooth tissue resorption with an associated proliferation of fibrous gingival connective tissue.

By 2006 it was felt that surgical curettage/repair and RCT of the affected teeth was futile as the lesions were progressive and tended to re-occur. The entire root treated and surgically repaired teeth shown in Figure 4 started to show new clinical signs of cervical root resorption. Any further treatment provided in a similar vein would only serve as a short term measure. After joint discussion between 3 Consultants in Oral/Maxillofacial Surgery, Paediatric and Restorative Dentistry, it was decided to plan for an implant based reconstruction.

The heavily restored, root treated UR6, UR5, UR3, UR2, UL2, UL3, UL5 and LL2 teeth, in addition to the LL4, LL5 and LL6 roots were planned for extraction. Diagnostic waxing suggested that a functional acceptable

result could be achieved if the patient was provided with a 4 unit implant supported bridge in the maxillary left, maxillary right and mandibular left quadrants.

The aforementioned UR6,UR5,UR3,UR2,UL2,UL3,UL5, LL2, LL4,LL5 and LL6 were removed under GA. Radiographs suggested that insufficient bone volume was present in the maxillary left and mandibular left quadrants to allow implant placement. The UL2, UL3 and LR2, LR3 regions were augmented with autogenous bone from the patient's chin under GA in 2007 by the surgical team.

Three 3.3 x 13 Branemark Implant fixtures were placed in the maxillary left quadrant and three more were placed in the maxillary right quadrant. Three 3.5x13mm Astra Implant fixtures were placed in the lower left mandibular quadrant. The implant system changed as a different clinician took over the patient's restorative care.

The implants were exposed and subsequently restored with 3 sets of 4 unit cement retained metal ceramic bridges by the restorative team (Figure 5). The bridges were cemented on with zinc phosphate. The patient was satisfied with the treatment she had received at 1 year review.

Discussion

Given that the MICRR has been known to cluster in families⁶ the patient's parents were made aware of this and advised that their other children should attend regular dental appointments for appropriate radiographic examination. In this patient, the lesions were identified with plain film radiographs. Cone Beam Computerised Tomography (CBCT) scanning may have been a better imaging modality to use. Yu *et al.*¹ identified early lesions on CBCT scans that were not visible on the plain film images. Furthermore the resorptive defects were often more extensive than the radiographs would suggest. They also reported that an interesting feature of the condition was that alveolar bone would grow into the root defects, and increase the height of alveolar bone. Given that this feature promotes the retention of alveolar bone, provision of implant retained restorations (without bony augmentation) may be possible for some of these patients. However it is unknown whether sites of active resorption will have an adverse effect on long term osseointegration¹⁵ and therefore implant retention.

Case reports have suggested that the resorptive process can be arrested with bisphosphonate medication¹³. However this will complicate the provision of implants in the future. Yu *et al.*¹ suggested a more practical protocol to manage these patients. Lesions that have been detected early can be surgically exposed and restored with glass ionomer cement. This can maintain teeth for many years. However the condition is progressive. Providing root treatments, surgical curettage and restoration of resorptive

defects only appears to play a palliative (but important) role in the management of these patients. If the defects are sub-crestal, consideration should be given to restoring the lesions with a bioactive material such as mineral trioxide aggregate (MTA). If a lesion is supra-crestal and in the aesthetic region, composite resin should be used to restore the defect (if moisture control permits). If affected teeth can be retained with these local measures until the patient's growth is complete, alveolar bone levels will be maintained.

As resorption continues to affect larger numbers of teeth, extraction and subsequent prosthodontic rehabilitation should be planned for. In the interim phase, this may take the form of a partial denture.

In the long term, the patient may need to be rehabilitated with fixed bridge work. If conventional/resin bonded bridges are prescribed, the abutment need to be carefully examined to ensure that they are free of resorptive defects. However the patient must be warned that the abutment teeth may also develop lesions in the future and that the bridges will need regular review. Alternatively, implant retained crowns and bridges can be provided. Such restorations appear to have a survival rate of 95% over a 5 year period ¹⁶. Although implant retained restorations have a high survival rate, it must still be remembered that a relatively high proportion can develop complications after a period of 5 years, including fracture of the veneering porcelain (14%), loosening or even fracture of the retaining screws (7%) ¹⁶. Even if the definitive dental rehabilitation is to be implant based, the clinician must remember that further teeth may still be lost in

the future. Therefore one must ensure that design features are incorporated to allow for the addition of further teeth. Perhaps if implant retained bridges are provided for such patients, screw retained frameworks should be planned. This would certainly allow for easy removal, modification and even replacement should further teeth require removal. If however all of the teeth are extensively affected by the resorptive process, a clearance and provision of complete dentures / implant retained overdentures may be necessary.

MICRR is not an endodontic problem. Therefore patients should not be provided with unnecessary root fillings. They require referral to a secondary care unit for appropriate treatment planning. Furthermore their family members should be advised to have their own dentitions checked as the condition can cluster in families ⁶.

The restorative, paediatric and surgical dentist have very important roles to play in this multidisciplinary management with regard to treatment planning. They need to be involved early in the decision making process. Issues regarding the prognosis of compromised teeth and methods of replacement (in both the short and long term) need to be discussed at the outset. These patients will clearly require multiple dental visits and interventions to manage their resorptive defects. Given the progressive nature of the condition, patients should be made aware of this at the beginning of their treatment cycle. They should also be advised that any teeth which have not been removed will require life-long radiographic review, to ensure that they have not developed any new lesions.

Although the dental management of MICRR is technically challenging and time consuming, these patients can be managed successfully using a carefully planned multi-disciplinary approach.

Acknowledgements

We wish to thank the Photography Department at the Leeds Dental Institute for taking all of the photos included in this Case Report.

References

- 1) Yu VSH, Messer HH & Tan KB. Multiple Idiopathic Cervical Resorption: Case Report and Discussion of Management Options. *Int Endod J.* 2010; 44: 77-85.
- 2) Mueller E & Roy HR. Laboratory Studies of an Unusual Case of Resorption. *J Am Dent Ass.* 1930; 17: 326-334.
- 3) Macdonald-Jankowski D. Multiple Idiopathic Cervical Resorption most frequently seen in younger females. *Evid Based Dent* 2005; 6: 20.
- 4) Kim PH & Leslie BH. Multiple Idiopathic Resorption in the Primary Dentition. Review of the Literature and Case Report. *Oral Surg Oral Med Oral Pathol* 1999; 88:501-555.
- 5) Liang H, Burkes EJ & Fredderikson NL. Multiple Idiopathic Cervical Root Resorption: Systematic Review and Report of Four Cases. *Dentomaxillofac Radiol* 2003; 32: 150-5.
- 6) Neely AL, Gordon SC. A Familial Pattern of Multiple Idiopathic Cervical Root Resorption in a Father and Son: a 22 year Follow-Up. *J Periodontol* 2007; 78: 367-371.
- 7) George DI & Miller RL. Idiopathic Resorption of Teeth: A Report of Three Cases. *Am J Orthod.* 1986; 89: 13-20.
- 8) Nikolidakis D, Nokou G, Meijer GJ. Cervical External Root Resorption: 3 Year Follow-Up of a Case. *J Oral Sci* 2008; 4: 487-491.
- 9) Cholia SS, Wilson PHR & Makdissi J. Multiple Idiopathic External Apical Root Resorption: Report of Four Cases. *Dentomaxillofac Radiol* 2005;34: 240-246.

- 10) Von Arx T, Schawalder P, Ackerman M, et al. Human and Feline Invasive Cervical Reorptions: the missing link? Presentation of four cases. *J Endod.* 2009; 35:904-913.
- 11) DeLaurier A, Boyde A, Jackson B, Horton et al. Identifying Early Osteoclastic Resorptive Lesions in Feline Teeth: A model for Understanding the Origin of Multiple Idiopathic Root Resorption. *J Perio Res.* 2009; 44, 248-57.
- 12) Moody AB, Speculand B, Smith AJ et al. Multiple Idiopathic External Resorption of Teeth. *Int J Oral Maxillofac Surg* 1990; 19: 200-202.
- 13) Iwamatsu-Kobayashi Y, Sato-Kuriwade S, Yamamoto T et al., A Case of Multiple Idiopathic External Root Resorption: A 6 Year Follow Up Study. *Oral Surg Oral Med Oral Pathol Oral Radiol Endod* 2005;100:772-779.
- 14) Kerr DA, Courtney RM & Burker EJ. Multiple Idiopathic Root Resorption: Case Report and Discussion of Management Options. *Oral Surg Oral Med Oral Pathol* 1970; 29:552-565.
- 15) Marx RE & Garg AK. Bone Structure, Metabolism and Physiology: Its Impact on Dental Implantology. *Implant Dent* 1998: 7: 267-276.
- 16) Pjetursson BE, Tan K, Lang NP, Brägger U & Egger M, Zwahlen M. A systematic review of the survival and complication rates of fixed partial dentures (FPDs) after an observation period of at least 5 years. *Clin Oral Implants Res.* 2004: 15: 625-42.

Figure Legends and Images

Figure 1: DPT of the Patient taken in 2002, pre-orthodontic treatment.

There was no clinical/radiographic evidence of resorption associated with any tooth

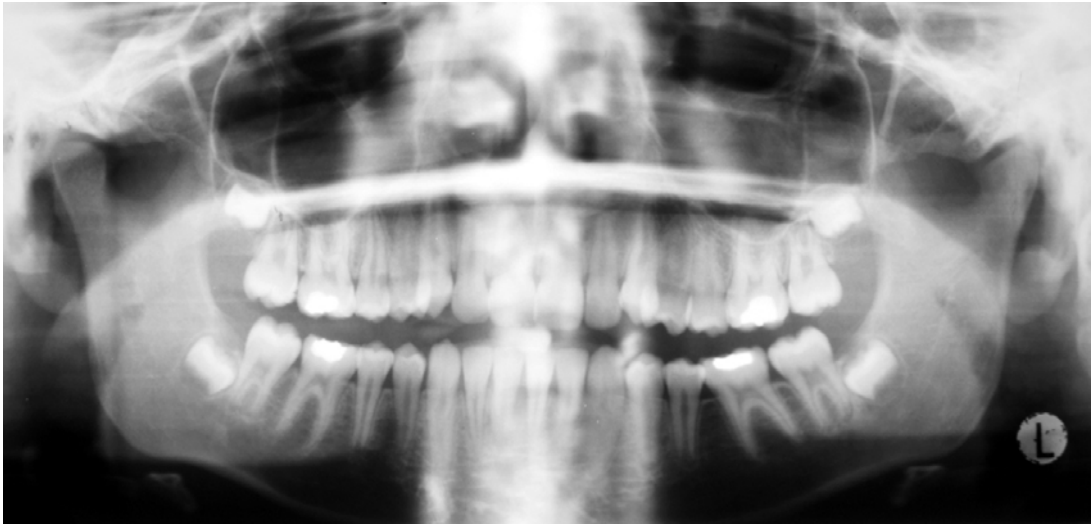


Figure 2: DPT taken in 2004 during Orthodontic Treatment. Note the resorptive lesions associated with the LL3, LL4, LL5, LL6, UL6, UR3, UR4, UR5 and UR6 teeth

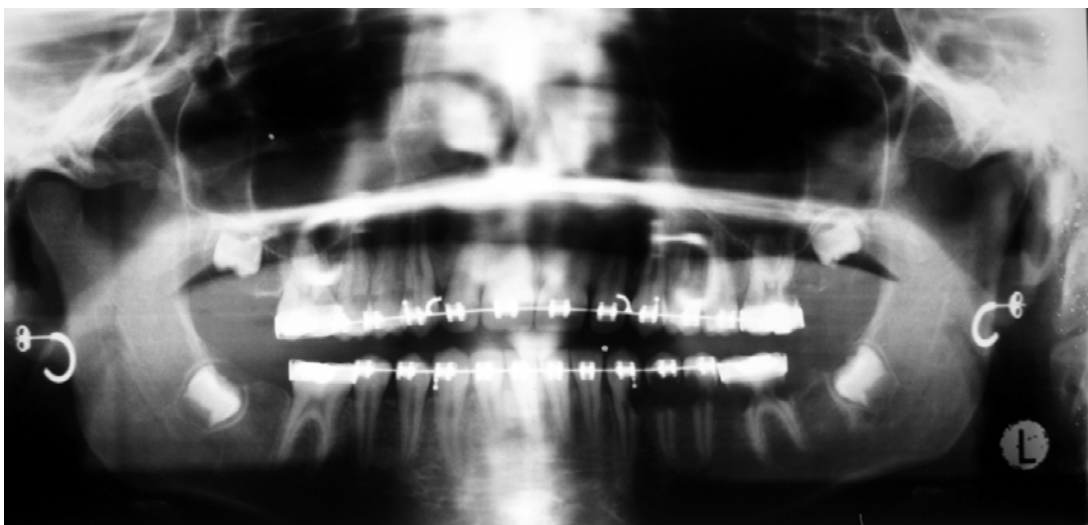


Figure 3 (a): Labial View of the Patient in 2004 after her orthodontic treatment had finished. The orthodontic appliance was left in situ in the lower left quadrant to prevent the teeth from decoronating.

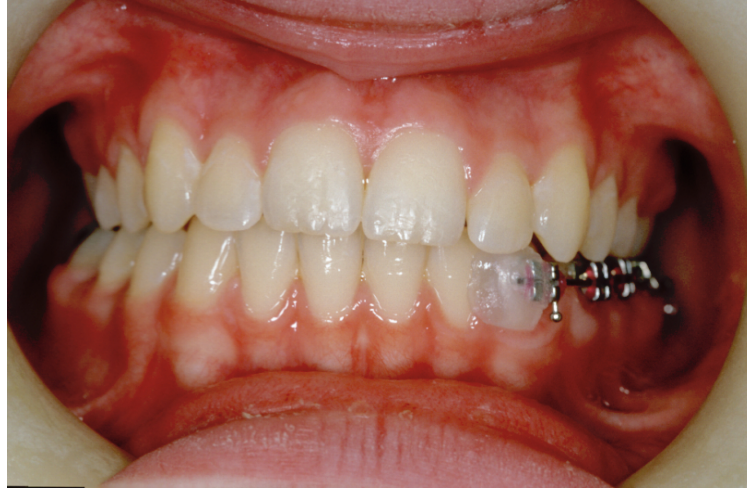

Figure 3 (b): Palatal View of the Patient in 2004. Notice that the teeth appear clinically free of any resorptive defect or pathology.

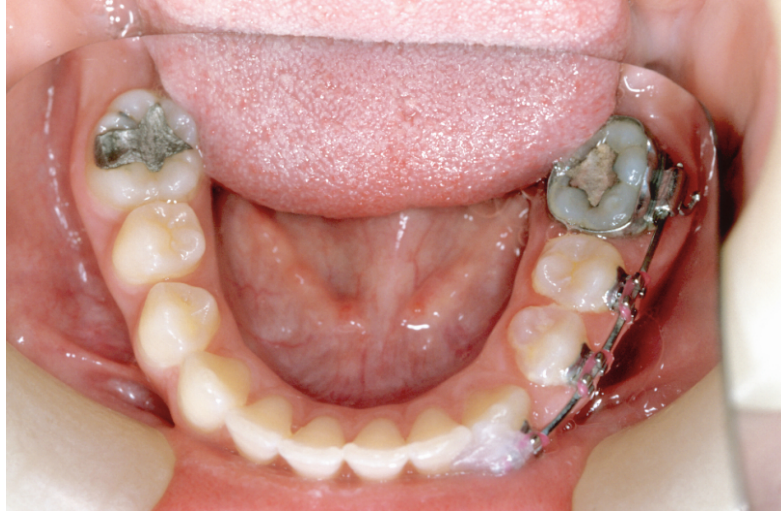

Figure 4: DPT taken in 2006. The teeth affected by resorptive defects have either been root treated and restored with GIC or extracted if found to be unrestorable.

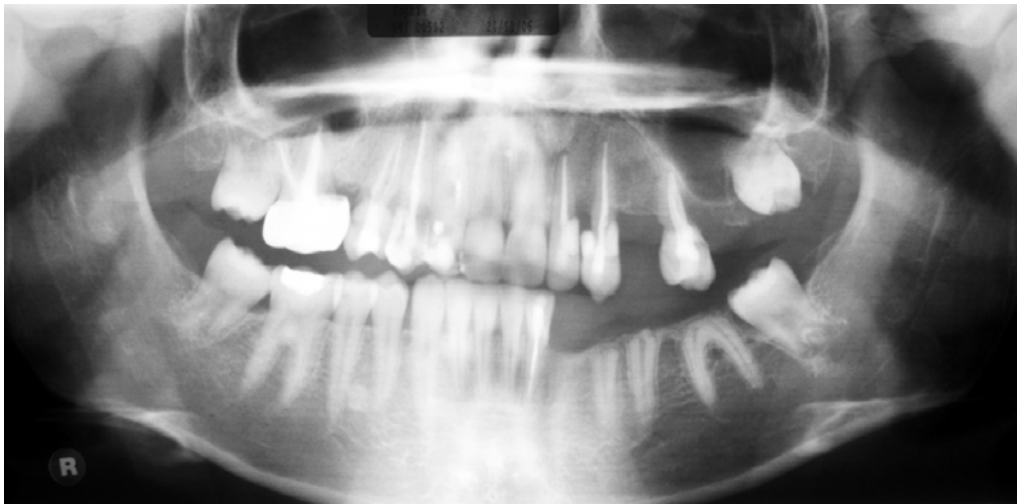


Figure 5 (a): Labial View of the Patient's 4-Unit Cement Retained Implant Supported Bridges in the Maxillary and Mandibular Arches in 2012.

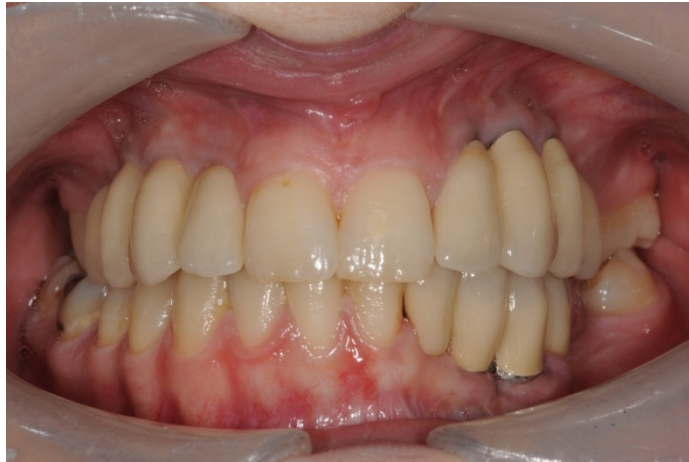

Figure 5 (b): Left Buccal View of the Patient's 4-Unit Cement Retained Implant Supported Bridges in the Maxillary Arch replacing the LL2, LL3, LL4 and LL5 and the Cement Retained Implant Supported Bridge replacing the UL2, UL3, UL4 and UL5 teeth.

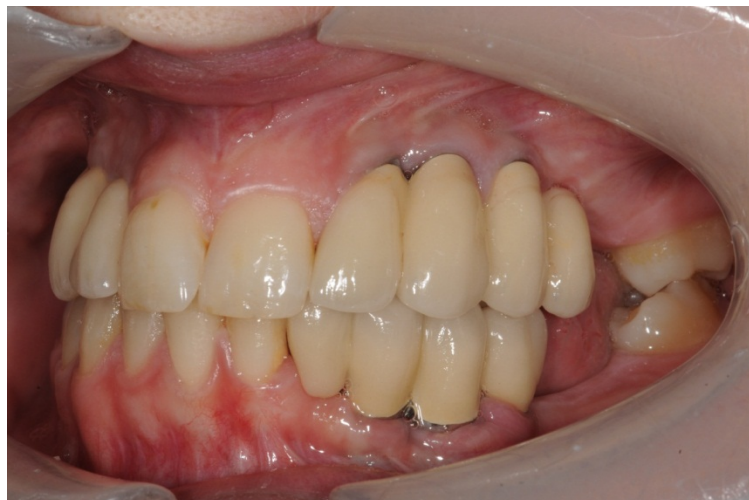

Figure 5 (c): Right Buccal View of the Patient's 4-Unit Cement Retained Implant Supported Bridge in the Maxillary Arch replacing the UR2, UR3, UR4 and UR5 teeth.

