

promoting access to White Rose research papers



Universities of Leeds, Sheffield and York
<http://eprints.whiterose.ac.uk/>

This is an author produced version of a paper published in **Human
Reproduction Update**.

White Rose Research Online URL for this paper:
<http://eprints.whiterose.ac.uk/9074/>

Published paper

Saravelos, S.H., Cocksedge, K.A. and Li, T-C. (2008) *Prevalence and diagnosis of congenital uterine anomalies in women with reproductive failure: a critical appraisal*. Human Reproduction Update, 14 (5). pp. 415-429.

<http://dx.doi.org/10.1093/humupd/dmn018>

TITLE

Prevalence and diagnosis of congenital uterine anomalies in women with reproductive failure: A critical appraisal

RUNNING TITLE

Congenital uterine anomalies in reproductive failure

AUTHORS

Sotirios H Saravelos^{1,3}, Karen A. Cocksedge¹, Tin-Chiu Li^{1,2}

ADDRESS

¹ Reproductive Medicine and Surgery Unit, University of Sheffield, Sheffield Teaching Hospitals, Jessop Wing, Tree Root Walk, Sheffield, S10 2SF, UK.

² Biomedical Research Unit, Jessop Wing, Tree Root Walk, Sheffield, S10 2SF, UK

³ To whom correspondence should be addressed: Email mdb04ss@shef.ac.uk

ABSTRACT

BACKGROUND: The prevalence of congenital uterine anomalies in women with reproductive failure remains unclear, largely due to methodological bias. The aim of this review is to assess the diagnostic accuracy of different methodologies and estimate the prevalence of congenital uterine anomalies in women with infertility and recurrent miscarriage (RM). **METHODS:** Studies from 1950-2007 were identified through a computer MEDLINE search; all relevant references were further reviewed. **RESULTS:** The most accurate diagnostic procedures are combined hysteroscopy and laparoscopy, sonohysterography (SHG) and possibly three-dimensional ultrasound (3D US). Two-dimensional ultrasound (2D US) and hysterosalpingography (HSG) are less accurate and are thus inadequate for diagnostic purposes. Preliminary studies (n=24) suggest MRI is a relatively sensitive tool. A critical analysis of studies suggests that the prevalence of congenital uterine anomalies is ~6.7% [confidence interval (CI) 95%, 6.0 – 7.4] in the general population, ~7.3% (CI 95%, 6.7 – 7.9) in the infertile population and ~16.7% (CI 95%, 14.8 – 18.6) in the recurrent miscarriage (RM) population. The arcuate uterus is the commonest anomaly in the general and RM population. In contrast, the septate uterus is the commonest anomaly in the infertile population, suggesting a possible association. **CONCLUSION:** Women with RM have a high prevalence of congenital uterine anomalies and should be thoroughly investigated. HSG and/or 2D US can be used as an initial screening tool. Combined hysteroscopy and laparoscopy, SHG and 3D US can be used for a definitive diagnosis. The accuracy and practicality of magnetic resonance imaging (MRI) remains unclear.

KEY WORDS

Congenital uterine anomalies/ infertility/ prevalence/ recurrent miscarriage

Introduction

Congenital uterine anomalies have been clearly implicated in women suffering with recurrent miscarriage (RM) (Grimbizis *et al*, 2001). In women with infertility, however, the role of these anomalies, and particularly that of the septate uterus, remains unclear (Homer *et al*, 2000; Taylor and Gomel, 2008). Correct assessment of the prevalence of these anomalies in the RM and infertile populations, and comparison to the general population, will help make any association more apparent. For any population group, the exact prevalence of congenital uterine anomalies is difficult to elucidate mainly due to three reasons:

- i. Different diagnostic procedures used;
- ii. Subjectivity of the diagnostic criteria used (Grimbizis, 2001; Woelfer, 2001); and
- iii. Inconsistent interpretation of the classification of congenital uterine anomalies (Raga, 2003)

There are a number of studies which have investigated the prevalence of congenital uterine anomalies in the RM, infertile and general population. However, they lack consistency in the characteristics of each population examined and homogeneity in the diagnostic methods used. Previous reviews (Acien, 1997; Nahum, 1998; Propst and Hill, 2000; Grimbizis *et al*, 2001; Kupesic, 2001; Troiano and McCarthy, 2004) have not taken these two factors into account when assessing the prevalence of these anomalies. This critical review attempts to determine the true prevalence of congenital uterine anomalies in three populations. This is achieved by assessing and taking into account the

accuracy of different diagnostic procedures, and considering the characteristics of different patient groups.

Methods

Literature search

Articles were identified through a computer MEDLINE search (1950-2007).

References of all relevant articles were hand-searched for additional citations.

There were no language restrictions.

Accuracy of diagnostic procedures

a. Identification of the presence of congenital uterine anomalies

Studies comparing the diagnostic accuracy of different procedures used for assessing congenital uterine anomalies were identified. From these, the studies comparing hysterosalpingography (HSG), sonohysterography (SHG), 2D ultrasound (2D US), 3 D ultrasound (3D US) and magnetic resonance imaging (MRI) to hysteroscopy were selected for analysis. This is because hysteroscopy allows for the direct visualization of the internal uterine contour, and was considered the most valid method of identifying the presence of an anomaly (but not the different subtypes). Sensitivity, specificity, positive predictive value (PPV) and negative predictive value (NPV) for each diagnostic procedure were individually calculated for each study. The value of total correct predictions (accuracy), which is dependent on the prevalence and is of more clinical significance (Altman, 1993), was also estimated using the formula:

$$\text{Accuracy} = \frac{\text{number of True Positives} + \text{number of True Negatives}}{\text{number of True Positives} + \text{False Positives} + \text{False Negatives} + \text{True Negatives}}$$

Finally, the weighted mean values of sensitivity, specificity, PPV, NPV and accuracy were estimated for each procedure from all the studies.

b. Identification of congenital uterine anomaly subtypes

Studies assessing the accuracy of different procedures in diagnosing specific subtypes of congenital uterine anomalies were similarly reviewed. These reports compared the findings of each methodology to a definitive diagnosis made by means of visualization of both the internal and external uterine contour (e.g. hysteroscopy and laparoscopy).

Classification of diagnostic procedures

Following analysis, the diagnostic procedures were ranked into three classes (I – III) according to their diagnostic accuracy:

Class I

Ia. Investigations capable of accurately identifying congenital uterine anomalies and classifying them into appropriate subtypes (accuracy >90%).

Ib. Investigations capable of correctly identifying congenital uterine anomalies (accuracy >90%) without being able to classify them into appropriate subtypes.

Class II

Investigations capable of identifying congenital uterine anomalies with accuracy <90%.

Class III

Investigations of which the accuracy in identifying congenital uterine anomalies is uncertain.

Assessing the prevalence of congenital uterine anomalies

Studies assessing the prevalence of congenital uterine anomalies in three different populations: general/fertile, infertile and recurrent miscarriage, were identified. Studies were excluded when the population examined or the diagnostic methods used, were not accurately defined. Studies were then grouped into three classes (I – III), as described above, according to the diagnostic procedures they used. The mean overall and subtype prevalence of congenital uterine anomalies (for each population group) were then estimated from each class of study.

Uterine development

Embryology

The uterus is formed at around 8-16 weeks of foetal life from the development of the two paired paramesonephric ducts, called Müllerian ducts. The process involves three main stages (Letterie, 1998; Braun *et al*, 2005):

- i. Organogenesis: The development of both Müllerian ducts.
- ii. Fusion: The lower Müllerian ducts fuse to form the upper vagina, cervix and uterus; this is termed lateral fusion. The upper cranial part of the Müllerian ducts will remain unfused and form the Fallopian tubes.
- iii. Septal absorption: After the lower Müllerian ducts fuse, a central septum is left which starts to resorb at approximately 9 weeks eventually leaving a single uterine cavity and cervix.

It is also important to note the role of the mesonephric (or Wolffian) ducts. These are a precursor and inducer of female reproductive tract development, and play a crucial role in renal development (Hannema and Hughes, 2007). In addition, they act with the Müllerian tubercle to form part of the vagina. As a result, abnormalities originating from mesonephric maldevelopment may also have an effect on genital tract and uterine formation (Acien *et al*, 2004).

This is reflected in the fact that up to 60% of women with unilateral renal agenesis have been shown to have genital anomalies (Barakat, 2002), most commonly a unicornuate uterus (Troiano, 2004). Interestingly, approximately 40% of all patients with a unicornuate uterus suffer from renal abnormalities (Fedele *et al*, 1996), while one study showed that more than 80% of patients with a uterus didelphys suffered from renal agenesis (Li *et al*, 2000). Consequently, the detection of a congenital renal abnormality should alert the physician to look for associated genital anomalies and vice versa (Oppelt *et al*, 2007).

Genetics

The role of genetic factors in the development of uterine anomalies remains unclear (Kobayashi and Behringer, 2003). A study of 1397 cases by Hammoud *et al* (2008) showed that there is strong evidence for familiarity contributing to congenital uterine anomalies, with first-degree relatives having a 12-fold risk of developing an abnormality. However, a specific genetic aetiology for each type of anomaly was considered unlikely, as members of the same family had different phenotypic expressions of uterine anomalies. The authors concluded that in addition to genetic predisposition, socioeconomic and geographic factors may

also play a role, as the pattern of familial clustering was shown to be consistent with polygenetic/multifactorial disorders.

Interestingly, Rabinson *et al* (2006) in a study of 24 women with uterine anomalies, found that 22.7% had an undiagnosed sensorineural hearing loss (200-fold higher rate than expected). Similar findings have been previously reported in the literature (Letterie and Vauss, 2001). Although the authors of this study were unable to identify a possible mutation contributing to this association, they suggested routine referral of all patients with congenital uterine anomalies for audiometric testing (Rabinson *et al*, 2006).

Nevertheless, there has been recent progress in understanding certain genetic processes that underlie genital tract development (Kobayashi and Behringer, 2003; Hannema and Hughes, 2007). Several genes, such as *Pax2* (paired box gene 2), *Pax8* (paired box gene 8), *Lim1* (LIM homeobox 1) and *Emx2* (empty spiracles homeobox 2), have been implicated in the development of the Wolffian and Müllerian ducts, although most data has been derived from mouse knockout studies (Hannema and Hughes, 2007). In addition, genes responsible for certain human syndromes that also affect the reproductive tract have been identified. Examples include Maturity-onset diabetes of the young type V (*TCF2* mutation), McKusick-Kaufman syndrome (*MKKS* mutation), Persistent Müllerian duct syndrome type I and II (*MIS* and *MISR2* mutations) and Hand-foot-genital syndrome (*HOXA13* mutation) (Kobayashi and Behringer, 2003).

Classification of congenital uterine anomalies

Congenital uterine anomalies may arise from malformations at any step of the Müllerian developmental process (Devi Wold, 2006). Buttram and Gibbons

(1979) first proposed a classification of the congenital uterine anomalies based on the degree of failure of the Müllerian ducts to develop normally, and divided them into groups with similar clinical manifestations, treatments and prognosis. This was revised and modified first in 1983 and then in 1988 by the American Society of Reproductive Medicine (formerly known as the American Fertility Society) to provide a classification which is now the most widely accepted and used worldwide (Figure I) (Letterie, 1998). This consists of seven groups, some with further subdivisions (Devi Wold, 2006):

I. Müllerian agenesis or hypoplasia

- a. Vaginal
- b. Cervical
- c. Fundal
- d. Tubal
- e. Combined

II. Unicornuate uterus (agenesis or hypoplasia of one of the two Müllerian ducts)

- a. With a communicating rudimentary horn
- b. With a non-communicating rudimentary horn
- c. With a rudimentary horn with no cavity
- d. With an absent rudimentary horn

III. Didelphys uterus (failure of lateral fusion of the vagina and uterus Müllerian ducts)

IV. Bicornuate uterus (incomplete fusion of the uterine horns at the level of the fundus)

- a. Complete

b. Partial

V. Septate uterus (absent or incomplete resorption of the uterovaginal septum)

a. Complete

b. Partial

VI. Arcuate uterus (a mild indentation at the level of the fundus from a near-complete resorption of the uterovaginal septum)

VII. Diethylstilbestrol (DES) exposed uterus (T-shaped uterus resulting from DES exposure of the patient in utero)

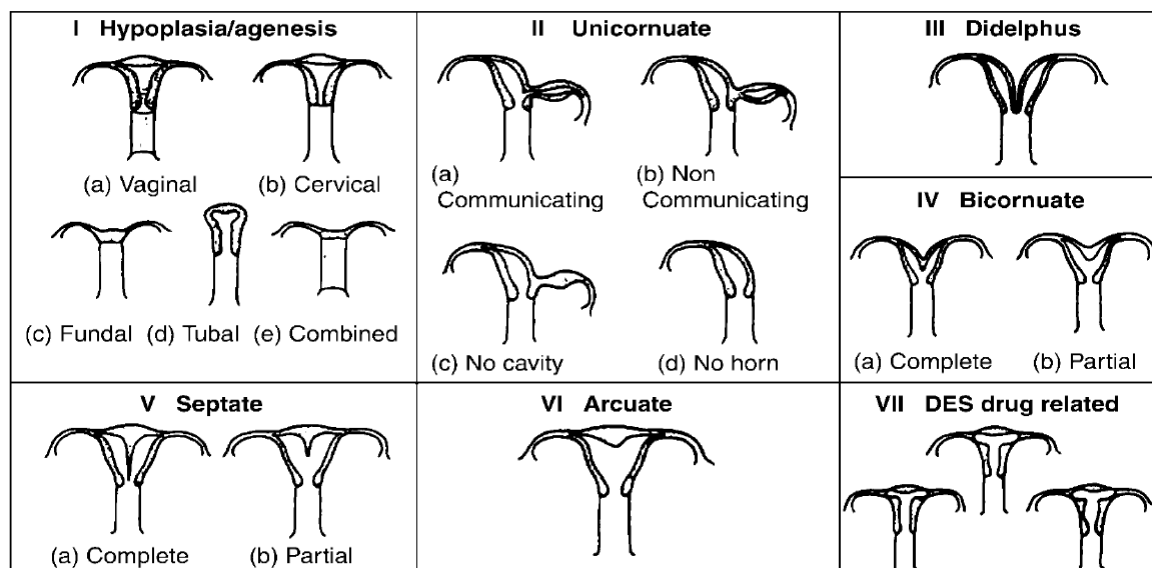


Figure I: Classification of congenital uterine anomalies as described by the American Fertility society (1988)

One limitation of this classification is that it does not specify the diagnostic methods or criteria that should be used in order to diagnose the anomalies and as a result this is solely based on the subjective impression of the clinician performing the test (Woelfer, 2001).

In addition, this classification is by no means comprehensive. A number of rarer anomalies, such as a hypoplastic non-cavitated uterus with two rudimentary

horns (Sadik *et al*, 2002), a uterus with a vaginal anastomosis and cervical atresia (Deffrages *et al*, 2001), a septate uterus with cervical duplication and a longitudinal vaginal septum (Wai *et al*, 2001; Pavone *et al* 2006) and a normal uterus with a double cervix and vagina, and a blind cervical pouch (Dunn and Hantes, 2004) are not included. For this reason, the American Fertility Society classification system should function as a framework for the description of anomalies, rather than an exhaustive list of all possible anomaly types. Consequently, clinicians faced with complex or combined uterine anomalies, should try to describe them according to their component parts rather than categorize them into the class that most approximates the dominant feature (Troiano, 2004).

The above concept has been incorporated in another more recent classification proposed by Oppelt *et al* (2005): the VCUAM classification. This intends to make the description of complex genital anomalies easier by subdividing external and internal female genital organs into the following subgroups: vagina (V), cervix (C), uterus (U), adnexa (A) and associated malformations (M). An anomaly is therefore graded individually for each anatomical structure. For example, a particular case of uterus didelphys could be described as: V2b (complete septate vagina), C1 (duplex cervix), U2 (bicornate uterus), A0 (normal adnexa), M0 (no associated malformations) (Oppelt *et al*, 2005).

Finally, Acien *et al* (2004) have stressed the importance of considering the embryological origin of the different elements of the genitourinary tract in order to understand and effectively treat complex genital tract anomalies. For this reason, they proposed the revised 'Clinical and embryological classification of the

malformations of the female genital tract', which classifies anomalies according to their embryological origin, and includes changes in the vagina, adnexa, and renal system in addition to those of the uterus, (Acien *et al*, 2004).

Diagnostic procedures: characteristics and accuracy

Hysterosalpingography

Hysterosalpingography (HSG), first performed by Rindfleisch in 1910 (Golan, 1989), is a widely acceptable and available diagnostic tool. It provides valuable information regarding the interior cavity of the uterus. When it shows a unicornuate uterus, however, a second cervical opening must be considered; if it is found, further injection of contrast into the cervix may lead to the diagnosis of a uterine didelphys or a complete septate uterus (Letterie, 1998). In assessing a unicornuate uterus with HSG, blocked or non-communicating rudimentary horns will not appear on film (Propst and Hill, 2000). This is of significance as studies have reported that in patients with such anomaly, 13% of pregnancies occur in the non-communicating rudimentary horn, secondary to transmigration of sperm (Letterie, 1998). As this would warrant removal of the rudimentary horn due to possible rupture, it is of great importance that non-communicating rudimentary horns are correctly identified and differentiated. By removing rudimentary horns, dysmenorrhoea and endometriosis (caused by retrograde menstrual effluent) may also be reduced or prevented (Taylor and Gomel, 2008). Transabdominal ultrasound has demonstrated 85% sensitivity and 100% specificity in diagnosing the presence of a rudimentary horn, and 80% sensitivity and 100% specificity in assessing the presence of a cavity in that horn. This was shown to be more accurate than a laparoscopic investigation (Litterie, 1998). In cases where clear ultrasound imaging is not achieved, MRI could be of use.

HSG does not evaluate the external contour of the uterus and therefore it cannot reliably differentiate between a septate and a bicornuate uterus (Kupesic, 2001; Troiano and McCarthy, 2004; Braun, 2005). Some authors suggest that an

angle of less than 75° between the uterine horns is suggestive of a septate uterus and an angle of more than 105° indicates a bicornuate uterus (Litterie, 1998; Troiano and McCarthy, 2004). Interestingly, an angle of less than 60° has been used for identifying septate uteri in MRI and US imaging (Litterie, 1998). However, a diagnostic accuracy of 55% in differentiating between the two has been reported in the past (Reuter *et al*, 1989), although the criteria used in this study are not known. Small septal defects can also be missed with HSG (Homer *et al*, 2000). In contrast, it has been considered accurate in diagnosing most DES-linked uterine anomalies (Nguyen, 1997).

HSG has been reported to produce pain in more than half the patients, although often not severe enough to require analgesia (Homer *et al*, 2000). Guilmares Filho *et al* (2006) reported that 93.3% (n=56) of women experienced moderate to severe pain during HSG although they did not mention whether analgesia was required. In contrast, Tur-Kaspa *et al* (1998) in a prospective randomized blinded study of 61 patients, found that from a pain scale of 0-10 (10 being very severe pain) women scored the HSG as being 5.6 ± 2 when a metal cannula was used and 3.8 ± 2 when a balloon catheter was used. The difference reached statistical significance, and the authors concluded that balloon catheter HSG is superior to the traditional metal cannula technique, as it also requires significantly less fluoroscopic time, a smaller amount of contrast agent, is easier for the physician to perform and allows for concurrent transcervical tubal catheterization (Tur-Kaspa *et al*, 1998).

Complications of HSG include pelvic inflammatory disease, particularly if the patient has previous tubal disease or is *Chlamydia trachomatis* positive (Homer *et al*, 2000). Bleeding, and rarely reaction to the contrast media or uterine

perforation may also occur (Simpson, 2006). In addition, there is exposure to radiation and iodinated contrast media, although this has been shown to be within the safety limits (Litterie, 1998; Homer, 2000).

There have been a number of reports assessing the diagnostic accuracy of HSG versus hysteroscopy. A summary of the reports is shown in Table I.

Although the weighted mean of sensitivity and specificity of HSG according to our review is approximately 78% and 90% respectively, this investigation seems to be poor in differentiating between classes of congenital anomalies. Alborzi *et al* (2003) reported only 25% sensitivity in diagnosing bicornuate uteri. Furthermore, Pellerito *et al* (1992), in an attempt to categorize congenital abnormalities into different types, found HSG to be incorrect in all 20 cases.

In conclusion, HSG remains a useful screening tool for the diagnosis of a normal or abnormal uterine cavity (Letterie, 1998). It has a good sensitivity for diagnosing uterine malformations with a more aggressive morphological expression (Soares *et al*, 2000); however, it cannot reliably differentiate between different types of congenital uterine anomalies.

Table I: Sensitivity, specificity, positive predictive value (PPV) and negative predictive value (NPV) of HSG compared with hysteroscopy in diagnosing congenital uterine anomalies (Total cases $n = 625$)

Study	Cases n	Sensitivity	Specificity	PPV	NPV	Accuracy
Alatas <i>et al</i> , 1997	62	100	100	100	100	100
Brown <i>et al</i> , 2000	46	100	100	100	100	100
Traina <i>et al</i> , 2004	80	100	97	85	100	96
Valenzano <i>et al</i> , 2006	54	91	100	100	94	96
Keltz <i>et al</i> , 1997	18	90	20	53	67	58
Raziel <i>et al</i> , 1994	60	74	59	62	72	67
Alborzi <i>et al</i> , 2003	186	70	92	83	88	83
Guilmares Filho <i>et al</i> , 2006	54	63	98	83	94	85
Soares <i>et al</i> , 2000	65	44	96	67	92	75
Weighted mean		78	90	83	91	86

Two-dimensional ultrasound (2D US)

Transabdominal or transvaginal US is a readily available diagnostic tool which is widely accepted and used. In assessing the presence of congenital uterine anomalies it may play a useful role. The advantage of US is that it allows measurements and quantification of observations to be made. However, there are no universally accepted criteria for the US diagnosis of congenital uterine anomalies. Different authors appeared to implement their own criteria. In a double cavity appearance of a uterus on US, Fedele *et al* (1989) and Troiano and McCarthy (2004) consider a uterus to be septate rather than double (i.e. bicornuate or didelphys) when there is a fundal distal border indentation of 5mm

above the line joining the two ostia (interostial line) or less. In contrast, Wu *et al* (1997), Litterie (1998) and Woelfer *et al* (2001) consider the uterus to be septate when the fundal indentation is less than 10mm *below* the interostial line. There have also been quotes of a threshold of 10mm of fundal indentation used in laparoscopy (Troiano and McCarthy, 2004). The use of an angle of less than 60° between the two indenting medial margins of the fundus can similarly be used to distinguish between the septate and bicornuate uterus. Nicolini *et al* (1987) reported that using these criteria, 92% sensitivity and 100% specificity in diagnosing bicornuate uteri can be achieved (Nicolini *et al*, 1987). However, the value of these criteria remains unclear. The measurement of the serosal-endometrial thickness of the uterus along its fundal border in longitudinal sections could also be used as a criterion to aid diagnosis; in the septate uterus the thickness should increase reaching the midline as the septate becomes apparent (Litterie, 1998). However, there is no evidence in the literature of such criteria which describe the septate uterus and differentiate it from the arcuate deformity.

Pooled data from reports comparing 2D US and hysteroscopy suggest low sensitivities of under 60% but high specificities of nearly 100%. Results from these studies are summarized in Table II.

Although some authors in the past have quoted an accuracy of 90-92% in diagnosing congenital uterine anomalies (Byrne, 2000; Troiano and McCarthy, 2004), we failed to find valid reports (comparing 2D US to hysteroscopy) showing sensitivities of more than 90%. There seems to be a pattern of low sensitivities coupled with high specificities with 2D US imaging. This suggests that although 2D US can only identify about half of the congenital uterine anomalies present, its diagnosis is very likely to be correct (due to its very low

false positive rate). Therefore, it could prove to be a very effective screening tool in conjunction with HSG since they are both widely available.

Table II: Sensitivity, specificity, positive predictive value (PPV) and negative predictive value (NPV) of 2D US compared with hysteroscopy in diagnosing congenital uterine anomalies (Total cases $n = 350$)

Study ¹	Cases n	Sensitivity	Specificity	PPV	NPV	Accuracy
Valenzano <i>et al</i> , 2006	54	86	100	100	91	94
Alatas <i>et al</i> , 1997	62	50	100	100	97	87
Nicolini <i>et al</i> , 1987	89	43	98	94	68	76
Traina <i>et al</i> , 2004	80	64	99	88	94	86
Soares <i>et al</i> , 2000	65	44	100	100	92	84
Weighted mean		56	99	96	87	84

¹Studies by Raga *et al* (1996) and Jurkovic *et al* (1995) are not included due to inadequate diagnostic method of comparison used.

Sonohysterography

Sonohysterography (SHG) is also known as hysterosonography or saline-infused sonography (Devi Wold, 2006). It uses the introduction of fluid into the uterine cavity to enhance US imaging studies. It therefore improves the internal delineation of the uterine contour. It is a safe procedure (Hamilton, 1998) and not particularly painful for the patient (Amborzi, 2003). Guilmares Filho (2006) reported that 21.7% ($n=13$) women undergoing SHG experienced some degree of pain, which was however significantly reduced compared to HSG or hysteroscopy. Kelekci *et al* (2005) also reported significantly lower pain scores for SHG compared to hysteroscopy (4.3/10 vs 7.2/10; $p=0.042$).

Reports comparing SHG with hysteroscopy have suggested that SHG is highly accurate in both diagnosing and categorizing congenital uterine anomalies. The weighted mean sensitivity and specificity was 93% and 99% respectively. A summary of the reports reviewed are shown in Table III.

It appears that SHG is a safe procedure which provides more information about uterine abnormalities than HSG or US alone (Devi Wold, 2006). It seems to be accurate not only in diagnosing congenital uterine anomalies, but also in classifying them into appropriate groups (Ventolini, 2004; Valenzano, 2006).

Table III: Sensitivity, specificity, positive predictive value (PPV) and negative predictive value (NPV) of SHG compared with hysteroscopy in diagnosing congenital uterine anomalies (Total cases $n = 486$)

Study	Cases <i>n</i>	Sensitivity	Specificity	PPV	NPV	Accuracy
Alatas <i>et al</i> , 1997	62	100	100	100	100	100
Brown <i>et al</i> , 2000	46	100	100	100	100	100
Keltz <i>et al</i> , 1997	18	100	100	100	100	100
Valenzano <i>et al</i> , 2006	54	100	100	100	100	100
Guilmares Filho <i>et al</i> , 2006	55	100	94	73	100	92
Alborzi <i>et al</i> , 2003	186	91	100	100	96	97
Soares <i>et al</i> , 2000	65	73	100	100	97	93
Weighted mean		93	99	97	98	97

Three-dimensional ultrasound (3D US)

As in the case of 2D US, 3D US is a non-invasive method of investigation. 3D US works by attaining an initial 2D US image of the uterus and storing it onto a computer. A vaginal transducer then performs a sweep of transversal sections which are also subsequently stored. The computer then integrates the images and allows the investigator to view images of three planes simultaneously (Raga, 1996). This 3D image, along with the complete volume scan, can be stored for later viewing and appraisal (Devi Wold, 2006). As discussed above, both 2D and 3D US allow for the uterine dimensions to be measured, which could help in quantifying the morphological defects (Salim, 2004). The introduction of appropriate criteria could improve the homogeneity of diagnoses in the future. A study by Salim *et al* (2003b) evaluated the interobserver variability of 83 US volumes using two different observers, who were blind to each other's findings. The results showed a 99% agreement between the two observers, suggesting that this investigation is highly reproducible.

Unfortunately there have not been many reports comparing the accuracy of 3D US to hysteroscopy and or laparoscopy. Four reports identified in the literature, containing an overall of 679 subjects, all reported 100% sensitivity, specificity, PPV, NPV and accuracy of 3D US in diagnosing congenital uterine anomalies, when compared with hysteroscopy (Wu *et al*, 1997; Radoncic *et al*, 2000; Makris *et al*, 2007a; Makris *et al*, 2007b). However, in the studies by Makris *et al* (2007a, 2007b), only a small number of congenital uterine anomalies were identified in the groups of women screened, Two other studies were excluded as their method of comparison were investigations other than hysteroscopy (Jurkovic *et al*, 1995; Raga *et al*, 1996).

In conclusion, reports suggest that 3D US has a very high accuracy rate in diagnosing congenital uterine anomalies. Wu *et al* (1997) further showed that it is accurate in classifying the anomalies, although further studies are required to confirm this. With the prospect of an introduction of a classification based on 3D US criteria, this method seems promising.

Hysteroscopy

Hysteroscopy allows direct visualisation of the intrauterine cavity and ostia. It is therefore very accurate in identifying congenital uterine anomalies and is often used to establish a definitive diagnosis after an abnormal HSG finding (Letterie, 1998; Soares *et al*, 2000; Homer *et al*, 2000). However, it does not allow for the evaluation of the external contour of the uterus and is therefore often inadequate in differentiating between different anomaly types. Consequently, for the correct differentiation between bicornuate and septate uteri, further investigation is required, most commonly a diagnostic laparoscopy. Some authors consider this combination (hysteroscopy/laparoscopy) to be the gold standard in evaluating congenital uterine anomalies (Hamilton *et al*, 1998; Litterie, 1998; Homer *et al*, 2000; Grimbizis *et al*, 2001; Taylor and Gomel, 2008). However, it can still be criticized for relying solely on the subjective impression of the clinician and not on strict diagnostic criteria (Woelfer, 2001). Hysteroscopy with laparoscopy offers the added advantage of concurrent treatment, as in the case of a uterine septum resection.

Bettochi *et al* (2007) recently proposed a new method for differentiating between a septate and bicornuate uterus with the use of office hysteroscopy alone, in a procedure that may also be performed without the use of anaesthesia or

analgesia. Three criteria were used while assessing 260 patients with a double uterine cavity: the presence of vascularized tissue, sensitivity of the tissue based on its innervation, and its appearance at incision (if suspected to be a septum). In this series, 93.1% of the patients went on to successfully undergo an office hysteroscopic metroplasty during this procedure. In 15 of 18 (83%) patients who underwent laparoscopy, the diagnosis of a suspected bicornuate uterus was confirmed.

Ultimately, the main disadvantage of hysteroscopy is the invasiveness of the procedure which in the past was usually performed under general anaesthetic. Nowadays, hysteroscopy is often performed under local anaesthetic. Complications are similar to HSG although rarely air emboli or uterine perforation may also occur (Kupesic, 2001).

Magnetic resonance imaging (MRI)

MRI offers a non-invasive approach of assessing the internal and external contour of the uterus. Criteria used to distinguished bicornuate from septate uteri are often similar to those used in US: a 10mm threshold of fundal indentation, an intracornual distance of more than 4cm or an angle between the two indenting medial margins of the fundus of more than 60° (Litterie, 1998). Pellerito *et al* (1992) reported 100% accuracy ($n = 24$) in assessing women with a surgically proven uterine anomaly; results were compared to hysteroscopy and laparoscopy. Fedele *et al* (1989) reported 100% sensitivity ($n = 4$) and 79% specificity (11/14) in diagnosing congenital uterine anomalies; however their results were compared to HSG and laparoscopy.

MRI seems a relatively sensitive tool and some authors suggest that it could supplant invasive procedures such as laparoscopy for the diagnosis of a double uterus (Nguyen, 1997). However, due to the lack of evidence more studies are required to confirm its diagnostic accuracy.

Which method to use

Overall, hysteroscopy and laparoscopy, SHG and 3D US are the most accurate investigations and can be used as diagnostic tools. 3D US offers the advantage of being non invasive. SHG requires the introduction of fluid into the uterine cavity and this can often be uncomfortable. Hysteroscopy and laparoscopy are both invasive procedures; however they offer the advantage of concurrent diagnosis and treatment. Hysteroscopy alone can identify the presence of an anomaly but cannot accurately differentiate between the different subtypes.

2D US is the least accurate method of investigation; however it is the most widely available and easiest to perform. If used in conjunction with HSG, it can increase accuracy and serve as a valuable screening tool, particularly in the absence of 3D US, or where SHG is not practiced. MRI seems to be more accurate than 2D US or HSG alone, and could potentially be used for screening. However, its diagnostic accuracy remains unclear. Disadvantages are that it is more expensive than US and HSG, and is not available in the office setting.

A summary and classification of the procedures reviewed according to their diagnostic accuracy is presented in Table IV.

Table IV: Classification of investigations according to diagnostic accuracy

Class Ia

Investigations capable of accurately identifying congenital uterine anomalies and classifying them into appropriate subtypes (accuracy > 90%):

1. Hysteroscopy and laparoscopy
2. SHG
3. 3D US

Class Ib

Investigations capable of accurately identifying congenital uterine anomalies (accuracy > 90%) without being able to classify them into appropriate subtypes:

1. Hysteroscopy alone

Class II

Investigations capable of identifying congenital uterine anomalies with an accuracy < 90%:

1. HSG
2. 2D US

Class III

Investigations of which the accuracy in diagnosing congenital uterine anomalies is uncertain:

1. MRI
 2. Physical examination during pregnancy or delivery
-

Prevalence

In assessing the prevalence of congenital uterine anomalies, investigators have used different diagnostic methods, some of which may be more accurate than others. In this aggregate analysis we grouped the studies into three classes (as shown in Table IV) according to the diagnostic accuracy of the methods they used: i.e. class Ia studies used hysteroscopy/laparoscopy, SHG or 3D US; class Ib studies used hysteroscopy alone; class II studies used HSG or 2D US; and class III studies used a methodology of uncertain accuracy. The prevalence was then estimated for each class of studies.

General population

Assessing the prevalence of congenital uterine anomalies in the general population poses added difficulties. Many congenital uterine anomalies remain asymptomatic and investigations such as HSG, hysteroscopy and laparoscopy would not be warranted in women without a particular indication. The studies reviewed in this paper include patients either undergoing sterilization or being investigated for non-obstetric reasons such as pelvic pain, ovarian cancer screening, abnormal bleeding and suspected fibroids (Woelfer *et al*, 2001). Consequently the results are indicative of the fertile and general population combined. However, it has to be noted that the varying presentation of the patients and their different background/origin may have an effect on the homogeneity of the results. A summary of the studies reviewed is shown in Table V. The pooled prevalence estimated using these studies is summarized in Table VI.

According to our evaluation of the literature, the prevalence of congenital uterine anomalies in the fertile/general population based on class Ia and Ib studies is approximately 6.7% (CI 95%, 6.0 – 7.4). This is higher than what is most commonly quoted in the literature (Grimbizis *et al*, 2001; Troina, 2004; Nauhum, 2006). Class II investigations seem to indicate a pooled prevalence of 2.4%, suggesting under-diagnosis. The 60-80% sensitivity of these class II investigations could have contributed to the finding of this lower prevalence.

The commonest congenital uterine anomaly diagnosed in both class I and class II investigations seems to be that of the arcuate uterus. This is different to the finding of other reviews which considered the septate uterus to be the commonest (Grimbizis *et al*, 2001; Troiano and McCarthy, 2004; Taylor and Gomel, 2008). According to the findings of this review the commonest anomalies follow the order of arcuate, septate and bicornuate at a ratio of approximately 17:7:1 (based on class Ia studies). It is interesting to note that this seems to follow the inverse sequence of the embryological events that occur during uterine formation. A unicornuate uterus was noted in only one of the three class Ia studies (Salim *et al*, 2003) thus indicating a prevalence of approximately 1 in 4000 women. In contrast, class II studies suggested a prevalence of 1 in 1000 women. Keeping in mind that 3 of the 5 class II studies (Raga, 1997; Acien, 1997; Sorensen, 1988) used HSG with laparoscopy (an accurate way of diagnosing unicornuate uteri), the rate of 1 in 1000 may be closer to the true prevalence. This may suggest that 3D US (which comprised 3 of 4 class Ia studies reviewed) is not so sensitive in identifying unicornuate uteri. It could be that the single cavity of the unicornuate uterus is misleading when seen on US and is confused with a normal single uterine cavity. Similarly the transvaginal 2D US used as an initial

screening method by Salim *et al* (2003) could have the same limitation. In addition, the use of 2D US as a screening tool could have led to an overall under-diagnosis of all congenital uterine anomalies in that study (as this investigation has shown to be approximately 60% sensitive). HSG should not have the limitation of under-diagnosing unicornuate uteri as the Fallopian tubes would be depicted on X-ray, unless a blocked tube is present. Similarly the tubal ostia should be visualized by hysteroscopy.

Table V: Prevalence of congenital uterine anomalies in the general/fertile population (US=ultrasound; TVS=transvaginal ultrasound; TAS=transabdominal ultrasound; HSG=hysterosalpingography; SHG=sonohysterography; HSc=hysteroscopy; Lap=laparoscopy/Laparotomy)

Class	Study	Country	Cases <i>n</i>	Reason for investigation	Initial Investigation	Definitive Investigation	Total <i>n</i> (%)	Hypoplastic <i>n</i> (%)	Unicornuate <i>n</i> (%)	Didelphys <i>n</i> (%)	Bicornuate <i>n</i> (%)	Septate <i>n</i> (%)	Arcuate <i>n</i> (%)	T-shaped <i>n</i> (%)
Ia	Salim <i>et al</i> , 2003 ¹	UK	1976	Not stated	2D TVS	3D US	105 (5.3)	-	1 (0.05)	-	4 (0.2)	28 (1.4)	72 (3.6)	-
	Woelfer <i>et al</i> , 2001 ¹	UK	1089	Non-obstetric	-	3D TVS	106 (9.7)	-	-	-	5 (0.5)	29 (2.7)	72 (6.6)	-
	Jurkovic <i>et al</i> , 1997	UK	1047	Various	-	3D US	55 (5.3)	-	-	-	-	-	-	-
	Tur-Kaspa <i>et al</i> , 2006	Canada/ USA	409	Abnormal uterine bleeding	-	SHG	39 (9.5)	-	-	1 (0.2)	1 (0.2)	11 (2.7)	26 (6.4)	-
Ib	Cooper <i>et al</i> , 1983	-	323	Hysteroscopic sterilization	-	HSc	20 (6.2)	-	-	-	-	-	-	-
II	Byrne <i>et al</i> , 2000	USA	2065	Non-obstetric	-	TAS/TVS	8 (0.4)	-	-	3 (0.1)	3 (0.1)	2 (0.1)	-	-
	Raga <i>et al</i> , 1997	Spain	1289	Tubal sterilization	-	HSG/Lap	49 (3.8)	-	2 (0.2)	1 (0.1)	5 (0.4)	20 (1.5)	21 (1.6)	-
	Simon <i>et al</i> , 1991 ²	Spain	679	Tubal sterilization	-	HSG/Lap	22 (3.2)	-	-	1(0.1)	1 (0.1)	20 (2.9)	-	-
	Ashton <i>et al</i> , 1988 ³	-	840	Transcervical sterilization	-	HSG	19 (2.3)	-	1 (0.1)	-	-	15 (1.8)	-	3 (0.4)
	Nasri <i>et al</i> , 1990	UK	300	Multiple	-	2D TVS	8 (2.7)	-	-	2 (0.7)	-	6 (2.0)	-	-
	Acien <i>et al</i> , 1997 ⁴	Spain	241	Contraception	2D TVS	HSG/Lap	26 (10.8)	5 (2.1)	1 (0.4)	-	3 (1.2)	4 (1.7)	13 (5.4)	-
	Sorensen, 1988 ⁵	Denmark	111	Laparoscopic sterilization	-	HSG/Lap	6 (5.4)	-	1 (0.9)	1 (0.9)	-	4 (3.6)	-	-
III	Nahum, 1998 [Review: 1947-1990] ⁶	-	571619	Pregnancy/ Delivery	-	Various	927 (0.16)	-	-	-	-	-	-	-

1 May have similar cases.

2 Included in the study by Raga *et al* (1997) and thus not included in Table VI.

3 Bicornuate/septate diagnosis not included in Table VI.

4 HSG and laparoscopy/laparotomy was not performed in all cases detected by transvaginal US.

5 Author does not consider "mild to moderate fundal excavations" a uterine structural abnormality.

6 Not included in Table VI.

7

1
Table VI: Prevalence of congenital uterine anomalies in the general/fertile population from selected series

Class	Studies ¹ <i>n</i>	Cases <i>n</i>	Total <i>n</i> (%)	Hypoplastic <i>n</i> (%)	Unicornuate <i>n</i> (%)	Didelphys <i>n</i> (%)	Bicornuate <i>n</i> (%)	Septate <i>n</i> (%)	Arcuate <i>n</i> (%)	T-shaped <i>n</i> (%)
Ia	4	4521	305 (6.7) ²	-	1 (0.03)	1 (0.03)	10 (0.3)	68 (2.0)	170 (4.9)	-
Ib	1	323	20 (6.2)							
II ¹	6	4846	116 (2.4)	5 (0.1)	5 (0.1)	7 (0.1)	11 (0.3) ³	36 (0.9) ³	34 (0.7)	3 (0.1)
Total	11	9690	441 (4.6)	5 (0.1)	6 (0.1)	8 (0.1)	21 (0.3)	104 (1.3)	204 (2.4)	3 (0.03)

2 ¹ Summary of studies shown in Table V.

3 ² Jurkovic et al (1997) (*n* of anomalies = 55) do not provide a breakdown of the congenital uterine anomalies they diagnosed, however their data
 4 has been used to estimate the *Total* prevalence according to Class Ia studies.

5 ³ Asthon et al (1988) (*n* of bicornuate/septate uteri = 15) do not distinguish between bicornuate and septate uteri; therefore their data has not been
 6 used for the prevalence estimates of these two subtypes.

1 *Infertile population*

2 The role of congenital uterine anomalies in infertility remains unclear (Kupesic,
3 2001; Grimbizis *et al*, 2001). However, it has been suggested that uterine
4 anomalies may contribute to infertility , possibly by interfering with normal
5 implantation and placentation. (Taylor and Gomel, 2008). A review by Grimbizis
6 *et al* (2001) found that the overall prevalence was similar to the general
7 population, which would suggest that there is no causal relation. Another review
8 by Nahum (1998) found the prevalence in the infertile population to be 21 times
9 higher than in the general population. However, in both these reviews the
10 reliability of the diagnostic methods used by the reported studies was not
11 considered. A summary of the studies reviewed in this paper is shown in Table
12 VII. The pooled prevalence estimated using these studies is shown in Table VIII.

13 According to our evaluation of the literature, the prevalence of congenital
14 uterine anomalies in the infertile population based on class Ia and Ib studies is
15 approximately 7.3% (CI 95%, 6.7 – 7.9). This is comparable to that found for the
16 general/fertile population. However, class II studies show a pooled prevalence of
17 10.8%, which is surprisingly higher.

18 In terms of different anomalies, in both class I and class II studies the
19 septate uterus is the commonest observed followed by the arcuate and bicornuate
20 uteri. The ratios based on class Ia studies, are approximately 4:2:1. This is
21 different to what was observed in the general/fertile population where the arcuate
22 was more than twice as common as the septate uterus. Furthermore, there seems
23 to be an increase in the prevalence of septate uteri in the infertile population
24 compared to the general/fertile population, from 1.1% to 3.9%. This suggests a
25 link between the septate uterus and infertility. This result is consistent with the

1 findings of relatively small studies that have shown that women with a septate
2 uterus and otherwise unexplained infertility may benefit from metroplasty.
3 However, to date there has been no published trial to randomize and compare
4 women with treatment versus no treatment. For this reason controversy exists as
5 to whether infertile women should undergo metroplasty (Taylor and Gomel,
6 2008). On the other hand, as removal of the septum will potentially decrease the
7 risk of miscarriage and preterm birth if these women are to conceive, it could be
8 argued that metroplasty should be considered in these cases (Homer *et al*, 2001).

9 In addition to the septate uterus, the prevalence of the unicornuate and
10 hypoplastic uteri are also relatively higher in the infertile population compared to
11 both the general/fertile and RM population, indicating an association. On the
12 other hand, this does not seem to be the case for the arcuate uterus, which is of
13 lower prevalence compared to the general/fertile and RM group. Interestingly, if
14 pooled data from all studies (class I and II) is considered, the prevalence of
15 arcuate uteri is almost identical to that of the general/fertile population (2.1 vs
16 2.4%). This would suggest that the arcuate uterus does not have a causal role in
17 infertility. Ultimately, the results of this review highlight the necessity for further
18 assessment of the role of the septate uterus in infertility.

Table VII: Prevalence of congenital uterine anomalies in the infertile population (US=ultrasound; TVS=transvaginal ultrasound; TAS=transabdominal ultrasound; HSG=hysterosalpingography; SHG=sonohysterography; HSc=hysteroscopy; Lap=laparoscopy/Laparotomy; RM= recurrent miscarriage)

Class	Study	Country	Cases <i>n</i>	Infertility Description	Initial Investigation	Definitive Investigation	Total <i>n</i> (%)	Hypoplastic <i>n</i> (%)	Unicornuate <i>n</i> (%)	Didelphys <i>n</i> (%)	Bicornuate <i>n</i> (%)	Septate <i>n</i> (%)	Arcuate <i>n</i> (%)	T-shaped <i>n</i> (%)
Ia	Ugur <i>et al</i> , 1995 ¹	Turkey	3332	Majority of patients	-	PE/US/HSG/ HSc/Lap/ HSc or Lap	167 (5.0)	47 (1.4)	13 (0.4)	11 (0.3)	26 (0.3)	61 (1.8)	9 (0.3)	-
	Tulandi <i>et al</i> , 1980	Canada	2240	-	HSG	HSc or Lap	23 (1.0)	-	2 (0.1)	1 (0.05)	13 (0.6)	-	7 (0.3)	-
	Tur-Kaspa <i>et al</i> , 2006	Canada/ USA	600	-	-	TVS/SHG	120 (20)	1 (0.2)	1 (0.2)	-	-	28 (4.7)	90 (15.0)	-
	Hamilton <i>et al</i> , 1998 ²	UK	500	-	-	US/SHG	24 (4.8)	-	1 (0.2)	-	2 (0.4)	21 (4.2)	-	-
	Radoncic <i>et al</i> , 2000	Croatia	267	-	-	3D US/HSc	96 (36.0)	-	-	-	-	95 (35.6)	1 (0.4)	-
	Arbozi <i>et al</i> , 2003 ³	Iran	186	Infertile/RM	-	Hsc/Lap	58 (31.2)	-	7 (3.8)	-	7 (3.8)	35 (18.8)	9 (4.8)	-
	Soares <i>et al</i> , 2000	Brazil	65	-	-	SHG/HSG/ TVS/HSc	9 (13.8)	-	3 (4.6)	-	1 (1.5)	-	5 (7.7)	-
	Alatas <i>et al</i> , 1997	Turkey	62	-	-	TVS/HSG/ SHG/HSc	4 (6.5)	-	-	-	-	-	-	-
	Raga <i>et al</i> , 1996	Spain	42	-	-	HSG/Lap/ 3D US	12 (28.6)	-	1 (2.4)	1 (2.4)	5 (12.0)	5 (12.0)	-	-
Wu <i>et al</i> , 1997		38	-	-	2D US/ HSG/3D US/ HSc/Lap	25 (65.8)	-	4 (10.5)	2 (5.3)	3 (7.9)	11 (28.9)	5 (13.2)	-	
Ib	Siegler <i>et al</i> , 1976	USA	104	-	-	HSG/HSc	10 (9.6)	-	-	-	-	10 (9.6)	-	-
	Taylor <i>et al</i> , 1979	Canada	68	-	-	HSG/HSc	1 (1.3)	-	-	-	-	1 (1.3)	-	-
II	Raga <i>et al</i> , 1997	Spain	1024	>2 years	-	HSG/Lap	25 (2.4)	-	1 (0.1)	1 (0.1)	5 (0.5 ⁴)	6 (0.6)	12 (1.1)	-
	Braun <i>et al</i> , 2005	Spain	705	-	-	HSG	66 (9.4)	-	3 (0.4)	-	9 (1.3)	16 (2.3)	38 (5.4)	-
	Acien, 1997 ⁴	Spain	200	-	2D TVS	HSG/Lap	32 (16)	12 (6)	2 (1)	1 (0.5)	1 (0.5)	2 (1)	14 (7)	-
	Nickerson <i>et al</i> , 1977 ⁵	USA	190	Primary	-	HSG	93 (48.9)	-	3 (1.6)	-	3 (1.6)	87 (45.8)	-	-
	Sorensen <i>et al</i> , 1981	Denmark	134	-	-	HSG	32 (23.9)	-	2 (1.5)	-	7 (5.2)	23 (17.2)	-	-
	Vasiljevic <i>et al</i> , 1996	Serbia	102	-	-	HSG/Lap	6 (5.9)	-	-	-	-	-	-	-

¹The number of patients investigated by either of these investigations is not mentioned.²Septate/arcuate diagnosis has not been included in Table VIII.³3.8% of the cases were RM patients.⁴HSG and laparoscopy/laparotomy was not performed in all cases detected by transvaginal ultrasound.⁵ Author includes subdivision into subseptate (*n* = 31; 16.3%), mildly subseptate (*n* = 31; 16.3%), very mildly subseptate (*n* = 25; 13.2%).

1
Table VIII: Prevalence of congenital uterine anomalies in the infertile population from selected series

Class	Studies ¹ <i>n</i>	Cases <i>n</i>	Total <i>n</i> (%)	Hypoplastic <i>n</i> (%)	Unicornuate <i>n</i> (%)	Didelphys <i>n</i> (%)	Bicornuate <i>n</i> (%)	Septate <i>n</i> (%)	Arcuate <i>n</i> (%)	T-shaped <i>n</i> (%)
Ia	10	7332	538 (7.3) ²	48 (0.7)	32 (0.4)	15 (0.2)	57 (0.8)	235 (3.5) ³	126 (1.9) ³	-
Ib	2	172	11 (6.4)	-	-	-	-	11 (6.4)	-	-
II	6	2355	254 (10.8) ⁴	12 (0.1)	11 (0.5)	2 (0.1)	25 (1.1)	111 (5.2) ⁵	64 (3.0) ⁵	-
Total	18	9859	803 (8.1)	60 (0.6)	43 (0.4)	17 (0.2)	82 (0.8)	357 (3.9)	190 (2.1)	-

2 ¹ Summary of studies shown in Table VII.

3 ² Alatas et al (1997) (*n* of anomalies = 4) do not provide a breakdown of the congenital uterine anomalies they diagnosed, however their data has
 4 been used to estimate the *Total* prevalence according to Class Ia studies.

5 ³ Hamilton et al (1998) (*n* of septate/arcuate = 21) do not distinguish between septate and arcuate uteri; therefore their data has not been used for
 6 the prevalence estimates of these two subtypes.

7 ⁴ Vasiljevic et al (1996) (*n* of anomalies = 6) do not provide a breakdown of the congenital uterine anomalies they diagnosed, however their data
 8 has been used to estimate the *Total* prevalence according to Class II studies.

9 ⁵ Sorensen et al (1998) (*n* of septate/arcuate uteri = 23) do not distinguish between septate and arcuate uteri; therefore their data has not been used
 10 for the prevalence estimates of these two subtypes.

1 *Recurrent miscarriage population*

2 Although the association between congenital uterine anomalies and RM has been well
3 documented (Grimbizis *et al*, 2001; Homer *et al*, 2001; Kupesic *et al*, 2001; Taylor
4 and Gomel, 2008), the exact prevalence in this population has not been clearly
5 defined. A summary of the studies reviewed in this paper is shown in Table IX. The
6 pooled prevalence estimated using a selection of these studies is shown in Table X.

7 According to our evaluation of the literature, the prevalence of congenital
8 uterine anomalies in the RM population based on class Ia and Ib studies is
9 approximately 16.7% (CI 95%, 14.8 – 18.6). Studies with ≥ 3 consecutive
10 miscarriages were included in the analysis. However, the study by Salim *et al* (2003),
11 which provides approximately 34% of the cases of class I studies, examined patients
12 with unexplained recurrent pregnancy loss. By excluding all patients with concurrent
13 diagnoses their findings could be exaggerated. By not including the study of Salim *et*
14 *al* (2003) the pooled prevalence according to class I studies is reduced to
15 approximately 13.1%. Therefore it can be assumed that the true prevalence lies
16 approximately somewhere between 13 and 17%. Surprisingly, class II studies show a
17 pooled prevalence of 23.3%, suggesting an over-diagnosis, rather than an under-
18 diagnosis, which would be expected from investigations of a low sensitivity (under
19 60% for 2D US). This could be partly due to the investigators having a lower
20 threshold for diagnosing congenital uterine anomalies in patients suffering with RM.

21 Class I studies evaluating women with ≥ 3 non-consecutive miscarriages,
22 show a pooled prevalence of 15.8%; this is similar to women with ≥ 3 consecutive
23 miscarriages (16.7%). Corresponding class II studies show a prevalence of 23.3% for
24 women with ≥ 3 consecutive miscarriages, and only 3.3% for those with ≥ 3 non-
25 consecutive miscarriages; this decrease may be partly due to the different miscarriage

1 pattern (consecutive vs non-consecutive), but may also be a chance finding. Class I
2 studies of women with ≥ 2 consecutive miscarriages, show a pooled prevalence of
3 28.3%. Corresponding class II studies show a prevalence of 13%. Both findings
4 suggest that women presenting with only 2 miscarriages may also warrant
5 investigations for the presence of a congenital uterine anomaly. This has been
6 suggested by the report of Weiss *et al* (2005) who found no significant differences
7 between the prevalence of congenital uterine anomalies in women with ≥ 2 versus ≥ 3
8 miscarriages. Unfortunately, the heterogeneity of the reports does not allow for
9 further analysis to be conducted.

10 Regarding the different anomaly types, class Ia studies suggest that the arcuate
11 uterus is the commonest followed by the septate and bicornuate uterus with a ratio of
12 approximately 12:5:1. This does not vary greatly from the findings for the general
13 population; however it is different to what is observed in the infertile population. A
14 summary of the ratios and prevalence of different anomaly types within the three
15 population groups is shown in Tables XI and XII respectively.

16 The prevalence of the arcuate uterus in the RM population is 12.2%, more
17 than 3-fold the prevalence for the general/fertile population (3.8%). This suggests a
18 causal relation between this type of deformity and recurrent miscarriage, something
19 which has been suggested by authors in the past (Grimbizis *et al*, 2001; Woelfer *et al*,
20 2001). Interestingly, although the arcuate uterus could be considered a mild form of
21 partial septate uterus (Grimbizis *et al*, 2001), the study by Woelfer *et al* (2001)
22 suggests a different pattern of pregnancy loss in patients with arcuate versus septate
23 uteri. Notably, their data supports the suggestion that women with arcuate uteri tend
24 to miscarry more in the second trimester, whereas patients with septate uteri are more
25 likely to miscarry in the first trimester. This finding could suggest a different

1 mechanism of miscarriage for these two uterine anomaly types. Ultimately, the
2 impact of the arcuate uterus on the reproductive outcome should not be
3 underestimated.

4 Interestingly, in the current review, there are a number of class II studies that
5 failed to identify any arcuate uteri. This could reflect the lower sensitivities of the
6 investigations used (i.e. 2D US and HSG), which may have failed to identify the less
7 prominent arcuate deformity. Overall, more studies are required to further clarify the
8 prevalence of different congenital uterine anomalies within the RM population, and
9 delineate their causal relation to RM.

Table IX: Savvalov et al. Human Reproduction Update 2008 14(5):415-429
 prevalence of congenital reproductive anomalies in the recurrent miscarriage population (US=ultrasound; TVS=transvaginal ultrasound; TAS=transabdominal ultrasound; HSG=hysterosalpingography; SHG=sonohysterography; HSc=hysteroscopy; Lap=laparoscopy/Laparotomy; RM= recurrent miscarriage)

Class	Study	Country	Cases <i>n</i>	Miscarriage details	Initial Investigation	Definitive Investigation	Total <i>n</i> (%)	Hypoplastic <i>n</i> (%)	Unicornuate <i>n</i> (%)	Didelphys <i>n</i> (%)	Bicornuate <i>n</i> (%)	Septate <i>n</i> (%)	Arcuate <i>n</i> (%)	T-shaped <i>n</i> (%)
Ia	Salim <i>et al</i> , 2003	UK	509	≥ 3 consecutive unexplained 1 st trimester	2D TVS	3D US	121 (23.8)	-	2 (0.4)	-	6 (1.2)	27 (5.3)	86 (16.9)	-
	Li <i>et al</i> , 2002	UK	453	≥ 3 consecutive	2D US/ HSG	HSc/Lap	49 (10.8)	-	-	-	-	-	-	-
	Stephenson <i>et al</i> , 1996	Canada	197	≥ 3 consecutive	HSG or HSc	SHG or Lap	15 (7.6)	-	1 (0.5)	1 (0.5)	1 (0.5)	8 (4.1)	-	4 (2.0)
	Weiss <i>et al</i> , 2005 ¹	Israel	165 98	≥ 2 consecutive ² ≥ 3 consecutive	-	HSc/Lap HSc/Lap	32 (19.4) 17 (17.3)	-	1 (0.6)	-	3 (1.8)	13 (7.9)	13 (7.9)	-
Ib	Valli <i>et al</i> , 2001	Italy	344 141	≥ 2 consecutive ² ≥ 3 consecutive	-	HSc HSc	112 (32.6) 39 (27.7)	-	3 (0.9)	-	30 (8.7)	79 (23.0)	24 (17.0)	-
	Raziel <i>et al</i> , 1994 ²	Israel	106	≥ 3	-	HSG/HSc	23 (21.7)	-	-	-	-	23 (21.7)	-	-
	Guimaraes Filho <i>et al</i> , 2006	Brazil	60	≥ 3 consecutive	-	HSc	8 (13.3)	-	-	-	-	-	-	-
	Tulppala <i>et al</i> , 1993 ³	Finland	55	RM clinic	-	HSc	4 (7.3)	-	-	-	-	4 (7.3)	-	-
	Ventolini <i>et al</i> , 2004 ²	USA	23	≥ 3	-	US/HSc	3 (13.0)	-	-	-	-	3 (13.0)	-	Excluded
II	Makino <i>et al</i> , 1992 ²	Japan	1200	≥ 2	-	HSG	188 (15.7)	-	5 (0.4)	-	-	50 (4.1)	133 (11.1)	-
	Clifford <i>et al</i> , 1994 ²	UK	500	≥ 3	-	US	9 (1.8)	-	-	-	3 (0.6)	6 (1.2)	-	-
	Coulam <i>et al</i> , 1991 ²	USA	214	≥ 2	HSG	HSc	1 (0.5)	-	-	-	-	1 (0.5)	-	-
	Stray-Pedersen, 1984	Norway	195	≥ 3 consecutive	-	HSG	19 (9.7)	-	-	-	-	-	-	-
	Acien <i>et al</i> , 1998 ³	Spain	189	RM clinic	-	HSG	71 (37.6)	-	-	-	-	-	-	-
	Harger <i>et al</i> , 1983 ²	USA	155	≥ 2 consecutive	HSG	HSc	17 (11.0)	-	1 (0.6)	-	5 (3.2)	3 (1.9)	4 (2.9)	4 (2.9)
	Coulam, 1986 ²	USA	110	≥ 3	-	HSG	11 (9.1)	-	1 (0.9)	2 (1.8)	6 (5.5)	2 (1.8)	-	-
	Tho <i>et al</i> , 1979 ²	Georgia	100	≥ 2 or ≥ 1 abnormal conceptus	HSG	Gynae- cography	10 (10)	-	-	-	-	10 (10)	-	-
	Traina <i>et al</i> , 2004 ²	Brazil	80	≥ 2 consecutive	-	HSG/TVS/ HSc	11 (13.6)	-	-	-	-	-	-	-
Portuondo <i>et al</i> , 1986	Spain	40	≥ 3 consecutive	-	HSG	9 (22.5)	-	-	-	-	6 (15)	3 (7.5)	-	
Keltz <i>et al</i> , 1997 ²	USA	34	≥ 2 consecutive	-	SHG	5 (14.7)	-	-	-	1 (2.9)	2 (5.9)	-	2 (5.9)	

1 Contains also 2 undetermined bicornuate/septate uteri.
 2 Data not included in Table X as subjects do not fulfil the criteria for RM.
 3 Number or pattern of miscarriages not specified by author (assumed to be ≥ 3 consecutive as patients were attending a RM clinic).
 4

1

Table X: Prevalence of congenital uterine anomalies in the recurrent miscarriage population (≥ 3 consecutive miscarriages) from selected series

Class	Studies ¹ , <i>n</i>	Cases <i>n</i>	Total <i>n</i> (%)	Hypoplastic <i>n</i> (%)	Unicornuate <i>n</i> (%)	Didelphys <i>n</i> (%)	Bicornuate <i>n</i> (%)	Septate <i>n</i> (%)	Arcuate <i>n</i> (%)	T-shaped <i>n</i> (%)
Class Ia ¹	4	1257	202 (16.1) ²	-	3 (0.4)	1 (0.1)	7 (1.0)	35 (5.0)	86 (12.2)	4 (0.6)
Class Ib	3	256	51 (19.9) ³	-	-	-	-	19 (9.7)	24 (12.2)	-
Class II	3	424	99 (23.3) ⁴	-	-	-	-	6 (15.0)	3 (7.5)	-
Total	20	1937	352 (18.2)	-	3 (0.3)	1 (0.1)	7 (0.7)	60 (6.4)	113 (12.0)	4 (0.4)

2 ¹ Summary of studies shown in Table IX.

3 ² Weiss et al (2005) and Li et al (2001) (total *n* of anomalies = 66) do not provide a breakdown of the congenital uterine anomalies they
4 diagnosed, however their data has been used to estimate the *Total* prevalence according to Class Ia studies.

5 ³Guimaraes Filho et al, (2006) (*n* of anomalies = 8) do not provide a breakdown of the congenital uterine anomalies they diagnosed, however
6 their data has been used to estimate the *Total* prevalence according to Class Ib studies.

7 ⁴Acien et al (1998) and Stray-Pedersen (1984) (total *n* of anomalies = 90) do not provide a breakdown of the congenital uterine anomalies they
8 diagnosed, however their data has been used to estimate the *Total* prevalence according to Class II studies.

Table XI: Approximate ratios of uterine anomaly types in different populations¹

Population	Arcuate	Septate	Bicornuate
General/Fertile	17	7	1
Infertile	2	4	1
RM	12	5	1

1 ¹ Data based on class Ia studies

Table XII: Congenital uterine anomalies: percentage of subtypes in different population groups.¹

Population	Hypoplastic %	Unicornuate %	Didelphys %	Bicornuate %	Septate %	Arcuate %
General/fertile (<i>n</i> = 250)	-	0.4	0.4	4.0	27.2	68.0
Infertile (<i>n</i> = 510)	9.4	6.1	2.9	10.8	46.1	24.7
Recurrent Miscarriage (<i>n</i> = 132)	-	2.3	0.8	5.3	26.5	65.2

2 ¹Data based only on class Ia studies using an appropriate classification of the
3 congenital uterine anomaly types.

4

5 **Conclusion**

6 Based on the data derived from class Ia and Ib studies, the prevalence of
7 congenital uterine anomalies is approximately 6.7% (CI 95%, 6.0 – 7.4) in the
8 general/fertile population, 7.3% (CI 95%, 6.7 – 7.9) in the infertile population and
9 16.7% (CI 95%, 14.8 – 18.6) in the RM population. The prevalence in the infertile
10 population is similar to that of the general/fertile population. However, there
11 seems to be a higher prevalence of septate uteri in the infertile population,
12 suggesting an association. In addition, the high prevalence of arcuate uteri in the
13 RM population (12.2%) highlights the potentially important role of this deformity
14 in recurrent miscarriage, something which should not be underestimated. The
15 relation between most congenital uterine anomalies and RM has been well

1 documented in the literature; furthermore, it has been suggested that treatment of
2 certain anomalies may result in an improved pregnancy outcome (Homer *et al*,
3 2000; Grimbizis *et al*, 2001; Kupesic, 2001; Taylor and Gomel, 2008). Therefore,
4 any woman suffering from RM should be thoroughly investigated, to identify
5 whether a congenital uterine anomaly is present. A number of different
6 investigations can be used. 2D US and HSG have the lowest accuracy rates,
7 which would not warrant use for diagnosis. However, they can be used alone or in
8 combination as an effective screening tool. In contrast, SHG has been shown to be
9 highly accurate in diagnosing and classifying uterine anomalies; however, it is
10 more invasive and is not commonly practiced. Studies to date suggest that 3D US
11 is also very accurate and can be used as a diagnostic tool; limitations include a
12 possible underdiagnosis of unicornuate uteri and lack of availability in some
13 centres. The accuracy and practicality of MRI has not yet been determined,
14 however its role in screening or diagnosing congenital uterine anomalies may
15 become more important in the future. Combined hysteroscopy and laparoscopy
16 allows for a direct visualization of the internal and external contour of the uterus,
17 and is therefore considered by many to be the gold standard. The main advantage
18 is that it allows concurrent diagnosis and treatment, while the disadvantage is the
19 invasiveness of the procedures.

1 **References**

- 2 Acien P (1997) Incidence of Müllerian defects in fertile and infertile women.
3 *Human Reproduction*, **12**(7), 1372-6.
- 4 Acien P (1996) Uterine anomalies and recurrent miscarriage. *Infertility and*
5 *Reproductive Medicine Clinics of North America*, **7**(4), 689-720.
- 6 Acien P (1993) Reproductive performance of women with uterine malformations.
7 *Human Reproduction*, **8**(1), 122-6.
- 8 Acien P, Acien, M, Sanchez-Ferrer M (2004) Complex malformations of the
9 female genital tract. New types and revision of classification. *Human*
10 *Reproduction*, **19**(10), 2377-2384.
- 11 Alatas C, Aksoy E, Akarsu C, Yakin K, Aksoy S and Hayran M (1997)
12 Evaluation of intrauterine abnormalities in infertile patients by
13 sonohysterography. *Human Reproduction*, **12**(3), 487-90.
- 14 Alborzi S, Dehbashi S and Khodae R (2003) Sonohysterosalpingographic
15 screening for infertile patients. *International Journal of Gynaecology &*
16 *Obstetrics*, **82**(1), 57-62.
- 17 Alborzi S, Dehbashi S and Parsanezhad ME (2002) Differential diagnosis of
18 septate and bicornuate uterus by sonohysterography eliminates the need for
19 laparoscopy. *Fertility & Sterility*, **78**(1), 176-8.
- 20 Altman DG (1991) Practical statistics for medical research. Chapman & Hall,
21 London, UK.
- 22 Ashton D, Amin HK, Richart RM and Neuwirth RS (1988) The incidence of
23 asymptomatic uterine anomalies in women undergoing transcervical tubal
24 sterilization. *Obstetrics & Gynecology*, **72**(1), 28-30.
- 25 Barakat AJ (2002) Association of unilateral renal agenesis and genital anomalies.

- 1 *Case Rep Clin Pract Rev*, **3**(2), 57-60.
- 2 Braun P, Grau FV, Pons RM and Enguix DP (2005) Is hysterosalpingography
3 able to diagnose all uterine malformations correctly? A retrospective study.
4 *European Journal of Radiology*, **53**(2), 274-9.
- 5 Bettocchi S, Ceci O, Nappi L, Pontrelli G, Pinto L and Vicino M (2007) Office
6 hysteroscopic metroplasty: three "diagnostic criteria" to differentiate between
7 septate and bicornuate uteri. *Journal of Minimally Invasive Gynecology*, **14**(3),
8 324-8.
- 9 Brown SE, Coddington CC, Schnorr J, Toner JP, Gibbons W and Oehninger S
10 (2000) Evaluation of outpatient hysteroscopy, saline infusion
11 hysterosonography, and hysterosalpingography in infertile women: a
12 prospective, randomized study *Fertility & Sterility*, **74**(5), 1029-34.
- 13 Byrne J, Nussbaum-Blask A, Taylor WS, Rubin A, Hill M, O'Donnell R and
14 Shulman S (2000) Prevalence of Müllerian duct anomalies detected at
15 ultrasound. *American Journal of Medical Genetics*, **94**(1), 9-12.
- 16 Clifford K, Rai R, Watson H and Regan L (1994) An informative protocol for the
17 investigation of recurrent miscarriage: preliminary experience of 500
18 consecutive cases. *Human Reproduction*, **9**(7), 1328-32.
- 19 Cooper JM, Houck RM and Rigberg HS (1983) The incidence of intrauterine
20 abnormalities found at hysteroscopy in patients undergoing elective
21 hysteroscopic sterilization. *Journal of Reproductive Medicine*, **28**(10), 659-61.
- 22 Coulam CB (1991) Epidemiology of recurrent spontaneous abortion. *American*
23 *Journal of Reproductive Immunology*, **26**(1), 23-7.
- 24 Deffarges JV, Haddad B, Musset R and Paniel BJ (2001) Utero-vaginal
25 anastomosis in women with uterine cervix atresia: long-term follow-up and

- 1 reproductive performance. A study of 18 cases. *Human Reproduction*,
2 **16**, 1722–1725.
- 3 Devi Wold AS, Pham N and Arici A (2006) Anatomic factors in recurrent
4 pregnancy loss. *Seminars in Reproductive Medicine*, **24**(1), 25-32.
- 5 Dunn R, Hantes J (2004) Double cervix and vagina with a normal uterus and
6 blind cervical pouch: a rare mullerian anomaly. *Fertility & Sterility*, **82**, 458–9.
- 7 Fedele L, Bianchi S, Agnoli B, Tozzi L, Vignali M (1996) Urinary tract
8 anomalies associated with unicornuate uterus. *J Urol*, **155**, 847–848.
- 9 Fedele L, Dorta M, Brioschi D, Massari C and Candiani GB (1989) Magnetic
10 resonance evaluation of double uteri. *Obstetrics & Gynecology*, **74**, 844-847.
- 11 Golan A, Langer R, Bukovsky I and Caspi E (1989) Congenital anomalies of the
12 Müllerian system. *Fertility & Sterility*, **51**(5), 747-55.
- 13 Green LK and Harris RE (1976) Uterine anomalies. Frequency of diagnosis and
14 associated obstetric complications. *Obstetrics & Gynecology*, **47**(4), 427-9.
- 15 Grimbizis GF, Camus M, Tarlatzis BC, Bontis JN and Devroey P (2001) Clinical
16 implications of uterine malformations and hysteroscopic treatment results.
17 *Human Reproduction Update*, **7**(2), 161-74.
- 18 Guimaraes Filho HA, Mattar R, Pires CR, Araujo Junior E, Moron AF and
19 Nardoza LM (2006) Comparison of hysterosalpingography,
20 hysterosonography and hysteroscopy in evaluation of the uterine cavity in
21 patients with recurrent pregnancy losses. *Archives of Gynecology & Obstetrics*,
22 **274**(5), 284-8.
- 23 Guimaraes Filho HA, Mattar R, Pires CR, Araujo Junior E, Moron AF and
24 Nardoza LM (2006). Prevalence of uterine defects in habitual abortion

- 1 patients attended on at a university health service in Brazil. *Archives of*
2 *Gynecology & Obstetrics*, **274**(6), 345-8.
- 3 Hamilton JA, Larson AJ, Lower AM, Hasnain S and Grudzinskas JG (1998)
4 Routine use of saline hysterosonography in 500 consecutive, unselected,
5 infertile women. *Human Reproduction*, **13**(9), 2463-73.
- 6 Hammoud AO, Gibson M, Mathew Peterson C, Kerber RA, Mineau GP, Hatasaka
7 H (2008) Quantification of the familial contribution to Müllerian anomalies.
8 *Obstetrics & Gynecology*, **111**(2), 378-384.
- 9 Hannema SE, Hughes IA (2007) Regulation of Wolffian Duct Development.
10 *Horm Res*, **67**, 142–151.
- 11 Hatasaka HH (1994) Recurrent miscarriage: epidemiologic factors, definitions,
12 and incidence. *Clinical Obstetrics & Gynecology*, **37**(3), 625-34.
- 13 Harger JH, Archer DF, Marchese SG, Muracca-Clemens M and Garver KL
14 (1983) Etiology of recurrent pregnancy losses and outcome of subsequent
15 pregnancies. *Obstetrics & Gynecology*, **62**(5), 574-81.
- 16 Heinonen PK and Pystynen PP (1983) Primary infertility and uterine anomalies.
17 *Fertility & Sterility*, **40**(3), 311-6.
- 18 Jauniaux E, Farquharson RG, Christiansen OB and Exalto N (2006) Evidence-
19 based guidelines for the investigation of recurrent miscarriage. *Human*
20 *Reproduction*, **21**(9), 2216-2222.
- 21 Jurkovic D, Geipel A, Gruboeck K, Jauniaux E, Natucci M and Campbell S
22 (1997) Three-dimensional ultrasound for the assessment of uterine anatomy
23 and detection of congenital anomalies: a comparison with
24 hysterosalpingography and two-dimensional sonography. *Ultrasound in*
25 *Obstetrics and Gynecology*, **5** (4), 233.

- 1 Jurkovic D, Gruboeck K, Tailor A and Nicolaides KH (1997) Ultrasound
2 screening for congenital uterine anomalies. *British Journal of Obstetrics &*
3 *Gynaecology*, **104**(11), 1320-1.
- 4 Keltz MD, Olive DL, Kim AH and Arici A (1997) Sonohysterography for
5 screening in recurrent pregnancy loss. *Fertility & Sterility*, **67**(4), 670-4.
- 6 Kobayashi A, Behringer RR (2003) Developmental genetics of the female
7 reproductive tract in mammals. *Nat Rev Genet*, **12**, 969– 980.
- 8 Kupesic S (2001) Clinical implications of sonographic detection of uterine
9 anomalies for reproductive outcome. *Ultrasound in Obstetrics & Gynecology*,
10 **18**(4), 387-400.
- 11 Li S, Oayvum A, Coakley FV, Hedvig H (2000) Association of Renal Agenesis
12 and Mullerian Duct Anomalies. *Journal of Computer Assisted Tomography*,
13 **24**(6), 829-834.
- 14 Li TC, Iqbal T, Anstie B, Gillham J, Amer S, Wood K and Laird S (2002) An
15 analysis of the pattern of pregnancy loss in women with recurrent miscarriage.
16 *Fertility & Sterility*, **78**(5), 1100-6.
- 17 Letterie GS, Vauss N (1991) Müllerian tract abnormalities and associated
18 auditory defects. *J Reprod Med*, **36**, 765-8.
- 19 Letterie GS (1998) Structural abnormalities and reproductive failure: Effective
20 techniques of diagnosis and management. Blackwell Science, New York, USA.
- 21 Makino T, Umeuchi M, Nakada K, Nozawa S and Iizuka R (1992) Incidence of
22 congenital uterine anomalies in repeated reproductive wastage and prognosis
23 for pregnancy after metroplasty. *International Journal of Fertility*, **37**(3), 167-
24 70.

- 1 Makris N, Kalmantis K, Skartados N, Papadimitriou A, Mantzaris G and
2 Antsaklis A (2007) Three-dimensional hysterosonography versus hysteroscopy
3 for the detection of intracavitary uterine abnormalities. *International Journal of*
4 *Gynaecology & Obstetrics*, **97**(1), 6-9.
- 5 Makris N, Skartados N, Kalmantis K, Mantzaris G, Papadimitriou A and
6 Antsaklis A (2007) Evaluation of abnormal uterine bleeding by transvaginal 3-
7 D hysterosonography and diagnostic hysteroscopy. *European Journal of*
8 *Gynaecological Oncology*, **28**(1), 39-42.
- 9 Nahum GG (1998) Uterine anomalies. How common are they, and what is their
10 distribution among subtypes? *Journal of Reproductive Medicine*, **43**(10), 877-
11 87.
- 12 Nguyen L, Harford RI and Trott EA (1997) Evaluating Müllerian anomalies as a
13 cause of recurrent pregnancy loss. *Delaware Medical Journal*, **69**(4), 209-12.
- 14 Nickerson CW (1997) Infertility and uterine contour. *American Journal of*
15 *Obstetrics & Gynecology*, **129**(3), 268-73.
- 16 Nicolini U, Bellotti M, Bonazzi B, Zamberletti D and Candiani GB (1987) Can
17 ultrasound be used to screen uterine malformations? *Fertility & Sterility*, **47**(1),
18 89-93.
- 19 Oppelt P, von Have M, Paulsen M, Strissel P, Strick R, Brucker S, Wallwiener S,
20 Beckmann M (2007) Female genital malformations and their associated
21 abnormalities. *Fertility & Sterility*, **87**(2), 335-342.
- 22 Oppelt P, Renner SP, Brucker S, Strissel P, Strick R, Oppelt PG, *et al* (2005) The
23 VCUAM (vagina cervix uterus adnex-associated malformation) classification:
24 a new classification for genital malformations. *Fertility & Sterility*, **84**, 1493-7.

- 1 Patton PE (1994) Anatomic uterine defects. *Clinical Obstetrics & Gynecology*,
- 2 **37**(3), 705-21.
- 3 Pavone ME, King JA, Vlahos N (2006) Septate uterus with cervical duplication
- 4 and a longitudinal vaginal septum: a mullerian anomaly without a
- 5 classification. *Fertility & Sterility*, **85**, 494.e9–10.
- 6 Pellerito JS, McCarthy SM, Doyle MB, Glickman MG and DeCherney AH (1992)
- 7 Diagnosis of uterine anomalies: relative accuracy of MR imaging, endovaginal
- 8 ultrasound, and hysterosalpingography. *Radiology*, **183**, 795–800.
- 9 Portuondo JA, Camara MM, Echanojauregui AD and Calonge J (1986) Müllerian
- 10 abnormalities in fertile women and recurrent aborters. *Journal of Reproductive*
- 11 *Medicine*, **31**(7), 616-9.
- 12 Propst AM and Hill JA (2000) Anatomic factors associated with recurrent
- 13 pregnancy loss. *Seminars in Reproductive Medicine*, **18**(4), 341-50.
- 14 Rabinson J, Orvieto R, Shapira A, Brownstein Z, Meltzer S, Tur-Kaspa I (2006)
- 15 Müllerian anomalies, hearing loss and Connexin 26 mutations. *Fertility &*
- 16 *Sterility*, **85**, 1824-25.
- 17 Radonci E and Funduk-Kurjak B (2000) Three-dimensional ultrasound for routine
- 18 check-up in in vitro fertilization patients. *Croatian Medical Journal*, **41**(3),
- 19 262.
- 20 Raga F, Bauset C, Remohi J, Bonilla-Musoles F, Simon C and Pellicer A (1997)
- 21 Reproductive impact of congenital Müllerian anomalies. *Human Reproduction*,
- 22 **12**(10), 2277-81.
- 23 Raga F, Bonilla-Musoles F, Blanes J and Osborne NG (1996) Congenital
- 24 Müllerian anomalies: diagnostic accuracy of three-dimensional ultrasound.
- 25 *Fertility & Sterility*, **65**(3), 523-8.

- 1 Rai R and Regan L (2006) Recurrent miscarriage. *Lancet*, **368**(9535), 601-11.
- 2 Raziel A, Arieli S, Bukovsky I, Caspi E and Golan A (1994) Investigation of the
3 uterine cavity in recurrent aborters. *Fertility & Sterility*, **62**(5), 1080-2.
- 4 Reuter KL, Daly DC and Cohen SM (1989) Septate versus bicornuate uteri: errors
5 in imaging diagnosis. *Radiology*, **172**, 749 –52.
- 6 Sadik S, Taskin O, Sehirali S, Mendilcioglu I, O' noglu AS, Kursun S and
7 Wheeler JM (2002) Complex Mu'llerian malformation: report of a case with a
8 hypoplastic non-cavitated uterus and two rudimentary horns. *Hum Reprod*,
9 **17**, 1343–1344.
- 10 Salim R and Jurkovic D (2004) Assessing congenital uterine anomalies: the role
11 of three-dimensional ultrasonography. *Best Practice & Research in Clinical*
12 *Obstetrics & Gynaecology*, **18**(1), 29-36.
- 13 Salim R, Regan L, Woelfer B, Backos M and Jurkovic D (2003) A comparative
14 study of the morphology of congenital uterine anomalies in women with and
15 without a history of recurrent first trimester miscarriage. *Human Reproduction*,
16 **18**(1), 162-6.
- 17 Salim R, Woelfer B, Backos M, Regan L and Jurkovic D (2003) Reproducibility
18 of three-dimensional ultrasound diagnosis of congenital uterine anomalies.
19 *Ultrasound in Obstetrics & Gynecology*, **21**(6), 578-82.
- 20 Sanders B (2006) Uterine factors and infertility. *Journal of Reproductive*
21 *Medicine*, **51**(3), 169-76.
- 22 Simon C, Martinez L, Pardo F, Tortajada M and Pellicer A (1991) Mu'llerian
23 defects in women with normal reproductive outcome. *Fertility & Sterility*,
24 **56**(6), 1192-3.

- 1 Simpson WL Jr, Beitia LG and Mester J (2006) Hysterosalpingography: a
2 reemerging study. *Radiographics*, **26**(2), 419-31.
- 3 Soares SR, Barbosa dos Reis MM and Camargos AF (2000) Diagnostic accuracy
4 of sonohysterography, transvaginal sonography, and hysterosalpingography in
5 patients with uterine cavity diseases. *Fertility & Sterility*, **73**(2), 406-11.
- 6 Sorensen SS (1981) Minor Müllerian anomalies and oligomenorrhea in infertile
7 women. A new syndrome. *American Journal of Obstetrics & Gynecology*,
8 **140**(6), 636-44.
- 9 Stampe Sorensen S (1988) Estimated prevalence of Müllerian anomalies. *Acta*
10 *Obstetrica et Gynecologica Scandinavica*, **67**(5), 441-5.
- 11 Stephenson MD (1996) Frequency of factors associated with habitual abortion in
12 197 couples. *Fertility & Sterility*, **66**(1), 24-9.
- 13 Stray-Pedersen B and Stray-Pedersen S (1984) Etiologic factors and subsequent
14 reproductive performance in 195 couples with a prior history of habitual
15 abortion. *American Journal of Obstetrics & Gynecology*, **148**(2), 140-6.
- 16 Taylor PJ and Cumming DC (1979) Hysteroscopy in 100 patients. *Fertility &*
17 *Sterility*, **31**(3), 301-4.
- 18 The American Fertility Society (1988) The American Fertility Society
19 classifications of adnexal adhesions, distal tubal occlusion, tubal occlusion
20 secondary to tubal ligation, tubal pregnancies, müllerian anomalies and
21 intrauterine adhesions. *Fertility & Sterility*, **49**, 944 –55.
- 22 Tho PT, Byrd JR and McDonough PG (1979) Etiologies and subsequent
23 reproductive performance of 100 couples with recurrent abortion. *Fertility &*
24 *Sterility*, **32**(4), 389-95.

- 1 Traina E, Mattar R, Moron AF, Neto LCA and Matheus EDE (2004) Diagnostic
2 Accuracy of Hysterosalpingography and Transvaginal Sonography to Evaluate
3 Uterine Cavity Diseases in Patients with Recurrent Miscarriage. *RBGO*, **26**(7),
4 527 -533.
- 5 Troiano RN and McCarthy SM (2004) Müllerian duct anomalies: imaging and
6 clinical issues. *Radiology*, **233**(1), 19-34.
- 7 Tulandi T, Arronet GH and McInnes RA (1980) Arcuate and bicornuate uterine
8 anomalies and infertility. *Fertility & Sterility*, **34**(4), 362-4.
- 9 Tulppala M, Palosuo T, Ramsay T, Miettinen A, Salonen R and Ylikorkala O
10 (1993) A prospective study of 63 couples with a history of recurrent
11 spontaneous abortion: contributing factors and outcome of subsequent
12 pregnancies. *Human Reproduction*, **8**(5), 764-70.
- 13 Tur-Kaspa I, Gal M, Hartman M, Hartman J and Hartman A (2006) A prospective
14 evaluation of uterine abnormalities by saline infusion sonohysterography in
15 1,009 women with infertility or abnormal uterine bleeding. *Fertility & Sterility*,
16 **86**(6), 1731-5.
- 17 Ugur M, Karakaya S, Zorlu G, Arslan S, Gulerman C, Kukner S and Gokmen O
18 (1995) Polycystic ovaries in association with Müllerian anomalies. *European
19 Journal of Obstetrics, Gynecology, & Reproductive Biology*, **62**(1), 57-9.
- 20 Umbricht W (1969). Infertility and uterine abnormalities. *Gynaecologia*, **168**(6),
21 449-52.
- 22 Valenzano MM, Mistrangelo E, Lijoi D, Fortunato T, Lantieri PB, Risoo D,
23 Constantini S and Ragni N (2006) Transvaginal sonohysterographic evaluation
24 of uterine malformations. *Eur Jou Obs Gyne Rep Biol.*, **124**(2), 246-249.

- 1 Valli E, Zupi E, Marconi D, Vaquero E, Giovannini P, Lazzarin N and Romanini
2 C (2001) Hysteroscopic findings in 344 women with recurrent spontaneous
3 abortion. *Journal of the American Association of Gynecologic Laparoscopists*,
4 **8**(3), 398-401
- 5 Vasiljevi M, Ganovi R, Jovanovi R and Markovi A (1996) Diagnostic value of
6 hysterosalpingography and laparoscopy in infertile women. *Srpski Arhiv Za*
7 *Celokupno Lekarstvo*, **124**(5-6), 135-8
- 8 Ventolini G, Zhang M and Gruber J (2004) Hysteroscopy in the evaluation of
9 patients with recurrent pregnancy loss: a cohort study in a primary care
10 population. *Surgical Endoscopy*, **18**(12), 1782-4.
- 11 Wai CY, Zekam N, Sanz LE (2001) Septate uterus with double cervix and
12 longitudinal vaginal septum. A case report. *J Reprod Med*, **46**, 613-7.
- 13 Weiss A, Shalev E and Romano S (2005) Hysteroscopy may be justified after two
14 miscarriages. *Human Reproduction*, **20** (9), 2628-2631.
- 15 Woelfer B, Salim R, Banerjee S, Elson J, Regan L and Jurkovic D (2001)
16 Reproductive outcomes in women with congenital uterine anomalies detected
17 by three-dimensional ultrasound screening. *Obstetrics & Gynecology*, **98**(6),
18 1099-103.
- 19 Wu MH, Hsu CC and Huang KE (1997) Detection of congenital Müllerian duct
20 anomalies using three-dimensional ultrasound. *Journal Article Journal of*
21 *Clinical Ultrasound*, **25**(9), 487-92.