



UNIVERSITY OF LEEDS

This is a repository copy of *Comparison of focal boost high dose rate prostate brachytherapy optimisation methods*.

White Rose Research Online URL for this paper:
<http://eprints.whiterose.ac.uk/90517/>

Version: Accepted Version

Article:

Mason, J, Bownes, P, Carey, B et al. (1 more author) (2015) Comparison of focal boost high dose rate prostate brachytherapy optimisation methods. *Radiotherapy and Oncology*, 117 (3). pp. 521-524. ISSN 0167-8140

<https://doi.org/10.1016/j.radonc.2015.09.021>

© 2015, Elsevier. Licensed under the Creative Commons Attribution-NonCommercial-NoDerivatives 4.0 International
<http://creativecommons.org/licenses/by-nc-nd/4.0/>

Reuse

Unless indicated otherwise, fulltext items are protected by copyright with all rights reserved. The copyright exception in section 29 of the Copyright, Designs and Patents Act 1988 allows the making of a single copy solely for the purpose of non-commercial research or private study within the limits of fair dealing. The publisher or other rights-holder may allow further reproduction and re-use of this version - refer to the White Rose Research Online record for this item. Where records identify the publisher as the copyright holder, users can verify any specific terms of use on the publisher's website.

Takedown

If you consider content in White Rose Research Online to be in breach of UK law, please notify us by emailing eprints@whiterose.ac.uk including the URL of the record and the reason for the withdrawal request.



eprints@whiterose.ac.uk
<https://eprints.whiterose.ac.uk/>

Comparison of focal boost high dose rate prostate brachytherapy optimisation methods

Josh Mason^a, Peter Bownes^a, Brendan Carey^a, Ann Henry^a

a - Leeds Cancer Centre, Leeds, UK

Corresponding author:

Josh Mason

Department of Medical Physics

St James's University Hospital

Leeds LS9 7TF

United Kingdom

44 113 20 67905

joshua.mason@nhs.net

Running title:

HDR prostate focal boost optimisation

Keywords:

Multi-parametric MRI; prostate brachytherapy; focal boost, sector optimisation

This manuscript is nine pages including title page, summary and references.

There is also one figure and one table.

Summary

For HDR prostate brachytherapy treatments of 15Gy to the whole gland plus focal boost, optimisation to either tumour plus margin (F-PTV) or involved sectors was compared. For 15 patients median F-PTV D90 and V150 were 21.0Gy and 77.2% for F-PTV optimisation and 19.8Gy and 75.6% for sector optimisation.

Introduction

In radiotherapy for prostate cancer, it is common practice to prescribe one dose level to the whole prostate, as prostate cancer is known to be a multi-focal disease. Tumour control probability may be improved with a focal boost treatment where the whole gland is treated to the standard dose prescription and a focal boost dose is given to the dominant intra-prostatic lesion (DIL) [1,2] or other CTV sub-volume as described in GEC-ESTRO recommendations [3]. Focal boost treatments in high dose rate (HDR) prostate brachytherapy [4-7] typically use multi-parametric-MRI (mp-MRI) for tumour delineation; this is then fused to images acquired after needle insertion for treatment planning. Targeting of the focal boost dose is therefore impacted by uncertainties in tumour delineation and image fusion. Two approaches to mitigating these uncertainties are (i) applying a margin to the delineated tumour or (ii) dividing the prostate into sectors and boosting the sectors involved in the tumour. In this study dose optimisation is compared for the two approaches.

Many patients have several months of hormone therapy before HDR prostate brachytherapy and this can reduce prostate size and tumour conspicuity. Ideally treatment planning MRI scans are acquired after hormone therapy however pre-hormone therapy scans may be used if MRI capacity is limited. In the latter case due to prostate volume changes boosting based on involved prostate sectors may be the preferred approach to reducing image fusion uncertainties. In this study pre- and post-hormone therapy MRI scans are compared to determine whether or not the same prostate sectors are identified as being involved before and after hormone therapy.

Method

16 patients included in an mp-MRI guided focal boost prostate HDR brachytherapy pilot study [6] were retrospectively analysed for this investigation. The patients were aged 57 - 77 years, with biopsy proven prostate cancer, stages T1c - T3b, PSA at diagnosis 5 - 30 ng/ml, combined

Gleason 7 - 9. All patients received 2 - 5 months (mean 3 months) hormone therapy before treatment with a single fraction of 15Gy to the whole prostate planned using intra-operative trans-rectal ultrasound (TRUS), including focal boost to the visible tumour (detailed below), followed by 37.5Gy in 15 fractions of external beam to the prostate and seminal vesicles [8].

Pre-hormone therapy staging mp-MRI scans were performed 3 - 6 months (mean 4 months) before brachytherapy and pre-treatment mp-MRI scans in the week before brachytherapy. The mp-MRI sequences are detailed in the supplementary material and included T2-weighted (T2W) MRI, diffusion weighted MRI (DWI) and dynamic-contrast enhanced MRI (DCE-MRI) (DCE-MRI was included in the pre-treatment scans but not the staging scans). Focal gross tumour volume (F-GTV) targets for focal boost were delineated on the MRI data by a consultant radiologist. This was done at the time of brachytherapy treatment for the pre-treatment MRI scans, with the delineated F-GTV fused to TRUS to perform focal boost treatments. F-GTVs were based on the combination of all suspicious areas on the mp-MRI sequences with multiple separate F-GTVs per patient if appropriate. For the focal boost treatments a 4.5mm margin in all directions (constrained to avoid the urethra and remain inside the prostate capsule) was applied to the F-GTV to generate an F-PTV, on the TRUS images, to allow for tumour delineation and image registration uncertainties [6]. Staging scans were delineated more than one year after the last patient treatment for this retrospective planning study. For consistency of MRI scan parameters, only staging scans performed at the same centre as pre-treatment scans were analysed, which restricted this part of the study to 10 patients. For both sets of MRI data, the prostate volume was determined to assess the effects of hormone therapy. 12 prostate sectors were defined by first dividing into three base, mid-gland and apex segments, and then dividing each of these into four sectors: right anterior, left anterior, right posterior and left posterior. The sectors intersected by the F-GTV/F-PTVs were manually determined for each scan.

Treatment plans were generated using DVH-based inverse optimisation in Oncentra Prostate™ v4.0 [9], with minor manual adjustments to dwell times applied if necessary to meet plan objectives and constraints: prostate $V_{100} > 95\%$, PTV $V_{100} > 95\%$, urethra $D_{10} < 17.5$ Gy and rectum $D_{2\text{cm}^3} < 11.8$ Gy, $V_{\text{rect},100} = 0$ (PTV = prostate + 3mm, 0mm posteriorly, 100% dose = 15Gy). 2mm spaced dwell positions were activated throughout the PTV. Three optimisation strategies were compared for each patient.

- Standard plans with optimisation objectives set to give 100% dose to the whole prostate.
- F-PTV boost plans with optimisation objectives set to give 150% dose to as much of the F-PTV as possible while giving 100% dose to the remainder of the prostate and maintaining the plan objectives and constraints listed above.
- Sector boost plans with optimisation objectives set to give 150% dose to as much as possible of the prostate sectors intersected by the F-PTV, while giving 100% dose to the other sectors and maintaining the plan objectives and constraints listed above.

All treatment plans were based on the pre-treatment mp-MRI data fused to planning TRUS. Plans used the same needle positions except that up to two additional needles were inserted to target the F-GTV if required for focal boost plans. Note that the involved sectors boosted in sector boost plans were determined from the TRUS F-PTVs to allow direct comparison of optimisation to the F-PTV boost plans. If implementing sector boost in clinical practice it would not be necessary to generate F-PTVs so that the tumour delineation and image fusion steps would not be required.

Results

One patient had no visible tumour in the pre-treatment MRI scan so was excluded from the optimisation study. Of the remaining fifteen patients, five had bi-lateral disease and ten had uni-lateral disease. Table 1 summarises the DVH values achieved in the optimisation study. The per-patient median (and range) of the boosted volume was 5.8 cm^3 ($1.6 \text{ cm}^3 - 13.4 \text{ cm}^3$) in F-

PTV-based and 9.8 cm^3 (2.2 cm^3 - 14.2 cm^3) in sector-based focal boost plans. Median prostate conformal index [10] values were 0.62, 0.62 and 0.61 in standard, F-PTV boost and sector boost plans respectively. Median PTV conformal index [10] values were 0.87, 0.85 and 0.84 in standard, F-PTV boost and sector boost plans respectively. The number of involved sectors per patient were one (one patient), two (five patients), three (three patients), four (four patients), five (one patient) and six (one patient). In almost all cases the involved sectors were adjacent. Across all patients 47 sectors were boosted, with 37 posterior and 10 anterior, and 6, 23 and 18 in apex, mid-gland and base segments respectively. Suppl Figure 1 (in supplementary material) shows an isodose comparison for one patient in the study. Higher doses and better coverage was achieved for posterior sectors compared to anterior sectors due to the position of the urethra. The median D90 and V150 were 18.4 Gy and 53.3% for anterior sectors and 21.0 Gy and 80.6% for posterior sectors.

For the 10 patients for whom staging and pre-treatment scan tumour delineations were compared, the median prostate volume was 30.4 cm^3 in the staging scan and 21.8 cm^3 in the pre-treatment scan, corresponding to a median reduction in volume of 28% (range 4% - 54%). Tumour delineation examples are shown in Figure 1. For five patients the involved sectors were identical in staging and pre-treatment scans. For four patients the involved sectors overlapped but did not exactly match - in three cases this was due to delineation variation as the tumour was less conspicuous in the pre-treatment scan and in one case this was due to changes in prostate morphology along with a large reduction in prostate volume (over 50%). For one patient there was no visible tumour on the pre-treatment MRI but tumour was delineated on the pre-hormone therapy staging MRI.

Discussion

This study has compared two different strategies for accounting for uncertainties in tumour delineation and image fusion in focal boost optimisation: applying a margin to the F-GTV and boosting the resulting F-

PTV, and giving a focal boost to the involved prostate sectors. Optimising to the involved sectors rather than F-PTVs was possible without compromising prostate and PTV coverage, and without exceeding OAR tolerances. Sector boost plans were similar to F-PTV boost plans, although with slightly lower boost dose to the F-PTV itself. There are no published studies of sector based focal boost planning in HDR prostate brachytherapy. A systematic review by Bauman et al. [11] of treatments boosting an imaging defined F-GTV found that brachytherapy studies achieved 130-155% boost doses. In this study the median F-GTV D90 in F-PTV boosted plans was 162% but in the sector boosted plans the F-GTV D90, at 149%, was still comparable to those studies, suggesting that the sector boost approach is an acceptable compromise even though it is less tightly targeted than the F-PTV boost approach. Because the involved sectors represent a higher proportion of the prostate volume than F-PTVs, the overall volume of the prostate that receives a boost dose is higher in sector boost plans with no detrimental impact on OAR dose. Sector boost doses were higher for posterior sectors than for anterior sectors – generally the anterior sectors are closer to the urethra and smaller than the posterior sectors. Similar results are also seen for F-PTVs, with lower boost doses achieved for F-PTVs located closer to the urethra. The study has used a standardized approach to selecting sectors for boosting but in clinical practice a judgment would need to be made on an individual patient basis using the size and location of the tumour, the amount of shrinkage due to hormone therapy, and the uncertainty in mapping sector positions from MRI to TRUS, to determine whether sectors adjacent to the involved sectors should be included in the boosted volume.

If access to MRI is limited staging MRI scans may be used for focal boost treatment planning but this increases the difficulty of image fusion if patients have received hormone therapy between the staging MRI scan and treatment, due to changes in prostate morphology and volume. In this study all 10 patients for whom staging scans were available had received several months hormone therapy at the time of the pre-treatment scan and this

resulted in reductions in prostate volume as well as changes in the relative sizes of central gland and peripheral zone [12]. Differences in tumour delineation occur even when the same images are delineated on separate occasions and hormone therapy will reduce the contrast between normal and cancerous prostate tissue. It is therefore not surprising that there were differences in the sectors selected as involved in the tumour between staging and pre-treatment scans. Similar results were reported in a study by Groenendaal et al [13] comparing tumour delineation before and after hormone therapy, who found that a longer duration of hormone therapy was associated with reduced tumour conspicuity but that tumours were still identified in 18 out of 21 cases after >3months hormone therapy. These differences between pre-treatment and staging scans underline the importance of using mp-MRI to improve confidence in tumour delineation. A limitation of this study is that DCE-MRI was not routinely used on staging scans at the time these patients were scanned which may contribute to the differences observed compared to pre-treatment scans.

Sector boosting does not adversely affect plan optimisation results compared to F-PTV boosting, and provides an alternative approach to delineating and fusing tumours that may be preferable if staging scans are used for focal boost treatment planning.

REFERENCES

- [1] Karavitakis M, Ahmed HU, Abel PD, Hazell S Winkler MH. Tumor focality in prostate cancer: implications for focal therapy. *Nat Rev Clin Oncol* 2011;8:48-55.
- [2] Dearnaley DP, Sydes MR, Graham JD, et al. Escalated-dose versus standard-dose conformal radiotherapy in prostate cancer: first results from the MRC RT01 randomised controlled trial. *Lancet Oncol* 2007;8:475-487.
- [3] Hoskin PJ, Colombo A, Henry A, et al. GEC/ESTRO recommendations on high dose rate afterloading brachytherapy for localised prostate cancer: An update. *Radiother Oncol* 2013;107:325-332
- [4] Dankulchai P, Alonzi R, Lowe GJ, Burnley J, Padhani AR Hoskin PJ. Optimal source distribution for focal boosts using high dose rate (HDR) brachytherapy alone in prostate cancer. *Radiother Oncol* 2014;113:121-125.
- [5] Kim Y, Hsu I, Chow J, et al. Class solution in inverse planned HDR prostate brachytherapy for dose escalation of DIL defined by combined MRI/MRSI. *Radiother Oncol* 2008;88:148-155.
- [6] Mason J, Al-Qaisieh B, Bownes P, et al. Multi-parametric MRI-guided focal tumor boost using HDR prostate brachytherapy: A feasibility study. *Brachytherapy* 2014;13:137-145.
- [7] Pouliot J, Kim Y, Lessard E Hsu I. Inverse planning for HDR prostate brachytherapy used to boost dominant intraprostatic lesions defined by magnetic resonance spectroscopy imaging. *Int J Radiat Oncol Biol Phys* 2004;59:1196-1207.
- [8] Morton G, Loblaw A, Cheung P, et al. Is single fraction 15Gy the preferred high dose-rate brachytherapy boost dose for prostate cancer? *Radiother Oncol* 2011;100:463-467.
- [9] Oncentra Prostate Reference Manual 190.037ENG-05: Nucletron.
- [10] Baltas D, Kolotas C, Geramani K, et al. A conformal index (COIN) to evaluate implant quality and dose specification in brachytherapy. *Int J Radiat Oncol Biol Phys* 1998;40:515-524.
- [11] Bauman G, Haider M, Van der Heide UA Ménard C. Boosting imaging defined dominant prostatic tumors: A systematic review. *Radiother Oncol* 2013;107:274-281.
- [12] Padhani AR, MacVicar AD, Gapinski CJ, et al. Effects of Androgen Deprivation on Prostatic Morphology and Vascular Permeability Evaluated with MR Imaging. *Radiology* 2001;218:365
- [13] Groenendaal G, van Vulpen M, Pereboom SR, et al. The effect of hormonal treatment on conspicuity of prostate cancer: Implications for focal boosting radiotherapy. *Radiother Oncol* 2012;103:233–238.

Table 1 Median DVH values for the 15 patients in the optimisation study. For F-GTV, F-PTV and sectors, the values shown are the median (range) of the combined values (for both F-GTVs/F-PTVs or all sectors) for each patient

	Plan	D90 (Gy)	V100 (%)	V150 (%)	V200 (%)
Prostate*	STD	17.2 (16.6 - 17.5)	99.9 (99.3 - 100)	33.3 (28.1 – 43.2)	10.1 (5.5 – 13.5)
	FBOOST	17.3 (16.6 - 17.8)	99.9 (99.0 - 99.9)	42.1 (32.1 – 52.5)	12.1 (8.7 – 20.5)
	SBOOST	17.3 (16.6 - 17.7)	99.8 (99.2 - 100)	43.4 (32.5 – 57.2)	12.3 (8.6 – 17.5)
PTV	STD	16.2 (15.5 - 16.6)	92.8 (87.3 – 97.2)	28.8 (26.2 – 36.7)	8.9 (5.4 – 11.5)
	FBOOST	16.3 (15.3 – 16.8)	91.6 (87.4 - 97.1)	35.0 (28.0 – 44.5)	10.1 (7.6 – 16.4)
	SBOOST	16.1 (15.3 – 16.8)	91.6 (87.4 - 97.1)	35.9 (28.5 – 45.3)	10.9 (8.0 – 13.7)
F-GTV	STD	18.3 (16.1 – 21.8)	100 (99.6 - 100)	35.8 (9.1 – 85.1)	6.1 (0.6 – 32.2)
	FBOOST	24.3 (20.5 – 30.4)	100 (-)	95.4 (73.1 – 100)	46.9 (14.5 – 91.4)
	SBOOST	22.3 (19.9 – 25.8)	100 (-)	88.7 (66.3 – 100)	29.9 (12.3 – 59.9)
F-PTV	STD	17.5 (15.8 - 19.3)	100 (97.5 - 100)	33.7 (16.0 – 56.5)	8.9 (2.5 – 16.7)
	FBOOST	21.0 (18.8 – 24.1)	100 (-)	77.2 (64.7 – 96.9)	30.2 (12.3 – 54.1)
	SBOOST	19.8 (18.9 – 24.2)	100 (-)	75.6 (49.7 – 96.7)	23.4 (10.1 – 48.1)
Involved sectors	STD	17.7 (16.8 - 18.3)	100 (99.0 - 100)	37.8 (14.4 – 49.4)	9.8 (3.3 – 18.6)
	FBOOST	19.0 (18.0 – 21.5)	100 (99.6 - 100)	62.2 (53.1 – 82.7)	20.9 (14.4 – 31.7)
	SBOOST	20.3 (18.7 – 22.8)	100 (-)	74.7 (56.9 – 91.1)	27.5 (16.1 – 38.7)
		D10 (Gy)	D2cm³ (Gy)	V100 (cm³)	
Urethra	STD	17.1 (17.1 – 17.2)	-	-	
	FBOOST	17.2 (17.1 – 17.5)	-	-	
	SBOOST	17.2 (17.1 – 17.5)	-	-	
Rectum	STD	-	8.4 (6.5 – 9.7)	0 (-)	
	FBOOST	-	8.9 (6.6 – 10.4)	0 (-)	
	SBOOST	-	8.9 (6.8 – 10.6)	0 (-)	

STD – standard plan delivering 15Gy to the whole prostate

FBOOST –plan delivering 15Gy to the whole prostate and escalating dose to the F-PTV(s)

SBOOST –plan delivering 15Gy to the whole prostate and escalating dose to the involved sector(s)

* Prostate is the whole prostate including F-GTV and F-PTV/sectors.

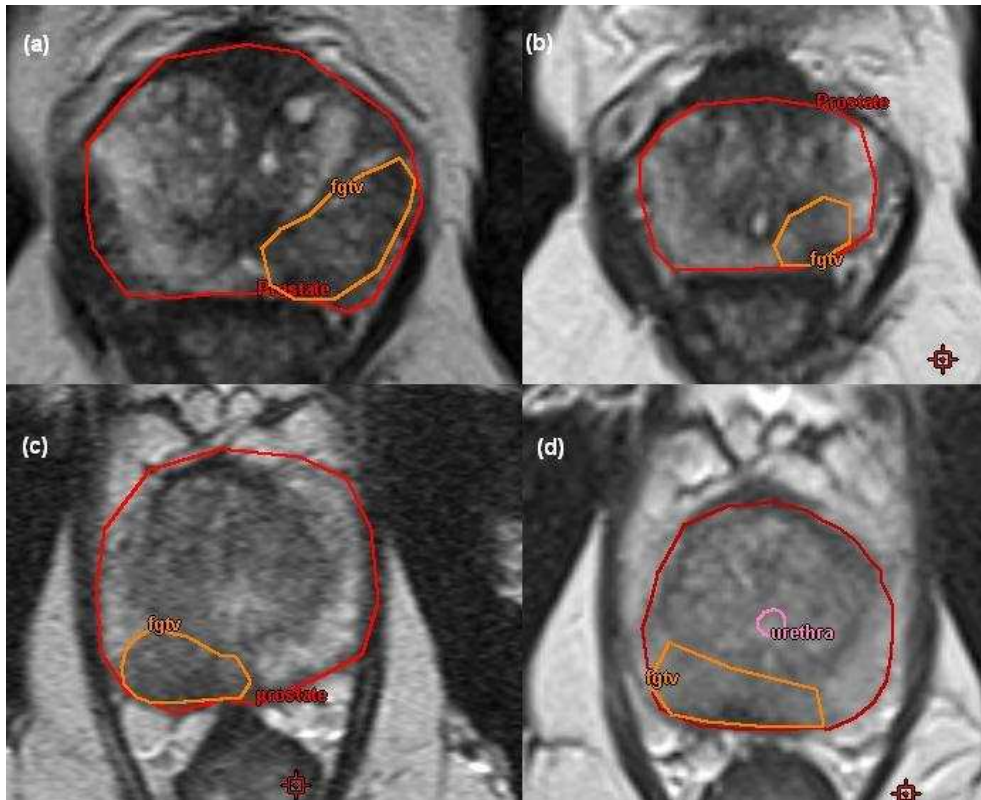
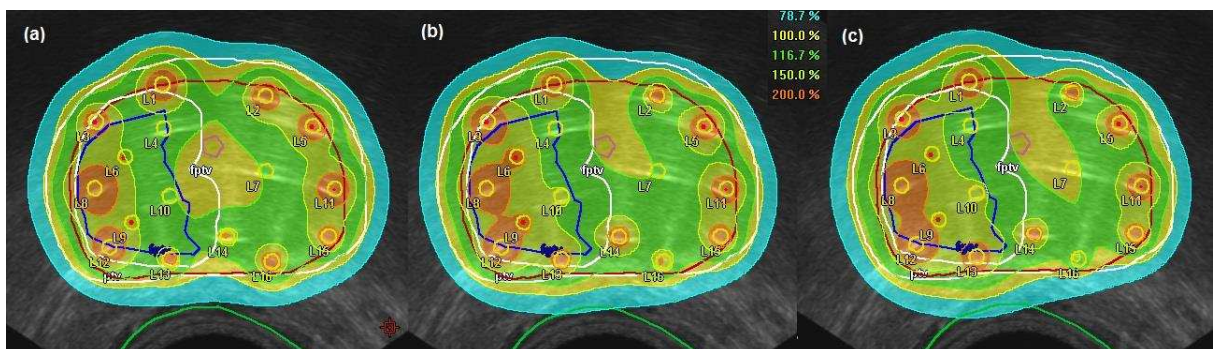


Figure 1: Staging and pre-treatment MRI . (a) and (b) are from staging and pre-treatment MRI s respectively for the same patient illustrating prostate and tumour shrinkage. (c) and (d) are from staging and pre-treatment MRIs respectively for a different patient and illustrate that tumour can be more difficult to distinguish in the pre-treatment MRI (post hormone therapy). Note in all cases the delineated tumour volumes were based on mp-MRI data, not just on the T2 weighted images shown.

Suppl Figure 1



Suppl Figure 1 Comparison of isodoses for a patient with F-PTV in the right anterior and right posterior mid-gland sectors. (a) no boost plan (b) F-PTV boost plan (c) sector boost plan.

MRI acquisition

Scans were performed on an Avanto (Siemens AG, Munich, Germany) 1.5T scanner, using phased-array pelvic and spine coils for signal reception. All MRI images were acquired in transverse-oblique planes such that slice-by-slice the posterior edge of the prostate remains in as consistent a position as possible. This is designed to assist matching of prostate position in MRI to TRUS image registration for treatment planning. T2W MRI used a turbo-spin echo (SE) sequence with repetition time (TR) 4970ms, echo time (TE) 87ms, echo train length 13, 0.7mm pixel size, slice thickness 2.5mm (no slice gap) (3mm slice thickness for the staging scans), 28 slices, field of view (FOV) 220mm. DWI MRI used a single shot SE-echo planar imaging (EPI) sequence with TR 3000ms, TE 77ms, 1.4mm pixel size, slice thickness 4.5mm (0.5mm gap), 14 slices, FOV 220mm, b-values 0, 150, 500, 750 s/mm^2 . Apparent diffusion coefficient (ADC) maps generated by the scanner from all b-values were used for subsequent analysis. DCE MRI (included in the pre-treatment MRI scans only) used a 3D spoiled gradient echo sequence with TR 4.4ms, TE 1.2ms, flip angle 21° , $2 \times 2 \times 5 \text{mm}$ pixel size, FOV 320mm and 20 slices (6 additional slices were acquired superiorly to reduce in-flow effects). 200 acquisitions were acquired with 2s time resolution. A bolus injection of 0.1mmol/kg Dotarem® (Guerbet Group, Villepinte, France) was administered at 3ml/s after 10s scan time. A patient specific arterial input function (AIF) was measured in the iliac artery, and pixel maps of the volume transfer constant K^{trans} were generated by fitting a Tofts 1-compartment model to the data