



UNIVERSITY OF LEEDS

This is a repository copy of *Which patellofemoral joint imaging features are associated with patellofemoral pain? Systematic review and meta-analysis.*

White Rose Research Online URL for this paper:
<http://eprints.whiterose.ac.uk/89944/>

Version: Published Version

Conference or Workshop Item:

Drew, B, Redmond, AR, Smith, TO et al. (2 more authors) Which patellofemoral joint imaging features are associated with patellofemoral pain? Systematic review and meta-analysis. In: International Patellofemoral Pain Research Retreat, 02-04 Sep 2015, Manchester, UK.

Reuse

Unless indicated otherwise, fulltext items are protected by copyright with all rights reserved. The copyright exception in section 29 of the Copyright, Designs and Patents Act 1988 allows the making of a single copy solely for the purpose of non-commercial research or private study within the limits of fair dealing. The publisher or other rights-holder may allow further reproduction and re-use of this version - refer to the White Rose Research Online record for this item. Where records identify the publisher as the copyright holder, users can verify any specific terms of use on the publisher's website.

Takedown

If you consider content in White Rose Research Online to be in breach of UK law, please notify us by emailing eprints@whiterose.ac.uk including the URL of the record and the reason for the withdrawal request.

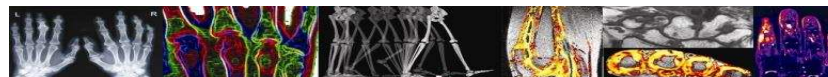


eprints@whiterose.ac.uk
<https://eprints.whiterose.ac.uk/>

Which patellofemoral imaging features are associated with patellofemoral pain?

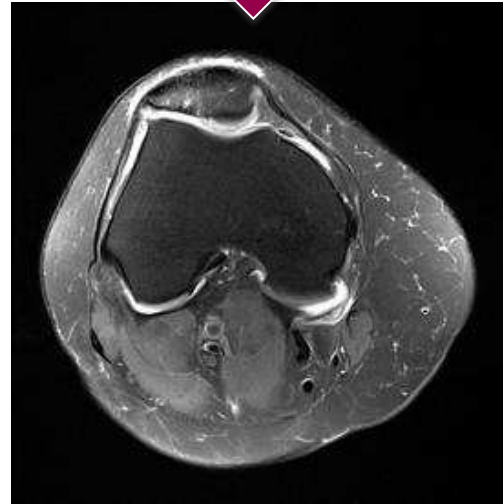
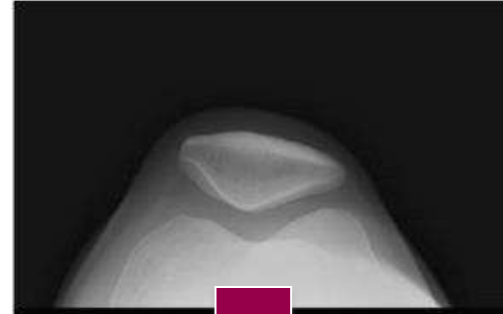Systematic review and meta-analysis

Benjamin T Drew; Anthony C Redmond; Toby O Smith;
Florence Penny; Philip G Conaghan



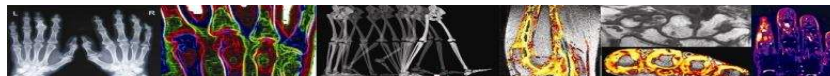
Background

- PFJ structure widely believed to be related to PFP
- Historically viewed using x-ray
- Advances in imaging over last 20 years
- No consensus on imaging features to use
- **To determine which imaging features are most likely to be associated to PFP**



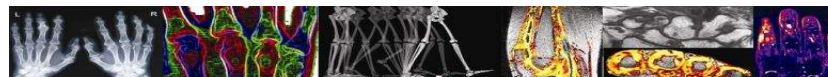
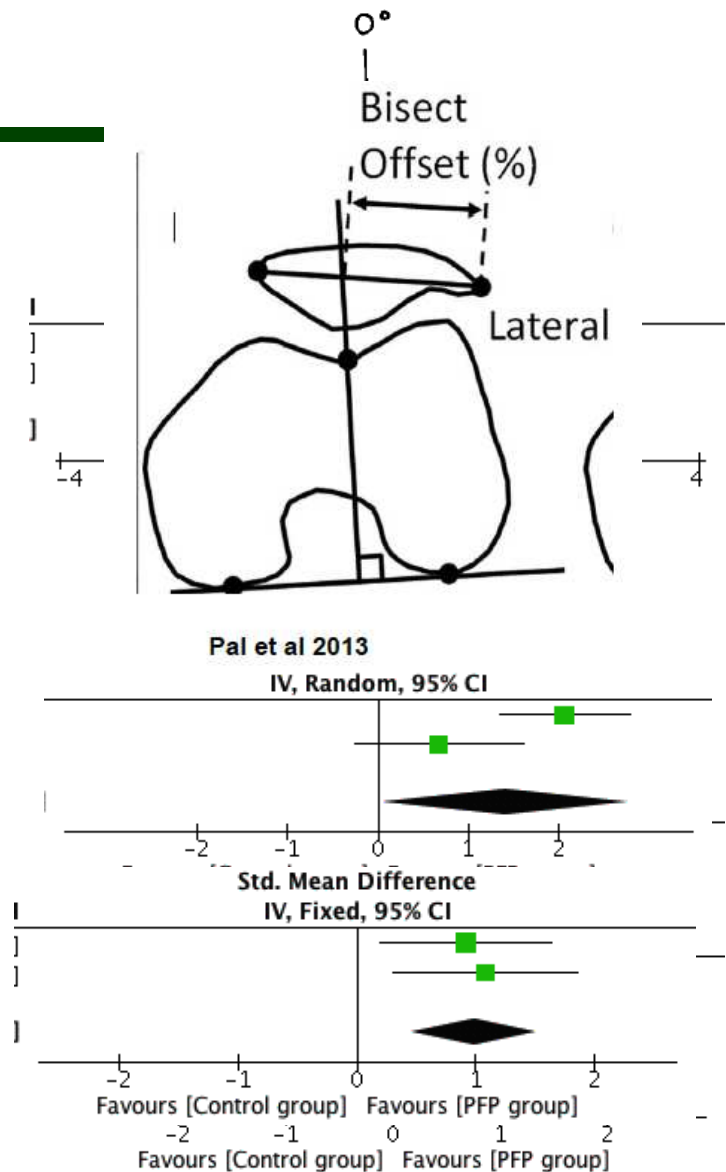
Methods

- Included studies:
 - PFP vs. Control
 - < 45 years old
 - US, MRI, CT & X-ray
- Quality assessment using Modified Downs & Black checklist
- Best-evidence synthesis and meta-analysis
- Sensitivity analysis for full weight bearing



Results

- 40 studies (all moderate to high quality)
- Two features :
 - MRI bisect offset at 0° with load
 - CT congruence angle at 15° with & without load
- Sensitivity analysis:
 - ↑MRI bisect offset
 - ↑MRI patella tilt



Conclusions

- Future studies need to clearly report:
 - Study population
 - Imaging-reporting issues
- Imaging under full weight bearing improved the ability to differentiate between PFP and control groups
- MRI bisect offset and CT congruence angle are imaging features most likely to be seen in PFP and not in controls

