



UNIVERSITY OF LEEDS

This is a repository copy of *Cortical Functioning in Children with Developmental Coordination Disorder: A Motor Overflow Study*.

White Rose Research Online URL for this paper:
<http://eprints.whiterose.ac.uk/87876/>

Version: Accepted Version

Article:

Licari, M, Billington, J orcid.org/0000-0003-0995-8875, Reid, S et al. (7 more authors) (2015) Cortical Functioning in Children with Developmental Coordination Disorder: A Motor Overflow Study. *Experimental Brain Research*, 233 (6). pp. 1703-1710. ISSN 0014-4819

<https://doi.org/10.1007/s00221-015-4243-7>

Reuse

Items deposited in White Rose Research Online are protected by copyright, with all rights reserved unless indicated otherwise. They may be downloaded and/or printed for private study, or other acts as permitted by national copyright laws. The publisher or other rights holders may allow further reproduction and re-use of the full text version. This is indicated by the licence information on the White Rose Research Online record for the item.

Takedown

If you consider content in White Rose Research Online to be in breach of UK law, please notify us by emailing eprints@whiterose.ac.uk including the URL of the record and the reason for the withdrawal request.



eprints@whiterose.ac.uk
<https://eprints.whiterose.ac.uk/>

Cortical Functioning in Children with Developmental Coordination Disorder: A Motor Overflow Study

Melissa K. Licari¹, Jac Billington², Siobhan L. Reid¹, John P. Wann³, Catherine M. Elliott⁴, Anne M. Winsor⁵, Erin Robins⁶, Ashleigh L. Thornton¹, Randall Jones⁵ & Michael Bynevelt^{5,6}

¹School of Sport Science, Exercise & Health, The University of Western Australia

²Institute of Psychological Sciences. University of Leeds.

³Department of Psychology, Royal Holloway, University of London

⁴School of Paediatrics & Child Health, The University of Western Australia

⁵Neurological Intervention & Imaging Service of Western Australia, Sir Charles Gairdner Hospital

⁶Department of Diagnostic Imaging, Princess Margaret Hospital for Children

Correspondence:

Asst. Prof. Melissa Licari

School of Sport Science, Exercise & Health

The University of Western Australia

35 Stirling Highway

Crawley WA 6009

Ph: +61 8 6488 7282

Email: melissa.licari@uwa.edu.au

Abstract

This study examined brain activation in children with Developmental Coordination Disorder (DCD) to reveal areas that may contribute to poor movement execution and/or abundant motor overflow. Using functional magnetic resonance imaging (fMRI), 13 boys with DCD (mean age = 9.6yrs ± 0.8) and 13 typically developing controls (mean age = 9.3yrs ± 0.6) were scanned performing two tasks (finger sequencing and hand clenching) with their dominant hand, while a four-finger motion sensor recorded contralateral motor overflow on their non-dominant hand. Despite displaying increased motor overflow on both functional tasks during scanning, there were no obvious activation deficits in the DCD group to explain the abundant motor overflow seen. However, children with DCD were found to display decreased activation in the left superior frontal gyrus on the finger

sequencing task, an area which plays an integral role in executive and spatially oriented processing. Decreased activation was also seen in the left inferior frontal gyrus, an area typically active during the observation and imitation of hand movements. Finally, increased activation in the right postcentral gyrus was seen in children with DCD, which may reflect increased reliance on somatosensory information during the execution of complex fine motor tasks.

Keywords: Developmental Coordination Disorder, functional magnetic resonance imaging, brain function, motor overflow

Introduction

Affecting up to 6% of school-aged children, Developmental Coordination Disorder (DCD) is a condition characterized by the inability to execute movement skills at an age-appropriate level (American Psychiatric Association 2013). Children display a wide variety of movement problems, including fine and gross motor clumsiness, difficulty with balance and postural control, and the presence of neurodevelopmental immaturities such as choreiform and mirror movements (World Health Organisation 2012). The coordination issues are relatively mild when compared to other movement conditions, but significant enough to cause activity limitations and participation restrictions, as well as negatively impacting social and emotional development (Cairney et al. 2010).

The underlying etiology of the movement difficulties associated with DCD is largely unknown, but has long been suspected to reflect subtle deficits in neurological functioning. To date, there have been limited neuroimaging studies completed to examine suspected deficits in neurological functioning in this population. On a response inhibition task, Querne et al. (2008) examined the functional connectivity of the attentional network of nine children with DCD aged 8-13 years. Even though children with DCD performed the task as well as controls and were found to engage similar cortical regions, activation patterns of the cortical networks were different. Specifically, the connectivity between the middle frontal and anterior cingulate cortex to inferior parietal cortex varied, potentially resulting in the engagement of other inhibitory mechanisms to sustain a good level of inhibitory control. Other studies examining neurological functioning of children with DCD have looked at performance on visuomotor tasks. Kashiwagi et al. (2009) found decreased activation in regions associated with visuomotor control in 12 boys with DCD aged 9-12 years. Finally, Zwicker, Missiuna, Harris and Boyd (2010) found extensive activation differences in the frontal, parietal and temporal regions of seven children with DCD aged 8-12 years, with children with DCD activating a different neural network to complete a fine motor task compared to typically developing children.

While the aforementioned studies have provided great insight into potential mechanisms underlying DCD, there is certainly a need for ongoing research in this area. Due to the heterogeneous nature of DCD, future research examining children who present with specific motor symptoms, and not purely on a diagnosis of DCD, are likely to provide greater insight into cortical areas contributing to particular motor symptoms. One symptom with the potential to reveal distinct differences in cortical activation patterns, particularly in relation to suspected deficits in inhibitory control, is motor overflow. Motor overflow, one of a cluster of symptoms classified as a neurological soft sign, refers to the presence of extraneous movements occurring in parts of the body not

actively involved in the performance of a task (Licari et al. 2006). Even though motor overflow is considered a normal developmental phenomenon in children (Largo et al. 2003), abundance or persistence is likely to substantially interfere with the aesthetics of motor performance (Kuhtz-Buschbeck et al. 2000) and potentially delay motor development. Neurological soft signs were recently suggested to not be indicative for the diagnosis of DCD (Blank et al. 2012), but evidence from our previous research suggests otherwise (Licari et al. 2006; Licari and Larkin 2008), highlighting the need for further work to examine such signs in this population.

Motor overflow is displayed on a variety of different tasks and is classified according to the anatomical location of extraneous movements presented. One type of motor overflow with the potential to be highly suited to the neuroimaging environment, causing activation in homologous muscles on the side opposite to the primary action, is contralateral motor overflow. Tasks commonly used to evoke contralateral motor overflow are repetitive sequential finger movement tasks (Licari et al. 2006; Licari and Larkin 2008; Largo et al. 2001; MacNeil et al. 2011), with such tasks employed in previous functional magnetic resonance imaging (fMRI) research to investigate other clinical populations (Mostofsky et al. 2006). To date, no studies have been conducted to investigate cortical activation patterns contributing to increased motor overflow in children with DCD. This was the primary aim of the present study. In addition, this study sought to examine whether children with DCD display activation profiles similar to previous fMRI studies investigating other complex visuomotor tasks. Children with DCD were recruited into this study on the provision that they presented with abundant motor overflow on clinical examination.

Materials and Methods

Participants

A total of 26 right-handed boys aged 8-10 years were recruited for this study, 13 from State Child Development Centre in Western Australia with a diagnosis of DCD and 13 group-aged matched typically developing controls. All children were assessed using the MABC-2 (Henderson et al. 2007) to ensure motor performance was below that expected for chronological age in the DCD group ($\leq 5^{\text{th}}$ percentile) and within the normative range for the control group ($> 15^{\text{th}}$ percentile). Handedness was screened using the Edinburgh Handedness Inventory (Oldfield 1971). Children with DCD were also assessed using selected items from the Zurich Neuromotor Assessment (Largo et al. 2001) to ensure they displayed moderate to severe contralateral motor overflow. These items included finger tapping, finger sequencing and the pegboard. Finally, all children were screened using the Vanderbilt ADHD Diagnostic Parent Rating Scale (VADPRS, MacNeil et al. 2011) to exclude children with

attention deficits that may impact motor overflow severity or alter neurological function.

Two weeks prior to scanning, all participants completed fMRI training to familiarise them with the scanning environment (noise, confined space, head coil), scanning procedure and behavioural tasks to be performed. Parental consent and child assent was obtained throughout each phase of the study. Ethics approval was obtained from the Human Research Ethics Committees at the University of Western Australia (RA/4/1/2572) and Princess Margaret Hospital for Children (1804).

Behavioral Tasks

Participants completed two active tasks on their dominant right hand. The first was a sequential finger sequencing task which involved participants touching each finger onto their thumb one at a time (Figure 1a). Children with DCD have been shown to present with abundant contralateral motor overflow on this task (Licari et al. 2006; Licari and Larkin 2008) and it is a task easily adapted to the scanning environment. The second task was a repetitive hand clenching task which involved participants opening and closing their hand (Figure 1b). This task was selected because it involved movement of the same digits and activated similar cortical regions during piloting. Children with DCD were also assessed performing this task prior to scanning and minimal contralateral motor overflow was observed, making it a suitable contrast task for this study.

INSERT FIGURE 1 ABOUT HERE

Imaging Parameters

Imaging was conducted on a 3T Philips Achieva TX scanner using an 8 channel head coil. High resolution anatomical images were acquired first (T1-weighted 3D FFE 160 slices 1x1x1 mm), followed by two functional studies (T2-weighted gradient echo, TR/TE = 3000/35ms, flip angle 90°, 24 axial slices with a thickness of 4mm, interslice gap = 0mm). A randomized block design was employed, with participants completing a task continuously for 27 seconds followed by a 12 second period of rest. Each task was completed 8 times in total. Visual and auditory stimuli (metronome ticks at 0.8Hz) were used to prompt and coordinate each task. Total scan time was 16 minutes.

An individually made thermo-plastic splint was worn by participants on the active dominant hand during scanning to isolate movement in the digits. A custom built four-finger motion sensor glove (Mag Design & Engineering, California) with flex sensors along each digit (see Fig. 2) was worn by participants on their non-

dominant inactive hand to record any displacement of digits during performance of functional tasks (sampling rate 100Hz).

INSERT FIGURE 2 ABOUT HERE

Statistical Analysis

MRI data were analyzed using Brainvoyager QX software (version 2.1, Brain Innovations, Maastricht, Netherlands). Preprocessing of the data included both three-dimensional motion correction (mean displacement DCD = 1.08mm, Control = 0.92mm) and temporal filtering to remove head movement and signal drift respectively. All images were smoothed using an 8mm full half width maximum Gaussian kernel to improve registration across participants. Each participant's functional images were co-registered with their high resolution anatomical image and normalized to Talairach space. Contrast maps were created at the individual level for each subject. In a second level multi-subject random effects GLM, ANOVAs were performed to explore differences between conditions and groups. All results are reported in Talairach space with activation passing a threshold of $p < 0.05$ (false discovery rate (FDR) corrected) with a voxel-extent threshold of $k > 15$.

Analysis of the glove data was performed using a custom written program in MATLAB (MATLAB, version 7.11.0 2010b, Mathworks, Inc., USA) synchronized to functional run times. A fast fourier transform analysis was carried out to discern the mean amplitude of displacement for each digit, which was then summed to create a mean total overflow score for each condition. A one-way ANOVA using SPSS 18.0 was performed to look at the differences between groups across conditions and to explore participant characteristics (age, MABC-2, VADPRS).

Results

Participant Characteristics

The DCD (mean age = $9.6 \text{ yrs} \pm 0.8$) and control group (mean age = $9.3 \text{ yrs} \pm 0.6$) were well matched for age with no significant differences between the groups ($p = 0.395$). As expected, the DCD group displayed significantly lower scores on the MABC-2 (mean = 1.7 ± 1.6 , $p < 0.003$) compared to the control group (mean = 42.2 ± 18.15), with all children with DCD falling below the 5th percentile. While the DCD group displayed slightly higher scores on the VADPRS (mean = 22.2 ± 14.3) compared to the control group (mean = 19.6 ± 14.0), these were not statistically significant ($p = 0.091$).

Motor Overflow

As illustrated in Fig. 3, the DCD group displayed significantly greater contralateral motor overflow compared to controls on both the finger sequencing ($p=0.002$) and hand clenching tasks ($p=0.039$) during scanning. When the tasks were compared within groups, children with DCD displayed significantly more motor overflow on the finger sequencing task compared to hand clenching ($p=0.034$), while there was no significant differences between the tasks in the control group ($p=0.483$).

INSERT FIGURE 3 ABOUT HERE

Condition Contrasts (Sequencing > Clenching)

On both the finger sequencing and hand clenching tasks, there was extensive activation in the left and right middle and inferior occipital gyri (BA19) and the left frontal and parietal lobes (BA 3,4,5,6, 9,40). There were two regions of activation seen on the finger sequencing task that were not seen on the hand clenching task; these included the right precentral gyrus (BA6) and the right precuneus (BA7). There was also significantly greater activation in the right middle occipital gyrus (BA19) on the finger sequencing task.

Group x Condition Contrasts

On the finger sequencing task, the control group displayed greater activation in the left superior frontal gyrus (BA9, Fig. 4a) and the left inferior frontal gyrus (BA44, Fig. 4b), while the DCD group displayed increased activation in the right postcentral gyrus (BA3, Fig. 4c). Coordinates and volumes of significant clusters on the finger sequencing task are presented in Table 1. There were no significant activation differences between groups in the hand clenching condition.

INSERT TABLE 1 ABOUT HERE

INSERT FIGURE 4 ABOUT HERE

Discussion

The aim of this study was to investigate cortical activation in children with DCD to reveal areas that potentially

contribute to poor execution of movement tasks and the increased prevalence of motor overflow. The tasks included in this study were both complex, one requiring individualized synchronization of each digit and the other precise movements of all four digits. Even though there were visual prompts on screen to assist with the timing of tasks, participants were unable to see their hand during scanning and had to rely on sensory input from sources such as proprioception and touch. Of the two tasks, finger sequencing initiated the most contralateral motor overflow and it was also the task where three distinct areas of activation difference were seen between the two groups.

A large cluster of deactivation was found in the DCD group in the left superior frontal gyrus (SFG), encompassing the lateral and superior portion of BA9. Lesion studies have revealed that the left SFG plays an integral role in working memory, is active during the highest level of executive processing, and is involved in spatially oriented processing (Du Boisgueheneuc et al. 2006), all key elements necessary for the execution of the finger sequencing task used in this study. The finding of decreased activation in the left SFG in the DCD group is consistent with Zwicker et al. (2010), indicating that children with DCD potentially have a deficit in this region. The findings also provide evidence to support behavioural studies reporting poorer performance on working memory tasks in this population (Piek et al. 2007).

The SFG forms part of an extensive cortical-subcortical network, the cerebellar-thalamic-prefrontal network, predominantly involved in higher order functioning. Even though studying activation of subcortical regions was beyond the scope of our study, it is impossible to rule out that the hypoactivity seen in the SFG was not related to deficits extending to and from other regions. Deficits in the structure and function of the cerebellar-thalamic-prefrontal network have been reported in other clinical populations presenting with abundant motor overflow, in particular in schizophrenia. Studies have revealed that patients with schizophrenia have reduced volumes in the superior frontal gyrus and cerebellum, and these reduced volumes have been moderately correlated with abundant neurological soft signs (Mouchet-Mages et al. 2011; Venkatasubramanian et al. 2008) which typically includes the measurement of motor overflow. According to the cognitive dysmetria model of schizophrenia, disrupted connectivity is thought to occur between cortical regions and the cerebellum which has negative consequences for linking perception, retention, retrieval and response (Andreasen et al. 1996). This ultimately influences cognitive systems including memory, attention and execution and their related sub-processes such as inhibition (Venkatasubramanian et al. 2008). Even though schizophrenia and DCD are two distinctly different conditions, there are similarities in certain motor symptoms and measures of cognitive function (i.e. working memory), which may suggest some commonality in underlying pathophysiology at the

network level. Cerebellar deficits in DCD have long been suspected (Zwicker et al. 2009), and there is some preliminary evidence to suggest slight morphological differences (Mariën et al. 2010) and underactivation of the cerebellum (Zwicker et al. 2011), however further research is needed to examine whether this region and its associated networks play a role in this disorder.

The second area of activation difference seen between the two groups in the present study was in the posterior part of the left inferior frontal gyrus (IFG), a finding once again consistent with Zwicker et al. (2010). Some may consider activation in this area to be quite an unusual finding, certainly when this area is normally associated with speech production. Interestingly, this area is also involved in the imagination, imitation and observation of complex hand movements, forming part of the mirror neuron system (MNS, Binkofski et al. 1999a, 199b). The MNS is thought to play a key role in our ability to model the behavior and action of others, the most widely used form of learning. The participants involved in this study were certainly imitating the hand actions observed during scanning, with the images presented individually within each condition; thus, it is highly likely that the MNS was active during the performance of the tasks. Even though the participants with DCD were able to perform the required actions during scanning, the decreased activity seen in the IFG may reflect a potential deficit in the development and functioning of the MNS. The MNS was recently hypothesized to be an underlying cause of motor impairments in children with DCD (Werner et al. 2012) with supportive evidence coming from studies reporting that children with DCD have difficulty learning and performing complex imitative gestures (Ozbič and Filipčič 2010). These findings however are not consistent with other studies reporting no such difficulties in gestural and imitative performance (Dewey et al. 2007). Therefore, there is a need for further research to examine whether children with DCD truly have difficulties learning complex imitative tasks and, at the cortical level, if there is a deficit in the functioning of parietal-premotor networks where the MNS is thought to exist.

The final area of activation difference in the present study was in the right postcentral gyrus, with the DCD group displaying increased activation in this area. This area plays an important role in the ongoing processing of somatic sensation. Because the children had to rely heavily on sensory information to execute the sequencing task, it is possible that the increased activation seen in the DCD group may have reflected increased reliance on this information to execute the task correctly. It may also reflect sensory integration deficits frequently seen in this population (Elbason et al. 2012). Interestingly, this finding is not consistent with Zwicker et al. (2010), who found decreased activation in the left postcentral gyrus in children with DCD when performing a trail tracing task. Additionally, on a similar sequential finger movement task to the one used in the

present study, Mostofsky et al. (2006) reported decreased activation of the right postcentral gyrus in children with attention deficit hyperactivity disorder (ADHD), a population known to display abundant motor overflow and some overlap with other motor symptoms. The differences found between studies may reflect task exposure, with children in the present study introduced to the behavioral tasks during their familiarization session two weeks prior to scanning and having the opportunity to practice at home. This may have facilitated the increased utilization of this sensory area and enabled children to execute the tasks with greater ease. Other potential reasons for the conflicting results could simply relate to task differences and the higher demand for sensory processing in the present study.

While this study has revealed some interesting findings concerning potential cortical deficits in children with DCD, there were no obvious activation deficits to explain the abundant motor overflow seen. As mentioned, functioning of the SFG may be implicated based on moderate correlations between this area and neurological soft signs in previous research, but when comparing it to other studies examining motor overflow, the findings differ. Mostofsky et al. (2006) reported a smaller extent of activation in the contralateral primary motor cortex of children with ADHD, which they attributed to insufficient neuronal activity necessary for the mobilisation of interhemispheric inhibition, a proposed causal mechanism for motor overflow. Interestingly, if this insufficiency existed, one may expect to see differing activation in the ipsilateral cortex also, but this was not seen. In the present study, no differences were found in the cortical activation patterns of the contralateral motor cortex between the two groups. Ipsilateral activation was seen in the premotor and motor areas; however this did not differ between the two groups. This ipsilateral activation could potentially be related to transcallosal inhibitory activation, but may also reflect bilateral planning and execution needed for the execution of complex unimanual tasks.

Even though fMRI certainly has the potential to explore motor symptoms linked to deficits like inhibition, other techniques may reveal more distinct differences in activation profiles. For instance, transcranial magnetic stimulation, capable of separating excitatory and inhibitory activation, may provide more detailed information concerning suspected inhibitory deficits in this population. This, along with further neuroimaging studies, are certainly an area worth pursuing in the future to help better understand the nature of this complex movement condition. Limitations of our work include the cortical area studied, with the scan volume not extending into sub-cortical areas. Further research examining these areas may provide greater insight into deficits in cognitive systems and their associated neural functions at a network level. In addition, despite attempts to select a contrast task that minimized the expression of motor overflow, children with DCD still

displayed considerable amounts of motor overflow during the hand clenching task. This may have impacted our ability to clearly identify areas contributing to abundant motor overflow across the two tasks studied. Finally, selection of children with DCD was based on one of the four diagnostic criteria from the DSM-IV criteria (American Psychiatric Association, 2000), with poor motor performance (<5th percentile) established using the MABC-2.

The present study has provided valuable confirmatory evidence to previous neuroimaging studies, adding to the growing body of literature demonstrating differences in neurological functioning in children with DCD. Specifically, it has provided evidence to support dysfunction in cortical regions associated with working memory and executive functioning, along with preliminary evidence to support suspected deficits in the MNS. This study is also one of the first to quantify a neurological symptom concurrently during scanning.

Acknowledgements

The authors would like to thank the radiology staff from Sir Charles Gairdner Hospital and Princess Margaret hospital involved in this project, and the children and parents for their time and participation. We would also like to thank Mag Design and Engineering who created the motion sensor glove.

Compliance with Ethical Standards

Funding: This project was funded by a Research Development Award from the University of Western Australia.

Conflict of interest: The authors declare they have no conflict of interest.

Ethical approval: All procedures performed in studies involving human participants were in accordance with the ethical standards of the Human Research Ethics Committees at the University of Western Australia (RA/4/1/2572) and Princess Margaret Hospital for Children (1804) and with the 1964 Helsinki declaration and its later amendments or comparable ethical standards.

Informed consent: Informed consent was obtained from all parents/guardians and verbal assent from individual participants included in the study.

References

1. American Psychiatric Association (2000) Diagnostic and Statistical Manual of Mental Disorders: 4th edition, text revision. Washington DC: American Psychiatric Association.
2. American Psychiatric Association (2013) Diagnostic and Statistical Manual of Mental Disorders: 5th edition. Washington DC: American Psychiatric Association.
3. Andreasen NC, O'Leary DS, Cizadlo T, Arndt S, Rezai K, Boles Ponto LL, et al. (1996) Schizophrenia and cognitive dysmetria: A positron-emission tomography study of dysfunctional prefrontal-thalamic-cerebellar circuitry. *Proc Nat Acad Sci* 3: 9985-990.
4. Binkofski F, Buccino G, Posse S, Seitz RJ, Rizzolatti G, et al. (1999a) A fronto-parietal circuit for object manipulation in man: evidence from an fMRI-study. *Eur J Neurosci* 11: 3276–3286. doi: 10.1046/j.1460-9568.1999.00753.x
5. Binkofski F, Buccino G, Stephan KM, Rizzolatti G, Seitz RJ, et al. (1999b) A parieto-premotor network for object manipulation: evidence from neuroimaging. *Exp Brain Res* 128: 210–213. doi:10.1007/s002210050838
6. Blank R, Smits-Engelsman B, Polatajko HJ, Wilson PH (2012) Recommendations on the definition, diagnosis and intervention of developmental coordination disorder. *Dev Med Child Neurol* 54:54-93. doi: 10.1111/j.1469-8749.2011.04171.x
7. Cairney J, Veldhuizen S, Szatmari P. (2010). Motor coordination and emotional-behavioral problems in children. *Curr Opin Psychiatr* 23: 324-29. doi: 10.1097/YCO.0b013e32833aa0aa.
8. Dewey D, Cantell M, Crawford SG (2007) Motor and gestural performance in children with autism spectrum disorders, developmental coordination disorder, and/or attention deficit hyperactivity disorder. *J Int Neuropsychol Soc* 13: 246-56. doi: 10.1017/S1355617707070270
9. Du Boisgueheneuc F, Levy R, Volle E, Seassau M, Duffau H, Kinkingnehun S, et al. (2006) Functions of the left superior frontal gyrus in humans: A lesion study. *Brain* 129: 3315-328. DOI:10.1093/brain/awl244
10. Elbasan B, Kayihan H, Dugun I (2012) Sensory integration and activities of daily living in children with developmental coordination disorder. *Ital J Pediatr* 38: 14. doi: 10.1186/1824-7288-38-14.
11. Henderson SE, Sugden DA, Barnett AL (2007) Movement assessment battery for children-2 second edition. London, UK: The Psychological Corporation.
12. Kuhtz-Buschbeck J, Krumlinde Sundholm L, Eliasson A, Forssberg H (2000) Quantitative assessment of mirror movements in children and adolescents with hemiplegic cerebral palsy. *Dev Med Child Neurol* 42: 728-36. doi: 10.1111/j.1469-8749.2000.tb00034.x

13. Largo RH, Caflisch JA, Hug F, Muggli K, Molnar AA, Molinari L (2001) Neuromotor development from 5 to 18 years. Part 2: Associated movements. *Dev Med Child Neurol* 43: 444-53. doi: 10.1111/j.1469-8749.2001.tb00740.x
14. Largo RH, Fischer JE, Rousson V (2003) Neuromotor development from kindergarten age to adolescence: developmental course and variability. *Swiss Med Wkly* 133: 193-99.
15. Kashiwagi M, Iwaki S, Narumi Y, Tamai H, Suzuki S (2009) Parietal dysfunction in developmental coordination disorder. *NeuroReport* 20: 1319-324. doi: 10.1097/WNR.0b013e32832f4d87
16. Licari M, Larkin D, Miyahara (2006) The influence of developmental coordination disorder and attention deficits on associated movements in children. *Hum Mov Sci* 25: 90-99. doi: 10.1016/j.humov.2005.10.012
17. Licari M, Larkin, D. (2008). Increased associated movement: Influence of attention deficits and movement difficulties. *Hum Mov Sci* 27: 310-24. doi:10.1016/j.humov.2008.02.013
18. MacNeil LK, Xavier P, Garvey MA, Gilbert DL, Ranta ME, Denckla MB, et al. (2011) Quantifying excessive mirror overflow in children with attention-deficit/hyperactivity disorder. *Neurol* 76: 622-28. doi: 10.1212/WNL.0b013e31820c3052
19. Mariën P, Wackenier P, De Surgeloose D, De Deyn PP, Verhoeven J (2010) Developmental coordination disorder: disruption of the cerebello-cerebral network evidenced by SPECT. *Cerebellum* 9: 405-10. doi: 10.1007/s12311-010-0177-6
20. Mostofsky SH, Rimrod SL, Schafer JGB, Boyce A, Goldberg MC, Pekar JJ, et al. (2006) Atypical motor and sensory cortex activation in attention-deficit/hyperactivity disorder: A functional magnetic resonance imaging study of simple sequential finger tapping. *Biol Psychiat* 59: 48-56. doi: 10.1016/j.biopsych.2005.06.011
21. Mouchet-Mages S, Rodrigo S, Cachia A, Mouaffak F, Oliel JP, Meder JF, et al. (2011) Correlations of cerebello-thalamo cortical-prefrontal structure and neurological soft signs in patients with first-episode psychosis. *Acta Psychiat Scand* 123: 451-58. doi: 10.1111/j.1600-0447.2010.01667.x.
22. Oldfield RC (1971) The assessment and analysis of handedness: the Edinburgh inventory. *Neuropsychologia* 9: 97-113. doi:10.1016/0028-3932(71)90067-4
23. Ozbič M, Filipčič T (2010) Complex imitation of gestures in school-aged children with learning difficulties. *Kinesiology* 4: 44-55.
24. Piek JP, Dyck MJ, Francis M, Conwell A. (2007) Working memory, processing speed, and set-shifting in children with developmental coordination disorder and attention-deficit-hyperactivity disorder. *Dev Med Child Neurol* 49: 678-83. doi: 10.1111/j.1469-8749.2007.00678.x

25. Querne L, Berquin P, Vernier-Hauvette M-P, Fall S, Deltour L, Meyer M-E, et al. (2008) Dysfunction of the attentional brain network in children with developmental coordination disorder: A fMRI study. *Brain Res* 1244: 89-102. doi: 10.1016/j.brainres.2008.07.066.
26. Venkatasubramanian G, Jayakumar PN, Gangadhar BN (2008) Neuroanatomical correlates of neurological soft signs in antipsychotic-naive schizophrenia. *Psychiat Res-Neuroim* 164: 215-22. doi: 10.1016/j.psychresns.2007.12.021.
27. Werner JM, Cermak SA, Aziz Zadeh L (2012) Neural Correlates of Developmental Coordination Disorder: The Mirror Neuron System Hypothesis in children and adolescents. *Behav Brain Sci* 2: 258-68. doi: 10.4236/jbbs.2012.22029
28. Wolraich ML. (2013) Vanderbilt ADHD Parent Rating Scale. American Academy of Pediatrics and the National Initiative for Children's Healthcare Quality. Cambridge: MA.
29. World Health Organisation (2012) ICD-10 Classifications of Mental and Behavioural Disorder: Clinical Descriptions and Diagnostic Guidelines. Geneva: World Health Organisation.
30. Zwicker JG, Missiuna C, Boyd LA. (2009) Neural correlates of developmental coordination disorder: a review of hypotheses. *J Child Neurol* 24:1273–1281. doi: 10.1177/0883073809333537
31. Zwicker J, Missiuna C, Harris R, Boyd LA (2010) Brain activation of children with developmental coordination disorder is different than peers. *Pediatr* 126:e678-86. doi: 10.1542/peds.2010-0059
32. Zwicker J, Missiuna C, Harris R, Boyd LA (2011) Brain activation associated with motor skill practice in children with developmental coordination disorder: an fMRI study. *Int J Dev Neurosci* 29:145-52. doi: 10.1016/j.ijdevneu.2010.12.002.

Fig. 1 Images displayed for the finger sequencing (a.) and hand clenching (b.) tasks

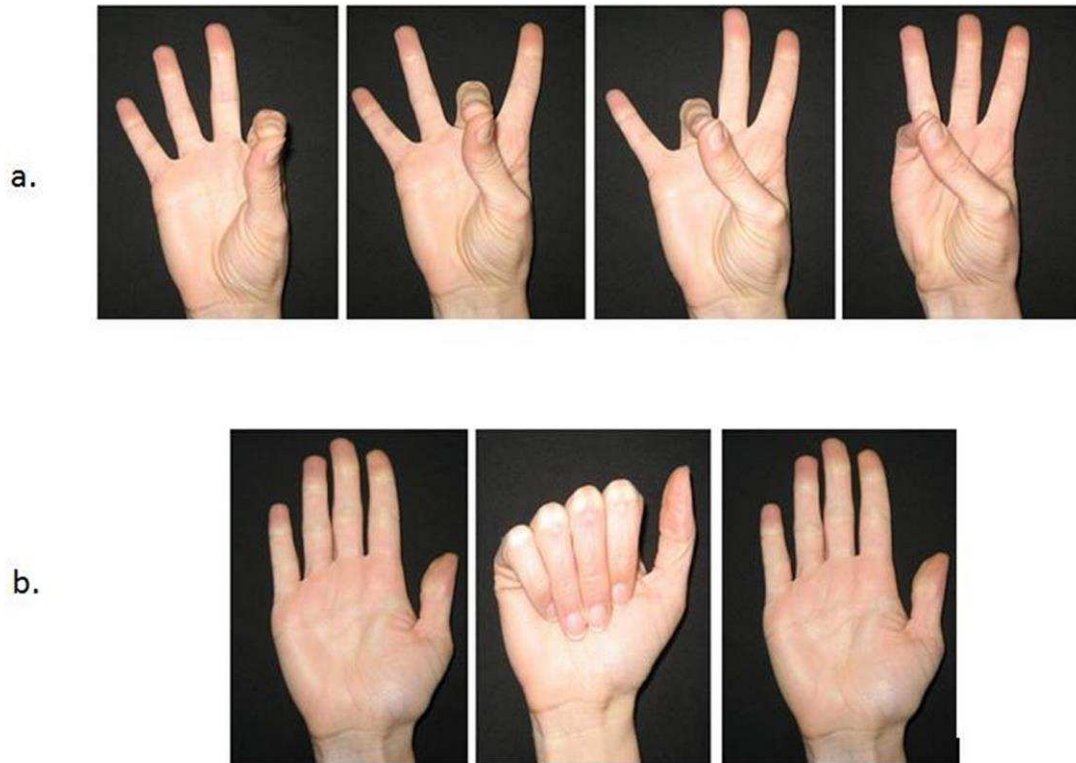


Fig. 2 Motion sensor glove used to record motor overflow.



Fig. 3 Total mean displacement (motor overflow) on the finger sequencing and hand clenching tasks in the DCD and Control groups

* $p < 0.05$, ** $p < 0.001$

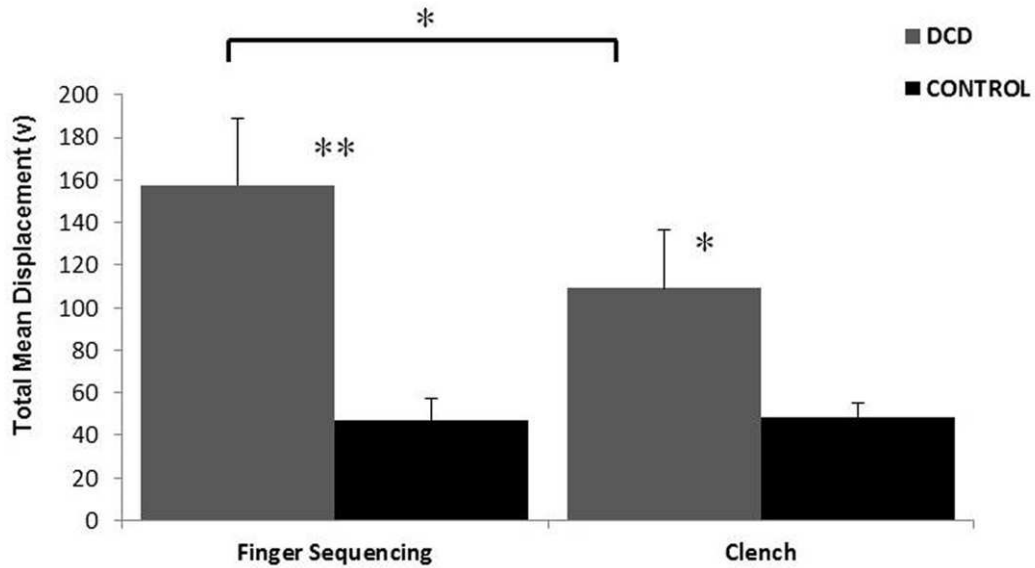


Fig. 4 Increased activation in the Con>DCD in the left superior frontal gyrus (a.) and left inferior frontal gyrus (b.), and increased activation in the DCD>Con in the right postcentral gyrus (c.) on the finger sequencing task.

TRA = transverse plane, COR = coronal plane

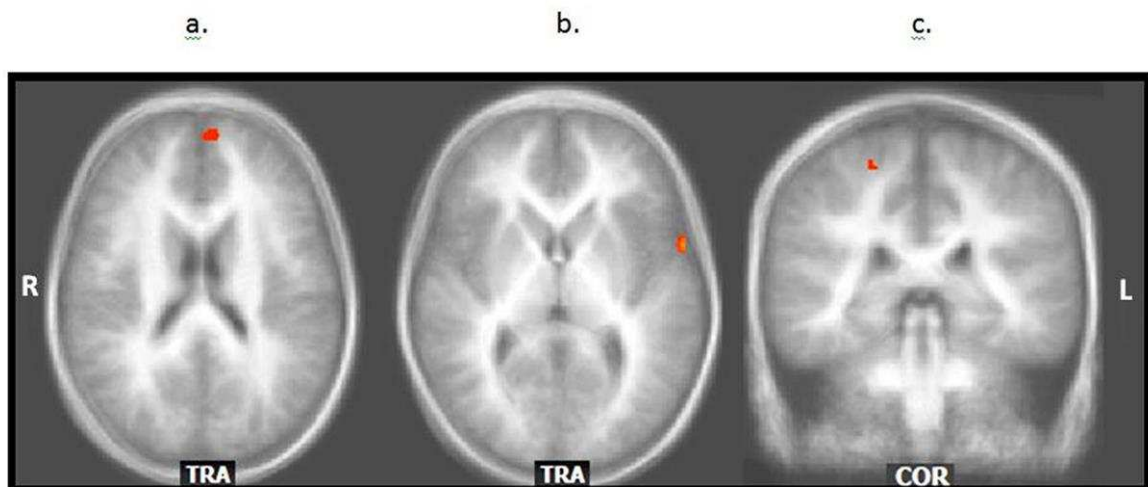


Table 1. Significant activation on the finger sequencing task

Brain Region	k	BA	Talairach Coordinates		
			x	y	z
Sequence: Con>DCD					
Left superior frontal gyrus	157	9	-7	53	23
Left inferior frontal gyrus	113	44	-59	7	6
Sequence: DCD>Con					
Right postcentral gyrus	59	3	20	-35	58

FDR corrected <0.05