

This is a repository copy of *On the differential diagnosis of arthropathy in bovids*.

White Rose Research Online URL for this paper:

<https://eprints.whiterose.ac.uk/46974/>

Version: Published Version

Article:

O'Connor, Terry (2008) On the differential diagnosis of arthropathy in bovids. *Documenta Archaeobiologiae*. pp. 165-186. ISSN 1611-7484

Reuse

Items deposited in White Rose Research Online are protected by copyright, with all rights reserved unless indicated otherwise. They may be downloaded and/or printed for private study, or other acts as permitted by national copyright laws. The publisher or other rights holders may allow further reproduction and re-use of the full text version. This is indicated by the licence information on the White Rose Research Online record for the item.

Takedown

If you consider content in White Rose Research Online to be in breach of UK law, please notify us by emailing eprints@whiterose.ac.uk including the URL of the record and the reason for the withdrawal request.

On the differential diagnosis of arthropathy in bovids

Terry O'Connor

Department of Archaeology, University of York, UK

Abstract / Zusammenfassung

The paper reviews the aetiology and diagnosis of joint pathologies in cattle and caprines. Key papers in the animal palaeopathology literature are briefly reviewed, and the potential and limitations of the veterinary literature are discussed. The aetiology and pathognomic clinical criteria of common arthropathies are described, with particular concentration on osteoarthritis and osteochondrosis. The term *osteochondrosis* (or *osteochondritis dissecans*) is not appropriate for zooarchaeological material and should be discontinued. The application of clinical criteria to dry bone specimens is demonstrated for series of zooarchaeological specimens that illustrate the common arthropathies and some more unusual cases. The need for greater diagnostic consistency and ready access to comparative specimens is identified and a provisional scheme for classification and differential diagnosis of arthropathies in bovid bones proposed.

Die Studie bewertet die Ätiologie und Diagnose von Gelenkpathologien bei Rindern und Caprinen. Die in der Literatur vorhandenen Schlüsselpublikationen zur Paläopathologie von Tieren werden kurz evaluiert und die Möglichkeiten und Grenzen der tiermedizinischen Literatur zu dieser Thematik aufgezeichnet. Es werden die Ätiologie und die pathognomonisch-klinischen Merkmale häufig vorkommender Arthropathien mit Gewichtung auf Osteoarthritis und Osteochondrose beschrieben. Der Begriff *Osteochondrosis* (bzw. *Osteochondritis dissecans*) erweist sich dabei als unangebracht für archäozoologisches Material und sollte daher vermieden werden. Die Anwendbarkeit von klinischen Kriterien auf Knochen wird anhand von archäozoologischen Fundserien, die sowohl die häufig auftretenden Arthropathien als auch einige seltenere Fälle beinhalten, demonstriert. In der Diskussion wird die Notwendigkeit einer einheitlicheren Vorgehensweise bei der Diagnosestellung sowie der direkte Zugang zu Vergleichsfunden herausgestellt und ein Schema für die Klassifikation und Differentialdiagnose von Arthropathien bei Bovidenknochen vorgeschlagen.

Key words: Palaeopathology, arthropathy, osteoarthritis, osteochondrosis, bovids
Paläopathologie, Arthropathie, Osteoarthritis, Osteochondrose, Boviden

Introduction

In the field of animal palaeopathology, evidence of disease and other abnormalities in synovial joints has been one of the few areas of investigation to have generated a substantial amount of literature (e.g. Harcourt 1967, 1971; von den Driesch 1975; Higham et al. 1981). None the less, the precision and confidence with which we can interpret the pathological specimens that occur in archaeological samples is appreciably less than we see in the interpretation of arthropathies in human osteological material (e.g. Rogers et al. 1987; Bank et al. 1998; Rogers & Waldron 1995; Mackenzie & Dawson. 2005; Dequeker & Luyten 2008). For example, the association of quite specific arthropathies in the metapodio-phalangeal joints with the stresses and strains resulting from traction has been investigated at length, and certain patterns of arthropathy in the feet of cattle has been taken to be pathognomic for this specific ac-

tivity (Bartosiewicz et al. 1997; De Cupere et al. 2000). Despite the considerable weight of research supporting this interpretation, Johannsen (2005) has recently shown that the body weight of individual animals may be a confounding factor in predisposing the development of 'traction' arthropathies, weakening the link between arthropathy and activity. This example serves to demonstrate the first problem that afflicts the investigation of arthropathies: precision of differential diagnosis, and the challenge of developing a diagnostic terminology and taxonomy that allows us to distinguish conditions of different aetiologies whilst recognising that we are studying the clinical outcomes of an individual physiological reaction to a particular set of factors. It is likely that different individuals will react differently to the same clinical challenge, and that different aetiologies may produce outwardly similar pathological outcomes in dry bone specimens. The modern veterinary literature is only intermittently

helpful, as it tends to concentrate on companion animals such as dogs and cats, on commercially valuable horses, and on farm livestock to the extent of deciding whether a condition is treatable or grounds for slaughter. Diagnosis by soft tissue or serological feature is clinically simpler and often less invasive than accessing and preparing hard tissues. Furthermore, it is unusual for pathological conditions to proceed to the point at which skeletal lesions are developed. It is unusual, therefore, for a chronic skeletal condition to be encountered in farm veterinary practice, and unusual for such cases to get into the literature. This problem is not specific to joint pathologies. Even a widespread and significant zoonotic condition such as tuberculosis presents significant disparities between the clinical, pathological and zooarchaeological literature (Lignereux & Peters 1999).

Our second challenge arises when we draw back from the individual specimen to understand the significance of arthropathies in the population concerned. Animal palaeopathology differs from human palaeopathology in the important detail that we are only rarely dealing with whole skeletons of animals. It is unusual to be able to link pathological signs in one joint surface with its articulating neighbour, and quite exceptional to be able to associate an arthropathy in one joint with the state of others in the same limb or with the antimeric limb. Any attempt to calculate prevalence has to be expressed in terms of the frequency of occurrence of abnormalities in a specific joint surface, not the relative frequency of occurrence in percent of animals (NISP). That in turn removes us from herds of cattle or flocks of sheep, and hence from an overtly archaeological interpretation of what may otherwise seem to be mere curiosity. Perhaps for this reason, arthropathies are rarely quantified when encountered in the zooarchaeological record, at least not in terms that allow some comparisons to be made of prevalence rates among different populations. That is particularly regrettable, as it is just those variations in prevalence rate that may yield information about livestock management and welfare. Finally, of course, there is the problem that taphonomic processes may mimic pathological conditions, or preferentially remove affected specimens (Bartosiewicz 2008).

This paper takes an overview of joint pathologies – arthropathies – in cattle and caprines. By reviewing what we know of joint function and malfunction and applying that to examples drawn from the literature and from the author's own experience, the aim is to clarify some diagnostic criteria and nomenclature and to propose some specific directions for further research.

Arthropathies in the zooarchaeological literature

The study of palaeopathologies in non-human animals has a much shorter history than its study in humans. Early published examples are typically in the veterinary or vertebrate biology literature. Harcourt (1967) presents a case study of osteoarthritis (*sic*; see below) in a Romano-British dog, helpfully including comparative illustrations of affected and unaffected joint surfaces, and including some discussion of the possible symptomatic impact of the pathology. The same author, an experienced vet, later published what may be the first systematic survey of pathologies in zooarchaeological material (Harcourt 1971). Joint pathologies were noted by Harcourt as 'the commonest lesion in cattle', and he illustrates a typical case of ankylosis of the tarso-metatarsal joint. Further syntheses of this period include a particularly well-illustrated review by von den Driesch (1975), which includes a number of now familiar joint pathologies in cattle, and a review of pathological specimens from the early medieval settlement of Scharstorf (Feddersen & Heinrich 1978). The differential diagnosis of arthropathies in these early papers is based largely on veterinary sources such as Nieberle and Cohrs (1970).

The potential of animal palaeopathology as a research area in its own right was reviewed by Brothwell (1969) and by Siegel (1976). A few years later, Baker and Brothwell (1981) published what is still, remarkably, the only monograph (rather than collected papers) on the subject. Baker and Brothwell give one chapter to diseases of joints, and propose a grouping of joint disorders that is broadly followed in this paper. There is an interesting disjunction in their review. Many of the examples and conditions that are discussed from the veterinary point of view are commonly present in horses and dogs, the two animals most often encountered by Baker during his extensive veterinary career, whereas most of the archaeological examples are of pathologies in cattle and sheep. This is a minor point: Baker and Brothwell's review has been highly influential in subsequent work on joint pathologies in zooarchaeology. Otherwise, much of the published work around this time consisted of descriptions, diagnoses and (sometimes) illustrations of pathological specimens, often as part of a 'site bone report'. A brief but notable paper is that by van Wijngaarden-Bakker and Krauwer (1979). Although their descriptions are quite succinct, the authors have illustrated a number of specimens, including several instances of cattle metapodials to which the distal tarsals and naviculocuboid (centrotarsale) are fused by ankylosis (i.e. the formation of periarticular exostoses that 'bridge' between adjacent bones without involvement of the articular surfaces). This is one of the most familiar joint pathologies seen in ancient cattle

and, as noted above, one of the first to be systematically described in the literature. An important paper is that by Higham et al. (1981) in which they explore the relationship between exostosis development on the distal phalanges of cattle and water buffalo as evidence for the emergence of plough agriculture in Southeast Asia. The skeletal consequences of using cattle for draught purposes have since been the subject of extensive and detailed investigation, reviewed below.

Subsequent to Baker and Brothwell's influential volume, much of the published work on animal palaeopathology in general, and arthropathies in particular, has consisted of research papers that investigate a specific pathological condition (e.g. Brothwell et al. 1996; Davies 2005), overviews of animal pathology at major archaeological sites (e.g. Brothwell 1995; Shaffer & Baker 1997), and papers that propose a more systematic *modus operandi* for the description and recording of animal palaeopathology (e.g. Clark 1994; Vann & Thomas 2006). In a recent compilation of papers on the topic, four of the sixteen contributions were explicitly about arthropathies in cattle (Davies et al. 2005).

Arthropathies in the veterinary literature

This is not the place for a full review of joint pathologies in living cattle and sheep, nor is the author qualified to write such a review. It is, however, important to take an overview of the current veterinary understanding of some of the major pathological conditions that leave traces on the bony skeleton. Arthropathies in mammals in general fall into just a few broad categories, and the development of a useful taxonomy and criteria for diagnosis has been a particular issue in the human palaeopathology literature. Rogers et al. (1987) proposed a scheme for classifying joint changes seen in human remains. This scheme cannot be transferred to bovids for two principal reasons. First, the authors stress the importance examining the skeleton in its entirety, a consummation devoutly to be wished, but seldom possible in zooarchaeology. Second, humans are bipeds, so the pattern of stress and strain seen in our musculoskeletal system is a poor *comparandum* for quadrupeds. Thus it is to the veterinary literature that we must turn, even though it may seem that the human palaeopathologists have already tilled the same ground.

Joint pathology generally attracts veterinary investigation when it has consequences in terms of productivity, either of meat or other resources, or in terms of reproductive success (Greenough et al. 1972; Singh et al. 2005). Thus Meimandi-Parizi and Shakeri (2007) present a useful radiographic survey of the distal

metapodials and phalanges in a series of 94 cattle that presented severe abnormalities of the digits when delivered to a single slaughterhouse. The economic consequence of the observed lameness is discussed, though these authors do make a point that there may be welfare considerations as well. This balancing of economic and welfare outcomes is a key issue in modern farming, and presumably would have been in the past, too. However, we have few grounds on which to base any assumptions about past attitudes to animal welfare, and should beware of projecting present-day sensitivities, or lack of them, into the past. Persson et al. (2007) specifically test the hypothesis that joint disorder may be a cause of infertility in beef sires, concluding that their data indicate a significant positive correlation. In this, they are following the more simply empirical observation of 18th and 19th century farmers, who regularly noted the occurrence of joint disease in the hind limbs of breeding cattle and sheep. Thus, much of the veterinary literature starts from an observed economic or welfare problem, and proceeds towards an investigation of joint disorders in samples that are already pre-selected as symptomatic. Our zooarchaeological investigation takes the reverse trajectory; it begins with observed disorders and seeks to infer economic or welfare implications, if any. The veterinary literature includes little research to indicate the prevalence of asymptomatic joint disorders (i.e. morphologically detectable, but not significantly affecting the animal), although Persson et al. (2007) note in passing that their control group of eleven fertile bulls almost all exhibited a mild degree of what they termed osteoarthritis.

Osteoarthritis (OA) is one of the most frequently diagnosed and familiar joint disorders in bovids, as it is in humans. Despite this familiarity, nomenclature, definition and differential diagnosis are all problematic. Baker and Brothwell (1981, 114-7) point out that the term has been used in zooarchaeological and veterinary literature to refer to almost any joint condition that results in exostoses. Instead, they propose four osteological criteria for diagnosis, which have become widely used in animal palaeopathology. These are:

- Grooving of the articular surface
 - Eburnation
 - Extension of the articular surface by new bone formation
 - Exostoses around the periphery of the bone
- (Baker and Brothwell 1981, 115)

These criteria raise a nomenclatural problem. Inflammation of the joint is not a pathognomic character, nor could it be readily diagnosed in a dry bone specimen. Accordingly, the widely-used term *osteoarthritis* is not appropriate, as the suffix implies an acute, inflammatory condition, whereas the diagnostic criteria could equally indicate a chronic, non-inflammatory condi-

tion, for which *osteoarthrosis* would be the more appropriate term. Dry bone features alone will not necessarily allow a clear differential diagnosis of these two conditions. Whilst acknowledging that problem, the term *osteoarthrosis* is preferable for the condition as it typically presents in zooarchaeological specimens because we can only rarely diagnose inflammation in the affected joint, and because we may often be seeing the end result of a chronic condition. The abbreviation OA, as used in this paper, should therefore be taken to indicate *osteoarthrosis* unless specified to the contrary.

Despite our attempts to propose diagnostic criteria for dry bone specimens, OA is not primarily a disorder of the bony skeleton. It is *primarily* a degenerative condition of the articular cartilage, chronic in duration and non-infective, and often *secondarily* accompanied by hypertrophy of bone (the new bone formation and exostoses to which Baker and Brothwell refer) (Greenough et al. 1972, 275-284). Current veterinary opinion regards OA as characterised by deviant development of chondrocytes in the articular cartilage, which enter a developmental stage at which they produce matrix-degrading enzymes, compromising the structural integrity, and hence weight-bearing capacity, of the cartilage (van der Kraan & van den Berg 2008). This process is blocked in animals of reproductive age, and so OA onset shows a strong correlation with age, leading Aigner et al. (2004) to dub OA 'Alzheimer's Disease of articular cartilage'. Note two things: OA has been recorded in a very wide range of mammals (though not in sloths), birds (Rothschild & Panza 2006) and reptiles, and its onset is age-related, not time-dependent. It is not necessarily the case that older animals develop OA, i.e. the risk increasing progressively with age, but that its development is no longer inhibited once the individual animal enters senescence, defined as the post-reproductive age typical of that species. Thus if we are to understand the significance of OA prevalence in ancient herds of cattle and caprines, we need to understand the likely reproductive histories of the populations under study.

The pathology of OA is well described in most veterinary textbooks: this account is based on Greenough et al. (1972). Patches of cartilage in the affected joint become dry, dull in lustre, and often granular. In part, this presumably reflects the differentiation and death of chondrocytes postulated by van der Kraan and van den Berg (2008), and in part it may reflect the covalent cross-linking of Type II collagen fibrils that also seems to typify the onset of OA (Bank et al. 1998). Under continued biomechanical loading, splits and fissures appear in the articular cartilage, leading to fibrillation and, often, to the separation of small cartilage 'mice' (*corpora libera*, not *corpora libra* as in Greenough et al. 1972, 276-7) that persist as mobile bodies within the joint

space. Where biomechanical stress is greatest, patches of cartilage are completely destroyed, exposing subchondral bone, which becomes smoothly polished (eburnated), sometimes with grooving that reflects the predominant axis of movement of the joint. By this stage, the geometry and function of the joint are seriously disordered, often leading to realignment, and hence to further extension of the damage. Improper joint movement leads to abnormal development of perichondral cartilage. Lacking the differentiation block typical of young cartilage, this perichondral cartilage progresses to endochondral ossification, forming the exostoses ('lipping') that are often taken to be typical of OA. As this account shows, lipping is a tertiary response to the realignment of the joint, itself a secondary consequence of the primary disorder of the articular cartilage. It may be helpful to zooarchaeological diagnosis to note that bone adjacent to the affected cartilages and to areas of eburnation is often highly reactive, with realignment of trabeculae in the cancellous bone of the affected joint to produce 'cystic' regions of reduced bone density (see Fig. 1, and discussion below).

The second major joint disorder to be considered here is osteochondrosis. Here again there are problems of definition and inconsistent terminology. The troubled and often ambiguous history of the term is discussed by Ytrehus et al. (2007), who take as their starting point the use of *osteochondritis dissecans* to describe a condition in which epiphyseal cartilage is predisposed to the formation of loose bodies without the contribution of primary arthritis or trauma (Nagura 1960). As with OA, the term *osteochondritis* implies the involvement of inflammation, which is not a pathognomic primary feature of the condition, so *osteochondrosis* (OC) is generally preferred. Essentially, OC is a focal disturbance of endochondral ossification. Like OA, it is primarily a condition of the cartilage, not of the bone, but unlike OA, it is predominantly a condition of the growing animal. OC is a particular problem in growing pigs, with some indications that the condition may be predisposed in certain breeds (Reiland 1975; Hill et al. 1984; Kadarmideen & Janss 2005; Jørgensen & Nielsen 2005). In sheep, the condition is less frequently recorded, though there is some evidence that rapid growth in lambs of large-bodied breeds may predispose the disorder (Thompson 2008). OC occurs in wild artiodactyls, in which it presents clinical changes similar to those seen in domestic mammals (e.g. Johnson et al. 2008), and has been noted in birds (e.g. Duff 1984).

OC passes through three stages, of which only the second and third are likely to be detectable in zooarchaeological material. In the earliest stage (*osteochondrosis latens*), a focal area of necrotic cartilage develops within the thickness of the growth (i.e. proliferative) cartilage, involving neither the overlying articular cartilage

nor the underlying subchondral bone. As growth proceeds, this necrotic cartilage fails to undergo endochondral ossification, leading to an isolated patch of cartilage becoming surrounded by newly-formed subchondral bone (*osteochondrosis manifesta* – OCM). Thus on the articular surface of an immature epiphysis, the condition could manifest as a small, non-erosive pit in the bone surface. Finally, the necrotic cartilage fissures, and the lesion extends through the overlying articular cartilage, producing a loose flap or body of detached articular cartilage (*osteochondrosis dissecans* – OCD) (Ytrehus et al. 2007).

The aetiology thus described poses certain challenges for zooarchaeology. First, the terms *osteochondrosis* and *osteochondritis dissecans* have been heavily used in the veterinary literature, not necessarily referring to conditions of the same aetiology. Hill et al. (1984) draw attention to the need to differentiate OC from other chondrodysplasias. Second, the human pathology literature has tended to define OC very broadly, then often giving eponymic labels to specific disorders (e.g. Osgood-Schlatter disease, Köhler disease), at least some of which could equally be defined and named as OC. Third, it is evident that the third stage of development of the disorder – OCD – cannot be satisfactorily distinguished from OCM without knowledge of the condition of the articular cartilage, which is highly unlikely to be the case with zooarchaeological material. What we may be able to diagnose is the subchondral bone malformation pathognomonic of OCM, without being able to say whether the disorder had advanced to OCD in this individual. It is formally proposed, therefore, that the term *osteochondrosis dissecans* should not be used in the animal palaeopathology literature, other than in the exceptional circumstances that this specific differential diagnosis can be made and fully justified. Instead, the term *osteochondrosis manifesta* (OCM) should be used, to refer to a non-erosive, non-infective pit indicative of a failure of endochondral ossification in subchondral bone. Particular care may be required to distinguish this condition from similar lesions of the articular surface resulting from an acute trauma. In the latter case, traces of a healing or remodelling reaction should be apparent, though possibly only on close inspection of the specimen.

Beyond OA and OCM, the two forms of arthropathy that most concern us are traumatic arthropathies and infectious arthropathies. Traumatic joint injuries can be subdivided into those of acute origin, such as luxations and periarticular fractures, and those of chronic aetiology, such as those induced by repeated abnormal loading of the joint. This category obviously overlaps to some degree with age-related OA, repeated loading of the joint acting to ‘age’ the joint at an abnormally rapid rate. We return to this point below.

Acute traumatic arthropathies are likely to have been the outcome of a single event, occurring a sufficient length of time before death for some degree of bone reaction and modification to have taken place. How long that reaction would take depends upon the age and health of the animal concerned, and on any soft-tissue injuries sustained at the same time as the fracture. There is remarkably little clinical literature on rates of healing response in cattle and caprines. However, extrapolating from veterinary accounts of recovery from treated limb fractures, it seems likely that any traumatic arthropathy showing sufficient bone response to enable confident differentiation from a peri- or post-mortem break is likely to have happened at least one week before death. As healing proceeds, the open-textured woven bone initially deposited as a response to injury will undergo reduction in extent and internal reorganisation into dense, often smooth-surfaced, bone. Such new bone may persist as evidence of an old trauma for months or years.

A useful example of an acute traumatic arthropathy that is well-known to the veterinary profession is fracture of the distal phalanx in cattle (e.g. Vaughan & Osman 1967; Greenough et al. 1972), a condition that may be particularly associated with soils and fodder high in fluorine. The immediate cause is generally a sudden percussive load, typically to the forelimb and on hard ground, and the medial digit is affected more often than the lateral digit. The distal phalanx fractures transversely, from the palmar surface to the articular surface, separating a postero-distal section from the majority of the phalanx. The action of the deep flexor tendon then typically opens the fracture by rotating the palmar and distal portions of the foot. Although the events that cause the trauma will be particular to the individual case, the tendency of the distal phalanx to fracture in a particular way conveys a high degree of equifinality to this particular pathology. The outcome is that the animal is lame, though not necessarily unable to stand at least for short periods of time. Whether the degree of lameness is regarded as significant will depend upon the animal’s continued ability to feed, which in turn will depend upon specific husbandry practices, and on the degree of handling and management required of the affected animal. Cattle with joint disorders, of whatever aetiology, are likely to be less tractable than normal, affecting both their husbandry and diagnosis of the condition: as Greenough et al. dryly observe of cattle with distal phalanx fractures “Percussion with a hammer or pressure by hoof pincers is usually resented...” (1972, 205). Untreated, distal phalanx fractures gradually resolve following several weeks of lameness, though the fracture line may be evident radiographically for a number of months, long after all lameness has ceased. Baker and Brothwell (1981, 111) illustrate two prehistoric cattle distal

phalanges with what could be taken to be well resolved traumatic fractures; a third specimen from the same site is discussed in detail below.

Luxations and subluxations are commonly reported in the veterinary literature, often in order to report successful reduction (i.e. re-articulation) and treatment of the affected joint (e.g. Khol & Licka 2007). In modern cattle and caprines, reduction of a luxated joint requires treatment with muscle relaxants and anaesthetics. It is highly unlikely that luxations in cattle could have been successfully reduced in antiquity and even sheep or goats may have presented a challenge. We have the problem, then, that the veterinary literature typically presents the consequences of successfully reduced luxations and successfully treated subluxations, whereas the zooarchaeological record is more likely to present the chronic outcomes of untreated traumas. If a severe subluxation results in tearing of the ligaments around the joint capsule, it is likely that some degree of abnormal ossification will develop at the sites of ligament insertion, extending along the ligaments to involve the joint capsule (Funakoshi et al. 2007). This is probably the aetiology of a condition often seen in the elbow joints of sheep, in which exostoses extend proximally from the radius and distally from the humerus, particularly on the lateral aspect, inhibiting joint movement (see Fig. 5, and discussion below).

Chronic traumatic arthropathies will be difficult to distinguish from OA, and the two categories certainly overlap to some degree. However, it is important to have a diagnostic category that allows differentiation of joint disorders deriving primarily from age-related degeneration, and those in which some specific, repeated process or activity has caused a particular constellation of clinical signs to develop. This is one topic on which there has been considerable zooarchaeological research, especially relating to the recognition of traction in ancient cattle, and abnormal loading of the spine in equids (Rossel et al. 2008).

The use of cattle as draught animals, pulling ploughs and hauling carts, is an obvious source of repeated abnormal joint stress, and it is unsurprising that this association of usage and pathology has attracted particular attention. That said, much of the literature is zooarchaeological rather than veterinary, simply because modern vets only exceptionally encounter draught cattle. Although draught animals are frequently mentioned *passim* by Baker and Brothwell (1981), the association of specific pathologies with that usage is not made. Armour-Chelu and Clutton-Brock (1985) make the association quite explicitly, relating pathologies of the scapula and eburnation attributable to OA in the acetabulum of Neolithic cattle to significantly early use of the cattle for draught purposes. Bartosiewicz et al.

(1993) drew attention to the biomechanical implications of metapodial asymmetry in draft cattle, suggesting that the abnormally heavy loading of the limbs increased the structural asymmetry between the 3rd (medial) and 4th (lateral) components of the fused metapodium. This investigation was based on a large sample of draught cattle acquired from slaughterhouses in Rumania and Hungary, specimen acquisition that is probably no longer possible, barely 20 years later. Because the animals were conventionally butchered, only the feet were available for study, though this limitation somewhat mimics the disarticulated nature of the zooarchaeological record. The same authors published a more detailed study of the cattle (Bartosiewicz et al. 1997), in which a number of stages of development of periarticular exostoses, expansion of articular surfaces and other characteristic traits are well illustrated and scored. De Cupere et al. (2000) subsequently applied the scoring protocol to an archaeological assemblage. Allometric studies show that it may be difficult to disentangle the direct consequences of husbandry from other factors affecting the loading of joints. Bartosiewicz et al. (1997) note that the medial trochlea of the distal metapodium increases in width with increasing body mass more rapidly than the lateral trochlea, raising the possibility that large body mass alone could induce joint asymmetries that would be mistaken for the consequences of abnormal biomechanical loading. This last point has been demonstrated by Johannsen (2005), who showed that in a sample of Neolithic cattle proximal phalanges, the most advanced stages of lip-ping, as defined on modern draught cattle by Bartosiewicz et al. (1997) were seen significantly more often in the morphologically larger specimens.

Infectious arthropathies (IA – also *infectious arthritis* or *septic arthritis*: *arthritis* is appropriate here because inflammation is a pathognomic feature), constitute a rather unsatisfactory group, as the pathognomic signs may have their origins in some direct infection of the joint itself (*primary infectious arthritis*), or in adjacent parts of the skeleton, such as the medullary cavity of the affected specimen (*secondary infectious arthritis*), or in tissues elsewhere in the animal, remote from the affected joint (*tertiary infectious arthritis*) (Greenough et al. 1972, 271-5). Given that palaeopathological diagnosis in zooarchaeology is typically based on isolated, disarticulated specimens, a diagnosis of tertiary IA will generally have to be inferred from the absence of evidence for primary or secondary IA. Differential diagnosis of primary or secondary IA will depend upon the degree of fragmentation of the specimen, and hence how far the ‘health’ of the rest of the affected element can be assessed. The causative organism may be viral, bacterial or fungal, leading to a range of systemic reactions. Swelling of the joint accompanied by elevated temperature is typical in the live animal, but of no diag-




Fig. 1: Cattle metatarsal, distal aspect, showing extension of articular surface, eburnation and grooving, and peripheral exostoses, consistent with osteoarthritis. York, medieval. Original photo: Dick Hunter

nostic value in palaeopathology. Only if the condition persists will there be skeletal modification (see Heppelman et al. 2008). Destruction of the articular cartilages and consequent narrowing of the joint space may lead to articular surface and periarticular changes that could mimic OA. If the condition advances further, subchondral bone destruction, periarticular bone hypertrophy and periostitis are likely to develop. In zooarchaeological specimens, therefore, we will see only those IA cases in which the immune system has responded inadequately yet without the infection proving lethal, either directly or by rendering the animal more likely to be slaughtered. Depending on the strength and direction of the immune response, primary IA may be associated with pyogenesis, leading to substantial periarticular modification in order to accommodate the pus bodies and to facilitate their drainage.

Case studies

The paper now reviews a number of examples of arthropathy in bovids, with the emphasis on description and differential diagnosis of the pathology. The examples are drawn from the author's own work, principally on medieval material from York, including some modern specimens where appropriate.

Osteoarthritis

As discussed and defined above, OA is a degenerative, age-related condition that begins as cartilage lesions. In many of the ancient populations of livestock represent-

ed in the zooarchaeological record, life expectancy (i.e. E_0 – expectation of life at birth) was appreciably greater than it is in modern herds and flocks raised primarily for meat. It is of little surprise, then, that we frequently see cases of osteoarthritis. Fig. 1 shows a quite typical case, annotated to pick out the pathognomic features. The lateral trochlea (to the left of the photograph) has extended abnormally, though the bone surface appears normal. The medial trochlea shows a large area of eburnation, within which antero-posterior grooves are apparent. The presence of these grooves implies that the metatarso-phalangeal joint was still mobile at time of death, despite the evident destruction of a substantial area of articular cartilage. Within the eburnated area, post-mortem damage has opened a number of cavities that are larger than would be expected in healthy cancellous bone immediately below the articular surface. Although exposure of the cavities is of taphonomic origin, the cavities themselves are probably an aspect of the osteoarthrotic condition, in which cystic lesions develop in the abnormally stressed cancellous bone below a region of cartilage destruction.

Two more typical cases of OA are seen in Fig. 2. In the proximal phalanx, OA has caused destruction of a small area of cartilage on the medial proximal facet, and eburnation is apparent. In the medial phalanx, OA is more advanced, and little trace remains of the 'normal' articular surface. Substantial cavities have opened in the articular surface, and exostoses have proliferated around the margin of the joint. The extent of exostosis development could be taken to indicate some inflammatory reaction to joint sepsis. However, there

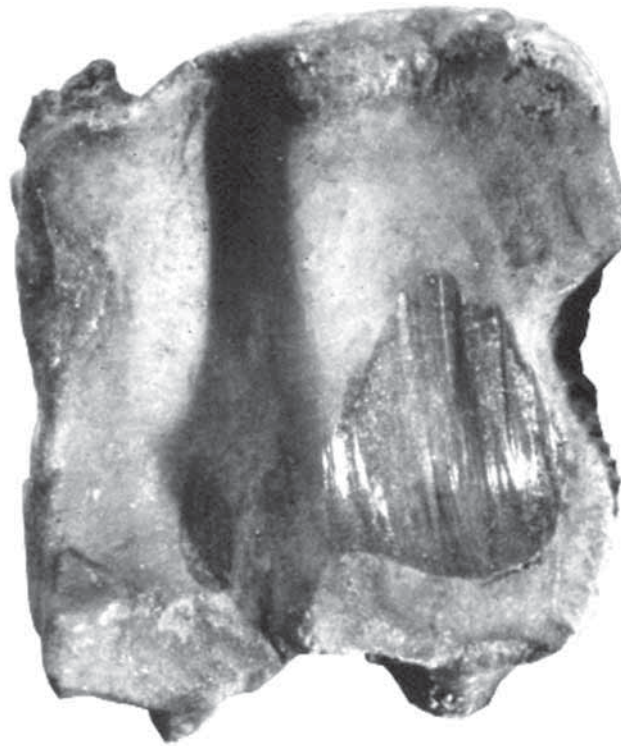


Fig. 2: Osteoarthritis in cattle proximal (above) and medial (below) phalanges. The medial phalanx shows greater destruction of the articular surface, with marked porosity where the bone surface has transected cystic lesions in the cancellous bone. York, medieval. Original photo: Dick Hunter




Fig. 3: Area of marked eburnation on the pubic face of a cattle acetabulum. Note the coarse porosity of the underlying cancellous bone exposed by eburnation. Danebury, Iron Age.

is no indication that pyogenesis was in progress, and no trace of draining sinuses. All of the clinical indications, albeit well advanced, are of OA with no further complications.

Fig. 3 shows a typical example of OA manifesting in a cattle *os innominatum*. There is a clearly-demarcated area of eburnation on the pubic face of the acetabulum, with exposure of coarsely-porous underlying bone. The acetabulum is unusually deep. Marginal exostosis development has extended the ilio-pubic region, such that the small notch that often marks the lateral end of the ilio-pubic suture has been retained as an elongated 'foramen' within the acetabular wall. Obviously, this modification of the acetabulum would compromise attempts to establish the sex of the animal on the basis of the acetabular morphology.

OA seems to be observed less frequently in caprine than in cattle remains, although this observation lacks rigorous quantified analysis. In Fig. 4, an advanced case of OA is illustrated, with strongly developed eburnation and grooving extending across all articular surfaces involved, though more marked on the medial, predominantly weight-bearing, aspects. The proliferation of marginal osteophytes may be an attempt to stabilise a joint that was becoming mechanically compromised. The eburnated areas have extended quite deeply into the normal articular surface. Coupled with the greatly reduced joint space, this must have considerably altered the joint geometry, putting abnormal strains on the ligaments of the joint capsule, hence the

particularly substantial osteophyte growth at the lateral margin.

Osteochondrosis

An association is made in the veterinary literature between the development of OCD in young animals and rapid growth to a high body weight, with the obvious implication that abnormal stress on the growing joint surface causes the patchy cartilage necrosis with which this condition begins. As such, OCD has been reported in young cattle, pigs, and even turkeys (Duff 1984), but we might expect it to be less frequently seen in zooarchaeological specimens that pre-date modern selective breeding for high growth rate and size. Fig. 5 shows a veterinary specimen diagnosed as OCD, with numerous shallow pits across the articular surface. Recognition of a comparable pathology in zooarchaeological material would require particularly good preservation of bone surfaces, as this form of diffuse pitting could all too easily be mimicked, or occluded, by taphonomic erosion of the bone surface.

Fig. 6 shows a cattle proximal phalanx in which two different arthropathies appear to be present. The marginal osteophytes, lateral extension of the articular surface and extensive eburnation are all consistent with OA. Anterior to the eburnation, and just overlapped by it, a shallow pit lies obliquely across the articular surface, measuring approximately 10 x 3mm. The position, profile, and finely-porous internal aspect of this lesion are all consistent with an osteochondrosis. As

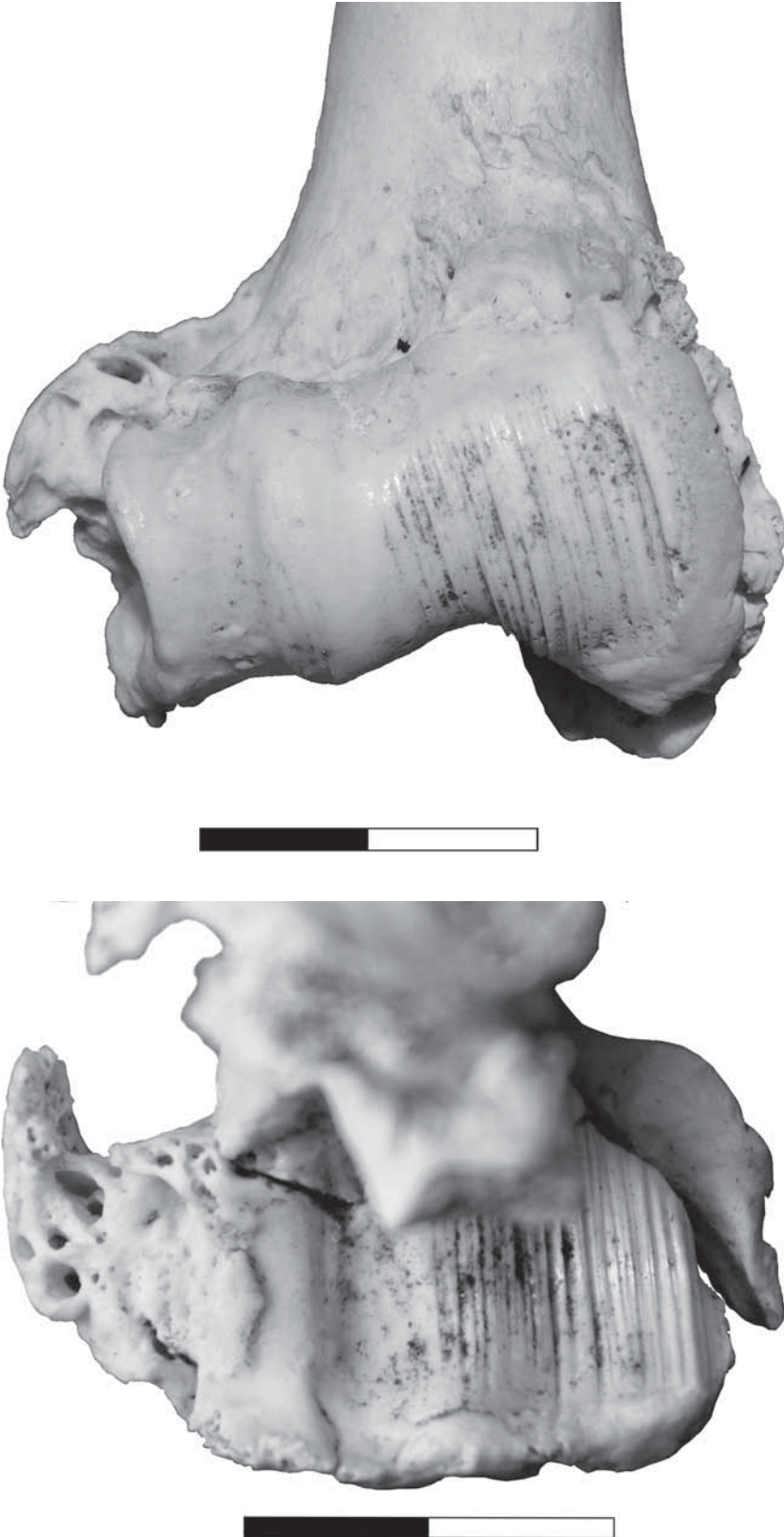


Fig. 4: Humerus distal articulation and radius proximal articulation of a modern sheep, showing advanced osteoarthritis. Both surfaces show well-developed eburnation, antero-posterior grooving, and a proliferation of marginal osteophytes. Modern, University of York collections.

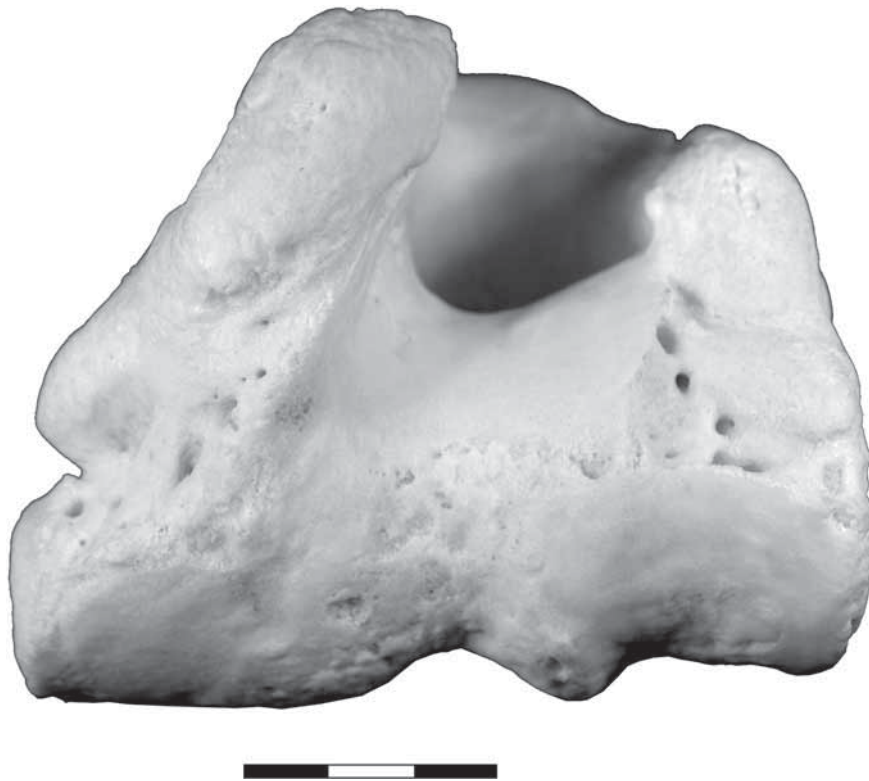


Fig. 5: Cattle humerus, distal aspect. There is irregular pitting and porosity across the articular surface, diagnosed in this veterinary specimen as osteochondrosis dissecans. Modern, University of York Baker Collection specimen 1088.



Fig. 6: Cattle proximal phalanx, proximal aspect. The most evident pathological condition is osteoarthritis, shown by marginal osteophytes, lateral extension of the articular surface, and an area of eburnation and grooving. Anterior to the eburnation, a lenticular pit may be an osteochondrosis of earlier formation.

argued above, even this substantial lesion should not be attributed to OCD without further evidence that the articular cartilage was cracked or detached. This spec-

imen thus manifests a pathology of the growing bone and another normally associated with an aged, senescent joint. If the osteochondrosis *had* developed to OCD, it is possible that the consequent cartilage damage predisposed the development of OA in this particular joint. However, it would be difficult to demonstrate any consistent association of OCD and OA in cattle phalanges in a zooarchaeological sample simply because the articular surface destruction typical of OA may have removed all trace of a pre-existing OCD lesion. The specimen in Fig. 6 may be relatively unusual in preserving evidence of both lesions.

Traumatic arthropathy

Fig. 7 shows a specimen scarcely recognisable as a cattle acetabulum and parts of the adjacent pelvic elements. The coxal joint was clearly not functional at time of death, and it appears that the femur no longer articulated with the acetabulum. The ischial rim of the acetabulum can be traced over most of its length, the iliac rim has been truncated by a 'chop' mark, and the pubic rim is scarcely discernible. It appears that the cranio-ventral part of the acetabular wall (i.e. the least robust part of it) has been traumatically disrupted, presumably by the femoral caput rupturing in a cranial direction. The remaining bone is dense and smooth-surfaced, indicating considerable resolution of the pathology after the initial trauma: that is, the animal lived

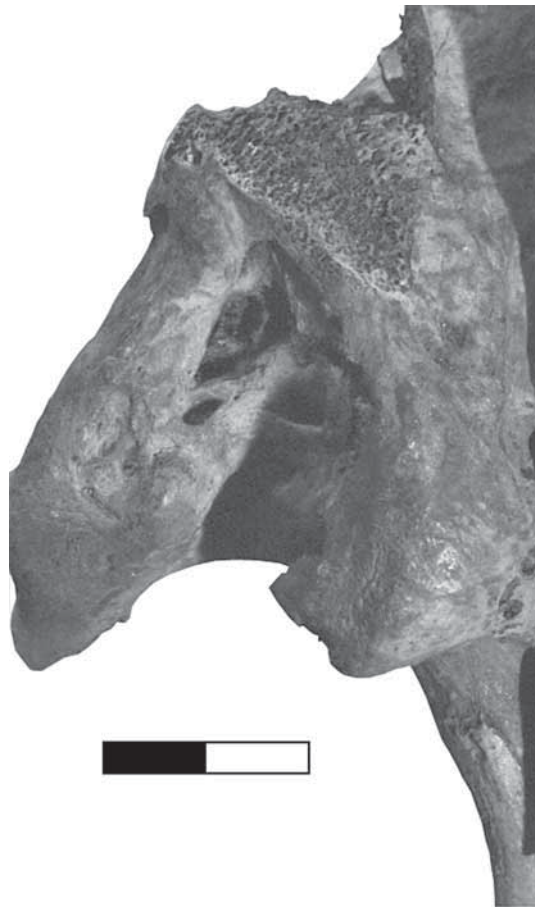

Fig. 7: Cattle acetabulum showing extensive destruction and remodelling, apparently as a result of trauma. The pattern of remodelling suggests that the femoral caput ruptured in a cranial direction, destroying much of the ilio-pubic margin of the acetabulum. Subsequent butchering has removed the ilium, making it impossible to ascertain whether a false joint developed. York, medieval. Original photo: Dick Hunter

for at least a number of months after whatever misadventure caused the damage. That inference is of some archaeological significance, as it indicates that a severely disabled beast was kept alive, furthermore in conditions that did not lead to secondary infection of the affected joint. Eventually, the animal died or was culled, and subsequent butchering of the carcass has prevented further diagnosis. Given the apparent direction of the traumatic disruption, it is possible that the femur and pelvis developed a 'false joint', somewhere on the medial or ventral aspects of the ilium. It is also likely that the contralateral limb would have developed abnormalities in response to the need to shift the foot of the functioning limb to a more medial position in order to support the great majority of the weight of the hindquarters of this unfortunate beast. Once again, we can only bemoan the scarcity of articulated skeletons in zooarchaeology!

Reference has already been made to the frequency with which subluxation occurs in the elbow joints of sheep.

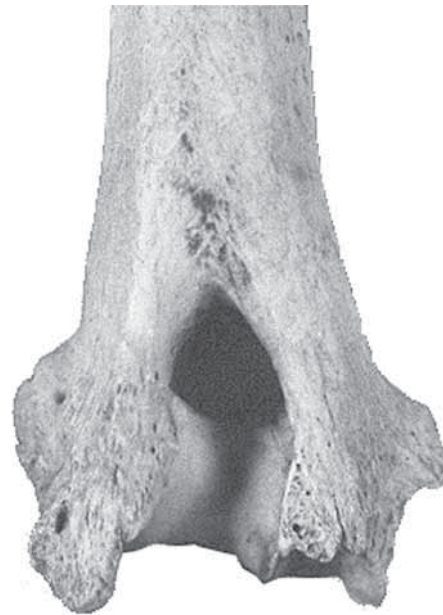

Fig. 8: Sheep humerus, posterior aspect, showing exostosis development consistent with traumatic subluxation. Note non-involvement of the articular surface. Modern, North Ronaldsay, University of York collection. Original photo: Jean Brown.

The skeletal consequences are seen in Fig. 8. The articular surface of the trochlea is quite normal, ruling out OA or OCM as a diagnosis. Small, dense exostoses have developed along the main axes and surfaces of the ligaments that constitute the joint capsule, most obviously on the lateral aspect, but also on the posteromedial tuberosity, where it has tended to 'bulge' medially, marginally intruding upon the olecranon fossa. There is no evidence of sepsis, and no indications of fracture or full luxation of the joint. The subluxation would probably have caused a period of lameness that resolved as the soft tissues healed, perhaps followed by some long-term loss of mobility in the joint as a consequence of the development of exostoses in the damaged tissues. The condition is quite common in the Orkney population from which this specimen was drawn, with maybe 10% of proximal radii and distal humeri showing clinical signs of a resolved subluxation (the percentage is approximate because mildly affected cases are difficult to discriminate from the normal range of morphological variation around the elbow joint). The condition is mentioned by Baker and Brothwell (1981, 127), who refer to vernacular association of the condition with trauma acquired when sheep are put through pens and races, i.e. when they are regularly moved through restricted spaces when tightly bunched. If that association of husbandry and pathology could be convincingly demonstrated, it would offer a useful indicator of ancient husbandry practice. However, the Orkney population is from the island of North Ronaldsay, where the sheep live on the foreshore in a more or less feral state. It is more probable that these sheep acquire injuries to

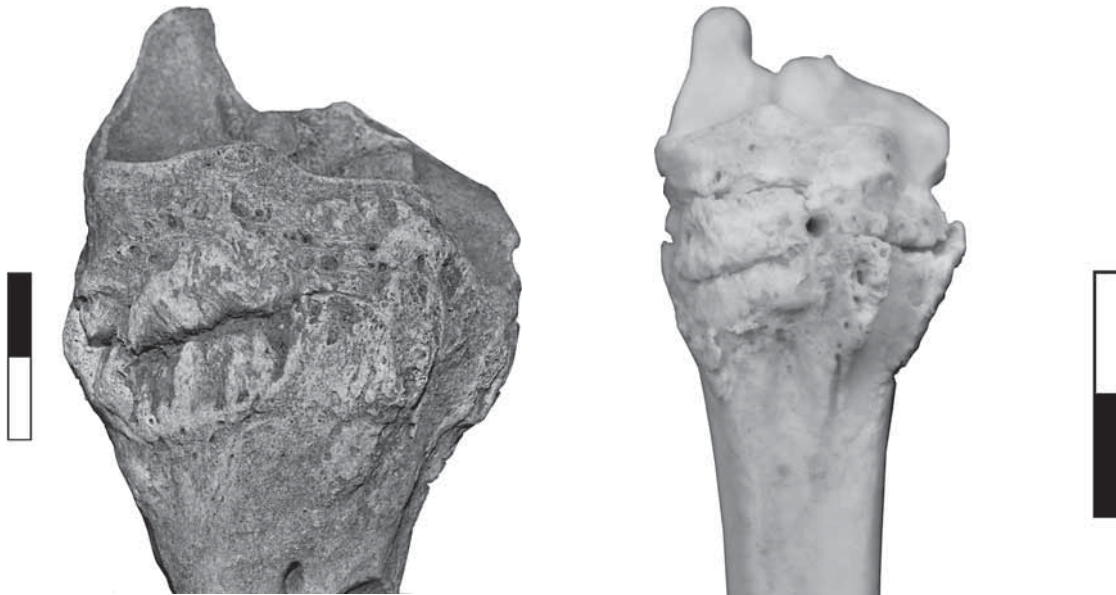


Fig. 9: Fusion of cattle tarsals and proximal metatarsal, anterior aspect. York, medieval.

the elbow joint through stumbling and falling when moving across a rocky foreshore covered in seaweed and wet with sea-spray or rain (usually both, in this author's experience).

A condition that is commonly encountered in the zooarchaeological record is a fusion of the tarsals and proximal metatarsal – the ankylosis that was amongst the first animal palaeopathologies to be systematically recorded in the zooarchaeology literature. This condition is seen quite frequently in cattle and horses, less often in caprines, and rather infrequently in other species. The condition is probably the same as that referred to in the English-language equine veterinary literature as *spavin*, and attributed to repeated abnormal loading of, or percussive shock to, the affected limb. Fig. 9 illustrates a typical bovine specimen. Fusion of the naviculocuboid (centrotarsale), cuneiform and metatarsal has occurred through the growth of 'bridging' osteophytes that extend around the joint capsule. The articular surfaces are not directly involved, though the positioning of the fused bones would seem to indicate an appreciably reduced joint space. Fig. 10 shows a similar specimen in a modern sheep, in which the joint surfaces can be seen with particular clarity. There seems to be no consistency in the sequence with which the three bones fuse. It is not uncommon to find specimens of metatarsal to which the cuneiform has become fused, or cases in which the naviculocuboid and cuneiform have fused, but the metatarsal is not involved (e.g. Fig. 11).

Based on examples of this pathology noted in the zooarchaeological literature, and the range of examples in the author's own experience, the condition appears to be chronic rather than acute. There is a progressive se-

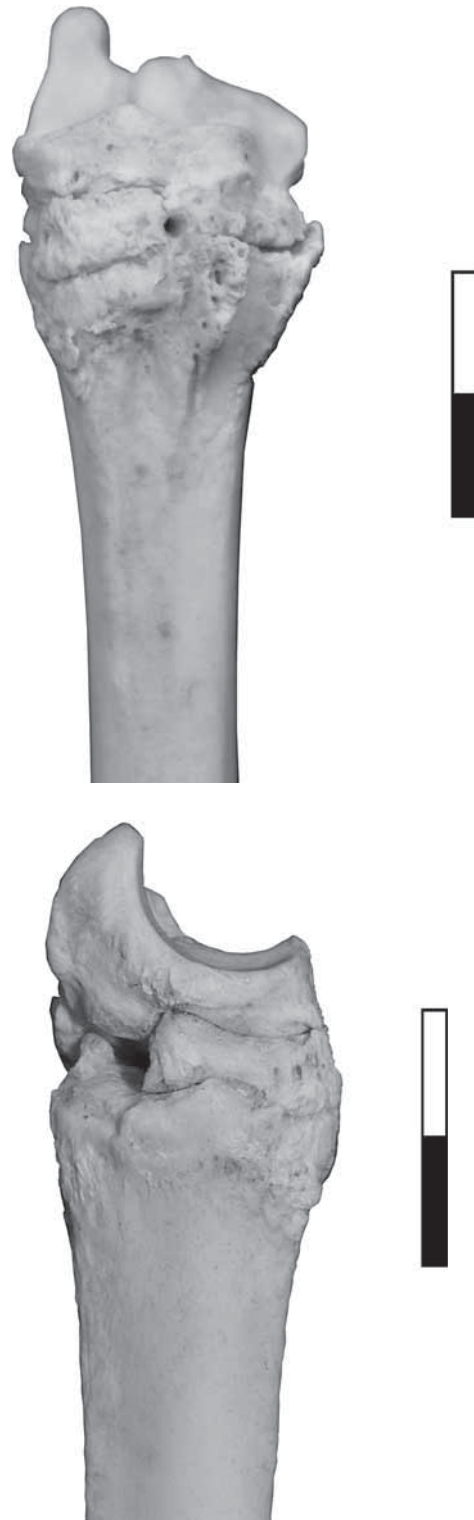

Fig. 10: Tarso-metatarsal fusion in a modern sheep, showing that the fusion has occurred by osteophytes 'bridging' the joint, not by direct involvement of the articular surfaces. Modern, University of York collections.

quence from minor osteophyte development with no fusion of adjacent bones through fusion of the three main bones involved, with increasing replacement of the soft tissues of the joint capsule by dense osteo-



Fig. 11: Fusion of cattle naviculocuboid and cuneiform by marginal osteophyte development. York, late medieval.

phytes. Although a specimen such as that in Fig. 9 could be diagnosed in isolation as an acute subluxation, the consistency with which the pathology occurs and its apparently chronic nature indicate that this is a degenerative pathology, perhaps related to joint senescence and chronic strain. If so, then there is another group of pathological specimens that should probably be included in this syndrome. In cattle, and less often caprines, metatarsal specimens are sometimes found to show a granular degeneration of the articular surface, always in association with marginal osteophytes. The articular degeneration is not associated with eburnation. However, this joint surface undergoes little articulation in life, acting as a shock-absorber, so the sliding abrasion associated with joint eburnation does not occur. The example in Fig. 12 shows the granular degeneration quite typically. Note that the cuneiform is fused in place on the metatarsal. The naviculocuboid appears not to have been fused, but the large 'chopping' cut-mark at the posterior margin shows that the joint was disarticulated during carcass butchering. It is possible that the metatarsal/cuneiform and naviculocuboid had undergone a degree of fusion but were separated during butchering. If we take the full range of these specimens into one pathological hypodigm, they represent a condition that develops progressively, perhaps initially by osteophyte development in response to repeated minor

trauma to the joint capsule, with subsequent necrotic degeneration of the articular surfaces in response to the loss of joint function. The condition is invariably sterile: I have never seen, and can find no reference to, a case in which these clinical signs are associated with evidence of inflammation and/or pyogenesis, nor a case in which an osteomyelitic condition was present. Furthermore, in complete specimens for which the distal articulation can be examined, it is usually unaffected. Thus we have a commonly-occurring degenerative arthropathy that is probably predisposed and initiated by chronic minor trauma to the affected limb.

Infectious arthropathy

Reliable diagnosis of IA relies on there being clear evidence of pyogenesis. Fig. 13 shows a cattle proximal phalanx from Viking Age York in which there is destruction of around 30% of the articular surface, a triangular area approximately 30 x 25 x 20mm. A vigorous development of reactive bone is apparent, both as osteophyte development around the affected joint, and in extensive remodelling of the cancellous bone immediately underlying the area of destruction. There is no associated eburnation or extension of the articular surface. Within the osteophytes developed along the anterior margin of the joint there is a substantial drain-



Fig. 12: Cattle proximal metatarsal showing granular degeneration of the articular surface and marginal osteophytes. York, medieval.

ing sinus that extends onto the anterior aspect of the epiphysis. An irregular interruption to the osteophytes on the posterior margin may represent another sinus. A diagnosis of infectious arthropathy can be made in this case. The absence of any evidence for osteomyelitis supports a diagnosis of primary IA. The location of the pathology is consistent with a penetrating wound to the foot, and the lesion appears to have been quite restricted in extent. Although the more proximal parts of the foot cannot be compared, the distal articulation of this phalanx is unaffected.

Problematic diagnosis

A more ambiguous case of arthropathy in the same region of the bovine foot is seen in Fig. 14. No eburnation is apparent on any of the articular surfaces involved, but exostoses have developed on the antero-medial aspects of both phalanges. The two digits diverge more than is normal, associated with some extension of the lateral part of the metatarsal articular surface and with extension of the surface on the posterior aspect. There is no evidence of sepsis or of traumatic fracture. At first sight, the author was inclined to accept this specimen

as a case of age-related joint degeneration. However, in the absence of the pathognomic features of OA, and given the abnormal alignment of the lateral digit, a diagnosis of traumatic subluxation of one or both digits is more supportable.

Terminal phalanx fracture has been described above as a pathology frequently reported in the modern veterinary literature. It is doubtful that this condition has been identified with certainty in zooarchaeological material. Cattle terminal phalanges with cracks or grooves running transversely across the articular surface are occasionally reported. Baker and Brothwell (1981, 111) illustrate two examples from the Neolithic site of Skara Brae, Orkney. The context of the illustrations is a discussion of developmental anomalies in cattle phalanges, manifested as a range of clefts and pits seen in the articular surfaces of proximal, medial and terminal phalanges, though the authors note the possibility that the illustrated specimens could equally be examples of healed fractures. The specimen illustrated here (Fig. 15) is not either of the specimens discussed by Baker and Brothwell, but derives from the same deposits at Skara Brae. In this specimen, the position of the trans-



Fig. 13: Cattle proximal phalanx, proximal aspect, showing substantial destruction of the articular surface and underlying cancellous bone, with active bone response. A draining sinus is present in the osteophyte formation on the anterior margin, consistent with an infectious arthropathy. York, Viking Age.

verse groove is consistent with the usual location of fractures in terminal phalanx fracture cases, but there is no evidence of a healing response at the 'fracture' margins, and the lateral and medial aspects of the specimen are anatomically normal, with no trace of a former fracture. In veterinary reports of terminal phalanx fracture, it is a common observation that the fracture is pulled apart by contraction of the affected foot, which would lead to some distortion of the anatomy of the phalanx even in a well-healed case. It is more likely, therefore, that the specimen in Fig. 15 shows a developmental anomaly of the terminal phalanx, in effect a linear osteochondrosis along which subchondral ossification has failed. If such features are not uncommon in modern cattle (and there is no literature on this topic), it is possible that the presence of such a linear anomaly would predispose the affected phalanx to fracture, hence the quite consistent position of terminal phalanx fractures in cattle. At present, this can only be speculation, but a more systematic study of anomalies and traumatic pathologies in cattle terminal phalanges could readily be undertaken and may shed light on the postulated relationship.

Conclusions

Arthropathies remain one of the most frequently encountered pathologies in the zooarchaeological record, and therefore they particularly invite an interpretation in terms of animal husbandry or welfare. As this paper has argued, the classification of arthropathies originally proposed by Baker and Brothwell (1981) still constitutes a useful starting point, not least because such a classification requires us to consider the presence and absence of pathognomic characters that would allow a confident differential diagnosis. A consensus diagnostic classification would also facilitate the investigation of prevalence, by allowing the direct comparison of data collected by different researchers. The scoring system proposed by Bartosiewicz *et al* (1997) serves just this purpose, but it is highly species- and element-specific, having been developed as part of the investigation of a particular husbandry practice and its pathological outcomes. That said, it is unlikely that a descriptive protocol, let alone diagnostic criteria, could be developed that would be applicable across a wide range of species. The physiological and anatomical differences between, for example, dogs, pigs, horses and goats are simply too

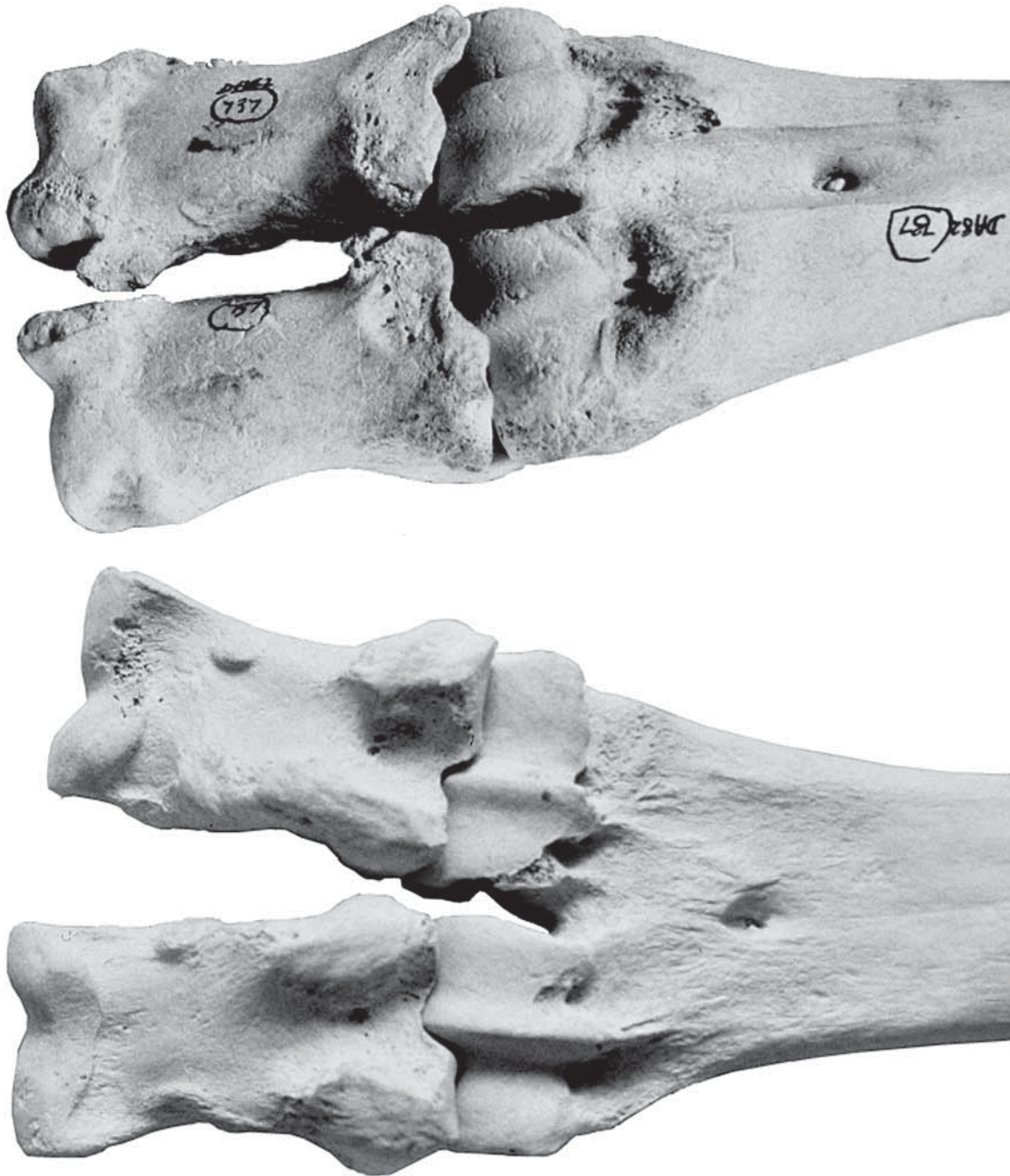

Fig. 14: Cattle metatarsal and proximal phalanges, anterior (a) and posterior (b) aspects. Note (above) the development of exostoses on the phalanges, (below) abnormal divergence of the medial and lateral phalanges, and the abnormal extension of the metatarsal articular surface. Danebury, Iron Age.

great. Cattle and caprines are a useful group on which to focus, as they have been central to pastoral economies across much of Eurasia for many millennia. Furthermore, samples of bison (*Bison* spp.) in North America, aurochs (*Bos primigenius*) in Europe and wild caprines (*Ovis*, *Capra* and *Ammotragus* spp.) in Europe, North Africa and South-West Asia offer free-living, anatomically similar comparanda with which to compare our results from husbanded herds and flocks. Johannsen's examples of 'traction' pathologies on aurochs foot bones illustrate this point rather well (Johannsen 2005).

Table 1 offers a provisional and probably over-simplistic scheme for the classification and differential diagnosis of arthropathies seen in bovid specimens of zooarchaeological origin. That objective is a tall order for a single table; Table 1 only sketches the outlines of a workable scheme. However, by including pathologies that will not be recognisable in dry bone specimens (e.g. OCL), the scheme aims to remind us not only of what we may hope to diagnose, but also what we may not diagnose but which could have afflicted the animals that we study.



Fig. 15: Cattle terminal phalanx, showing a transverse groove across the articular surface. Compare Baker & Brothwell (1981, 111). In this specimen, the anatomically normal medial aspect indicates that this is not a healed terminal phalanx fracture, but probably a developmental anomaly. Neolithic, Skara Brae, Orkney islands.

<p>OA Osteoarthritis</p> <p>Predominantly in aged individuals</p>		<p>Senescent degeneration of articular cartilage. Failure to block osteogenesis in periarticular cartilages. Joint biomechanically compromised</p>	<p>Patches of eburnation ± grooving, especially in areas of greatest load Periarticular osteophytes Extension of articular surfaces</p>
<p>OC Osteochondrosis</p> <p>Predominantly in growing individuals, though traces may persist in adults</p>	L <i>latens</i>	<p>Localised necrosis of growth cartilage. Articular cartilage and subchondral bone not involved</p>	<p>Unlikely to be detectable in dry bone specimens</p>
	M <i>manifesta</i>	<p>Irregular osteogenesis in growth cartilage leads to pits in subchondral bone surface, corresponding to necrotic cartilage in OCL</p>	<p>Pitting of articular surface; possibly detached flakes of bone surface</p>
	D <i>dissecans</i>	<p>Cracks in, and detachment of, articular cartilage, extending the lesion from subchondral bone to the joint space</p>	<p>Unlikely to be differentiated from OCM in dry bone specimens</p>
<p>IA Infectious arthropathy</p> <p>Not age-specific</p>	Primary	<p>Joint tissues are directly infected by micro-organisms</p>	<p>Vigorous bone lysis and proliferation Evidence of pyogenesis e.g. cavities, sinuses</p>
	Secondary	<p>Joint acquires infection from a primary site elsewhere in the same skeletal element</p>	<p>Joint as above; evidence of primary infection e.g. osteomyelitis elsewhere on specimen. Not differentiated on incomplete specimens</p>
	Tertiary	<p>Joint acquires infection from a primary site elsewhere in the body</p>	<p>Joint as above; only differentiated on articulated whole- or part-skeletons</p>
<p>Traumatic arthropathy</p> <p>Not age specific, though healed traumas are more likely in older individuals</p>	Acute	<p>Major change of joint morphology attributable to a single event e.g. luxation, fracture. Progressive bone reaction exclusively ‘healing’</p>	<p>Single, simple fracture or other morphological alteration to the joint. Reactive new bone typically callus at fracture or remodeling to accommodate new joint geometry</p>
	Chronic	<p>Joint morphology shows sequential changes, with bone reaction to repeated trauma as well as healing/resolution</p>	<p>Sequence of formation of e.g. osteophytes, progressive ankylosis. Articular surface degeneration that is not typical OA or IA (though may show elements of both/either)</p>

Table 1: Provisional scheme for classification and differential diagnosis of arthropathies in bovid bones.

The key to any such consensus classification is that it can be used in isolation by different researchers with confidence. One means of enhancing that confidence may be to apply the hypodigm concept: i.e. the publication and detailed description of a number of specimens that serve as defining examples for a particular category of arthropathic pathology. This has obvious overtones of biological systematics, and colleagues familiar with that particular can of worms may have their reservations! However, it is not necessary that we define 'holotype' specimens of, for example, secondary IA in the goat tibia, only that some accessible published and regularly updated source can be consulted that provides clear illustrations and detailed descriptions of a number of specimens that are generally accepted as good examples of a particular pathology. The APWG or Bone Commons websites would be appropriate hosts for such a source. The danger with such collective efforts is the obvious temptation to contribute the exceptional, eye-catching or incomprehensible examples, rather than very good examples of the routine. In selecting specimens to illustrate this paper, the aim has been to depict the typical rather than the spectacular.

Arthropathies have the attraction that they can be understood both physiologically and biomechanically, and it is through combining those two approaches that we can most readily understand the pathological traces that survive in the zooarchaeological record. However, despite the normative simplicity of Table 1 and much that has been written in this paper, we should never lose sight of the fact that different individual animals will have reacted in different ways and to different extents in response to the same acute or chronic insult. Each of the animals whose remains we study was unique, and each of them lived in particular conditions of nutrition, husbandry, hygiene, reproductive outcomes and so on. The pathologies that they manifest offer us a valuable insight into their lives, but we must always remember that we are examining the reaction of *this* cow to *that* event or process, and not over-interpret minor individual variations.

Acknowledgements

I am grateful to Don Brothwell, Simon McGrory, Sonia O'Connor and Joris Peters for their comments on earlier drafts of this paper. Some of the photographs used here were taken by Dick Hunter (formerly University of York) and Jean Brown (formerly University of Bradford): I thank them both. Unless otherwise attributed, all other photographs are by the author.

Bibliography

- Aigner T., Rose J., Martin J. & Buckwalter J., 2004. Ageing theories of primary osteoarthritis: from epidemiology to molecular biology. *Rejuvenation Research* 7: 134-145.
- Armour-Chelu M. & Clutton-Brock J., 1985. Notes on the evidence for the use of cattle as draught animals at Etton. In: Pryor F. French C. & Taylor M. (eds). An interim report on excavations at Etton, Maxey, Cambridgeshire, 1982-1984. *Antiquaries Journal* 65: 297-302.
- Baker J.R. & Brothwell D.R. 1981. *Animal diseases in archaeology*. London: Academic Press.
- Bank R.A., Bayliss M.T., Lafeber F.P., Maroudas A. & TeKoppele J.M., 1998. Ageing and zonal variation in normal human articular cartilage. The age-related increase in non-enzymatic glycation affects biomechanical properties of cartilage. *Biochemical Journal* 330: 345-351.
- Bartosiewicz L., 2008. Taphonomy and palaeopathology in archaeozoology. *Geobios* 41: 69-77.
- Bartosiewicz L., Van Neer W. & Lentacker A., 1993. Metapodial asymmetry in draft cattle. *International Journal of Osteoarchaeology* 3: 69-75.
- Bartosiewicz L., Van Neer W. & Lentacker A., 1997. *Draught cattle: their osteological identification and history*. Tervuren: Koninklijk Museum voor Midden-Afrika, Annalen Zoölogische Wetenschappen 281.
- Brothwell D.R., 1969. The palaeopathology of Pleistocene and more recent mammals. In: Brothwell D. & Higgs E. (eds). *Science in Archaeology*: 310-314. London: Thames and Hudson.
- Brothwell D.R. 1995. The special animal pathology. In: Cunliffe B. (ed.). *Danebury: an Iron Age hillfort in Hampshire, vol 6. A hillfort community in perspective*: 207-233. York, Council for British Archaeology Research Reports 102.
- Brothwell D.R., Dobney K.M. & Ervynck A., 1996. On the causes of perforations in archaeological domestic cattle skulls. *International Journal of Osteoarchaeology* 6: 471-487.
- Clark K.M., 1994. *Palaeopathology in archaeological faunal remains. A new approach*. Unpublished PhD thesis, Department of Archaeology, University of Southampton.
- Davies J.J. 2005. Oral pathology, nutritional deficiencies and mineral depletion in domesticates – a literature review. In: Davies J., Fabiš M., Mainland I., Richards M. & Thomas R. (eds). *Diet and health in past animal populations. Current research and future directions*: 80-88. Proceedings of the 9th conference of the ICAZ, Durham, August 2002. Oxford: Oxbow Books.
- Davies J., Fabiš M., Mainland I., Richards M. & Thomas R. (eds), 2005. *Diet and health in past animal populations. Current research and future directions*. Proceedings of the 9th conference of the ICAZ, Durham, August 2002. Oxford: Oxbow Books.

- De Cupere B., Lentacker A., Van Neer W., Waelkens M. & Verslype L., 2000.
Osteological evidence for the draught exploitation of cattle: first applications of a new methodology. *International Journal of Osteoarchaeology* **10**: 254-267.
- Dequeker J. & Luyten F.P., 2008.
The history of osteoarthritis-osteoarthritis. *Annals of Rheumatic Disease* **67**: 5-10. DOI: 10.1136/ard.2007.079764.
- von den Driesch A., 1975.
Die Bewertung pathologisch-anatomischer Veränderungen an vor- und frühgeschichtlichen Tierknochen. In: Clason A.T. (ed). *Archaeozoological Studies*: 413-425. Amsterdam: Elsevier.
- Duff S.R.I., 1984.
Osteochondritis dissecans in turkey. *Journal of Comparative Pathology* **94**: 467-496.
- Feddersen D. & Heinrich D., 1978.
Anomalien und Pathologien an Haustierknochen aus einer frühmittelalterlichen Siedlung und deren Bewertung im Hinblick auf die Tierhaltung. *Zeitschrift für Tierzüchtung und Züchtungsbiologie* **94**: 161-170.
- Funakoshi Y, Hariu M., Tapper J.E., Marchuk L.L., Shrive N.G., Kanaya F., Rattner J.B., Hart D.A. & Frank C.B., 2007.
Periarticular ligament changes following ACL/MCL transection in an ovine stifle joint model of osteoarthritis. *Journal of Orthopaedic Research* **25**: 997-1006.
- Greenough P.R., MacCallum F.J. & Weaver A.D., 1972.
Lameness in cattle. Edinburgh: Oliver & Boyd.
- Harcourt R.A., 1967.
Osteoarthritis in a Romano-British dog. *Journal of Small Animal Practice* **8**: 521-522.
- Harcourt R.A., 1971.
The palaeopathology of animal skeletal remains. *The Veterinary Record* **89**: 267-272.
- Heppelmann M., Rehage J., Kofler J. & Starke A., 2008.
Ultrasonographic diagnosis of septic arthritis of the distal interphalangeal joint in cattle. *The Veterinary Journal* (in proof) doi:10.1016/j.tvjl.2007.10.017.
- Higham C.F.W., Kijngam A., Manly B.F.J. & Moore S.J.E., 1981.
The bovid third phalanx and prehistoric ploughing. *Journal of Archaeological Science* **8**: 353-365.
- Hill M.A., Ruth G.R., Hilley H.D. & Hangsen D.C., 1984.
Dyschondroplasias, including osteochondrosis, in boars between 25 and 169 days of age: histologic changes. *American Journal of Veterinary Research* **45**: 903-916.
- Johannsen N.N., 2005.
Palaeopathology and Neolithic cattle traction: methodological issues and archaeological perspectives. In: Davies J., Fabiš M., Mainland I., Richards M. & Thomas R. (eds). *Diet and health in past animal populations. Current research and future directions*: 39-51. Proceedings of the 9th conference of the ICAZ, Durham, August 2002. Oxford: Oxbow Books.
- Johnson S., Houser B.S., Frederick H. & Patterson B., 2008.
Osteochondrosis dissecans in a juvenile Roan Antelope (*Hippotragus equinus*). *Journal of Zoo and Wildlife Medicine* **39**: 111-114. DOI: 10.1638/2006-0053.1
- Jørgensen B. & Nielsen B., 2005.
Genetic parameters for osteochondrosis traits in elbow joints of crossbred pigs and relationships with production traits. *Animal Science* **81**: 319-324.
- Kadarmideen H.N. & Janss L.L.G., 2005.
Evidence of a major gene from Bayesian segregation analyses of liability to osteochondral diseases in pigs. *Genetics* **171**: 1195-1206.
- Khol J.L. & Licka T.F., 2007.
Closed reduction of coxofemoral luxation in a goat: case report. *Acta Veterinaria Hungarica* **55**: 301-308.
- van der Kraan P.M. & van den Berg W., 2008.
Osteoarthritis in the context of ageing and evolution. Loss of chondrocyte differentiation block during ageing. *Ageing research Reviews* **7**: 106-113. DOI: 10.1016/j.arr.2007.10.001
- Lignereux Y. & Peters J., 1999.
Elements for the retrospective diagnosis of tuberculosis on animal bones from archaeological sites. In: Pálfi G., Dutour O., Deák J. & Hutás I. (eds). *Tuberculosis past and present*: 339-348. Golden Book Publisher Ltd., Tuberculosis Foundation.
- Mackenzie A.R. & Dawson J., 2005.
Could rheumatoid arthritis have an infectious aetiology? *Drug Discovery Today: Disease Mechanisms* **2**: 345-349.
- Meimandi-Parizi A. & Shakeri M.A., 2007.
Abattoir study of radiographic changes of bones and joints of digital region in cattle with abnormal claws. *Veterinarski Arhiv* **77**: 187-194.
- Nagura S., 1960.
The so-called osteochondritis dissecans of König. *Clinical Orthopedics* **18**: 100-121.
- Nieberle K. & Cohrs P., 1970.
Lehrbuch der speziellen pathologischen Anatomie der Haustiere (3. Aufl.). Jena: Gustav Fischer.
- Persson Y., Söderquist L. & Ekman S., 2007.
Joint disorder; a contributory cause to reproductive failure in beef bulls? *Acta Veterinaria Scandinavica* **49**: 31. DOI: 10.1186/1751-0147-49-31
- Reiland S., 1975.
Osteochondrosis in the pig. PhD Thesis, Royal Veterinary College, Stockholm.
- Rogers J. & Waldron T., 1995.
A field guide to joint disease in archaeology. Chichester: John Wiley & Sons.
- Rogers J., Waldron T., Dieppe P. & Watt I., 1987.
Arthropathies in palaeopathology: the basis of classification according to Most Probable Cause. *Journal of Archaeological Science* **14**: 179-193.
- Rossel S., Marshall F., Peters J., Pilgram T., Adams M.D. & O'Connor D., 2008.
Domestication of the donkey: timing, processes and indicators. *Proceedings of the National Academy of Sciences* **105**: 3715-3720.
- Rothschild B.M. & Panza R., 2006.
Osteoarthritis is for the birds. *Clinical Rheumatology* **25**: 645-647.

- Shaffer B.S. & Baker B.W., 1997.
Historic and prehistoric animal pathologies from North America. *Anthropozoologica* **25/26**: 255-261.
- Siegel J., 1976.
Animal palaeopathology: possibilities and problems. *Journal of Archaeological Science* **3**: 349-384.
- Singh G.R., Amarpal, Aithal H.P. & Kinjavdekar P., 2005.
Lameness in cattle – a review. *Indian Journal of Animal Sciences* **75**: 723-740.
- Thompson K.G., 2008.
Skeletal diseases of sheep. *Small Ruminant Research* **76**: 112-119. DOI: 10.1016/j.smallrumres.2007.12.024
- Van Wijngaarden-Bakker L. & Krauwer M., 1979.
Animal Palaeopathology. Some examples from the Netherlands. *Helinium* **19**: 37-53.
- Vann S. & Thomas R., 2006.
Humans, other animals and disease: a comparative approach towards the development of a standardised recording protocol for animal palaeopathology. *Internet Archaeology* **20** (http://intarch.ac.uk/journal/issue20/vannthomas_index.html).
- Vaughan L.C. & Osman M.A., 1967.
Fracture of the third phalanx in cattle. *Veterinary Record* **80**: 537-543.
- Ytrehus B., Carlson C.S. & Ekman S., 2007.
Etiology and pathogenesis of osteochondrosis. *Veterinary Pathology* **44**: 429-448.