



This is a repository copy of *Orthodontic palatal implants: clinical technique*.

White Rose Research Online URL for this paper:  
<http://eprints.whiterose.ac.uk/388/>

---

**Article:**

Tinsley, D., O'Dwyer, J.J., Benson, P.E. et al. (2 more authors) (2004) Orthodontic palatal implants: clinical technique. *Journal of Orthodontics*, 31 (1). pp. 3-8. ISSN 1465-3125

<https://doi.org/10.1179/146531204225011472>

---

**Reuse**

Unless indicated otherwise, fulltext items are protected by copyright with all rights reserved. The copyright exception in section 29 of the Copyright, Designs and Patents Act 1988 allows the making of a single copy solely for the purpose of non-commercial research or private study within the limits of fair dealing. The publisher or other rights-holder may allow further reproduction and re-use of this version - refer to the White Rose Research Online record for this item. Where records identify the publisher as the copyright holder, users can verify any specific terms of use on the publisher's website.

**Takedown**

If you consider content in White Rose Research Online to be in breach of UK law, please notify us by emailing [eprints@whiterose.ac.uk](mailto:eprints@whiterose.ac.uk) including the URL of the record and the reason for the withdrawal request.



[eprints@whiterose.ac.uk](mailto:eprints@whiterose.ac.uk)  
<https://eprints.whiterose.ac.uk/>

CLINICAL  
SECTIONOrthodontic palatal implants:  
clinical technique

D. Tinsley\*, J. J. O'Dwyer\*, P. E. Benson†, P. T. Doyle\* and J. Sandler\*

\*Chesterfield Royal Hospital, Calow, and †University of Sheffield, UK

*The aim of this paper is to familiarize the readers with some of the clinical considerations necessary to ensure successful use of mid-palatal implants. Both surgical and technical aspects will be discussed along with a description of impression techniques used.*

**Key words:** Mid-palatal implants, endosseous implants, supplementing anchorage

Received 20th January 2003; accepted 9th October 2003

## Introduction

Control of anchorage is fundamental if orthodontics is to be a success and treatment goals realized. Many patients require anchorage supplementation with extra-oral devices such as headgear. There are, however, recognized complications of wearing this type of appliance. Samuels<sup>1</sup> surveyed 1117 dentists in the UK, regarding the headgear use in their clinical practice and injuries sustained by their patients. Thirty-three injuries to the face and surrounding areas were reported. Three of these involved ocular damage, with one patient losing the sight in one eye.<sup>2</sup> In a further study,<sup>3</sup> there were 17 substantiated reports of ocular damage worldwide. Recently, locking facebows have become available, which are much safer;<sup>4</sup> however, when headgear injury does happen the results can be catastrophic.

A further problem of using headgear is patient compliance. Studies using headgear timers have shown that patients wear their headgear for less than half the time that is actually prescribed by the clinician.<sup>5,6</sup>

One method of overcoming the problems and complications associated with headgear is to utilize the principle of osseointegration to gain a stationary intra-oral anchorage site. An implant, unlike a natural tooth does not move when a force is applied and, therefore, can be used to reinforce anchorage. Endosseous dental implants used to restore the edentulous space are a reliable and safe treatment option.<sup>7</sup> Studies show high success rates even after 15 years of follow-up.<sup>8</sup>

The implant system described in this article is the Straumann Ortho Implant<sup>®</sup>. This is a one-piece titanium implant specifically designed for use in the mid-palatal region to reinforce anchorage in orthodontics and was first described by Wehrbein.<sup>9</sup> To utilize this anchorage,

the mid-palatal implant is connected to the anchor teeth via a transpalatal arch. The design of the transpalatal arch and the method of attachment to the anchor teeth are central to the success of the technique. The attachment must be reliable to prevent unwanted loss of anchorage. It should also be relatively simple and inexpensive to construct.

This article outlines a reliable method for predictable surgical positioning of the Straumann palatal implant and discusses various techniques for connection of the implant to the teeth requiring anchorage reinforcement.

## Surgical technique

Twenty patients with a mean age of 16.6 years and a range of 12–39 years had implants placed. Fourteen were female and 6 were male. All had orthodontic records taken including intra- and extra-oral photos, study models and appropriate radiographs.

## Radiographic stent

For each of these patients, the laboratory constructed a radiographic stent (Figure 1). The stent contained two metal tubes the same diameter and length as the implant (length 6 mm, diameter 3.3 mm), positioned within an acrylic base plate. Using tubes the same size as the implant means any magnification of the X-ray can be accounted for. To identify the optimum implant position, the metal markers should be placed in the region between the premolars and angled approximately perpendicular to the curve of the palate, aimed towards the anterior nasal spine. The stent can then be fitted to the patient

(Figure 2) and a lateral cephalogram taken, the markers acting as a reference point in the sagittal plane (Figure 3).

The radiograph allows accurate assessment of bone depth, shows the position of the floor of the nose and, when combined with clinical information, helps assess the probable location of the apices of the incisors teeth. The optimal position and length of the implant can now be determined with accuracy.

The implants are available in two lengths (4 mm and 6 mm) and, in this example, the longer one was selected, positioned between the 2 markers and angulated towards the anterior nasal spine.

### *Surgical stent*

The radiographic stent is now converted into a surgical stent to be used at the time of surgery. This modification is achieved by removing the markers and preparing a 6 mm hole in the thinned base plate, through which the implant preparation drills can be used (Figure 4). As a guide to the orientation of the implant, a 10 mm section of 0.7 mm stainless steel wire is embedded into the acrylic at the appropriate angle to indicate to the surgeon how the drill must be held (Figure 5).

The surgeon now has the ideal position and angulation for the implant predetermined, and can therefore prepare the implant site avoiding vital structures and using the optimal depth of available bone.

### *Pre-surgical preparation*

One hour prior to surgery all patients have appropriate prophylactic antibiotics (3 g Amoxycillin) and a 0.2% chlorhexidine gluconate mouthwash. The surgery is completed under local anesthesia, using aseptic techniques. To gain access to the bone a mucosal trephine placed into a slow speed surgical hand piece is used (Figure 6). The circular 'tag' of palatal soft tissue is 'coned' using the mucosal trephine then is removed with a hand instrument, such as an excavator. Once the mucosal 'tag' is removed, a round steel rose-head bur allows access to the softer cancellous bone of the palate. Throughout the surgery, the hand piece is regulated to run at no more than 700 rpm. Copious amounts of saline are used as a coolant and sprayed directly at the rotating bur using a syringe. This ensures that the bone does not overheat during preparation of the implant site, which would result in tissue necrosis and lack of integration. A 'profile' drill is used to prepare the site (Figure 7). The cutting part is available in two lengths (4 or 6 mm) depending on the size of the implants to be used. The length of the shank is also variable and selection depends upon the shape of the palate (Figure 8). The longer shank allows easier access in a high vaulted palate. Care must be taken during the preparation to ensure the bur is moved into and out of the

bone only once, and in one direction. If the preparation is not parallel sided, it is impossible to achieve primary stability. Once the implant site is prepared, it is checked with a periodontal probe to ensure it is of adequate depth and that no perforation of the nasal cavity has occurred.

### *Implant placement*

The implants are also manufactured with 2 different neck lengths. The neck of the implant is the highly polished section of the implant that passes through the mucosa. The mucosa thickness can be measured with a probe, and the corresponding implant selected from a choice of 2.5 or 4.5 mm neck length.

All of the implants are stored in sterile ampoules, which should not be opened until the implant is ready to be inserted. The implant is placed initially with a finger held instrument called the 'ortho inserting device' then tightened with a ratchet until seated. It is important not to touch the implant before placement to avoid bacterial contamination of its sterile surface.

Once inserted the implant is assessed for stability. If any lateral movement is detected under digital pressure, possibly as a result of an oversized hole, a wider 4 mm 'emergency' implant is available. In four cases in this study, this implant was inserted in preference to the standard implant. All cases had primary stability following placement. The healing cap was then placed and a radiograph was taken at this point (Figure 9) to confirm the final implant position.

### *Post-surgical instructions*

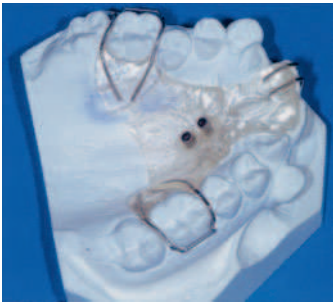After surgery a chlorhexidine mouthwash is prescribed for daily use. In addition, patients were instructed to clean their implants initially with a cotton wool bud, while the gingivae was tender, followed by the use of a small headed toothbrush as soon as the patients were able. Patients are asked not to allow the tongue to 'play with' or push the implants, particularly over the first few weeks following placement. Analgesics are prescribed post-operatively, with specific instructions on their use if required.

The implants are left unloaded for 3 months to allow integration. At the end of this period, and prior to construction of the palatal arch, the implants are reviewed clinically and checked for stability.

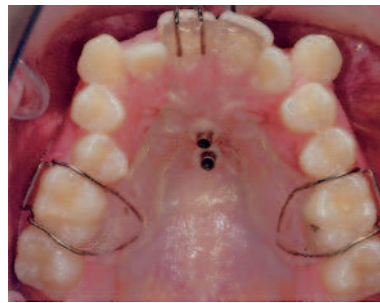## **Implant connection: technical aspects**

### *Bonded and banded palatal arches*

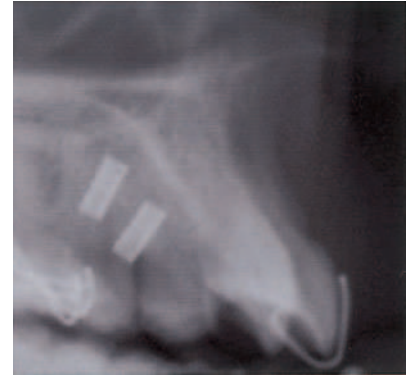To utilize the anchorage offered by the implant, it is necessary to connect it to the anchor teeth with a suitable



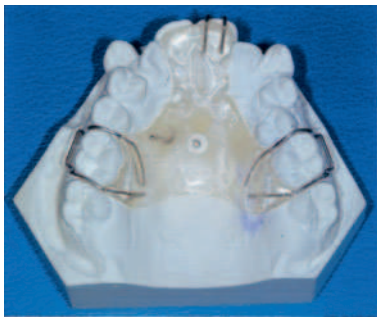**Figure 1** Radiographic stent on working model



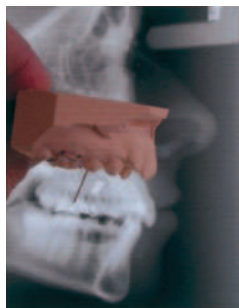**Figure 2** The stent in position in the mouth



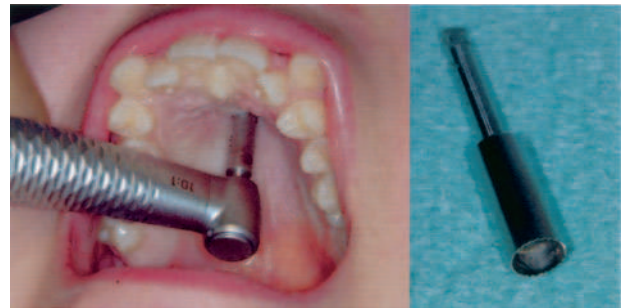**Figure 3** Resultant lateral cephalograms with the stent in position



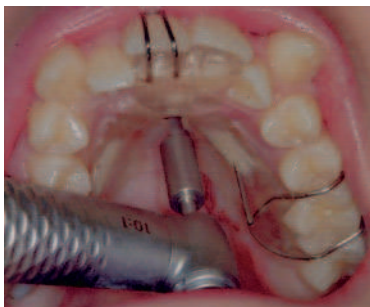
**Figure 4** Conversion of radiographic stent to surgical stent




**Figure 5** Orientation guide of the surgical stent



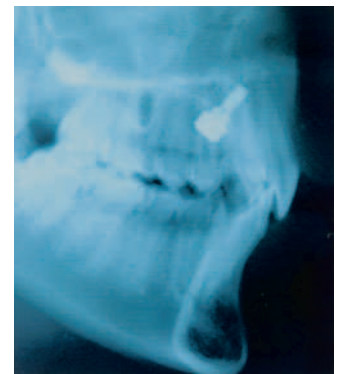
**Figure 6** The mucosal trephine bur



**Figure 7** The implant site being prepared



**Figure 8** 'Profile' drills (6 mm): 3 different shank sizes



**Figure 9** Radiograph of final implant with healing cap

palatal arch. Three types of palatal arch have been described in the literature. Palatal arches bonded to the lingual aspect of the anchor teeth were reported by Wehrbein<sup>10</sup> and Celenza,<sup>11</sup> and are recommended by Straumann. In some of our cases, offset premolar brackets were used on the arch to bond to the palatal aspect of the anchor tooth (Figure 10), usually a premolar. These arches proved easy to construct and place, but had several disadvantages:

- The debond rate was extremely high and anchorage was subsequently lost (Figure 11). During mastication

teeth move within their periodontal ligament, which is not the case with implants, as they are rigidly fixed to the bone. This differential movement of the anchor teeth relative to the implants may well have contributed to the failures encountered.

- Major rotations on the anchor teeth had to be accepted initially. Correction only becomes possible once anchorage reinforcement is no longer necessary.

The use of palatal arches connected to bands on the anchor teeth has also been described<sup>10</sup> and an example of these can be seen in Figure 12. However, problems were

encountered with this design that do not appear to have been described in the literature to date:

- The hexagonal head of the implant is parallel sided (Figure 13) and, consequently, attachments have a single path of insertion.
- The path of insertion of the bands on the anchor teeth and the implant itself must be similar, particularly when the bands are a tight fit. Occasionally, it proved possible to overcome a small difference in angulations by using slightly oversized bands on the anchor teeth. In these cases, although the palatal arch can be placed, its removal is even more problematic and may necessitate sectioning of the arch, rather than removal in one piece. In some cases, the discrepancy between the paths of insertion is too great and placement is impossible. This would be the case with the lateral cephalogram illustrated in Figure 9, where an alternative method of attachment is required.
- To achieve a perfect Class I molar and canine relationship, small amounts of antero-posterior movement of the upper molars is sometimes required. This one-piece arch has little facility to accommodate these movements.
- No leveling or aligning of the anchor teeth is possible with a completely rigid system. The transpalatal arch prevents any rotations or angulation/inclination discrepancies of the anchor teeth from being corrected. Placing flexible leveling archwires is no problem, although later in the treatment the placement of stiffer stainless steel wires can prove to be impossible.

#### *Attachment with lingual hinge bracket*

Some of the problems described using banded and bonded transpalatal arches can be overcome using lingual brackets or lingual clips. These attach the arch to bands on the anchor teeth as first described by Männerchen.<sup>12</sup>

The design we favor involves the use of an Ormco lingual bracket (Figure 14), which is welded on to the palatal aspect of the bands on the anchor teeth. The size of the lingual bracket slot limits the transpalatal arch to 0.8 mm wire. Alternatively, it is possible to trim the ends of a 0.9 mm wire palatal arch until it can be accommodated in the brackets.

Path of insertion problems are no longer an issue as the bands can be cemented prior to arch placement. The palatal arch can then be fitted and the hinge clip of the bracket closed over the transpalatal arch wire (Figure 15a–c). When required, it is possible to incorporate elements to drive the anchor teeth distally. We have found the incorporation of a distal jet is effective in cases requiring a small amount of distal movement (Figure 16). These palatal arches are well tolerated by patients, and are easy for the clinician to fit and adjust.

#### *Impression technique*

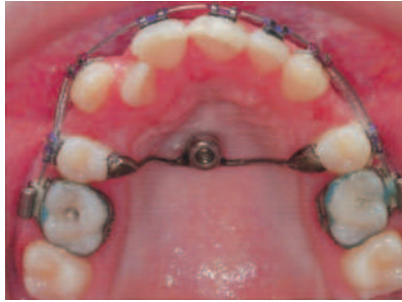- Construction of the palatal arch requires an accurate impression of the implant and the anchor teeth. The impression technique is reasonably straightforward:
- The healing cap used to cover the implant for the first 3 months after placement is removed (Figure 17) and the transfer coping is placed over the implant (Figure 18). In those patients with unusually high vaulted palates, the transfer coping occasionally impinges on the palate. A small amount of the plastic coping can be trimmed back with an air rotor without any detriment. It is imperative that the coping is fully seated on the implant to obtain an impression that will allow accurate 'implant' placement in the working model.
- Alginate is an unsuitable material, as the transfer coping can tear through as the impression is removed from the mouth. Silicone impression material is much stronger and, therefore, tearing is eliminated.
- If brackets are already in place, silicone impressions can be difficult to remove. This problem can be overcome by covering the brackets with either softened wax or a proprietary product design for this purpose (e.g. Mor-Tight, TP Orthodontics) as the labial surface of the teeth is not required for the construction of a palatal arch.
- Bands are selected and positioned on the molars in the usual way.

In the laboratory, a replica of the implant (called the Ortho analog) is placed into the open end of the transfer coping before the impression is cast (Figure 19). This accurately locates the implant within the working model in relation to the molar teeth. The technician then constructs the prescribed transpalatal arch.

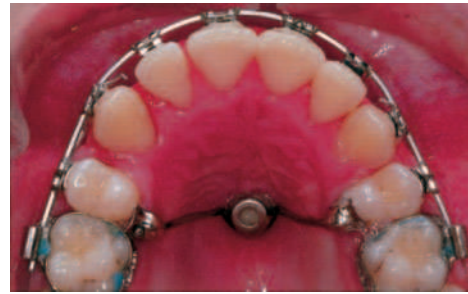## Discussion

To enable the optimal length of implant to be placed without either perforating the lining of the nasal cavity or damaging the apices of the upper incisors, careful planning is essential. A stent is required to remove the need for guesswork. The radiographic stent, followed by its conversion to a surgical stent, appears to be a reliable, easy and inexpensive method of ensuring accurate positioning of the palatal implants. They enabled the surgeon to confidently place the longer 6 mm implant in all cases. On careful examination at the time of surgery, there was no communication with the nasal cavity in any case. Lateral cephalograms taken post-operatively confirmed that the implants were not too close to the maxillary incisors.

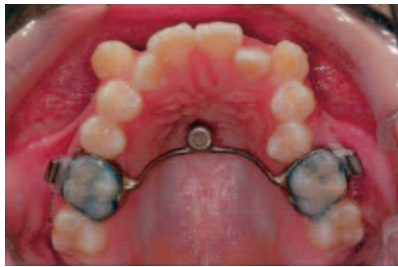In this series of cases, 3 implants did not integrate, although the reason for these failures is not clear. A number of factors have been implicated.<sup>13,14</sup> The bone of



**Figure 10** Transpalatal arch bonded to upper second premolars




**Figure 11** Debonded transpalatal arch and the resultant anchorage loss



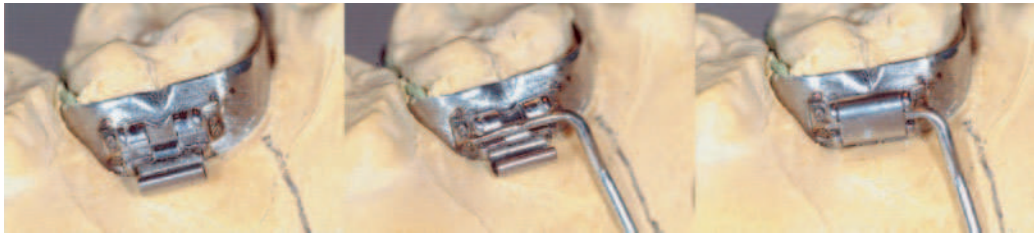
**Figure 12** Implant supported palatal arch connected to bands on the first molars



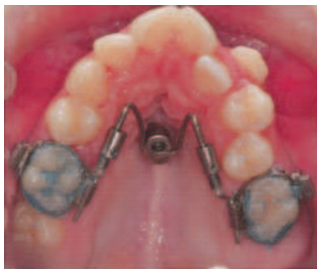
**Figure 13** Straumann Ortho implant



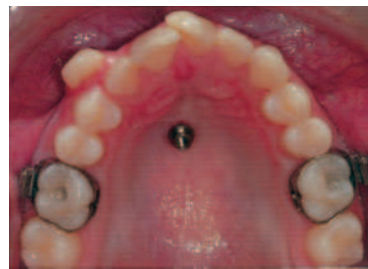**Figure 14** Ormco lingual hinge brackets



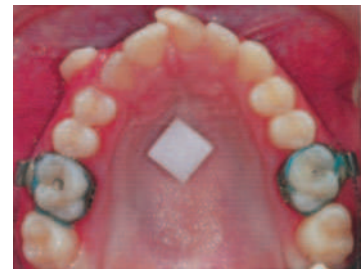**Figure 15** (a-c) Lingual hinge bracket open, bracket with archwire in place and then closed



**Figure 16** Distal jet anchored with mid-palatal implant, used to move anchor teeth distally



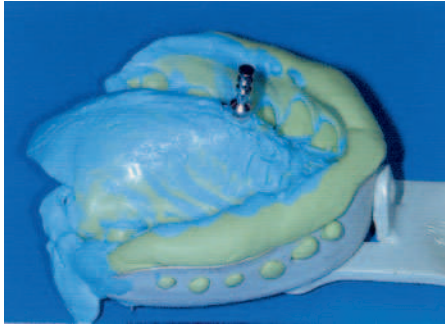
**Figure 17** Healing cap removed after 3 months



**Figure 18** Ortho transfer coping in position on implant prior to taking impression

the palate tends to be of poorer quality and not as dense as that of the mandible. The surgeons, when preparing the implant sites, commented on the variability of bone density between patients and the less dense bone may have contributed to implant failure.

A patent mid-palatal suture may also be problematical in younger patients and contribute to failure. A recent study,<sup>15</sup> examining cadavers, concluded that suture ossification begins no earlier than 17 years of age, which means the implant failure rate may be higher in patients under



**Figure 19** Ortho analogue positioned in impression prior to casting

this age. Some authors have suggested placing the implants lateral to the mid line to avoid this problem.<sup>16</sup>

A final consideration is the experience of the surgeon. As with any surgical technique, there is a steep learning curve. Although the surgical technique is not difficult, it requires precision. The preparation for the implant must be parallel sided, otherwise primary stability will be compromised. In this case series, two different surgeons placed the implants. One surgeon placed the first 13 implants and the second surgeon the last 7. With both surgeons, the failures occurred within the first few patients treated. Experience with the system and technique may also, therefore, contribute to success or failure.

Patient acceptance of the technique was excellent, as for most of the patients this was the first operative dentistry they had ever experienced. The procedure was considered to be acceptable and worthwhile by all. Only one patient experienced post-operative pain and this was relatively minor, requiring a single dose of an analgesic on the evening of placement.

## Summary

- The stent described in this article is an effective tool to aid in the positioning of palatal implants.
- Careful design of the palatal arch is central to the success of using palatal implants for anchorage reinforcement.
- Arches constructed with bands on the anchor teeth soldered to the palatal arch have problems associated with their path of insertion and can be difficult to fit.
- Arches bonded on to the palatal aspect of the anchor teeth often debond, leading to anchorage loss.

- Palatal arches retained with lingual brackets welded to the palatal aspect of the bands on the anchor teeth offer the greatest flexibility and have no path of insertion problems.

## References

1. Samuels RH, Willner F, Knox J, Jones ML. A national survey of orthodontic facebow injuries in the UK and Eire. *Br Dental J* 1996; **23**: 11–20.
2. Booth-Mason S, Birnie D. Penetrating eye injury from orthodontic headgear — a case report. *Eur J Orthod* 1988; **10**(2): 111–14.
3. Samuels RHA, Jones ML. Orthodontic injuries and safety equipment. *Eur J Orthod* 1994; **16**: 385–94.
4. Samuels RHA, Brezniak N. Orthodontic facebows: safety issues and current management. *J Orthod* 2002; **29**: 101–7.
5. Cureton SL, Regennitter FJ, Yancey JM. Clinical versus quantitative assessment of headgear compliance. *Am J Orthod Dentofac Orthop* 1993; **104**: 277–84.
6. Bartsch A, Witt E, Sahm G, Schneider S. Correlates of objective patient compliance with removable appliance wear. *Am J Orthod Dentofac Orthop* 1993; **104**(4): 378–86.
7. Brånemark P-I, Zarb GA, Albrektsson T. *Tissue-integrated Prostheses: Osseointegration in Clinical Dentistry* 1985. Quintessence Publishing Co. Inc., Chicago.
8. Adell R, Lekholm U, Rockler B, Brånemark P-I. A 15-year study of osseointegrated implants in the treatment of the edentulous jaw. *Int J Oral Surg* 1981; **10**: 387–416.
9. Wehrbein H, Merz BR, Diedrich P, Glatzmaier J. The use of palatal implants for orthodontic anchorage. *Clin Oral Implants Res* 1996; **7**: 410–16.
10. Wehrbein H, Feifel H, Diedrich P. Palatal implant anchorage reinforcement of posterior teeth: a prospective study. *Am J Orthod Dentofac Orthop* 1999; **116**: 678–86.
11. Celenza F, Hochman MN. Absolute anchorage in orthodontics: direct and indirect implant-assisted modalities. *J Clin Orthod* 2000; **34**: 397–402.
12. Männchen R. A new supraconstruction for palatal orthodontic implants. *J Clin Orthod* 1999; **33**: 373–82.
13. Kronstrom M, Svenson B, Hellman M, Persson GR. Early implant failures in patients treated with Branemark System titanium dental implants: a retrospective study. *Int J Oral Maxillofac Implants* 2001; **16**(2): 201–7.
14. O'Mahony A, Spencer P. Osseointegrated implant failures. *J Ir Dent Assoc* 1999; **45**(2): 44–51.
15. Schlegel KA, Kinner F, Schlegel KD. The anatomic basis for palatal implants in orthodontics. *Int J Adult Orthodon Orthognath Surg* 2002; **17**: 133–9.
16. Bernhart T, Vollgruber A, Gahleitner A, Dortbudak O, Haas R. Alternative to the median region of the palate for placement of an orthodontic implant. *Clin Oral Implants Res* 2000; **11**: 595–601.