



This is a repository copy of *Successful treatment of obscure gastrointestinal bleeding with intraoperative enteroscopy*.

White Rose Research Online URL for this paper:

<https://eprints.whiterose.ac.uk/201385/>

Version: Published Version

---

**Article:**

Shiha, M.G. [orcid.org/0000-0002-2713-8355](https://orcid.org/0000-0002-2713-8355), Tai, F.W.D. [orcid.org/0000-0002-4272-2007](https://orcid.org/0000-0002-4272-2007), Ching, H.-L. et al. (2 more authors) (2023) Successful treatment of obscure gastrointestinal bleeding with intraoperative enteroscopy. *Endoscopy*, 55 (S 01). E850-E851. ISSN 0013-726X

<https://doi.org/10.1055/a-2107-2889>

---

**Reuse**

This article is distributed under the terms of the Creative Commons Attribution (CC BY) licence. This licence allows you to distribute, remix, tweak, and build upon the work, even commercially, as long as you credit the authors for the original work. More information and the full terms of the licence here:

<https://creativecommons.org/licenses/>

**Takedown**

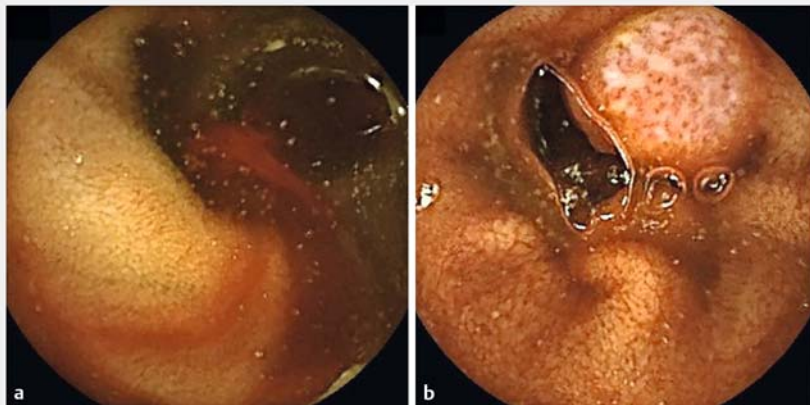
If you consider content in White Rose Research Online to be in breach of UK law, please notify us by emailing [eprints@whiterose.ac.uk](mailto:eprints@whiterose.ac.uk) including the URL of the record and the reason for the withdrawal request.



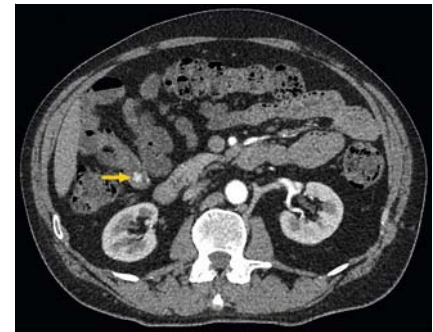
[eprints@whiterose.ac.uk](mailto:eprints@whiterose.ac.uk)  
<https://eprints.whiterose.ac.uk/>

## Successful treatment of obscure gastrointestinal bleeding with intraoperative enteroscopy

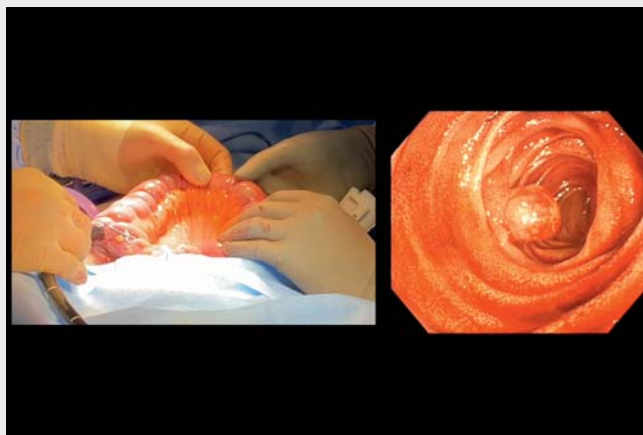
OPEN  
ACCESS



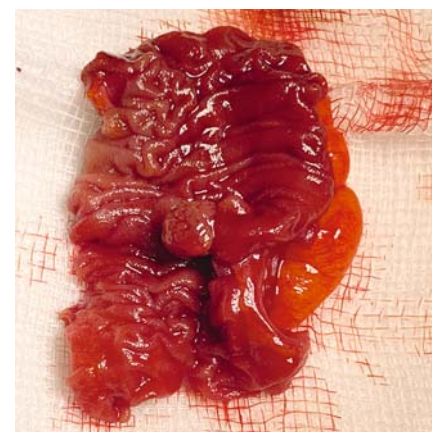
► **Fig. 1** Small bowel capsule endoscopy images. **a** Fresh bleeding. **b** Polypoid lesion in the distal small bowel.



► **Fig. 2** Abdominal computed tomography scan showing a polypoid lesion within the distal small bowel with hyper-enhancement on the arterial phase.



► **Video 1** The intraoperative enteroscopy procedure.



► **Fig. 3** The small bowel surgical resection specimen showing the lesion within the ileum.

A 51-year-old man was referred to our institution with persistent iron deficiency anemia. Initial gastroduodenoscopy and colonoscopy at his local hospital were unremarkable. A subsequent small bowel capsule endoscopy revealed a distal small bowel polyp with evidence of fresh bleeding (► **Fig. 1**). A triple-phase abdominal computed tomography scan confirmed a 13-mm vascular polypoid lesion within

the distal small bowel, with hyper-enhancement on the arterial phase (► **Fig. 2**). After a discussion in a multidisciplinary team meeting, it was decided that surgical resection guided by intraoperative enteroscopy to localize the lesion would be the most appropriate course of action. During intraoperative enteroscopy, an actively bleeding polyp was detected in

the distal ileum (► **Video 1**), and a limited small bowel resection was performed without complications (► **Fig. 3**). The patient was discharged 2 days after the surgery. Histological examination of the resected specimen showed a nodular area of ulceration lined with prominent granulation tissue. However, the cause for this ulceration was not histologically identified.

Obscure gastrointestinal bleeding (OGIB) is a challenging condition that accounts for nearly 5% of all gastrointestinal bleeding cases [1]. Small bowel vascular lesions

are the most common cause of OGIB [2]. Advances in small bowel capsule endoscopy and device-assisted enteroscopy revolutionized the diagnosis and management of small bowel bleeding [3]. Although the majority of cases can be managed endoscopically, this case highlights the value of intraoperative enteroscopy for the localization and treatment of small bowel lesions when endoscopic treatment is not feasible [4].

Endoscopy\_UCTN\_Code\_CCL\_1AC\_2AC

### Competing interests

The authors declare that they have no conflict of interest.

### The authors

**Mohamed G. Shiha**<sup>1</sup> , **Foong Way David Tai**<sup>1</sup> , **Hey-Long Ching**<sup>1</sup>, **Arun Loganathan**<sup>2</sup>, **David S. Sanders**<sup>1</sup>

- 1 Academic Unit of Gastroenterology, Sheffield Teaching Hospitals and The University of Sheffield, Sheffield, United Kingdom
- 2 Department of General Surgery, Sheffield Teaching Hospitals, Sheffield, United Kingdom

### Corresponding author

**Mohamed G. Shiha, MRCP**

Academic Unit of Gastroenterology, Royal Hallamshire Hospital, Glossop Rd., Broomhall, Sheffield S10 2JF, United Kingdom  
Mohamed.shiha1@nhs.net

### References

- [1] Sey MSL, Yan BM. Optimal management of the patient presenting with small bowel bleeding. *Best Pract Res Clin Gastroenterol* 2019; 42–43. doi:10.1016/j.bpg.2019.04.004
- [2] Rockey DC. Occult and obscure gastrointestinal bleeding: Causes and clinical management. *Nat Rev Gastroenterol Hepatol* 2010; 7: 265–279. doi:10.1038/nrgastro.2010.42
- [3] Pennazio M, Rondonotti E, Despott EJ et al. Small-bowel capsule endoscopy and device-assisted enteroscopy for diagnosis and treatment of small-bowel disorders: European Society of Gastrointestinal Endoscopy (ESGE) Guideline – Update 2022. *Endoscopy* 2023; 55: 58–95. doi:10.1055/a-1973-3796
- [4] Voron T, Rahmi G, Bonnet S et al. Intraoperative enteroscopy: Is there still a role? *Gastrointest Endosc Clin N Am* 2017; 27: 153–170. doi:10.1016/j.giec.2016.08.009

### Bibliography

*Endoscopy* 2023; 55: E850–E851

DOI 10.1055/a-2107-2889

ISSN 0013-726X

© 2023. The Author(s).

This is an open access article published by Thieme under the terms of the Creative Commons Attribution License, permitting unrestricted use, distribution, and reproduction so long as the original work is properly cited.

(<https://creativecommons.org/licenses/by/4.0/>)

Georg Thieme Verlag KG, Rüdigerstraße 14, 70469 Stuttgart, Germany



### ENDOSCOPY E-VIDEOS

<https://eref.thieme.de/e-videos>



*E-Videos* is an open access online section of the journal *Endoscopy*, reporting on interesting cases and new techniques in gastroenterological endoscopy. All papers include a high-quality video and are published with a Creative Commons CC-BY license. *Endoscopy E-Videos* qualify for HINARI discounts and waivers and eligibility is automatically checked during the submission process. We grant 100% waivers to articles whose corresponding authors are based in Group A countries and 50% waivers to those who are based in Group B countries as classified by Research4Life (see: <https://www.research4life.org/access/eligibility/>).

This section has its own submission website at

<https://mc.manuscriptcentral.com/e-videos>