

## An update on VEXAS syndrome

Adam Al-Hakim & Sinisa Savic

To cite this article: Adam Al-Hakim & Sinisa Savic (2023) An update on VEXAS syndrome, Expert Review of Clinical Immunology, 19:2, 203-215, DOI: [10.1080/1744666X.2023.2157262](https://doi.org/10.1080/1744666X.2023.2157262)

To link to this article: <https://doi.org/10.1080/1744666X.2023.2157262>



© 2022 The Author(s). Published by Informa UK Limited, trading as Taylor & Francis Group.



Published online: 26 Dec 2022.



Submit your article to this journal [↗](#)



Article views: 7597



View related articles [↗](#)




View Crossmark data [↗](#)



Citing articles: 1 View citing articles [↗](#)

## An update on VEXAS syndrome

Adam Al-Hakim<sup>a</sup> and Sinisa Savic <sup>a,b,c</sup>

<sup>a</sup>Department of Clinical Immunology and Allergy, Leeds Teaching Hospitals, NHS Trust, Leeds, UK; <sup>b</sup>Leeds Institute of Rheumatic and Musculoskeletal Medicine (LIRMM), School of Medicine, University of Leeds, Leeds, UK; <sup>c</sup>National Institute for Health Research (NIHR) Leeds Biomedical Research Centre, School of Medicine, University of Leeds, Leeds, UK

### ABSTRACT

**Introduction:** VEXAS (vacuoles, E1 enzyme, X-linked, autoinflammatory, somatic) syndrome is a recently described, late-onset, acquired autoinflammatory disorder caused by mutations in the *UBA1* gene. The various clinical manifestations of VEXAS broadly divided into inflammatory or haematological. VEXAS defines a new disease category – the hematoinflammatory disorders triggered by somatic mutations restricted to blood but causing systemic inflammation with multi-organ involvement and associated with aberrant bone marrow status. VEXAS causes significant morbidity and reduced life expectancy, but the optimum standard of care remains undefined

**Areas covered:** This review describes the discovery of VEXAS, relevant genetic causes and immunopathology of the disease. A detailed account of its various clinical manifestations and disease mimics is provided. Current treatment and management options are discussed.

**Expert opinion:** New rare variants in *UBA1* and VEXAS-like *UBA1* negative cases are reported. Consensus diagnostic criteria might be required to define VEXAS and its related disorders. Investigation of sporadic, VEXAS-like cases will require the application of deep sequencing using DNA obtained from various cellular or tissue locations. Prospective studies are needed to define the optimal supportive and treatment options for patients with varying disease severity and prognosis. VEXAS-specific hematopoietic stem cell transplant selection criteria also require development.

### ARTICLE HISTORY

Received 4 November 2022  
Accepted 7 December 2022

### KEYWORDS

Anti-IL1; anti-IL6; corticosteroids; E1 ubiquitin ligase; hematoinflammatory diseases; hematopoietic stem cell transplant; JAK inhibitor; macrocytic anaemia; myelodysplastic syndrome; sweets syndrome; relapsing polychondritis; venous thromboembolism; VEXAS; UBA1

## 1. Discovery of VEXAS

VEXAS (vacuoles, E1 enzyme, X-linked, autoinflammatory, somatic) syndrome is notable both for its presentation as a combined autoinflammatory and haematological disease, as well as the manner of its discovery using a ‘genotype-first’ approach. The latter heralds a new era for the identification of novel monogenic pathology [1].

Whereas monogenic autoinflammatory conditions have been discovered through the ‘top-down’ identification of early-onset inflammatory symptoms aggregating within families, VEXAS syndrome was identified in 2020 through the whole exome sequencing of 2,560 patients, during which a mutation in ubiquitin activating enzyme 1 (*UBA1*) was identified in three patients. A shared pattern of histopathology and disease emerged. This was predominantly a combination of cytopenias and multi-system inflammatory symptoms in older males. Once this phenotype was elucidated, similar perplexing cases with this characteristic mix, which had typically been managed as either myelodysplastic syndrome (MDS), discrete inflammatory illnesses or a systemic autoinflammatory disease (SAID), were found to have the same mutation. Eventually, 25 cases, all men, were reported [1].

This manner of discovery is not the only way in which VEXAS syndrome has challenged the established understanding of autoinflammatory disease. Most SAIDs are Mendelian

disorders, in that they arise from inherited germline mutations passed through generations. VEXAS syndrome, by contrast, emerges within a new category of autoinflammatory disease in which the causative mutation is acquired later in life, as a somatic mutation. The disease penetrance associated with the known pathogenic mutations in *UBA1* appears to be close to 100%, irrespective of the variant allele fraction of mutated cells [2]. Often this somatic mosaicism can only be identified through next-generation sequencing (NGS) gene analysis. VEXAS highlights the success of these new modalities and approaches, which offer the potential for further breakthroughs in the future.

## 2. Genetics of VEXAS

The occurrence of somatic mutations over time is well established, with consequences ranging from the accumulation of benign allele variants to tumorigenesis and clinical disease [3]. In VEXAS syndrome, there is an acquired inactivating mutation of the X-linked *UBA1* gene [4]. *UBA1* codes for the main E1 activating enzyme in humans, responsible for over 90% of the activation of ubiquitin, ubiquitylation-dependent intracellular protein degradation and cell homeostasis [5,6]. The gene can be expressed as either UBA1a, a nuclear isoform initiated at p.Met1, or as UBA1b, a shorter cytoplasmic isoform initiated at p.Met41 [1,4].

**Article highlights**

- VEXAS (vacuoles, E1 enzyme, X-linked, autoinflammatory, somatic) syndrome is an acquired, late-onset autoinflammatory disorder caused by mutations in the *UBA1* gene.
- Almost all pathogenic mutations lead to the loss of the cytoplasmic form of UBA1 (UBA1b), an essential E1 ubiquitin activating enzyme
- VEXAS has diverse clinical manifestations and can mimic inflammatory disorders such as relapsing polychondritis, vasculitis and Sweet's syndrome
- Haematological manifestations include cytopenias (macrocytic anaemia is almost universal); thromboembolic events; and typical and atypical myelodysplasia. However, progression to haematological malignancies, such as acute myeloid leukemia or chronic myelomonocytic leukemia, is rare
- Corticosteroids are effective, but their use is limited by toxicity
- Ideal standard of care is yet to be defined but biological and synthetic DMARD's can be useful for inflammatory complications and hypomethylating agents such as azacitidine have also shown promise
- Allogeneic hematopoietic stem cell transplant is a potentially curative option for selected patients, but VEXAS-specific selection criteria and the ideal conditioning regimen need to be developed

**2.1. Causative mutations**

To date, almost all of the known pathogenic mutations leading to VEXAS syndrome involve substitutions of Methionine-41 (p.Met41). Around half of all published cases of VEXAS have the c.122 T > C, p.Met41Thr substitution, whilst another 21% are made up of the c.121A > G, Met41Val and c.121A > C, Met41Leu substitutions, all of which disrupt initiation of the cytoplasmic isoform UBA1b, halting its expression [7–9]. If disrupted in this fashion, an alternative initiation codon at p. Met67 results in the expression of a novel isoform, termed UBA1c, which has reduced catalytic activity. The next most common group of mutations are the 6% affecting the splice acceptor site immediately preceding exon 3. Given Met41 is the second amino acid encoded by exon 3, these splice site mutations likely cause its omission, again leading to initiation at p.Met67 and expression of UBA1c, as seen in the more common p.Met41 substitution mutations [7,8].

Whether it is the presence of UBA1c or absence of UBA1b which drives the pathogenesis, in both the p.Met41 substitutions and splice acceptor mutations there is an overall loss of cytoplasmic UBA1 driven activity. It has been hypothesised that this results in a global loss of ubiquitination, accumulation of misfolded proteins, endoplasmic reticulum (ER) stress and likely activation of the unfolded protein response (UPR) [1,2,10].

Research from Ferrada et al. involving a retrospective case series from USA and UK has uncovered a relationship between the different mutations affecting Methionine-41 and the role of residual UBA1b in determining clinical presentation and severity of the resulting disease [11]. Methionine is coded for by the DNA nucleotide sequence ATG, the universal start codon in all eukaryotes. Though ATG (AUG once transcribed) almost exclusively fulfills this role, previous research has shown that other nucleotide sequences can act as alternative, but less efficient, start codons [12]. The most effective of these across six studies and assays include CTG, GTG, TTG and ACG [12]. Of note, although there are nine possible substitution mutations of ATG, the only

Methionine-41 substitutions discovered which cause VEXAS have been from ATG (methionine) to ACG (threonine), GTG (valine) and CTG (leucine). These have all been shown to be capable of initiating some degree of translation.

The researchers demonstrated that these three substitution mutations did indeed result in residual production of UBA1b to a greater degree than the six other possibilities, suggesting a threshold of UBA1b production which allows for cell survival and disease manifestation [11]. Though TTG also codes for a leucine and has some translational capacity, results showed that it produced less UBA1b than the other three, strengthening this idea of a threshold. This finding was further supported by a VEXAS patient identified with two novel mutations in exon 3 of UBA1: c.121 A > T, p.Met41Leu<sup>TTG</sup> (the only identified TTG case) which reduced UBA1b below the assumed disease-specific threshold, and c119G>C, p.Gly40Ala which actually increased UBA1b production compared to wildtype, thus concurrently bringing the UBA1b production to around the level of the p.Met41Val mutation and causing disease [11]. Finally, the VEXAS mutation with the lowest measured UBA1b production (c.121A > G, Met41Val) was associated with the worst prognosis of the three, suggesting a correlation between UBA1b production and disease severity [11]. This finding is keeping with another large cohort study which showed that UBA1 p.Met41Leu mutation was associated with a better prognosis [13]. It has been proposed that this is the first example of varying mutations in the same amino acid resulting in a spectrum of disease, directly due to protein translation [11].

The same case series showed that specific genetic variants were associated with a particular clinical presentation of the disease. Patients with the Leu variant were more likely to be diagnosed with Sweet's syndrome, patients with the Thr variants were more likely to develop inflammatory eye disease and those with the Val variant were less likely to develop ear chondritis [11]. Additional work is needed to identify how these mutations drive differing phenotypes and whether UBA1b production or some other processes are involved.

Further mutations have been identified and are unusual in that they do not seem to affect UBA1b initiation, nor cause UBA1c expression. Two cases of the Ser56Phe, also found in UBA1 exon 3, have been reported and result in reduced catalytic activity of UBA1 through temperature-dependent reduction in ubiquitination [7,14]. Furthermore, Collins et al. recently reported six novel somatic mutations in UBA1 (p. His55Tyr, p.Gly477Ala, p.Ala478Ser, p. Asp506Gly, p. Asp506Asn, and p.Ser621Cys) all leading to VEXAS syndrome, with none causing UBA1c production [15]. Rather, they too led to reduced catalytic function of both isoforms, UBA1a and UBA1b, and could be further subdivided in terms of how they affected catalysis [15]. Certainly, further research is needed on how this alternative pathophysiology drives the same disease.

**3. Pathogenesis of VEXAS**

In some somatic mutations, such as those in malignancy, a driver mutation confers a survival advantage in all cell types, with increasing variant allele frequency (VAF) seen

through successive generations of cells. In VEXAS, though the mutation is known to occur in multipotent haemopoietic progenitors, there appears to be selection pressures which determine the expression of the mutated allele in only specific cell lines. In myeloid progenitors with a VAF of 80%, there was a VAF of >80% in neutrophils and monocytes, whilst in megakaryocyte-erythrocyte progenitors with a VAF >65%, there was a VAF >90% in megakaryocytes, indicating propagation of the mutant alleles through positive selection pressure [7]. In contrast, where the lymphoid progenitor mutant allele VAF was >75%, the derived B and T lymphocytes contained almost exclusively wild-type alleles [1,7]. Interestingly, these patterns of distribution are consistent irrespective of the VAF in the hematopoietic progenitor cells [2].

The absence of the mutant allele in mature lymphocytes indicates its presence is incompatible with survival in these cell types. This negative clonal selection pressure is underscored by the development of lymphopenia as part of the disease [16]. However, it is worthwhile noting that lymphopenia in VEXAS might also result from frequent use of corticosteroids. It is not yet understood how or why the mature myeloid cells favour the mutant allele whereas the lymphocytes exclusively select against it. Further research is required to understand the mechanisms of this process.

In one particularly interesting case study, the patient was noted to have an initial CALR-mutated essential thrombocythemia (ET), which was later out-competed by a separate UBA1 gene mutation (pMet41Leu), with eventual UBA1 clonal dominance and resolution of the ET [17]. CALR mutations are themselves effective driver mutations in myeloproliferative neoplasms and the positive selective pressure of the UBA1 mutation in this patient highlights the strength of the mutant UBA1 survival advantage and raises questions around how this is achieved. One possibility is that the mutant UBA1 alleles create an autoinflammatory microenvironment which predispose these myeloid lineages to survival [17]. Ongoing studies in this area suggest that clonal haematopoiesis (CH) alleles are more commonly seen in VEXAS than previously thought, but the precise effects of co-occurring CH and mutated UBA1 on the clone survival and disease outcomes are yet to be fully characterised [18].

### 3.1. Inflammatory profile

The exact mechanisms underlying the progressive cytopenias and relapsing inflammatory symptoms in VEXAS remain poorly understood. As detailed above, these somatic mutations lead to impaired cytoplasmic UBA1 activity within affected cell lines, likely resulting in the UPR and overexpression of inflammatory cytokines. Patients with VEXAS were found to have overexpression of interferon gamma (IFN $\gamma$ ), interleukin (IL)-8 and interferon-inducible protein 10. The role of reduced UBA1 activity in driving this was supported by similar cytokine profiles in zebrafish models with germline UBA1 mutations [1]. A similar pathogenesis is seen in a subset of autoinflammatory diseases known as proteasomopathies, where activation of the UPR leads to a type I interferon response, with the release of IFN- $\alpha$  and IFN- $\beta$ , which induces inflammation [2,19].

There have been instances of patients presenting with a VEXAS-like syndrome in the absence of any identified pathogenic mutation in the UBA1 gene. Given our understanding of disease pathogenesis, this raises the possibility that mutations might be acquired elsewhere in the three-step ubiquitylation process, resulting in the same clinical disease. Expanding genetic analysis to associated enzymes (such as the E2 ligase enzyme) in patients with these phenocopies, may well become a frontier for disease research in the coming years [2].

### 3.2. Bone marrow morphology/manifestations

A key finding in VEXAS syndrome is of cytoplasmic vacuoles in myeloid and erythroid precursor cells. These are not pathognomonic for VEXAS syndrome and can be seen in alcoholism, MDS, zinc toxicity and copper deficiency. They are however, a rare finding and if identified in the context of inflammatory symptoms or presumed MDS should warrant genetic analysis to look for VEXAS syndrome [20]. Furthermore, some VEXAS cases have been found to have only minimal morphologic findings, such as the moderate hypercellularity with occasional cytoplasmic vacuoles in the myeloid precursor cells. This underlines the importance of genetic analysis where there is clinical suspicion of the disease [21].

Other typical marrow findings in patients with VEXAS syndrome include hypercellular marrow with granulocytic hyperplasia; minimal dyspoiesis without evidence of overt dysplasia; a normal karyotype; and no increase in blasts in the absence of associated MDS [20].

## 4. VEXAS and MDS

Cytopenias, and progression to MDS, are common features of VEXAS syndrome, although understanding of the underlying process remains elusive. In the two largest retrospective case-series, MDS was diagnosed in 31–50% of cases. This is much greater proportions than the 2–6% over 10 years seen in paroxysmal nocturnal haemoglobinuria, another clonal hematopoietic diseases [11,13,22,23]. In ‘classical’ MDS, mutations lead to clonal proliferation of haemopoietic stem cells (HSC), leading to inefficient haematopoiesis which can progress to cytopenias, bone marrow dysplasia and transformation into acute myeloid leukaemia (AML) [24]. There is a growing understanding of the bone marrow microenvironment as a key factor in the development of MDS. However, there is no consensus on whether clonal HSCs dysregulate the microenvironment, to enhance their own survival whilst suppressing normal haematopoiesis, or whether an altered microenvironment first initiates MDS [25,26]. It is conceivable that the UBA1 gene mutation could be driving either of these processes. There is already an established link between MDS and systemic autoimmune and/or inflammatory disease (approximately 20%), although with little data on the pathophysiological link between the two, nor which one drives the other [27]. Nonetheless, this data suggests a role for inflammation in the dysregulation of the marrow microenvironment resulting in the initiation of MDS. Furthermore, it suggests the inflammatory component of VEXAS may be playing a key role in the resultant hematologic phenotype.

It is not uncommon to identify mutations associated with MDS on genetic screens of VEXAS patients though the significance of these is unclear. In a French case series of 116 patients, additional genetic screening was performed in 75 patients with 18 somatic mutations (24%) identified, typically in DNMT3A and TET2 [13]. Of the 7 VEXAS cases identified from screening cytopenic patients, Poulter et al. found two with MDS associated gene mutations (in ASXL1 and DNMT3A), with no clear consequence [28]. These mutations might be age related, but further work is required to determine their role and significance in VEXAS-MDS.

Analysis of the USA/UK cohort found patients split into two groups based on their Revised International Prognostic Scoring System (IPSS-R) scores (very low/low risk versus intermediate/high risks) found no association between IPSS-R and death. In addition, most VEXAS patients had lower-risk MDS, with low IPSS-R scores, fewer associated MDS-related mutations and no cases of progression to acute myeloid leukaemia [11,29]. A novel scoring system for MDS, the Molecular International Prognosis Scoring System (M-IPSS) has been recently proposed and integrates mutations of 38 gene loci to better determine risk and to stratify patients. Of note, UBA1 has not been included, possibly because it is so recently discovered [24]. Although MDS in VEXAS was not associated with increased mortality compared to those without MDS, two large case series have demonstrated that transfusion dependence occurs in 32% of all VEXAS cases and increases the risk of dying by around 4.5-fold [11]. There is clearly a disconnect between MDS diagnosis in VEXAS, MDS risk scoring and overall mortality, which often relates to haematological dysfunction. Therefore, although VEXAS patients might fulfil the diagnostic criteria of MDS, there is a growing sense that the classification poorly describes both the disease course and mortality through MDS scoring systems. As first proposed by Ferrada et al., it is possible that VEXAS may come to represent its own haematological phenotype; a 'highly inflammatory clonal cytopenia' and something which will require further comprehensive research to elucidate [11].

## 5. Epidemiology

In order to determine the prevalence of UBA1 mutations and associated clinical disease in an unselected population, Beck et al. used a genomic ascertainment approach to seek UBA1 variants in exome data collected from 163,096 participants in the Geisinger MyCode Community Health Initiative [30]. Of this 'Geisinger cohort' the mean age was 52.8 years, with 94% European ancestry and 61% female. Eleven individuals comprising nine men and two women were identified with known pathogenic UBA1 mutations. All manifested inflammatory disease consistent with VEXAS and developed anaemia, with a high rate of macrocytosis (91%) and thrombocytopenia (91%). Overall, the study gave an estimated variant prevalence of 1 in 14,000 from the entire cohort, 1 in 4,000 for males >50 years, 1 in 26,000 for females >50 years and 1 in 8,000 combined for individuals aged >50 years [30]. Interestingly, no patients had been diagnosed with any of the proposed common inflammatory manifestations of VEXAS, including Sweet's syndrome, RP and PAN. Nevertheless, there was a comparable

rate of haematological and pulmonary involvement when compared with the original cohort. This was a novel insight, proving that acquisition of the mutation can precede clinical disease, whilst confirming the high penetrance of the mutations [30]. The paper proposed that VEXAS had a prevalence similar to Behcet disease (around 1 in 10,000) and MDS (around 1 in 14,000) which provides a helpful benchmark in the investigation of clinically challenging cases [30–32].

## 6. Clinical characteristics

### 6.1. Common inflammatory manifestations

VEXAS commonly presents as a progressive systemic inflammatory disease in men above the age of 50. As a somatic X-linked syndrome, this clinical profile is logical. However, as more cases are identified there have been seven females diagnosed. Three of these cases can be explained by monosomy X; two acquired due to somatic mosaicism, whilst another had constitutional 45,X Turner syndrome [33–35]. A fourth case did have a confirmed UBA1 mutation (p.Met41Leu) with relapsing polychondritis, though the VAF was only 0.14% [36]. Two further cases were identified by screening the exomes of the Geisinger cohort (described earlier) and were both euploid with VAFs of 19.3% and 20.9%, whilst manifesting clinical disease [30]. A further case was described by Poulter et al. who, on screening 460 cytopenic females, identified a single female patient with a UBA1 mutation (p.Met41Thr, VAF 33%) associated with VEXAS [28]. Subsequent analysis found no evidence of monosomy X or microdeletion around the wild-type UBA1 allele, although this could not be completely excluded. The authors proposed that the wild-type allele could have undergone X-inactivation, though previous studies have shown that this does not occur with the UBA1 gene [37]. Certainly, further work is needed to understand disease penetrance in these cases and any that may follow. The existence of these patients highlights the need for clinicians to maintain an open mind and consider VEXAS syndrome in female patients presenting with commensurate clinical or biochemical features.

Patients with VEXAS often present with intermittent and unexplained fevers, fatigue, myalgia, with a constellation of inflammatory symptoms affecting the skin, cartilage, joints, lungs and blood vessels [24]. There have been case series reported in France (n = 116), the USA/UK (n = 83), the Netherlands (n = 12), Mayo clinic (n = 9), Denmark (n = 11), Australia (n = 3) and Italy (n = 3) [11,13,38–42]. As the two largest cohorts, the French and USA/UK papers provide the best understanding of the frequency of the different clinical features seen in this highly heterogeneous condition.

The most common clinical features from the USA/UK and French cohorts (see Table 1) were skin lesions (82–83%); non-infectious fever (64–83%); weight loss (62%); lung involvement (50–57%); arthralgia/arthritis (27–58%); relapsing chondritis (36–52%); ocular symptoms (24–39%); venous thrombosis (35–41%) and lymphadenopathy (34%) [11,13]. Other less common inflammatory manifestations include pericarditis and myocarditis (13%) in the French cohort and orchitis (11%) in the USA/UK study [11,13]. Dermatological

**Table 1.** Clinical Characteristics of VEXAS Syndrome.

	Cohort 1 Ferrada et al. (n = 83)	Cohort 2 Georjin-Lavialle et al. (n = 116)
<b>Demographics</b>		
Age of disease onset, years, median (range)	66 (41–80)	67 (62.5–73)
Male sex, n (%)	83 (100)	111 (95.7)
<b>Clinical Diagnosis, n (%)</b>		
Relapsing polychondritis	43 (52)	N/A
Undifferentiated fever syndrome	19 (23)	N/A
Sweet's syndrome	18 (22)	N/A
MDS	26 (31)	58 (50)
<b>Clinical manifestations, n (%)</b>		
Fever	69 (83)	75 (64.6)
Skin involvement	68 (82)	97 (83.6)
Arthritis	48 (58)	33 (28.4)
Pulmonary infiltrates	47 (57)	47 (40.5)
Ear chondritis	45 (54)	37 (31.9)
Unprovoked deep vein thrombosis	34 (41)	41 (35.3)
Nose chondritis	30 (36)	18 (15.5)
Periorbital edema	25 (30)	10 (8.6)
Hearing loss	24 (29)	N/A
Ocular inflammation	20 (24)	43 (37)
Pulmonary embolism	11 (13)	N/A
Pleural effusion	11 (13)	11 (9.5)
Orchitis	10 (12)	N/A
Airway chondritis	1 (2)	0 (0)
<b>Haematological manifestations</b>		
Macrocytic anaemia	81 (97)	N/A
Thrombocytopenia	40 (83)	N/A

manifestations were reported in detail in the French study and included neutrophilic dermatoses; vasculitic rashes; erythema nodosum; urticaria; erythematous papules; periorbital oedema and injection-site reactions. This indicates the dermatological heterogeneity seen in this disease [13]. Ocular disease associated with the condition included cases of uveitis, scleritis, episcleritis and orbital masses, as might be expected in a systemic autoinflammatory condition. Lung disease presented as either pulmonary infiltrates or pleural effusions in both cohorts [11,13].

Borie et al recently performed further analysis on the French cohort, specifically to examine lung involvement in VEXAS [43]. Of note, the authors found that only 51 of the 114 initial patients in the French study (2 were added later) had a CT chest scan, having been requested following a clinical indication including fever, dyspnea, cough, hemoptysis or chest pain. Fever was the most common indication for requesting a CT in this subgroup (62%) and 88.2 (45/51) of this group had parenchymal or pleural lung disease. It is therefore difficult to draw conclusions from this data on the likely extent of lung disease in VEXAS, or to rely on comparisons in that cohort between patients with and without established lung disease [43]. Nevertheless, the study found that whilst pulmonary disease is prevalent in VEXAS, approximately half of cases present with an isolated fever and no respiratory symptoms, whilst 44% complain of dyspnoea and 2% require oxygen. Pleural effusions, ground-glass opacities and consolidations were the most common CT findings. These changes can mimic congestive cardiac failure or infection, but on follow-up, they rarely responded to conventional treatment for either and were instead found to improve with high-dose systemic corticosteroids [43].

A 5-year survival of 63% has previously been reported in VEXAS [9]. In the French cohort, after a median follow-up of 3 years, the 5-year survival for VEXAS with MDS was 83.0% and

without MDS 76.3%, although this difference was not statistically significant [13]. Significant risk factors associated with death in this study were gastrointestinal involvement (OR 3.7), lung infiltrates (OR 3.3) and mediastinal lymphadenopathy (OR 7.73) [13]. These data were further expanded by the USA/UK cohort whose retrospective analysis was performed over a longer period and recognised additional trends. In this cohort, the median survival time from symptom onset was 10 years and there was greater risk of dying in those with the Val variant, a correlation unrecognised in the French cohort due to shorter follow-up periods [11]. Median survival with this variant was 9 years, significantly shorter than patients with the Leu or Thr variants, whilst no patient with the Val variant survived beyond 12 years [11]. Significant risk factors associated with death in this cohort were the Val variant (OR 3.49) and transfusion dependence (OR 4.47), whilst ear chondritis was protective (OR 0.24) [11]. There was no association between UBA1 VAF and survival. Finally, the Geisinger paper of 163,096 unselected participants calculated that pathogenic UBA1 variants confer around 6.6-fold greater probability of mortality compared to age-, sex-, and BMI-matched non-carriers [30].

## 6.2. Inflammatory clinical mimics

Common inflammatory phenotypes seen in VEXAS include Sweet's syndrome, relapsing polychondritis (RP) and polyarteritis nodosa (PAN). Sweet's syndrome, also known as acute febrile neutrophilic dermatosis, presents with fever, neutrophilia and cutaneous or mucosal lesions. The characteristic lesions are tender erythematous papules, nodules or plaques which, on biopsy, show an infiltrate of mostly mature neutrophils [44]. In a study of eight patients with VEXAS and neutrophilic dermatosis, histology showed infiltrates of mature neutrophils with myeloid and lymphoid cells containing the same UBA1

mutation as paired bone marrow samples in all patients, suggesting the infiltrates were derived from the pathological clone [45]. Interestingly, in another study, this finding was replicated in two biopsies showing neutrophilic dermatoses but the *UBA1* mutation was not identified in cells from leukocytoclastic vasculitis (LCV) ( $n = 2$ ) or septal panniculitis ( $n = 2$ ) suggesting a differentiation of 'clonal' (neutrophilic dermatoses) and 'paraclonal' (LCV and septal panniculitis) cutaneous manifestations of the disease, which might help to direct targeted therapies in the future [46].

RP is a systemic inflammatory disease typically affecting the cartilage of the ears, nose and tracheobronchial tree, though it can also involve the joints, skin, eyes and other organs. A 2022 retrospective study of 95 patients assessing the differences between VEXAS associated RP and idiopathic RP showed that those with VEXAS-RP had a significantly higher rate of fever (60% vs 10%), skin lesions (82% vs 20%), ocular involvement (57% vs 28%), lung infiltrates (46% vs 0%) and a higher median CRP (64 mg/L vs 10 mg/L) [47]. Ferrada et al. showed that VEXAS could be predicted in those with RP with 100% sensitivity and 96% specificity if there was coexistent male sex, macrocytosis, and a platelet count of  $<200 \times 10^3/\mu\text{l}$  [48].

PAN is a medium-vessel vasculitis with widespread clinical manifestations including renal disease, hypertension, cutaneous lesions and cardiovascular injury. A literature review of vasculitis in VEXAS found nine patients who had developed medium vessel vasculitis, seven of whom fulfilled the criteria for PAN [49]. The most common vasculitis reported in VEXAS is actually LCV, which typically manifests as palpable purpura, and is often diagnosed on skin biopsies [49]. Large vessel vasculitis also occur in VEXAS with two cases of giant cell arteritis (GCA) and polymyalgia rheumatica (PMR) previously reported [7,49]. Furthermore, there have been two reported cases of ANCA-associated vasculitis in patients later diagnosed with VEXAS [41,42]. Vasculitis in VEXAS is reported as being particularly difficult to manage, with both reported VEXAS-GCA and VEXAS-PAN cases resistant to high dose corticosteroids and biologic therapy. Six of the nine patients with medium vessel vasculitis died during the treatment course, and of those that survived, two had successfully undergone allogeneic hematopoietic stem cell transplantation (HSCT) [49,50].

Other inflammatory phenotypes that have been diagnosed in patients with VEXAS include undifferentiated inflammatory bowel disease (IBD), spondylarthropathies and macrophage activation syndrome (MAS) [51–53].

### 6.3. Identifying screening populations

Multiple efforts have been made to screen populations of patients manifesting these discrete inflammatory phenotypes, both to identify further VEXAS cases and to clarify the prevalence of disease in these specific cohorts.

With the aim of identifying the association between Sweet's syndrome and VEXAS, Gurnari et al. investigated 19 patients with a diagnosis of Sweet's syndrome who had previously been investigated for haematological malignancies with a bone marrow (BM) biopsy [14]. Only 13 of these patients had DNA available and just four of these were male, three of whom had vacuoles on BM morphology. Remarkably,

the three male patients with vacuoles had pathogenic *UBA1* mutations and received a diagnosis of VEXAS, suggesting the need for *UBA1* screening in men with Sweet's syndrome and haematological abnormalities, especially those with vacuoles [14].

Poulter et al. investigated the frequency of VEXAS-associated mutations in two separate patient groups; those with unexplained cytopenia and those with confirmed GCA [28]. Of the 1055 male and female adults screened for cytopenia, seven patients with *UBA1* mutations were identified; six males and the female (XX) as mentioned above. All patients with clinical data available had presented with inflammatory phenotypes and anaemia, which was macrocytic in all but one, whilst the six patients with biopsy results showed vacuolation [28]. These findings suggested the need to screen patients with unexplained anaemia for *UBA1* mutations, especially in the context of macrocytic anaemia, inflammatory symptoms and vacuoles on bone marrow. There were no *UBA1* mutations discovered in the GCA cohort of 612 males, nor in a smaller study of 44 patients, suggesting that VEXAS is rarely misdiagnosed as GCA and should only be considered if other more overt features of VEXAS are present [28,54].

### 6.4. MDS populations screened

Huang et al. screened 47 patients with concurrent MDS and autoimmune disorders, identifying one VEXAS case [55]. The patient was a 61-year-old man with macrocytic anaemia, vacuoles on bone marrow morphology and a prior diagnosis of rheumatoid arthritis. With respect to his MDS, no other somatic mutations were detected and despite a low IPSS-R score he remained refractory to treatment and transfusion-dependent [55]. Our group retrospectively performed DNA analysis of the bone marrow samples of 44 patients (34 MDS, 10 CMML) who had undergone HSCT. We found no cases of missed known pathogenic *UBA1* mutations [56]. Given that only a few patients had experienced inflammatory symptoms and only 32% (14/44) had macrocytosis this result was unsurprising [56]. The findings of both studies underlines the way in which *UBA1* mutations manifest a very distinctive form of bone marrow failure which will need to be properly assessed and risk stratified in the context of MDS in the years to come.

## 7. Haematological manifestations

VEXAS is a disease characterised by its haematological component as much as its inflammatory features, such that any patient presenting with cytopenias and systemic inflammatory symptoms should be considered for genetic testing. Macrocytic anaemia is a classical finding of the disease, present in 96% (24/25) of the first published cohort [1]. A later, retrospective study of 18 patients highlighted the frequency of cytopenias, including macrocytic anaemia (100%), lymphopenia (80%), thrombocytopenia (50%) and monocytopenia (50%) [29].

Haematological malignancies and plasma cell dyscrasias also occur with the condition. In the same cohort 6/18 patients

developed MDS, with five becoming transfusion-dependent and the other experiencing worsening anaemia despite erythropoietin-stimulating agents [29]. In the French retrospective case-series 50% (58/116) developed MDS and 10.3% (12/116) had monoclonal gammopathy of unknown significance (MGUS), whilst elsewhere there have been reported cases of multiple myeloma [1,29,42,57].

### 7.1. Thrombosis in VEXAS

Thrombosis was identified as a key feature of VEXAS very early, with 44% (11/25) of the initial cohort having found to suffer a venous thromboembolism (VTE) [1]. VTEs are the most common thrombotic manifestation of VEXAS, typically presenting as unprovoked events. These generally occur within 2 years of the onset of inflammatory symptoms, as seen in two-thirds (6/9) of the reported VTEs in a case series assessing 16 patients of that initial group [29]. One review assessing the thrombosis and VEXAS in the literature gave an overall incidence of VTEs as approximately 40% [58]. Though less common, arterial thrombosis also occur in the condition and there is a reported incidences of 10–63% of all thrombotic events overall, including deep vein thrombosis' (DVT); pulmonary embolisms (PE); arterial thromboses; cardiovascular accidents (CVA); and myocardial infarctions (MI) in the published case series and combined case reports [58].

The underlying pathogenesis of thrombosis in VEXAS remains unclear. Thrombosis in conditions of chronic inflammation is a recognised phenomenon and likely to arise from myriad dysregulated pathways, including the inappropriate formation of fibrin (attaching thrombi to the vessel walls), or reduced synthesis and increased consumption of the natural anticoagulant, protein C [58–60]. Though the number of patients analysed is small, there is limited evidence that a proportion of those with VEXAS have elevated factor VIII activity, positively associated with increased CRP [29]. In an analysis of 16 patients, Obiorah et al. showed a high incidence of isolated or persistent lupus anticoagulant (LA) positivity at 69% (11/16) and 44% (7/16), respectively. Five of those with persistent LA positivity suffered a thrombotic event, whilst two of five patients who were LA negative also developed one, indicating the presence of multiple prothrombotic mechanisms at play with the disease.

Another consideration is the high incidence of vasculitis with VEXAS and the contribution of this towards thrombus formation. Thrombosis is a known complication of vasculitic conditions and is likely to arise from endothelial disruption in the context of an inflammatory environment, with neutrophil extracellular traps (NETs) playing a key role. NET formation is a function of neutrophils to release their DNA as a network of fibres, intended to bind extracellular pathogens. They play an important role in host-defence but, if dysregulated, can lead to thrombosis by providing a web-like scaffold for platelets and coagulation factors and causing endothelial dysfunction [58,61,62]. NETs have been implicated in the thrombogenesis of vasculitic conditions. In Behcet's, increased spontaneous NET formation with subsequent increased formation of thrombin has been

observed, whilst the anti-PR3 and anti-MPO antibodies of ANCA-associated vasculitis have been found to trigger neutrophil degranulation [63–65]. Given the manner in which neutrophils are ostensibly affected in VEXAS, with high prevalence of the genetic mutation and vacuoles on microscopy, NETs and other such cellular functions may play an important role in the thrombogenesis seen in this disease. Of course, whilst these highlight potential mechanisms underlying thrombosis formation in VEXAS, it remains the case that patients without vasculitis can still develop clots and those with vasculitis do not all develop them. Certainly, further work is required to elucidate the mechanisms leading to these events.

## 8. Treatment

### 8.1. General principles

The coexistence of inflammatory and haematological dysfunction presents a unique challenge in the management of VEXAS syndrome and often requires a multipronged approach, involving different specialist teams. There are two main approaches to therapy: to target and eradicate the UBA1-mutated haematopoietic population and to inhibit the inflammatory underpinnings of the disease [66]. Management of inflammatory symptoms can be difficult, and it is not unusual for these patients to remain on prolonged high-dose systemic corticosteroids, with associated toxicity, despite the addition of novel agents. In parallel to this, and often unrelated to inflammatory control, a subset of patients will become increasingly cytopenic and transfusion-dependent, whereby allogeneic haematopoietic stem cell transplant (AHSCT) becomes the only viable option, though this of course carries its own significant risk and is often contraindicated in those that have become too frail.

The severe and progressive nature of the disease, haematological complications and complications of prolonged glucocorticoid therapy means there is a huge unmet need for effective therapy of the disease [67]. Currently, there are no standardised treatment models for VEXAS and recommendations are based on a limited number of retrospective studies and best clinical reasoning. Certainly, comprehensive prospective research is required to firmly establish the optimal treatment options in these patients, preferably delineated by clinical features and risk factors.

As the only treatment with curative intent, it is increasingly likely that AHSCT will become the mainstay of early intervention upon diagnosis, though there will always be a subset of patients unable to have the treatment due to the high morbidity and mortality in older and frailer patients. Nor does early HSCT preclude the need to establish effective medical therapies, as multiple studies have shown good inflammatory control reduces the likelihood of post-transplant complications such as graft-versus-host disease (GVHD) [68,69]. Indeed, in the more established paediatric cohort of autoinflammatory patients requiring HSCT, we see firm recommendations on controlling inflammation prior to transplantation, in order to reduce post-transplant complications [70].



## 8.2. Risk stratification

VEXAS is a markedly heterogeneous disease, illustrated by the Geisinger cohort in whom pathogenic UBA1 mutations were identified with consistent disease penetrance but much lower rates of severe inflammatory symptoms than previously reported [30]. Furthermore, there is growing understanding of clinical factors which denote an increased risk of mortality as mentioned above. Thus, there is a need to take a holistic approach managing these patients, based on their clinical need and risk factors. In those with poorly controlled or high risk disease, e.g. patients with p.Met41Val mutation or transfusion dependence, AHSCT should be considered. In patients with only mild disease and no risk factors, there should be a focus on optimising medical management, though as more data arrives on the efficacy of treatments and thresholds for HSCT, this recommendation may change in time (Figure 1).

## 8.3. Medical management

Though there have been no studies to assess the efficacy of these measures, it is sensible to consider appropriate prophylactic and supportive treatments in patients with VEXAS syndrome. In lymphopenic patients, vaccinations could be considered, whilst prophylactic antibiotic/antivirals may be indicated in the context of recurrent infections. To reduce the risk of thrombotic complications, typically unprovoked VTEs, long-term anticoagulation should be discussed with the patient, though this needs to be balanced against the risk of bleeding, especially the likelihood of gastrointestinal bleeds if on non-steroidal anti-inflammatories or steroids [67]. Certainly, VTE prophylaxis should be prescribed for inpatient care, unless contraindicated. If patients are developing worsening anemia they should be referred to

haematology for consideration of appropriate supportive treatments.

Patients will often first attend clinic on high-dose systemic corticosteroids, which are highly effective at controlling the inflammatory symptoms, and the aim should be to provide steroid-sparing agents and reduce steroids as much as possible, even to cessation. What drugs are used may depend on whether they are manifesting primarily inflammatory or haematological disease.

In patients manifesting mostly inflammatory and rheumatological disease, therapeutic options include anti-interleukin (IL)1 (anakinra & canakinumab), anti-IL6 (tocilizumab) and JAK-inhibitors (e.g. baricitinib & ruxolitinib). Most case studies looking at the anti-IL1 drugs anakinra and canakinumab have shown equivocal results. In the Dutch case series looking at seven patients, two had a good response, four were discontinued due to injection site reactions and one had experienced recurrence [38]. Two of the patients were switched to canakinumab with one having a variable to good response and the other experiencing disease recurrence [38]. Skin site reactions are common with anakinra, though across multiple studies there have been particularly severe reactions reported when used for VEXAS and this should be counselled about and monitored for [51,67]. Tocilizumab similarly reports some success, though with high rates of non-response and recurrence [67]. In one case series of 11 patients, four had a good, though transient, clinical response with a median time of 8 months to the next treatment [9]. In the Dutch case, a series of the four patients on Tocilizumab three had a partial response and one had a good response [38].

In a recent retrospective case series of 30 patients assessing the efficacy of different JAK inhibitors (JAKi) in VEXAS, with ruxolitinib (n = 12), tofacitinib (n = 11), baricitinib (n = 4) and upadacitinib (n = 3) all compared [71]. Overall 50% (15/30) had

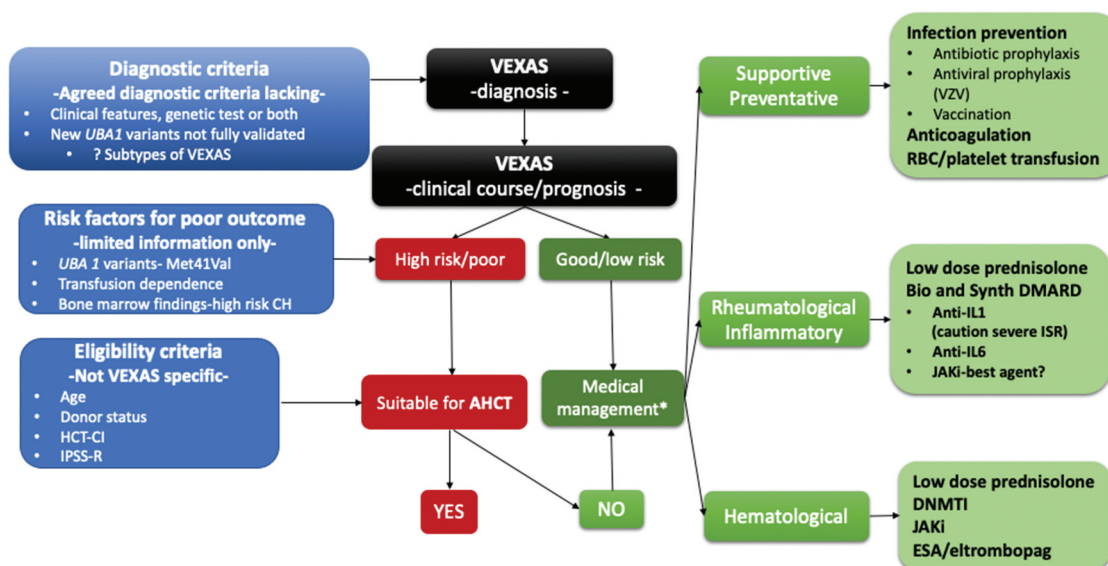


Figure 1. VEXAS-proposed treatment algorithm and outstanding questions to address.

\*based on anecdotal evidence and case/series reports.

CH: Clonal hematopoiesis; HCT-CI: Hematopoietic cell transplantation-specific comorbidity index; IPSS-R: Revised International Prognostic Scoring System; AHCT: allogeneic hematopoietic stem cell transplantation; VZV: varicella-zoster virus; RBC: red blood cells; Bio: Biological, Synth: Synthetic DMARD: Disease-modifying anti-rheumatic drugs; JAKi-Janus kinase inhibitor; DNMTi: DNA methyltransferase inhibitors; ESA: erythropoiesis-stimulating agents

a clinical response after 1 month, with 66% (20/30) experiencing partial (9/30) or total (11/30) CRP normalisation. Over 6 months, there was a significantly better clinical and biochemical response in ruxolitinib compared to the other JAKi whilst it was also superior in terms of improving red blood cell (RBC) and platelet levels [71]. In the 11 patients still on therapy at 6 months, there was a median steroid reduction of 83.6% in the ruxolitinib group, compared to 75% for the others. Of the four patients who achieved blood transfusion independence from dependence after 1 month, all were on ruxolitinib [71]. The most frequent adverse events were infections (36.7%) and thromboembolic events (20%), though these are commonly seen in VEXAS and relationship to JAKi's is not entirely clear [71]. Ruxolitinib, like baricitinib, is a JAK1/2 inhibitor, whereas upacitinib is a selective JAK1 inhibitor and tofacitinib targets JAK1/3 receptors. Whether this has a role in their efficacy in managing VEXAS requires further analysis. Finally, in a single-case report, one patient who received the anti-IL17 drug secukinumab and intravenous immunoglobulin had a sustained response with normalisation of CRP and RBCs [52].

In patients with haematological manifestations of VEXAS syndrome, the JAKi have become a viable option for their reported effect on cell counts and transfusion dependence. Another option to consider are the DNA methyltransferase inhibitors (DNMTI) e.g. azacitidine and decitabine, which are commonly used in MDS for pre-treatment prior to HSCT and have shown efficacy in MDS-associated inflammation [72]. Comont et al. showed that 46% (5/11) patients saw an improvement of inflammatory symptoms, reduction in steroid requirement and a concomitant haematological response in two of the five, over a median duration of >1 year [73]. More promising results were seen in Bourbon et al. where four patients, three with a diagnosis of MDS, received 4–5 months of therapy, with a comparatively better median time to the next therapy when compared to anti-cytokine agents, methotrexate and cyclosporine, though there was no improvement of dysplastic features [9]. In another study, a response to azacitidine was seen in two patients with co-existing DNMT3A mutations, but not in a patient with a TET2 mutation, suggesting targeted therapy dependent on MDS-related mutations may play a role [74].

Other supportive therapies that can be considered for improving VEXAS-associated cytopenias include erythropoietin stimulating agents (ESA) and the thrombopoietin receptor agonist eltrombopag. ESAs are used in low-risk MDS and have been found to be 70% effective if used when serum erythropoietin levels are <100 U/L, suggesting a potential role in VEXAS [75]. Eltrombopag has been found to increase haematopoiesis in both aplastic anaemia and low-risk MDS and may confer similar benefit, though it has not been studied in the context of VEXAS [76,77].

#### 8.4. Allogenic haematopoietic stem cell transplant

Increasingly, AHSCT has become a treatment option for all manner of haematological disease including non-malignant inherited and acquired disease, as in the case of VEXAS [78]. As a disease of older men, the VEXAS population would classically be regarded as high risk for post-transplant

complications including GVHD and infection. However, with the advent of reduced-intensity conditioning (RIC), age as a risk factor has been mostly nullified, with preceding performance status score, and co-morbid status, offering a higher predictive value for subsequent outcomes [67,79–81]. As a progressive inflammatory illness, performance status is likely to worsen over time and so early counselling and use of predictive tools for HCT will likely increasingly have a role, even in the early phase of treatment.

With regard to the reported success of AHSCT in VEXAS, results so far have been mixed. The first reported AHSCT in VEXAS was reported in the Mayo case series, whereby transplantation resulted in the resolution of the patients' arthritis and discontinuation of both tocilizumab and prednisolone [42]. In a French case series of six patients, five survived to the time of publication, though two of these had been followed up for less than 6 months [50]. Of the three patients followed up for 32 months or more, all were in complete disease remission, though two developed chronic GVHD [50]. In a UK case series of four patients receiving HSCT, only one patient survived in good health at 40 months, with one other developing marked disability (Karnofsky score 40) following Epstein–Barr virus reactivation and extensive GVHD, and the other two dying due to post transplant complications [56]. Notably, the patient who survived was identified retrospectively following HSCT for MDS and had not been treated for persistent inflammation despite multiple therapies, as was the case with the other three [56]. Similarly, all patients in the French series were treated on an indication of life-threatening autoinflammatory symptoms refractory to multiple therapies and this raises the question of whether patients with less severe, or better controlled, symptoms are likely to do better following transplantation [50]. A recent prospective series of five patients receiving reduced intensity conditioning AHSCT proposed a series of indications for the procedure by consensus and reported after a median follow up of 9.6 months that all patients were alive with normalisation of inflammatory markers and bone marrow morphology [82]. This study concluded that refractory inflammation, co-existent MDS and transfusion-dependent cytopenias were appropriate indications for HSCT and suggests a template for treatment protocols in the future [82]. As more cases present to clinic, collating this data to identify predictive values for outcomes post-HSCT will be essential to identify those most likely to benefit from the treatment.

## 9. Conclusion

Although VEXAS was identified less than 2 years ago, 150 different original articles, opinion pieces and reviews have already been published on this subject, reflecting the general medical interest this condition has generated. Initially thought to be quite rare, recent epidemiological work combined with anecdotal reporting around the world, suggest that VEXAS is significantly more prevalent than first assumed. More importantly, the underpinning pathological mechanism, which is based on somatic mutations, is likely to be more relevant for other non-malignant conditions. The concept of the cell/tissue specific pathological effects of somatic mutations in non-

malignant inflammatory conditions was also recently illustrated in patients with inflammatory bowel disease (IBD). Here, the cells from the mucosal epithelium were found to have frequent somatic mutations in several pathways relevant to the immune response to the resident microbiota [83–85]. Several different mechanisms have been proposed for how these mutations propagate disease pathogenesis and treatment resistance in IBD [86].

Establishing a diagnosis of VEXAS in previously undiagnosed cases has helped patients to cope psychologically with this debilitating condition and allows clinicians to develop a more informed management plan. However, robust evidence on ideal standard of care is still lacking. The aim of the medical community looking after patients with VEXAS should be to generate this missing evidence and formulate coherent treatment strategies over the coming years.

## 10. Expert opinion

The discovery of VEXAS syndrome has fundamentally changed our approach to the diagnosis, classification, and treatment of inflammatory disorders. The previous description of late onset NLRP3-associated autoinflammatory syndrome and the recognition that MDS is frequently associated with inflammatory complications, implied that acquired, leukocyte restricted, somatic mutations might have a role in the pathogenesis of a wider group of inflammatory conditions [87–90]. However, it was not until the discovery of VEXAS that this concept became a reality. The diversity of clinical manifestations associated with VEXAS is reflected by the wide range of diagnostic clinical criteria that patients appear to fulfill. Despite mimicking many rheumatological conditions, the uniqueness of VEXAS syndrome warranted introduction of a specific disease category – hematoinflammatory diseases, to reflect its particular immunopathogenesis. Broadly, these diseases are caused by somatic mutations restricted to the blood, but which cause systemic inflammation with multi-organ involvement and are associated with abnormal bone marrow changes [91]. The latter are typically pre-malignant states, such as myelodysplasia, with potential for malignant transformation. Other typical examples of hematoinflammatory diseases are histiocytoses. The concept of hematoinflammatory diseases is likely to be expanded to include less obvious examples. One such disease is arteriosclerosis, in which clonal haematopoiesis of indeterminate potential (CHIP), which develops with ageing, is associated with inflammatory damage to blood vessels which is typical of arteriosclerosis [92]. The CHIP is itself largely benign and rarely progresses to myelodysplasia. CHIP has also been shown to occur more frequently in patients with various rheumatological disorders [93,94]. However, the specific role of CHIP in the pathogenesis of these diseases, their progression, or the development of treatment resistance, remains unknown.

The genotype first approach, which led to discovery of VEXAS, demonstrates the power of genetic enquiry when applied to a large cohort of phenotypically well-characterised patients without a definitive diagnosis. The success of such an approach is likely to be replicated when applied to similar

cohorts, but the diagnosis of patients presenting with suspected late onset SAID, requires a different approach. For example, it might be necessary to combine deep sequencing of the whole exome (or ideally genome), using DNA obtained from various cellular or tissue locations to identify relevant somatic variants. This approach is currently used in the diagnosis of malignancies. Here, the genomic reference DNA sequence is obtained from skin fibroblasts and used to validate new somatic variants originating from lesional or malignant tissues. The difficulty in translating this approach into the investigation of inflammatory conditions is knowing which cell type or tissue might harbour the somatic variants in the first place. An additional challenge is confirming that such variants are indeed pathogenic. This might require additional functional tests but depending on which genes or biological pathways need to be studied, many of these tests might still need to be developed. Lastly, we might need to develop consensus criteria for the diagnosis of such disorders. These criteria are likely to include a combination of clinical characteristics and genetic findings. Until now, most newly diagnosed VEXAS patients appear to have broadly similar clinical features, but new pathogenic variants in *UBA1*, which are likely to be reported in the future, might be associated with a different or more restricted phenotype. This has already been suggested for patients harbouring the *UBA1* Ser56Phe variant [7].

The management of VEXAS syndrome is challenging. In part, this is due to the demographics of VEXAS population, largely consisting of elderly individuals with pre-existing comorbidities. A potentially greater challenge is the absence of robust studies informing best treatment choices or the development of treatment guidelines. As illustrated by [Figure 1](#), we have limited tools for predicting the clinical course or to identify those patients with more severe disease who may benefit from more aggressive treatment options such as HSCT. Furthermore, the risk factors which have been identified to predict worse outcomes, such as Met41Val variant and transfusion dependence, still need to be validated in prospective studies using larger cohorts of patients. The selection criteria for HSCT might also be inadequate since these are not VEXAS-specific but are based on the criteria for transplanting patients with high-risk MDS. In terms of transplantation, it is not known what effect the heightened inflammatory status associated with VEXAS might have on the bone marrow niche or its ability to accept donor cells, and whether these patients need a different conditioning regimen. The medical management of patients deemed to have a low-risk disease or who are not suitable for HSCT, is largely based on anecdotal evidence and retrospective cohort studies. There is emerging evidence from more robust, randomised studies, but these remain very limited [95]. Overall medical management might need to include supportive and preventative measures such as prevention of infections, which are a significant but under-recognized problem in VEXAS. Such measures are currently applied in an ad hoc fashion and their value is unknown since the utility of such approaches has not been tested in prospective studies.

Due to the rarity of VEXAS and the heterogeneity of its clinical manifestations, future clinical trials require a bespoke design to test various treatment options. Specific outcome

measures related to haematological, inflammatory and other manifestations of VEXAS will need to be developed. Furthermore, a platform-trial-based approach will also be necessary to test potentially several promising repurposed treatments simultaneously and adopt any advances from these trials into clinical practice in a timely manner.

## Funding

This paper was not funded.

## Declaration of interest

S Savic has received honoraria for advisory board participation and research grants from Novartis and SOBI. The authors have no other relevant affiliations or financial involvement with any organization or entity with a financial interest in or financial conflict with the subject matter or materials discussed in the manuscript apart from those disclosed.

## Reviewer disclosures

Peer reviewers on this manuscript have no relevant financial or other relationships to disclose.

## ORCID

Sinisa Savic  <http://orcid.org/0000-0001-7910-0554>

## References

**Papers of special note have been highlighted as either of interest (\*) or of considerable interest (\*\*) to readers.**

- Beck DB, Ferrada MA, Sikora KA, et al. Somatic Mutations in UBA1 and Severe Adult-Onset Autoinflammatory Disease. *N Engl J Med*. 2020;383(27):2628–2638.
- \*\* paper which describes discovery of VEXAS**
- Poulter JA, Savic S. Genetics of somatic auto-inflammatory disorders. *Semin Hematol*. 2021;58(4):212–217.
- Mustjoki S, Young NS, Longo DL. Somatic mutations in “Benign” disease. *N Engl J Med*. 2021;384(21):2039–2052.
- Patel BA, Ferrada MA, Grayson PC, et al. VEXAS syndrome: an inflammatory and hematologic disease. *Semin Hematol*. 2021;58(4):201–203.
- Callis J. The ubiquitination machinery of the ubiquitin system. *Arabidopsis Book*. 2014;12:e0174.
- Moudry P, Lukas C, Macurek L, et al. Ubiquitin-activating enzyme UBA1 is required for cellular response to DNA damage. *Cell Cycle*. 2012;11(8):1573–1582.
- Poulter JA, Collins JC, Cargo C, et al. Novel somatic mutations in UBA1 as a cause of VEXAS syndrome. *Blood*. 2021;137(26):3676–3681.
- first description of pSer56Phe pathogenic variant**
- Templé M, Duroyon E, Croizier C, et al. Atypical splice-site mutations causing VEXAS syndrome. *Rheumatology (Oxford)*. 2021;60(12):E435–E437.
- Bourbon E, Heiblig M, Gerfaud Valentin M, et al. Therapeutic options in VEXAS syndrome: insights from a retrospective series. *Blood*. 2021;137(26):3682–3684.
- Hetz C. The unfolded protein response: controlling cell fate decisions under ER stress and beyond. *Nat Rev Mol Cell Biol*. 2012;13:89–102. Doi: 10.1038/nrm3270.
- Ferrada MA, Savic S, Cardona DO, et al. Translation of cytoplasmic UBA1 contributes to VEXAS syndrome pathogenesis. *Blood*. 2022;140(13):1496–1506.

- manuscript describing the second largest cohort of VEXAS patients to date and also provides novel insights into pathogenesis of VEXAS**
- Kearse MG, Wilusz JE. Non-AUG translation: a new start for protein synthesis in eukaryotes. *Genes Dev*. 2017;31(17):1717–1731.
  - Georgin-Lavialle S, Terrier B, Guedon AF, et al. Further characterization of clinical and laboratory features in VEXAS syndrome: large-scale analysis of a multicentre case series of 116 French patients. *Br J Dermatol*. 2022;186(3):564–574.
  - description of the largest cohort of VEXAS patients to date**
  - Gurnari C, Mannion P, Pandit I, et al. UBA1 screening in sweet syndrome with hematological neoplasms reveals a novel association between VEXAS and chronic myelomonocytic leukemia. *HemaSphere*. 2022;6(10):e775.
  - Collins JC, Balanda N, Magaziner S, et al. Novel disease-causing mutations in UBA1 reveal disease mechanisms in Failure BM and Inflammation [Poster]. 64th ASH Annu Meet Expo, December 10–13, 2022, New Orleans, Louisiana.
  - description of new pathogenic variants in VEXAS**
  - Kusne Y, Fernandez J, Patnaik MM. Clonal hematopoiesis and VEXAS syndrome: survival of the fittest clones? *Semin Hematol*. 2021;58(4):226–229.
  - Hage-Sleiman M, Lalevée S, Guermouche H, et al. Dominance of an UBA1 mutant clone over a CALR mutant clone: from essential thrombocytopenia to VEXAS. *Haematologica*. 2021;106(12):3245–3248.
  - Bhavisha AP, Fernanda G-R, Yael K, et al. Clonal hematopoiesis in vexas syndrome [Poster]. 64th ASH Annu Meet Expo, December 10–13, 2022, New Orleans, Louisiana.
  - Beck DB, Werner A, Kastner DL, et al. Disorders of ubiquitylation: unchained inflammation. *Nat Rev Rheumatol*. 2022;18(8):435–447.
  - comprehensive review describing the role of ubiquitination in the pathogenesis of autoinflammatory disorders**
  - Patel N, Dulau-Florea A, Calvo KR. Characteristic bone marrow findings in patients with UBA1 somatic mutations and VEXAS syndrome. *Semin Hematol*. 2021;58(4):204–211.
  - Horton RK, Zheng G. A case of VEXAS syndrome with subtle morphologic findings. *Blood*. 2021;138(15):1378.
  - Grayson PC, Patel BA, Young NS. VEXAS syndrome. *Blood*. 2021;137(26):3591–3594.
  - Sun L, Babushok DV. Secondary myelodysplastic syndrome and leukemia in acquired aplastic anemia and paroxysmal nocturnal hemoglobinuria. *Blood*. 2020;136(1):36–49.
  - Templé M, Kosmider O. Syndrome: VEXAS. A Novelty in MDS Landscape. *Diagnostics (Basel)*. 2022;12:1590.
  - Medyouf H, Mossner M, Jann JC, et al. Myelodysplastic cells in patients reprogram mesenchymal stromal cells to establish a transplantable stem cell niche disease unit. *Cell Stem Cell*. 2014;14(6):824–837.
  - Li AJ, Calvi LM. The microenvironment in myelodysplastic syndromes: niche-mediated disease initiation and progression. *Exp Hematol*. 2017;55:3–18.
  - De Hollanda A, Beucher A, Henrion D, et al. Systemic and immune manifestations in myelodysplasia: a multicenter retrospective study. *Arthritis Care Res (Hoboken)*. 2011;63(8):1188–1194.
  - Poulter JA, Khan A, Martin S, et al. A high-throughput amplicon screen for somatic UBA1 variants in Cytopenic and Giant Cell Arteritis cohorts. *J Clin Immunol*. 2022;42(5):947–951.
  - Obiorah IE, Patel BA, Groarke EM, et al. Benign and malignant hematologic manifestations in patients with VEXAS syndrome due to somatic mutations in UBA1. *Blood Adv*. 2021;5(16):3203–3215.
  - Beck DB, Bodian DL, Shah V, et al. Genomic ascertainment for UBA1 variants and VEXAS syndrome: a population-based study. *medRxiv*. 2022.
  - manuscript describing prevalence of VEXAS in general population**
  - Ma X. Epidemiology of myelodysplastic syndromes. *Am J Med*. 2012;125(7 Suppl):S2.

32. Neukirchen J, Schoonen WM, Strupp C, et al. Incidence and prevalence of myelodysplastic syndromes: data from the Düsseldorf MDS-registry. *Leuk Res.* 2011;35(12):1591–1596.
33. Diarra A, Duployez N, Mutant TL. UBA1 and severe adult-onset autoinflammatory disease. *N Engl J Med.* 2021;384(22):2163–2164.
34. Barba T, Jamilloux Y, Durel CA, et al. VEXAS syndrome in a woman. *Rheumatology (Oxford).* 2021;60(11):E402–E403.
35. Stubbins RJ, McGinnis E, Johal B, et al. VEXAS syndrome in a female patient with constitutional 45,X (Turner syndrome). *Haematologica.* 2022;107(4):1011.
36. Tsuchida N, Kunishita Y, Uchiyama Y, et al. Pathogenic UBA1 variants associated with VEXAS syndrome in Japanese patients with relapsing polychondritis. *Ann Rheum Dis.* 2021;80(8):1057–1061.
37. Carrel L, Clemson CM, Dunn JM, et al. X inactivation analysis and DNA methylation studies of the ubiquitin activating enzyme E1 and PCTAIRE-1 genes in human and mouse. *Hum Mol Genet.* 1996;5(3):391–401.
38. van der Made CI, Potjewijd J, Hoogstins A, et al. Adult-onset autoinflammation caused by somatic mutations in UBA1: a Dutch case series of patients with VEXAS. *J Allergy Clin Immunol.* 2022;149(432–439.e4):432–439.e4.
39. Rasch MNB, Szabados F, Jensen JMB, et al. Patients with VEXAS diagnosed in a Danish tertiary rheumatology setting have highly elevated inflammatory markers, macrocytic anaemia and negative autoimmune biomarkers. *RMD Open.* 2022;8(2):e002492.
40. Islam S, Cullen T, Sumpton D, et al. VEXAS syndrome: lessons learnt from an early Australian case series. *Intern Med J.* 2022;52(4):658–662.
41. Muratore F, Marvisi C, Castrignanò P, et al. VEXAS syndrome: a case series from a single-center cohort of Italian patients with vasculitis. *Arthritis Rheumatol.* 2022;74(4):665–670.
42. Koster MJ, Kourelis T, Reichard KK, et al. Clinical heterogeneity of the VEXAS syndrome: a case series. *Mayo Clin Proc.* 2021;96(10):2653–2659.
43. Borie R, Debray MP, Guedon AF, et al. Pleuropulmonary manifestations of VEXAS syndrome. *Chest.* 2022. DOI:10.1016/J.CHEST.2022.10.011.
44. Cohen PR. Sweet's syndrome – a comprehensive review of an acute febrile neutrophilic dermatosis. *Orphanet J Rare Dis.* 2007;2:34.
45. Zakine E, Schell B, Battistella M, et al. UBA1 variations in neutrophilic dermatosis skin lesions of patients with VEXAS syndrome. *JAMA Dermatol.* 2021;157(11):1349–1354.
46. Lacombe V, Beucher A, Urbanski G, et al. Distinction between clonal and paraclonal cutaneous involvements in VEXAS syndrome. *Exp Hematol Oncol.* 2022;11(1). DOI:10.1186/540164-022-00262-5
47. Khitri MY, Guedon AF, Georgin-Lavialle S, et al. Comparison between idiopathic and VEXAS-relapsing polychondritis: analysis of a French case series of 95 patients. *RMD Open.* 2022;8(2):e002255.
48. Ferrada MA, Sikora KA, Luo Y, et al. Somatic mutations in UBA1 define a distinct subset of relapsing polychondritis patients with VEXAS. *Arthritis Rheumatol.* 2021;73(10):1886–1895.
  - **comparison between idiopathic RP and VEXAS-associated RP**
49. Watanabe R, Kiji M, Hashimoto M. Vasculitis associated with VEXAS syndrome: a literature review. *Front Med.* 2022;9. DOI:10.3389/FMED.2022.983939
50. Diarra A, Duployez N, Fournier E, et al. Successful allogeneic hematopoietic stem cell transplantation in patients with VEXAS syndrome: a 2-center experience. *Blood Adv.* 2022;6(3):998–1003.
  - **description of the largest case series of VEXAS patients undergoing hematopoietic stem cell transplantation**
51. Staels F, Betrains A, Woei-A-Jin S, et al. Case report: VEXAS syndrome: from mild symptoms to life-threatening macrophage activation syndrome. *Front Immunol.* 2021; 12(1):678927.
52. Magnol M, Couvaras L, Degboé Y, et al. VEXAS syndrome in a patient with previous spondyloarthritis with a favourable response to intravenous immunoglobulin and anti-IL17 therapy. *Rheumatology (Oxford, England).* 2021;60(9):e314–e315.
53. Grey A, Cheong PL, Lee FJ, et al. A case of VEXAS syndrome complicated by hemophagocytic lymphohistiocytosis. *J Clin Immunol.* 2021;41(7):1648–1651.
54. Rossignol J, Marzac C, Dellal A, et al. UBA1 gene mutation in giant cell arteritis. *Clin Rheumatol.* 2022;41(4):1257–1259.
55. Huang H, Zhang W, Cai W, et al. VEXAS syndrome in myelodysplastic syndrome with autoimmune disorder. *Exp Hematol Oncol.* 2021;10(1):1–5.
56. Al-Hakim A, Poulter JA, Mahmoud D, et al. Allogeneic hematopoietic stem cell transplantation for VEXAS syndrome: UK experience. *Br J Haematol.* 2022;199(5):777–781.
57. Lytle A, Bagg A. VEXAS: a vivid new syndrome associated with vacuoles in various hematopoietic cells. *Blood.* 2021;137(26):3690.
58. Groarke EM, Dulau-Florea AE, Kanthi Y. Thrombotic manifestations of VEXAS syndrome. *Semin Hematol.* 2021;58(4):230–238.
59. K A, A D, G K. Inflammation-induced thrombosis: mechanisms, disease associations and management. *Curr Pharm Des.* 2012;18(11): 1478–1493.
60. Branchford BR, Carpenter SL. The role of inflammation in venous thromboembolism. *Front Pediatr.* 2018;6:142.
61. Fuchs TA, Brill A, Duerschmied D, et al. Extracellular DNA traps promote thrombosis. *Proc Natl Acad Sci U S A.* 2010;107(36):15880–15885.
62. Yu S, Liu J, Yan N. Endothelial dysfunction induced by extracellular neutrophil traps plays important role in the occurrence and treatment of extracellular neutrophil traps-related disease. *Int J Mol Sci.* 2022;23. DOI:10.3390/IJMS23105626
63. Le Joncour A, Martos R, Loyau S, et al. Critical role of neutrophil extracellular traps (NETs) in patients with Behcet's disease. *Ann Rheum Dis.* 2019;78(9):1274–1282.
64. Nakazawa D, Masuda S, Tomaru U, et al. Pathogenesis and therapeutic interventions for ANCA-associated vasculitis. *Nat Rev Rheumatol.* 2019;15(2):91–101.
65. Misra DP, Thomas KN, Gasparyan AY, et al. Mechanisms of thrombosis in ANCA-associated vasculitis. *Clin Rheumatol.* 2021;40(12):4807–4815.
66. Patel BA, Young NS. Towards treatments for VEXAS. *Br J Haematol.* 2022;196(4):804–805.
67. Heiblig M, Patel BA, Groarke EM, et al. Toward a pathophysiology inspired treatment of VEXAS syndrome. *Semin Hematol.* 2021;58(4):239–246.
68. Artz AS, Wickrema A, Dinner S, et al. Pretreatment C-reactive protein is a predictor for outcomes after reduced-intensity allogeneic hematopoietic cell transplantation. *Biol Blood Marrow Transplant.* 2008;14(11):1209–1216.
69. Fuji S, Kim SW, Fukuda T, et al. Preengraftment serum C-reactive protein (CRP) value may predict acute graft-versus-host disease and nonrelapse mortality after allogeneic hematopoietic stem cell transplantation. *Biol Blood Marrow Transplant.* 2008;14(5):510–517.
70. Lankester AC, Albert MH, Booth C, et al. Perspective EBMT/ESID inborn errors working party guidelines for hematopoietic stem cell transplantation for inborn errors of immunity on behalf of the for Blood and Marrow Transplantation and the European Society inborn errors working party of the European society for immune deficiencies, and European reference network on Rare Primary Immunodeficiency Autoinflammatory Autoimmune diseases (RITA). DOI:10.1038/s41409-021-01378-8
71. Heiblig M, Ferrada MA, Koster MJ, et al. Ruxolitinib is more effective than other JAK inhibitors to treat VEXAS syndrome: a retrospective multicenter study. *Blood.* 2022;140(2):140.
  - **largest case series of VEXAS patients treated with JAK inhibitors**
72. Fraison JB, Mekinian A, Grignano E, et al. Efficacy of Azacitidine in autoimmune and inflammatory disorders associated with myelodysplastic syndromes and chronic myelomonocytic leukemia. *Leuk Res.* 2016;43:13–17.
73. Comont T, Heiblig M, Rivière E, et al. Azacitidine for patients with Vacuoles, E1 Enzyme, X-linked, Autoinflammatory, Somatic syndrome (VEXAS) and myelodysplastic syndrome: data from the French VEXAS registry. *Br J Haematol.* 2022;196(4):969–974.
74. Raaijmakers MHGP, Hermans M, Aalbers A, et al. Azacitidine treatment for VEXAS syndrome. *HemaSphere.* 2021;5(12):e661.

75. Hellström-Lindberg E, Gulbrandsen N, Lindberg G, et al. A validated decision model for treating the anaemia of myelodysplastic syndromes with erythropoietin + granulocyte colony-stimulating factor: significant effects on quality of life. *Br J Haematol.* **2003**;120(6):1037–1046.
76. Patel BA, Groarke EM, Lotter J, et al. Long-term outcomes in patients with severe aplastic anemia treated with immunosuppression and eltrombopag: a phase 2 study. *Blood.* **2022**;139(1):34–43.
77. Vicente A, Patel BA, Gutierrez-Rodriguez F, et al. Eltrombopag monotherapy can improve hematopoiesis in patients with low to intermediate risk-1 myelodysplastic syndrome. *Haematologica.* **2020**;105(12):2785–2794.
78. Passweg JR, Baldomero H, Chabannon C, et al. Hematopoietic cell transplantation and cellular therapy survey of the EBMT: monitoring of activities and trends over 30 years. *Bone Marrow Transplant.* **2021**;56(7):1651–1664.
79. Lim Z, Brand R, Martino R, et al. Allogeneic hematopoietic stem-cell transplantation for patients 50 years or older with myelodysplastic syndromes or secondary acute myeloid leukemia. *J Clin Oncol.* **2010**;28(3):405–411.
80. McClune BL, Weisdorf DJ, Pedersen TL, et al. Effect of age on outcome of reduced-intensity hematopoietic cell transplantation for older patients with acute myeloid leukemia in first complete remission or with myelodysplastic syndrome. *J Clin Oncol.* **2010**;28(11):1878–1887.
81. Heidenreich S, Ziagkos D, de Wreede LC, et al. Allogeneic stem cell transplantation for patients age  $\geq$  70 Years with myelodysplastic syndrome: a retrospective study of the MDS subcommittee of the chronic malignancies working party of the EBMT. *Biol Blood Marrow Transplant.* **2017**;23(1):44–52.
82. Mangaonkar AA MBBS, Langer KJ APRN, Lasho TL, et al. Reduced intensity conditioning allogeneic hematopoietic stem cell transplantation in VEXAS syndrome: data from a prospective series of patients. *Am J Hematol.* **2022**;1096–8652.
- **first prospective case series of VEXAS patients undergoing hematopoietic stem cell transplantation**
83. Kakiuchi N, Yoshida K, Uchino M, et al. Frequent mutations that converge on the NFKBIZ pathway in ulcerative colitis. *Nature.* **2020**;577(7789):260–265.
84. Nanki K, Fujii M, Shimokawa M, et al. Somatic inflammatory gene mutations in human ulcerative colitis epithelium. *Nature.* **2020**;577(7789):254–259.
85. Olafsson S, McIntyre RE, Coorens T, et al. Somatic evolution in non-neoplastic IBD-affected colon. *Cell.* **2020**;182(3):672–684.e11.
86. Olafsson S, Anderson CA. Somatic mutations provide important and unique insights into the biology of complex diseases. *Trends Genet.* **2021**;37(10):872–881.
87. Rowczenio DM, Gomes SM, Aróstegui JI, et al. Late-onset cryopyrin-associated periodic syndromes caused by somatic NLRP3 mosaicism-UK single center experience. *Front Immunol.* **2017**;8:1410.
88. Zhou Q, Aksentjevich I, Wood GM, et al. Brief report: cryopyrin-associated periodic syndrome caused by a myeloid-restricted somatic NLRP3 mutation. *Arthritis Rheumatol (Hoboken, NJ).* **2015**;67(9):2482–2486.
89. Mekinian A, Grignano E, Braun T, et al. Systemic inflammatory and autoimmune manifestations associated with myelodysplastic syndromes and chronic myelomonocytic leukaemia: a French multi-centre retrospective study. *Rheumatology (Oxford).* **2015**;55(2):291–300.
90. Watad A, Kacar M, Bragazzi NL, et al. Somatic mutations and the risk of undifferentiated autoinflammatory disease in MDS: an under-recognized but prognostically important complication. *Front Immunol.* **2021**;12. DOI:10.3389/FIMMU.2021.610019.
91. Grayson PC, Beck DB, Ferrada MA, et al. Disease taxonomy in rheumatology. *Arthritis Rheumatol (Hoboken, NJ).* **2022**;74:11. DOI:10.1002/ART.42258.
- **introduction of hematoinflammatory disease concept**
92. Páramo Fernández JA. Atherosclerosis and clonal hematopoiesis: a new risk factor. *Clin Investig Arterioscler.* **2018**;30(3):133–136.
93. Hecker JS, Hartmann L, Rivière J, et al. CHIP and hips: clonal hematopoiesis is common in patients undergoing Hip arthroplasty and is associated with autoimmune disease. *Blood.* **2021**;138(18):1727–1732.
94. Ricard L, Hirsch P, Largeaud L, et al. Clonal haematopoiesis is increased in early onset in systemic sclerosis. *Rheumatology.* **2020**;59(11):3499–3504.
95. Mekinian A, Zhao LP, Chevret S, et al. A Phase II prospective trial of azacitidine in steroid-dependent or refractory systemic autoimmune/inflammatory disorders and VEXAS syndrome associated with MDS and CMML. *Leuk.* **2022**;36(11):2739–2742.