



UNIVERSITY OF LEEDS

This is a repository copy of *The outcomes of auto-transplanted premolars into the anterior maxilla following traumatic dental injuries*.

White Rose Research Online URL for this paper:

<https://eprints.whiterose.ac.uk/196351/>

Version: Accepted Version

Article:

Albalooshy, A, Duggal, M, Vinnall-Collier, K et al. (2 more authors) (2023) The outcomes of auto-transplanted premolars into the anterior maxilla following traumatic dental injuries. *Dental Traumatology*, 39 (S1). pp. 40-49. ISSN 1600-4469

<https://doi.org/10.1111/edt.12829>

This article is protected by copyright. All rights reserved. This is the peer reviewed version of the following article: Albalooshy, A., Duggal, M., Vinnall-Collier, K., Drummond, B. and Day, P. (2023), The outcomes of auto-transplanted premolars into the anterior maxilla following traumatic dental injuries. *Dental Traumatology*. Accepted Author Manuscript, which has been published in final form at <https://doi.org/10.1111/edt.12829>. This article may be used for non-commercial purposes in accordance with Wiley Terms and Conditions for Use of Self-Archived Versions. This article may not be enhanced, enriched or otherwise transformed into a derivative work, without express permission from Wiley or by statutory rights under applicable legislation. Copyright notices must not be removed, obscured or modified. The article must be linked to Wiley's version of record on Wiley Online Library and any embedding, framing or otherwise making available the article or pages thereof by third parties from platforms, services and websites other than Wiley Online Library must be prohibited.

Reuse

Items deposited in White Rose Research Online are protected by copyright, with all rights reserved unless indicated otherwise. They may be downloaded and/or printed for private study, or other acts as permitted by national copyright laws. The publisher or other rights holders may allow further reproduction and re-use of the full text version. This is indicated by the licence information on the White Rose Research Online record for the item.

Takedown

If you consider content in White Rose Research Online to be in breach of UK law, please notify us by emailing eprints@whiterose.ac.uk including the URL of the record and the reason for the withdrawal request.



eprints@whiterose.ac.uk
<https://eprints.whiterose.ac.uk/>

The outcomes of auto-transplanted premolars in the anterior maxilla following traumatic dental injuries

Authors' names:

Amal Albaloochy¹  | Monty Duggal² | Karen Vinall-Collier³  | Bernadette Drummond³
| Peter Day^{3,4}

Affiliations:

¹College of Dentistry, Taif University, Taif, Saudi Arabia

²College of Dental Medicine, QU Health, Qatar University, Doha, Qatar

³Faculty of Medicine and Health, University of Leeds, Leeds, United Kingdom

⁴Community Dental Service, Bradford District Care NHS Foundation Trust, Bradford, United Kingdom.

Correspondence:

Amal Albaloochy, Assistant Professor in Paediatric Dentistry, Department of Preventive Dental Sciences, College of Dentistry, Taif University, P.O Box 11099, Taif 21944, Saudi Arabia, (amal.m@tu.edu.sa).

Acknowledgments:

The authors would like to acknowledge Taif University for their financial support, We would also like to acknowledge the invaluable support provided by Dr Brenda Murray, a consultant radiologist for her help in assessing dental radiographs, and to the multi-disciplinary transplant team at Leeds Dental Institute for their help in identifying and accessing the dental records. In Leeds, tooth auto-transplantation is undertaken by a multi-disciplinary team including, orthodontists, restorative dentists and oral surgeons. We would like to thank our colleagues, including Drs Nadine Houghton, Hannah Beddis and Richard Moore and Dr Jing (Biostatistician), whose expertise and teamwork has contributed to the cohort of patients we have reported on.

conflict of interest:

The authors confirm that they have no conflict of interest.

Orchid:

Amal Albaloochy: <https://orcid.org/0000-0003-2368-9261>

Monty Duggal: <https://orcid.org/0000-0002-8052-0676>

Karen Vinall-Collier: <https://orcid.org/0000-0001-6362-9824>

Peter Day: <https://orcid.org/0000-0001-9711-9638>

Abstract

Background/ Aims: Tooth auto-transplantation is a treatment option which is often not considered to replace anterior maxillary incisors in children and adolescents. There are multiple prognostic factors that may influence the outcomes of premolar auto-transplantation but there is limited evidence from human studies. The aim of this study was to report the outcomes of auto-transplanted premolars in the anterior maxilla following traumatic dental injuries (TDI) and to identify their prognostic factors.

Materials and Methods: The clinical records of patients who had premolars transplanted in the anterior maxilla following TDI, with appropriate radiographs and a minimal of one year follow up, were reviewed retrospectively. A specific data extraction form was developed, tested, and used to collect information for the prognostic factors and outcomes.

Results: The cohort included 120 patients with 144 auto-transplanted premolars. The mean age was 12.2 years (± 2.0), and the mean observation period was 3.7 years (± 1.8). The success rate was 80% and the survival rate was 93%. Unfavourable outcomes included external replacement resorption in 12.5%, uncontrolled external inflammatory resorption in 2.7% and both resorption types in 4.9% of teeth. Periodontal healing was significantly associated with donor tooth root maturity, graft handling at the time of surgery including ease of donor tooth extraction and placement at the recipient sites, recipient site alveolar bone status and post-operative transplant mobility. Seventy four teeth (53.4%) were immature at the time of transplantation where pulp revascularisation was anticipated and 52 (70%) of those had radiographic and clinical signs of pulp healing. Pulp healing was significantly related to donor tooth eruption stage, ease of extraction of donor tooth and ease of placement in the recipient site.

Conclusions: Good outcomes were observed for premolar teeth auto-transplanted in the anterior maxilla. The main prognostic factors were ease extraction of donor tooth and ease of placement in the recipient sites and donor tooth root maturity.

Key words: auto-transplantation, pulp healing, periodontal healing, traumatic dental injuries and incisors

1 | INTRODUCTION

Tooth auto-transplantation is where a tooth is extracted and transplanted to another site within the same individual.¹ Over the years, there have been significant improvements in the understanding of post operative healing and surgical techniques, making this a potentially more predictable treatment option especially for a young population, albeit not a widely used one. Worldwide, its popularity has been seen almost exclusively in developed countries and particularly in Scandinavian countries, Belgium, Japan and the UK.²⁻⁸ Despite relative popularity in these countries, many clinicians are unaware of this treatment option.³

Although dental implants are now widely used, auto-transplantation is a biologic option, especially during the period of growth and development. It can provide functional adaptation, alveolar ridge preservation and continuous induction of alveolar bone, periodontium and gingiva at the recipient sites.⁸⁻¹³ Following a successful procedure, the auto-transplanted teeth regain their proprioceptive function and normal periodontal ligament function within the growing dental arch.^{14, 15} As auto-transplantation is usually undertaken in patients who have a malocclusion, transplanted teeth which heal with a normal periodontium, can undergo orthodontic tooth movement in contrast to dental implants which osseointegrated with the bone.¹² Previous studies have also reported that auto-transplantation can provide good aesthetics by maintaining the attached keratinized gingiva and they are cost effective¹⁶⁻¹⁸, although there is little literature that has explored the long term aesthetics of auto-transplanted teeth.¹⁹ Placing auto-transplants in the anterior maxillary region following traumatic dental injuries can be difficult especially in cases with alveolar bone atrophy.¹⁶ In addition, placing a single transplanted tooth next to the adjacent teeth is especially challenging as masking the transplanted premolar requires careful aesthetic management, due to the premolar crowns being narrower at the gingival third and more rounded labially.¹²

Few studies have reported the success rate of premolar auto-transplantation in the anterior maxilla following TDI. Most studies in the literature have reported between 12 to 45 cases, with success rates between 70-100% and follow up periods of 1- 41 years.²⁰⁻²⁶ Like any treatment option, auto-transplantation can have complications, that can lead to failure and tooth loss, such as external replacement resorption, uncontrolled external inflammatory resorption and alveolar bone loss.²⁷ Understanding what pre-, peri- and post-operative factors are associated with successful and unsuccessful outcomes is critical and can help to improve success rates.

The aims of this retrospective study were:

- To evaluate the outcomes of premolar auto-transplantation in the anterior maxilla, following traumatic dental injuries for children and adolescents.
- To identify the prognostic clinical and radiographic factors that were associated with the periodontal and pulp healing outcomes of the auto-transplanted premolars.

2 | MATERIALS AND METHODS

Ethical approval was obtained from the Northwest - Greater Manchester East Research Ethics Committee (16/NW/0155). The cohort study included clinical and radiographic records for patients in whom premolar auto-transplants had been placed in the anterior maxilla were reviewed retrospectively. Auto-transplantation procedures were undertaken between 2000 and 2019, with follow-up census date of February 2020. To be included in the cohort, the records needed to have appropriate periapical radiographs for both the donor and recipient sites as well as clinical and radiographic records for a minimum of one year follow up after tooth auto-transplantation.

A specific data extraction form was used to collect the patient's demographic details and the diagnostic, clinical and treatment factors that were recorded in the clinical notes. These are shown in Table 1.

The outcomes of the auto-transplanted teeth were assessed based on both clinical and radiographic examinations at the last review visit. Periodontal healing was considered to be favourable clinically if there was normal tooth mobility, no tenderness on percussion and normal percussion sound. In addition, radiographic examination revealed evidence of intact root surface, normal periodontal tissues including continuous periodontal ligament space and intact lamina dura. External inflammatory (infection-related) resorption that was treated effectively (e.g., no further progressive resorption) or external surface (repair-related) resorption. However, presence of pathologic mobility or high percussion sound suggestive of ankylosis during clinical examination were considered to be unfavourable healing. In addition, radiographic evidence of widening of the periodontal ligament space, loss of lamina dura and presence of external replacement resorption and ankylosis.

Pulp healing was considered to be favourable clinically if there was positive response to sensibility tests (cold spray and electric pulp test) and absence of pathological signs (abscess, draining sinus) or symptoms (pain and history of irreversible pulpitis). If a negative sensibility response was recorded but no other signs or symptoms suggesting pulp necrosis were present, the pulp was considered to have healed favourably. In addition, presence of partial or complete pulp canal calcification according to Jacobsen and Kerekes classification (1977)²⁸, or evidence of continued root development on radiographic examination. However, unfavourable healing included clinical evidence of abscess and/or draining sinus, history of pain suggesting irreversible pulpitis. In addition, radiographic examination showed presence of periapical radiolucency or external inflammatory resorption and/or arrested root development.

Pathological gingival changes in particular gingival recession had been recorded in the dental notes by measuring the distance from gingival margin and the cemento-enamel junction of the

exposed root surface.²⁹ Gingival healing was considered to have been favourable if normal gingival colour, contour, shape, and consistency and absence of gingivitis were recorded in the notes.

The following criteria were used to determine survival and success at the time of assessment according to previous tooth auto-transplantation literature.^{9, 30, 31} The survival criterion was the auto-transplanted tooth was present in the mouth at the last review appointment. The success criteria were favourable clinical and radiographic pulp and periodontal healing, and successful endodontic outcomes for those transplanted teeth that had completed root development at the time of transplantation, or those teeth with incomplete root development where the pulp that had become necrotic and infected.

The data was entered into SPSS (Statistical Package for the Social Sciences- version 27, SPSS Inc, Chicago, USA) for data analysis. Descriptive statistics were followed up with subject level analysis in cases where two teeth had been transplanted in the same patient, with one transplant randomly selected for analysis. Univariate analysis including Chi-square or Fisher's Exact tests were used to examine the association between the prognostic factors and the outcomes for pulp healing and periodontal healing. To examine which prognostic factors had the strongest association with the outcomes, multivariate binary logistic regression analysis was undertaken, and statistical regression models were built for the outcomes of periodontal healing and pulp healing. Only the prognostic factors that had statistical significance in the univariate analysis were included in the regression models.

3 | RESULTS

A total of 120 patient records were identified, and 24 of those cases had two teeth auto-transplanted. Therefore, the total number of auto-transplanted teeth was 144. The mean age at auto-transplantation was 12.2 years (\pm 2 years) with a range of 9-20 years. The mean

observation period was 3.7 years (\pm 1.8 years), with a range of 1-10.4 years. All the donor teeth in this cohort were premolars and were transplanted by paediatric dentists in the anterior maxillary area following a TDI. The TDI's that had led to tooth loss and for which auto-transplantation had been carried out included avulsions (n=84), intrusions (n=23), root fractures (n=12), complicated crown-root fractures (n=10), extrusions (n=8) and lateral luxations (n=7).

Table 2 shows the various tooth and treatment related factors recorded for each auto-transplanted tooth. The majority of the auto-transplanted teeth were stabilised with a Titanium Trauma Splint (*Medartis AG, Basel, Switzerland*). The mean duration of the stabilisation period was 11.5 days (+ 3.5 days).

Twenty nine auto-transplanted teeth (20%) had unfavourable periodontal healing. This was recorded as being due to external replacement resorption in 18 cases (12.5%), uncontrolled external inflammatory resorption in four (2.7%), and both types of resorption types in seven (4.9%) cases.

Ninety two auto-transplanted teeth (62.9%) required endodontic treatment. Of these, 70 (48.6%) had completed root development at the time of the surgery and elective pulp extirpation was initiated post-operatively. Of the total sample of 74 teeth with incomplete root development at the time of the procedure, 22 (29.7%) required endodontic treatment with 52 (70.3%) demonstrating pulp healing. Figure 1 shows the progression of donor tooth apical maturity at three different time points including at the time of the surgery, 12-months and at the last review.

All auto-transplanted teeth that had continued root development had varying degrees of pulp canal calcification 32 (61.5%) had partial pulp canal calcification and 20 (38.4%) had complete pulp canal calcification based on radiographic appearance.

One hundred and seven (74.3%) auto-transplanted teeth had healthy gingiva. However, 28 (19.4%) had gingivitis, 4 (2.7%) had gingival recession and 5 (3.4%) had both gingivitis and gingival recession.

Regarding the success and survival rates, 80% of the auto-transplanted teeth were considered to meet the criteria for success but 93% met the criteria for survival. Ten auto-transplanted teeth had been extracted due to reasons of either infection or severe resorption.

Univariate analysis was conducted to examine the association between the prognostic factors, periodontal healing and pulp healing outcomes (Table 1). The analysis was carried out at a subject level. For subjects receiving two transplants, one was randomly selected and included in the analysis. Therefore, the following univariate and regression models are based on 120 transplanted teeth.

The variables with a significant relationship to periodontal healing are shown in Table 3. These variables included: donor tooth eruption stage at surgery, donor tooth stage of apical maturity, donor tooth root length, recipient site alveolar bone status, graft handling and placement at the recipient, socket preparation at recipient sites, type of socket preparation, degree of transplant mobility following splint removal and reasons for root canal treatment.

Pulp revascularisation was expected to occur in 63 auto-transplanted teeth but only occurred in 46 teeth. The following variables were significantly associated with pulp revascularisation: donor tooth eruption stage, graft handling and placement at the recipient site and alveolar bone status at the recipient sites (Table 4).

The relationship between the significant factors and the outcomes of periodontal healing and pulp healing were examined by building binomial logistic (multi-variate) regression models.

Only factors that were significant in the univariate analysis were included in further analysis. For periodontal healing, a binomial logistic regression was performed to ascertain the effects of donor tooth apical maturity, recipient site alveolar bone status, ease of extraction of the donor tooth, recipient site socket preparation, ease of placement of the donor tooth at the recipient site, transplant mobility following splint removal and reasons for endodontic treatment on the likelihood that auto-transplanted teeth had unfavourable periodontal healing. A high collinearity relationship was found among donor tooth root length, donor tooth eruption stage and donor tooth stage of root development. Therefore, only donor tooth apical maturity was included in the regression model. In addition, collinearity was found to be high between socket preparation and type of socket preparation. Therefore, only socket preparation was included in the regression model. The explained variation in the dependent variable in this model was 70.3% according to Nagelkerke R Square. Of the seven variables, five were statistically significantly related to periodontal healing as shown in Table 5.

Donor teeth with divergent apical walls had 0.015 (95% CI, 0.000- 0.925) lower odds to exhibit unfavourable periodontal healing than completely developed roots. In addition, recipient sites with sufficient bone levels had 0.006 (95% CI, 0.000- 0.632) lower odds to exhibit unfavourable periodontal healing compared with sites with deficient bone. In addition, ease of extraction of the donor tooth (OR=0.023 with 95% CI, 0.002- 0. 401), ease of placement of the donor tooth at the recipient site (OR=0.034 with 95% CI, 0.001- 0. 543) and normal to grade I mobility following splint removal (OR= 0.148 with 95% CI, 0. 024 – 0. 901) were associated with a decreased likelihood of unfavourable periodontal healing.

For pulp healing, the analysis was performed to ascertain the effects of donor tooth eruption stage, ease of extraction of the donor tooth, ease of placement of the donor tooth at recipient site and recipient site alveolar bone status on the likelihood that auto-transplanted teeth had pulp necrosis. No collinearity was found among the covariates. The explained variation in the

dependent variable in this model was 62.4% according to Nagelkerke R Square. Of the four predictor variables, three were statistically significant as shown in Table 6.

Partially erupted donor teeth had 0.048 (95% CI, 0.004 – 0.466) lower odds of exhibiting pulp necrosis than fully erupted donor teeth. In addition, donor teeth with easy extraction (OR=0.037 with 95% CI, 0.002 – 0.816) and easy placement at the recipient site (OR=0.086 with 95% CI, 0.011 – 0.556) were associated with a decrease the likelihood of pulp necrosis.

Both validity and reliability for this study were assessed. For validity, 10% of the cases (n=14) were randomly selected to examine inter-examiner agreement. The radiographs were assessed by both a consultant radiologist and the chief investigator (AA) separately. This exercise was undertaken two weeks after the original data collection. Kappa score for inter-examiner agreement was 0.90 which suggests ‘almost perfect agreement’.

For reliability, 10% of the cases (n=14) were randomly selected to examine intra-examiner agreement. A specific feature of SPSS version 27 software was used to randomly identify these cases. The chief investigator (AA) examined the dental records and radiographs at two separate time points, four weeks apart. Kappa score for intra-examiner agreement was 1.0 which suggests ‘total agreement’.

4 | DISCUSSION

This is the largest reported cohort of auto-transplanted premolars in the anterior maxilla following severe dentoalveolar injuries in children and adolescents during their period of growth and development. One of the drawbacks of this study is that it is a single site study and the collection of data depended on the accuracy of the dental records that were available for each subject. The Centre in which this study was carried out is an established clinical unit where auto-transplantation is carried out routinely, and record keeping is fairly standardised for all patient records.

The mean age of the patients at the auto-transplantation time was 12.2 ± 2.0 years. This is considered to be an ideal time for auto-transplantation of immature premolars prior to completion of root development which happens around 13-14 years of age.³² Of the prognostic factors evaluated, donor tooth eruption stage, and apical root maturity were the best predictors for favourable pulp and periodontal healing. It has been reported that the stage of root development is as significant as the eruption stage and these two variables were highly correlated.³³ Continued root development following auto-transplantation was obvious in stages 3 and 4 of the Moorrees et al. classification.³⁴ This is equivalent to divergent and parallel apical walls which were recorded in this study. In addition, auto-transplanted teeth with open apices had better periodontal healing compared with teeth with closed apices. This finding is consistent with published data.³³

Pulp canal calcification is a normal and well accepted radiographic sign for pulp healing. It is a result of connective tissue ingrowth into the pulp from the periapical tissues.^{35, 36} Fifty two auto-transplanted teeth that had continued root development showed pulp canal calcification in this study. This ranged from partial to complete calcification and the results are similar to other results reported in the literature.³⁵⁻³⁸ It is noteworthy that pulp revascularisation was higher in donor teeth that were unerupted at the time they were transplanted, compared to partially or fully erupted donor teeth. A possible explanation for that could be related to apical root maturity as unerupted and partially erupted donor teeth have more immature root forms than fully erupted donor teeth. A recent retrospective cohort study of 58 auto-transplanted premolars in the Netherlands found that auto-transplanted teeth with wide open apices (>2 mm) had more root elongated compared to narrower apices.³⁹

To ensure favourable pulp and periodontal healing for auto-transplanted teeth, minimal trauma to Hertwig's epithelial root sheath is essential during donor tooth extraction, socket preparation and transplant placement at the recipient site.⁴⁰ In the current study teeth that reported to be relatively ease to extract and place had better periodontal and pulp-healing

than those recorded as being difficult. Therefore, it is important to ensure the preservation of healthy and viable periodontal ligament cells on the transplanted root surface and extraction technique should be as atraumatic as possible.^{10, 35} If unfavourable periodontal ligament healing takes place, the risk of root resorption will increase.¹⁰ In the present study although both external replacement and inflammatory resorption were seen, the overall prevalence was low and consistent with a published systematic review and meta analysis⁴¹ where the rates of resorption were reported to be between 4.2-18% for replacement root resorption and between 3-10% for external inflammatory resorption.

Repeatedly trying the graft for fit at the recipient site increases the extra-alveolar time. Subsequently this would compromise periodontal healing as a result of increased trauma and damage to the Hertwig's epithelial root sheath of the donor tooth^{33, 42, 43} plus it may increase the risk of bacterial contamination which would jeopardise pulp healing.⁴⁴ Therefore, to minimise these risks, it is essential to use surgical templates. A previous study has reported the design and construction of surgical templates for premolar auto-transplantation of 125 premolars.⁴⁵ However, it is more common to use more modern imaging and 3D printing to construct such templates.¹⁷

Other important factors found to be associated with periodontal healing in the present study were transplant mobility and recipient alveolar bone status. The majority of the auto-transplanted teeth had grade I mobility following splint removal. Auto-transplanted teeth with normal to grade I mobility at the time of splint removal had higher rates of periodontal healing than those with grade II and III mobility. Most previous studies have reported normal mobility following auto-transplantation.^{31, 35, 46, 47} The association between the mobility and periodontal healing for auto-transplanted teeth at the time of splint removal has not been previously studied. In this study, recipient site alveolar bone status was found (prior to or during surgery) to be either sufficient or deficient. The recipient site alveolar bone status was

significantly associated with periodontal healing, but no previously published association was found.

Gingival healing was another evaluated outcome in the current study. Thirty three auto-transplanted teeth had been recorded as having gingival recession. Although gingival recession is irreversible and if it occurs in the anterior teeth would result in poor emergence profile and subsequently poor aesthetics, no previous studies were found reporting this outcome for premolars in the anterior maxilla. Data reported for transplanted canines shows the prevalence of gingival recession was around 12%.⁴⁸ The causes of gingival recession can be considered as multifactorial, related to the anatomy such as thin gingival biotype, insufficient attached gingiva, presence of bone dehiscence at the recipient sites or failure to position the auto-transplanted teeth within the gingival and bony pocket at the recipient site in either the vertical or axial directions. In addition, it could be related to periodontal disease leading to an exposure of the root surface.⁴⁹ As most transplanted teeth in this study were placed subsequent to tooth loss related to dental trauma, gingival recession in cases reported in this cohort was probably due to the relatively limited bone at the recipient site.

In this retrospective study, the success and survival rates were evaluated based on the criteria that were defined according to previous studies.^{32,37} The success and survival rates reported (80% and 93% respectively) are similar to those published in the literature.²⁰⁻²⁶

Although retrospective cohort studies are useful for evaluating prognostic factors, determining the incidence and the causality of an exposure and measuring multiple outcomes in the same exposure longitudinally⁵⁰, they are limited by some methodological weaknesses. Selection bias is one example, as some participants may not return for regular review visits.⁵¹

In addition, the cohort study's retrospective design makes it reliant on the recorded data and usually the recorded information was not gathered for research purposes. Consequently,

some variables were not recorded in all cases, creating a potential information bias. Also, this study was predisposed to misclassification bias as the data from dental notes that were recorded by a variety of clinicians, including postgraduate students, registrars, and consultants, with varying levels of clinical expertise. In addition, some variables and confounders that might have higher influence on the outcome may not have been recorded at all.⁵² The unavailability of information on confounders could also have led to unknown and unnoticed biases. However, the large sample included in this cohort has provided a robust dataset to support statistical analysis. In addition, the centre where the study was carried out is a well-established centre for auto-transplantation, and clinical record keeping is fairly standardised. For the variables that were used to define success and survival most of the required data had been recorded.

5 | CONCLUSIONS

Premolar auto-transplantation in the anterior maxilla had good success and survival rates and should be considered a viable biological option for tooth replacement in growing patients. Both periodontal healing and pulp healing were highly influenced by graft handling during the surgery including ease of extraction of the donor tooth and ease of placement at the recipient sites. In addition, donor tooth root maturity.

6 | REFERENCES

1. Natiella JR, Armitage JE, Greene GW. The replantation and transplantation of teeth. A review. *Oral Surg Oral Med Oral Pathol.* 1970;29:397-419.
2. Andreasen J, Paulsen H, Yu Z, Ahlquist R, Baye T, Schwartz O. A long term study of 370 autotransplanted premolars. Part I. Surgical procedures and standardized techniques for monitoring healing. *Eur J Orthod.* 1990a;12:3-13.
3. Tsukiboshi M, Yamauchi N, Tsukiboshi Y. Long-term outcomes of autotransplantation of teeth: a case series. *J Endod.* 2019;45:S72-S83.

4. Lundberg T, Isaksson S. A clinical follow-up study of 278 autotransplanted teeth. *Br J Oral Maxillofac Surg.* 1996;34:181-5.
5. Denys D, Shahbazian M, Jacobs R, Laenen A, Wyatt J, Vinckier F, et al. Importance of root development in autotransplantations: a retrospective study of 137 teeth with a follow-up period varying from 1 week to 14 years. *Eur J Orthod.* 2013;35:680-8.
6. Kafourou V, Tong HJ, Day P, Houghton N, Spencer RJ, Duggal M. Outcomes and prognostic factors that influence the success of tooth autotransplantation in children and adolescents. *Dent Traumatol.* 2017;33:393-9.
7. Abela S, Murtadha L, Bister D, Andiappan M, Kwok J. Survival probability of dental autotransplantation of 366 teeth over 34 years within a hospital setting in the United Kingdom. *Eur J Orthod.* 2019;41:551-6.
8. Paulsen HU, Andreasen JO. Eruption of premolars subsequent to autotransplantation. A longitudinal radiographic study. *Eur J Orthod.* 1998;20:45-55.
9. Czochrowska EM, Stenvik A, Bjercke B, Zachrisson BU. Outcome of tooth transplantation: survival and success rates 17-41 years posttreatment. *Am J Orthod Dentofacial Orthop.* 2002;121:110-9; quiz 93.
10. Tsukiboshi M. Autotransplantation of teeth: requirements for predictable success. *Dent Traumatol.* 2002;18:157-80.
11. Zachrisson BU, Stenvik A, Haanaes HR. Management of missing maxillary anterior teeth with emphasis on autotransplantation. *Am J Orthod Dentofacial Orthop.* 2004;126:284-8.
12. Andreasen JO, Andreasen FM, Andersson L. Textbook and color atlas of traumatic injuries to the teeth: John Wiley & Sons; 2018.
13. Jang Y, Choi YJ, Lee SJ, Roh BD, Park SH, Kim E. Prognostic factors for clinical outcomes in autotransplantation of teeth with complete root formation: survival analysis for up to 12 years. *J Endod.* 2016;42:198-205.
14. Park JH, Tai K, Hayashi D. Tooth autotransplantation as a treatment option: a review. *J Clin Pediatr Dent.* 2010;35:129-35.

15. Aslan BI, Ucuncu N, Dogan A. Long-term follow-up of a patient with multiple congenitally missing teeth treated with autotransplantation and orthodontics. *Angle Orthod.* 2010;80:396-404.
16. Monteiro J, Barber S, Jawad Z, Duggal M, Houghton N. Tooth Autotransplantation Part 1: uses, indications and factors affecting success. *Orthod update.* 2019;12:63-9.
17. Plotino G, Abella Sans F, Duggal MS, Grande NM, Krastl G, Nagendrababu V, et al. Clinical procedures and outcome of surgical extrusion, intentional replantation and tooth autotransplantation - a narrative review. *Int Endod J.* 2020;53:1636-52.
18. Nimčenko T, Omerca G, Varinauskas V, Bramanti E, Signorino F, Cicciù M. Tooth autotransplantation as an alternative treatment option: a literature review. *Dent Res J (Isfahan).* 2013;10:1.
19. Akhlef Y, Schwartz O, Andreasen JO, Jensen SS. Autotransplantation of teeth to the anterior maxilla: A systematic review of survival and success, aesthetic presentation and patient-reported outcome. *Dent Traumatol.* 2018;34:20-7.
20. Stange KM, Lindsten R, Bjerklin K. Autotransplantation of premolars to the maxillary incisor region: a long-term follow-up of 12–22 years. *Eur J Orthod.* 2016;38:508-15.
21. Mendoza-Mendoza A, Solano-Reina E, Iglesias-Linares A, Garcia-Godoy F, Abalos C. Retrospective long-term evaluation of autotransplantation of premolars to the central incisor region. *Int Endod J.* 2012;45:88-97.
22. Czochrowska EM, Stenvik A, Album B, Zachrisson BU. Autotransplantation of premolars to replace maxillary incisors: a comparison with natural incisors. *Am J Orthod Dentofacial Orthop.* 2000;118:592-600.
23. Tanaka T, Deguchi T, Kageyama T, Kanomi R, Inoue M, Foong KW. Autotransplantation of 28 premolar donor teeth in 24 orthodontic patients. *Angle Orthod.* 2008;78:12-9.
24. Kugelberg R, Tegsjö U, Malmgren O. Autotransplantation of 45 teeth to the upper incisor region in adolescents. *Swed Dent J.* 1994;18:165-72.
25. Bowden DE, Patel HA. Autotransplantation of premolar teeth to replace missing maxillary central incisors. *Br J Orthod.* 1990;17:21-8.

26. Plakwicz P, Wojtowicz A, Czochrowska EM. Survival and success rates of autotransplanted premolars: a prospective study of the protocol for developing teeth. *Am J Orthod Dentofacial Orthop.* 2013;144:229-37.
27. Chung WC, Tu YK, Lin YH, Lu HK. Outcomes of autotransplanted teeth with complete root formation: a systematic review and meta-analysis. *J Clin Periodontol.* 2014;41:412-23.
28. Jacobsen I, Kerekes K. Long-term prognosis of traumatized permanent anterior teeth showing calcifying processes in the pulp cavity. *Scand J Dent Res.* 1977;85:588-98.
29. Goldman HM, Cohen DW. *Periodontal therapy*: CV Mosby Company; 1973.
30. Cross D, El-Anbawi A, McLaughlin P, Keightley A, Brocklebank L, Whitters J, et al. Developments in autotransplantation of teeth. *The surgeon.* 2013;11:49-55.
31. Kristerson L, Johansson LA, Kisch J, Stadler LE. Autotransplantation of third molars as treatment in advanced periodontal disease. *J Clin Periodontol.* 1991;18:521-8.
32. Logan W, R. K. Development of the human jaws and surrounding structures from birth to the age of fifteen years. *J Am Dent Assoc.* 1933;20:379–427.
33. Andreasen J, Paulsen H, Yu Z, Bayer T, Schwartz O. A long-term study of 370 autotransplanted premolars. Part II. Tooth survival and pulp healing subsequent to transplantation. *Eur J Orthod.* 1990b;12:14-24.
34. Moorrees CF, Fanning EA, Hunt EE, Jr. Age Variation of Formation Stages for Ten Permanent Teeth. *J Dent Res.* 1963;42:1490-502.
35. Jonsson T, Sigurdsson TJ. Autotransplantation of premolars to premolar sites. A long-term follow-up study of 40 consecutive patients. *Am J Orthod Dentofacial Orthop.* 2004;125:668-75.
36. Paulsen HU, Andreasen JO, Schwartz O. Pulp and periodontal healing, root development and root resorption subsequent to transplantation and orthodontic rotation: a long-term study of autotransplanted premolars. *Am J Orthod Dentofacial Orthop.* 1995;108:630-40.

37. Kristerson L. Autotransplantation of human premolars. A clinical and radiographic study of 100 teeth. *Int J Oral Surg.* 1985;14:200-13.
38. Andreasen J, Paulsen H, Yu Z, Schwartz O. A long term study of 370 autotransplanted premolars. Part III. Periodontal healing subsequent to transplantation. *Eur J Orthod.* 1990c;12:25-37.
39. Van Westerveld KJ, Verweij JP, Fiocco M, Mensink G, Van Merkesteyn JR. Root elongation after autotransplantation in 58 transplanted premolars: the radiographic width of the apex as a predictor. *J Maxillofac Surg.* 2019;77:1351-7.
40. Andreasen J, Schwartz O, Kofoed T, Daugaard-Jensen J. Transplantation of premolars as an approach for replacing avulsed teeth. *Pediatr Dent.* 2009;31:129-32.
41. Machado LA, Do Nascimento RR, Ferreira DM, Mattos CT, Vilella OV. Long-term prognosis of tooth autotransplantation: a systematic review and meta-analysis. *Int J Oral Maxillofac Surg.* 2016;45:610-7.
42. Schwartz O, Bergmann P, Klausen B. Autotransplantation of human teeth. A life-table analysis of prognostic factors. *Int J Oral Surg.* 1985a;14:245-58.
43. Schwartz O, Bergmann P, Klausen B. Resorption of autotransplanted human teeth: a retrospective study of 291 transplantations over a period of 25 years. *Int Endod J.* 1985b;18:119-31.
44. Cho SY, Lee Y, Shin SJ, Kim E, Jung IY, Friedman S, et al. Retention and Healing Outcomes after Intentional Replantation. *J Endod.* 2016;42:909-15.
45. Day PF, Lewis BR, Spencer RJ, Barber SK, Duggal M. The design and development of surgical templates for premolar transplants in adolescents. *Int Endod J.* 2012;45:1042-52.
46. Kvint S, Lindsten R, Magnusson A, Nilsson P, Bjerklin K. Autotransplantation of teeth in 215 patients. A follow-up study. *Angle Orthod.* 2010;80:446-51.
47. Yu HJ, Qiu LX, Wang XZ. Long-term follow-up of autogenous canine transplants with application of guided bone regeneration. *Int J Oral Maxillofac Surg.* 2014;43:355-61.

48. Ahlberg K, Bystedt H, Eliasson S, Odenrick L. Long-term evaluation of autotransplanted maxillary canines with completed root formation. *Acta Odontol Scand.* 1983;41:23-31.
49. Satheesh K. Managing Gingival Recession. *Dimens Dent Hyg.* 2012;10:18-23.
50. Omair A. Selecting the appropriate study design Case-control and cohort study designs. *J Health Spec.* 2016;4
51. Henderson M, Page L. Appraising the evidence: what is selection bias? *Evidence-based mental health.* 2007;10:67-8.
52. Altman DG, Bland JM. Missing data. *BMJ.* 2007;334:424.
53. Welbury R, Kinirons MJ, Day P, Humphreys K, Gregg TA. Outcomes for root-fractured permanent incisors: a retrospective study. *Pediatr Dent.* 2002;24:98-102.
54. Miller SC. *Textbook of Periodontia.* 3rd ed. Philadelphia: The Blakeston Co.; 1950.

List of tables

Table 1: Tooth and treatment related factors with potential to influence the outcome of auto-transplantation (Prognostic factors).

Table 2: Tooth and treatment related factors recorded for each auto-transplanted tooth (n=144).

Table 3: Univariate analysis showing the significant prognostic factors associated with periodontal healing for 120 subjects.

Table 4: Univariate analysis for the significant prognostic factors associated with pulp healing in 63 subjects where pulp healing could be expected.

Table 5: Periodontal healing binomial logistic regression model (multivariate analysis).

Table 6: Pulp healing binomial logistic regression model (multivariate analysis).

Table 1: Tooth and treatment related factors with potential to influence the outcome of auto-transplantation (Prognostic factors)

Type	Description
Patient demographics	<ul style="list-style-type: none"> • Age • Gender
Tooth related factors including donor tooth and recipient site characteristics	<ul style="list-style-type: none"> • Donor tooth eruption stage: unerupted, partially erupted and fully erupted. • Donor tooth stage of root development at auto-transplantation time, including apical maturity that was classified into closed apex and open apex (divergent, parallel and convergent) according to the Welbury classification (2002)⁵³. • Recipient site alveolar bone status: whether the bone was sufficient or deficient. The height of the alveolar bone was assessed using the pre-operative radiographs.
Treatment factors including surgical and post-surgical characteristics.	<ul style="list-style-type: none"> • Ease of extraction of donor tooth. • Recipient site tooth socket preparation. • Ease of placement of donor tooth at recipient site. • Stabilization type and duration. • Use of antibiotics. • Tooth mobility following splint removal was assessed based on Miller Classification (1950)⁵⁴. • Endodontic treatment including reasons for the treatment, type of intra-canal medicament, and time initiate endodontic treatment (e.g., duration between date of auto-transplantation operation and date of endodontic access)

Table 2: Tooth and treatment related factors recorded for each auto-transplanted tooth (n=144)

Prognostic factors			Frequency	Percent
Tooth related factors	Donor tooth type	Upper 2 nd premolars	82	56.9
		Lower 2 nd premolars	46	31.9
		Lower 1 st premolars	9	6.3
		Upper 1 st premolars	7	4.9
	Donor tooth eruption stage	Unerupted	5	3.5
		Partially erupted	26	18
		Fully erupted	113	78
	Donor tooth apical maturity	Divergent	36	25
		Parallel	18	12.5
		Convergent	20	13.9
		Complete	70	48.6
	Donor tooth root length	Two-third	36	25
		Full length	108	75
	Recipient site alveolar bone status	Sufficient	131	91
Deficient		13	9	
Treatment factors	Ease of extraction of donor tooth	Easy	132	92
		Difficult	12	7
	Recipient site socket preparation	From outline of the existing socket	90	62
		Surgically prepared sockets	11	16
		Not recorded	38	26.4
	Type of socket preparation	Hand Instruments	33	22.9
		Implant Bur kit	9	6.3
		Both	51	35.4
		Not recorded	51	35.4
	Ease of placement of donor tooth	Easy	129	89.6
		Difficult	15	10.4
	Splint type	Titanium Trauma Splint (TTS)	138	96
		Orthodontic wire with composite	6	4
	Antibiotics	Pre- and post-operative	52	43.3
		Post-operative	7	5.8
		None	16	13.3
		Not recorded	45	37.5
	Tooth mobility following splint removal	Normal	5	3.5
		Grade I	65	45.1
		Grade II	19	13.2
		Grade III	2	1.4
		Not recorded	53	36.8
	Reason for root canal treatment	Pulp necrosis	20	13.9
		Elective pulp extirpation	70	48.6
		N/A Revascularisation	52	36.1

		No RCT as there was replacement resorption	2	1.4
	Type of intra-canal Medicament	Non-setting calcium hydroxide	69	76.6
		Ledermix® past	5	5.5
		Both	10	11.1
		None	6	6.6
N/A, not applicable. RCT, Root Canal Treatment.				

Table 3: Univariate analysis showing the significant prognostic factors associated with periodontal healing for 120 subjects.

Variables (prognostic factors)	Periodontal Healing		P-value
	Yes	No	
Donor tooth eruption stage			
Unerupted	4	0	P < 0.05
Partially erupted	21	1	
Fully erupted	71	23	
Donor tooth apical maturity			
Divergent	29	3	P < 0.05
Parallel	13	2	
Convergent	14	1	
Complete	40	18	
Donor tooth root length			
Two-third	29	2	P < 0.05
Full length	67	22	
Recipient site alveolar bone status			
Sufficient	93	15	P < 0.001
Deficient	3	9	
Ease of extraction of donor tooth			
Easy	95	13	P < 0.001
Difficult	1	11	
Ease of placement of donor tooth			
Easy	91	14	P < 0.001
Difficult	5	10	
Socket preparation			
From outline of the existing socket	88	18	P < 0.001
Surgically prepared sockets	8	6	
Type of socket preparation			
Hand Instruments	27	3	P < 0.001
Implant Bur kit	3	3	
Both	28	15	
Tooth mobility following splint removal			
Normal - Grade I	51	7	P < 0.05
Grade II	9	8	
Grade III	0	2	
Reason for RCT			
Pulp necrosis	12	2	P < 0.001
Elective pulp extirpation	40	18	
N/A Revascularisation	44	2	
No RCT as there was replacement resorption	0	2	

Subject level analysis (n=120) except type of socket preparation (n=79) and mobility (n=77)

Table 4: Univariate analysis for the significant prognostic factors associated with pulp healing in 63 subjects where pulp healing could be expected.

Variables (prognostic factors)	Pulp healing		P-value
	Yes	No	
Donor tooth eruption stage			
Unerupted	4	0	P < 0.001
Partially erupted	21	2	
Fully erupted	21	15	
Ease of extraction of donor tooth			
Easy	46	14	P < 0.05
Difficult	0	3	
Ease of placement of donor tooth			
Easy	46	11	P < 0.05
Difficult	0	6	
Recipient site alveolar bone status			
Sufficient	44	13	P < 0.05
Deficient	2	4	

Subject level analysis (n=63)

Table 5: Periodontal healing binomial logistic regression model (multivariate analysis).

Covariates (prognostic factors)	P-value	OR	95% CI	
			Lower	Upper
DT Apical maturity	0.127			
DT Apical maturity (divergent)	0.032	0.015	0.000	0.925
DT Apical maturity (parallel)	0.517	0.367	0.023	9.367
DT Apical maturity (convergent) *Reference was complete closed apex	0.110	0.021	0.000	2.332
DT ease of extraction (Easy) *Reference was difficult	0.011	0.023	0.002	0.401
Recipient site alveolar bone status (sufficient) *Reference was deficient	0.002	0.006	0.000	0.632
Socket preparation (From outline socket) *Reference was surgically prepared	0.547	0.540	0.068	4.533
DT ease of placement (Easy) *Reference was difficult	0.010	0.034	0.001	0.543
Mobility (Normal - Grade I) *Reference was Grade II-III	0.031	0.148	0.024	0.901
Reason for RCT	0.481			
Reason for RCT (Pulp Necrosis) *Reference was elective pulp extirpation	0.480	3.711	0.073	172.822
Constant	0.015	214.19		
ORs, Odds Ratio; CI, Confidence Interval; DT, Donor Tooth, RCT, Root Canal Treatment. Note: Predicted probability is of membership for No (unfavourable periodontal healing)				

Table 6: Pulp healing binomial logistic regression model (multivariate analysis).

Covariates (prognostic factors)	P-value	OR	95% CI	
			Lower	Upper
DT Eruption Stage	0.023			
DT Eruption Stage (unerupted)	0.265	0.0282	0.022	2.653
DT Eruption Stage (partially erupted) *Reference was fully erupted	0.022	0.048	0.004	0.466
DT ease of extraction (easy) *Reference was difficult	0.033	0.037	0.002	0.816
Recipient site alveolar bone status (sufficient) *Reference was deficient	0.144	0.360	0.084	1.442
DT ease of placement (easy) *Reference was difficult	0.021	0.086	0.011	0.556
Constant	0.005	392.822		

OR, Odds Ratio; CI, Confidence Interval; DT, Donor Tooth.
 Note: Predicted probability is of membership for No (No pulp healing = pulp necrosis)

List of figures

Figure 1: Donor tooth root development at three different time points (n=52)

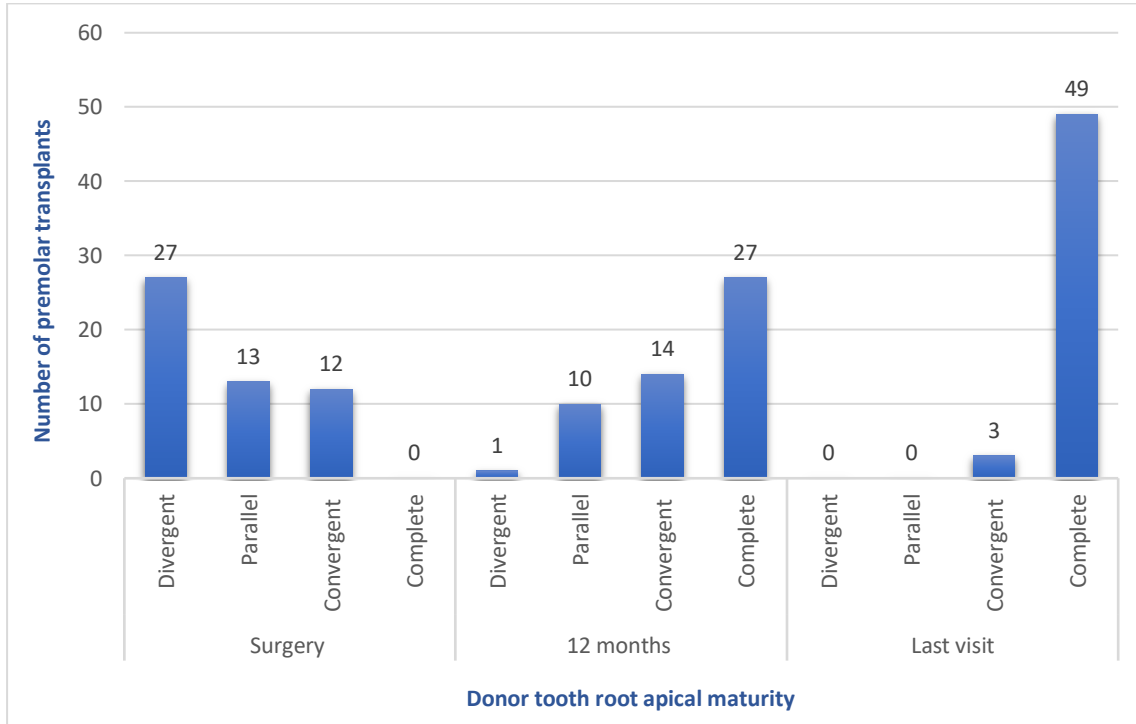


Figure 1: Donor tooth root development at three different time points (n=52)