



This is a repository copy of *Oral characteristics in adult individuals with periodontal Ehlers-Danlos syndrome*.

White Rose Research Online URL for this paper:

<https://eprints.whiterose.ac.uk/189568/>

Version: Published Version

Article:

Lepperdinger, U., Angwin, C., Milnes, D. et al. (12 more authors) (2022) Oral characteristics in adult individuals with periodontal Ehlers-Danlos syndrome. *Journal of Clinical Periodontology*, 49 (12). pp. 1244-1252. ISSN 0303-6979

<https://doi.org/10.1111/jcpe.13698>

Reuse

This article is distributed under the terms of the Creative Commons Attribution-NonCommercial (CC BY-NC) licence. This licence allows you to remix, tweak, and build upon this work non-commercially, and any new works must also acknowledge the authors and be non-commercial. You don't have to license any derivative works on the same terms. More information and the full terms of the licence here: <https://creativecommons.org/licenses/>

Takedown

If you consider content in White Rose Research Online to be in breach of UK law, please notify us by emailing eprints@whiterose.ac.uk including the URL of the record and the reason for the withdrawal request.



eprints@whiterose.ac.uk
<https://eprints.whiterose.ac.uk/>

Oral characteristics in adult individuals with periodontal Ehlers-Danlos syndrome

Ulrike Lepperdinger¹  | Chloe Angwin^{2,3} | Di Milnes⁴  | Glenda Sobey⁵ |
Neeti Ghali^{2,3} | Diana Johnson⁵ | Angela F. Brady^{2,3} | Tammy Kammin⁵ |
Jessica M. Bowen⁵ | Rebekka Gröbner⁶ | Pernilla Lundberg⁷  | James Scott⁸ |
Johannes Zschocke⁶ | Fleur S. van Dijk^{2,3} | Ines Kapferer-Seebacher¹ 

¹Department of Operative and Restorative Dentistry, Medical University of Innsbruck, Innsbruck, Austria

²National Ehlers Danlos Syndrome Service, London North West University Healthcare NHS Trust, London, UK

³Department of Metabolism, Digestion and Reproduction, Section of Genetics and Genomics, Imperial College London, London, UK

⁴Genetic Health Queensland, Royal Brisbane and Women's Hospital, Herston, Queensland, Australia

⁵Ehlers Danlos Syndrome National Diagnostic Service, Sheffield Children's Hospital, Sheffield, UK

⁶Institute of Human Genetics, Medical University of Innsbruck, Innsbruck, Austria

⁷Department of Molecular Periodontology, Umeå University, Umeå, Sweden

⁸Academic Unit of Restorative Dentistry, Sheffield University, Sheffield, UK

Correspondence

Ines Kapferer-Seebacher, Department of Operative and Restorative Dentistry, Medical University of Innsbruck, Anichstr. 35, Innsbruck 6020, Austria.
Email: ines.kapferer@i-med.ac.at

Funding information

Ehlers-Danlos Society, Grant/Award Number: 2019.02.PRO05

Abstract

Aim: Periodontal Ehlers-Danlos syndrome (pEDS) is a monogenic type of Ehlers-Danlos syndrome characterized by periodontal destruction at a young age. The present study aimed to document the oral phenotype of pEDS based on prospective clinical investigations.

Materials and Methods: Thirty-five adult individuals from 13 families with a clinically and genetically confirmed diagnosis of pEDS underwent a systematic oral assessment.

Results: Periodontitis stage 3 or 4 or edentulism due to periodontal destruction were diagnosed in 94% of the individuals. First permanent tooth loss was reported at the age of 21.5 years (median; range 13–43 years). Deep periodontal pockets were infrequent, with 94% measuring <4 mm. However, there was increased clinical attachment loss (CAL) averaging 8 mm (range 4–13 mm), and the probability of being edentate between the age of 35 and 44 years was 28–47% compared with less than 0.25% of the general population. Radiographic anomalous findings were only found in a portion of subjects and consisted of fused roots of maxillary second molars (81%), root hypoplasia (57%), taurodontism (26%) and tooth rotation of premolars (67%). As such, radiographic findings are not considered common characteristics of pEDS.

Conclusions: Characteristic oral traits of pEDS in adults are severe CAL with shallow probing depths and marked gingival recession. This is complemented by a lack of attached gingiva. These indications need to be paralleled by genetic analyses to diagnose pEDS unambiguously.

KEYWORDS

attached gingiva, C1R, C1S, Ehlers-Danlos syndrome, periodontitis

Clinical Relevance

Scientific rationale for study: Full description of oral characteristics of periodontal Ehlers-Danlos syndrome (pEDS) in adult individuals.

Principal findings: The oral phenotype of pEDS is characterized by severe clinical attachment loss in conjunction with shallow probing depths, marked gingival recession and lack of attached gingiva. Common characteristics are fused molar roots, taurodontism, tooth rotation and hypoplastic premolars roots.

Practical Implications: If there is a strong suspicion of pEDS, because of specific oral features, refer to a geneticist for further diagnostic work-up including molecular investigations. Due to the dominant inheritance pattern of pEDS, first-degree relatives should be offered oral investigations.

1 | INTRODUCTION

Ehlers-Danlos syndromes (EDS) are a group of clinically and genetically heterogeneous connective tissue diseases with overlapping features including joint hypermobility, skin and vascular fragility and generalized connective tissue friability (Malfait, 2018). Periodontal Ehlers-Danlos syndrome (pEDS) is additionally clinically characterized by lack of attached gingiva with marked gingival recession (GR) that is prone to an early onset of severe periodontitis (Figure 1).

Most EDS types are caused by variants in collagen-encoding genes, or in genes encoding collagen-modifying enzymes (Malfait et al., 2020). However, pEDS is caused by disease-causing heterozygous variants either in *C1R* (MIM 613785) or in *C1S* (MIM 120580). These encode complement 1 sub-components r and s, respectively (*C1r*; *C1s*) (Kapferer-Seebacher et al., 2016). These two serine proteases form a hetero-tetramer, which combines with six *C1q* subunits to initiate the complement 1 complex. The activation of the complement 1 complex is the first step of the classical complement cascade, a major antimicrobial pathway of the innate immune system involved in the inflammatory process leading to periodontitis (Wang et al., 2010; Hajishengallis et al., 2011; Maekawa et al., 2014). The central elements in the pathogenesis of pEDS are the intracellular activation of *C1r* and/or *C1s*, and secretion to the extracellular space of activated

C1s, which, irrespective of microbial triggers, may activate the classical complement cascade or have other functional effects (Bally et al., 2019; Grobner et al., 2019).

Whilst the central element in the pathogenesis of pEDS is the intracellular activation of *C1r* and/or *C1s*, intriguingly, individuals with pEDS also have other characteristic clinical symptoms. These include a lack of attached gingiva, which appears to be pathognomonic, as well as pretibial discoloration, joint hypermobility, and in rare cases aneurysms and organ ruptures (Kapferer-Seebacher et al., 2021, 2016). Histologic analysis from brownish pretibial skin demonstrated dermal fibrosis and hemosiderin deposition (Figure 1; Ronceray et al., 2013; George et al., 2016). Affected individuals often report on rather mild pretibial trauma leading to hematomas that never resolve.

Since the first reports of pEDS in the 1970s (McKusick, 1972; Stewart et al., 1977), 38 case reports/series, seven pedigree analyses and two cohort studies describing a total of 165 individuals have been published (Cortés-Bretón Brinkmann et al., 2021; Kapferer-Seebacher et al., 2017, 2019; Wu et al., 2018; Seo et al., 2019; El Chehadeh et al., 2021; Stock et al., 2021; Nakajima et al., 2022). Importantly, all authors reported severe periodontitis as a major criterion of pEDS. However, the severity of periodontal destruction has not been defined so far, nor have details been given on specific periodontal findings, such as probing depths, clinical attachment loss (CAL) and

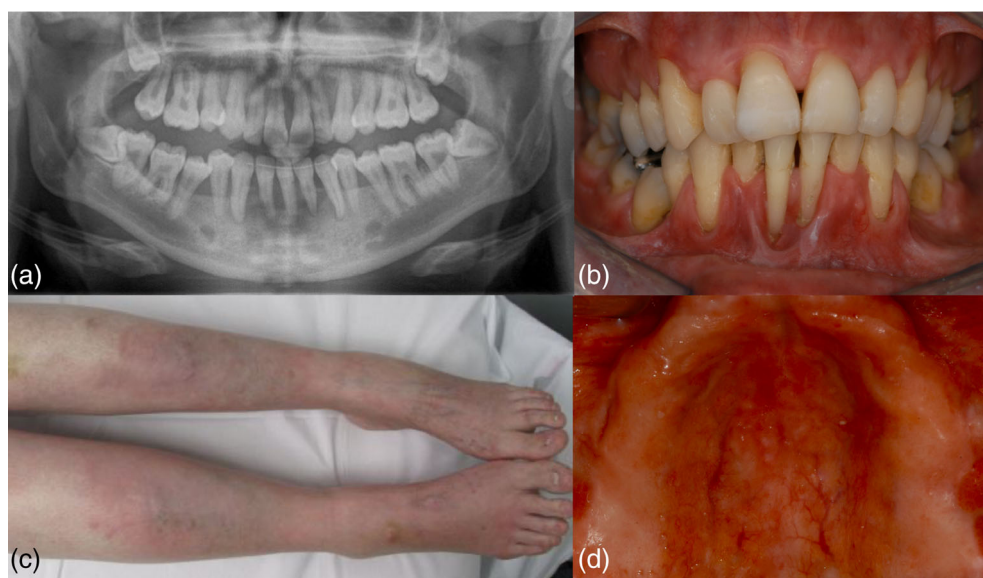


FIGURE 1 Main characteristics of adult individuals with periodontal Ehlers-Danlos syndrome. Major criteria are (a) early onset periodontitis (panoramic X-ray of a woman aged 22 years), (b) lack of attached gingiva and (c) pretibial plaque. Picture (d) shows increased visibility of vessels on the palate due to thin, translucent palatal gingiva in pEDS. [Colour figure can be viewed at wileyonlinelibrary.com]

bleeding on probing (BOP). Also, putative other oral manifestations of pEDS have not been investigated to date. Dental manifestations reported with other EDS types have been found to be pulp calcifications (pulp stones or pulp obliterations), abnormalities in the shape of the pulp chamber, root deformities (root hypoplasia or aplasia, bulbous roots, root fusions and exceeding root lengths), abnormalities in tooth number (supernumerary teeth or agenesis), tooth transposition, tooth discoloration and crown malformations.

In the present study, we compiled comprehensive periodontal and dental data of a cohort of adults with genetically confirmed pEDS. By providing a list of distinct markers, the authors are confident this will help clinicians to identify potential cases of pEDS and provide appropriate interventions and referrals for affected individuals.

2 | MATERIALS AND METHODS

2.1 | Ethics statement

The study was approved by the Ethics Committee of the Medical University Innsbruck, Austria (Studies no. UN4501 and no. 1074/2017). It is in accordance with the Declaration of Helsinki of 1975 as revised in 2013. Investigations were only conducted after declaration of the probands' understanding and after given a full verbally explained, written consent. Consent for using patient-specific photos was also obtained.

2.2 | Subject recruitment

Subject recruitment took place between January 2019 and March 2021. All adult individuals previously diagnosed with pEDS by the participating centres (Medical University of Innsbruck—Austria; National EDS Service London and National EDS Service Sheffield—United Kingdom; VU University Medical Center Amsterdam—The Netherlands; Genetic Health Queensland—Australia; Umeå University—Sweden) and first-degree relatives were recruited for the present study.

According to the current classification of EDS, a clinical diagnosis of pEDS was established if three out of four major criteria (severe and intractable periodontitis of early onset; lack of attached gingiva; pretibial plaques; family history of a first-degree relative who meets clinical criteria) and one minor criterion (easy bruising; joint hypermobility; skin hyperextensibility and fragility; abnormal scarring; increased rate of infections; hernias; marfanoid facial features; acrogeria; prominent vasculature) were present (Malfait et al., 2017). For molecular genetic testing, panel sequencing of target genes C1R, C1S, C1QA, C1QB and C1QC enriched from genomic DNA by Nextera® Rapid Capture (TruSight™ One Panel, Illumina) was followed by massively parallel sequencing (NextSeq, Illumina), sequence alignment to the human reference sequence GRCh37 (HG19) and data analysis using NextGene® and Geneticist Assistant™ (SoftGenetics). Detected variants were

confirmed by Sanger-sequencing. Family members without molecularly confirmed pEDS were excluded.

2.3 | Oral investigations

Standard periodontal investigations included measurement of probing pocket depths (PD), GR, CAL and BOP at six sites per tooth, as well as furcation involvement, tooth mobility, radiologic investigations and intra-oral inspection of soft tissues. Staging and grading of periodontitis were carried out according to the current classification scheme for periodontal and peri-implant diseases and conditions (Tonetti et al., 2018). In brief, stages I–IV of periodontitis are defined based on severity (primarily periodontal breakdown with reference to root length and periodontitis-associated tooth loss), complexity of management (PD, infrabony defects, furcation involvement, tooth hypermobility and masticatory dysfunction) and additionally described as extent (localized or generalized) (Tonetti et al., 2018). Lack of attached gingiva was diagnosed on buccal sites of teeth by rolling the mucosa with a periodontal probe to the gingival margin. Further investigations included inspection of hard and soft oral tissues, radiological analysis (OPG and bitewings) and intra-oral photographs to evaluate dental anomalies as previously reported with other EDS types. The questionnaire collated information regarding previous dental/periodontal treatment and risk factors for periodontal disease.

Standard descriptive statistics were used to summarize the variables studied. Unless otherwise stated, results on quantitative variables are expressed as median and range.

Family A was investigated at the Medical University of Innsbruck (Austria); families B, C, D, I, J and K were investigated at the National EDS Service, London (United Kingdom); family E was investigated at the VU University Medical Center, Amsterdam (The Netherlands); family F, L and M at the National EDS Service, Sheffield (United Kingdom); family G at Genetic Health Queensland (Australia); and family H at Umeå University, (Sweden). All oral investigations were performed by the same periodontal specialist (IK), except in Australia and Sweden, where periodontal investigations were performed by the periodontist KK and PL.

3 | RESULTS

3.1 | Subjects

All adult individuals from 13 families with clinically and genetically confirmed pEDS were included in the present study and underwent oral investigations (female: $n = 24$, male: $n = 11$, age range 20–89 years). All individuals had (likely) pathogenic heterozygous missense or insertion/deletion variants in C1R. At the time of investigation, 12 individuals (female: $n = 5$, male: $n = 7$) were edentate. They reported that most of their teeth were extracted due to hypermobility, or were spontaneously lost, which was considered the

endpoint of severe periodontal destruction. The retrospectively reported age of complete tooth loss in this subgroup was 25.5 years (range 14–48 years). The probability of being edentate at a specific age when diagnosed with pEDS is shown in Figure 2b.

Dentate individuals ($n = 23$) (female: $n = 18$, male: $n = 5$) had a median age of 33 years (range 18–73 years) and a median of 24 teeth (range 1–28) in situ. Seven individuals retained ≤ 11 teeth, notably only in one jaw (four in the upper and three in the lower jaw). The age of first tooth loss due to periodontal reasons was reported to be at a median of 21.5 years (range 13–43 years).

3.2 | Periodontal characterization

Of 23 dentate individuals, one was a smoker (20 cigarettes per day) and two were former smokers (15–20 cigarettes per day); none had diabetes. Sixteen individuals (age range 20–73 years) had stage

4 periodontitis, five (age range 21–45 years) had stage 3 and one (aged 33 years) had stage 2 periodontitis (Table 1). Only one individual aged 45 years was not affected by periodontal destruction. Periodontal grading was estimated in category C for all individuals by measuring radiographic bone loss in percentage of root length divided by the age of the patient being >1 .

Maximal CAL per individual ranged from 4 to 13 mm (median 8 mm). CAL was mainly attributable to GR and not to increased PDs (Figure 2a). The median of PDs was 2 mm, with 94% of all PDs measuring ≤ 3 mm. Only three individuals presented with single sites of PDs >5 mm (one to four sites with PDs of 6–8 mm). The median of BOP was 30% (range 3%–100%). GR ≥ 1 mm was diagnosed in all dentate individuals, 93% (range 4%–100%) of teeth per individual were affected. GR ≥ 3 mm was diagnosed in 21 individuals, 68% (range 4%–100%) of teeth were affected and 16 probands had 29% (range 8%–100%) of teeth with recession ≥ 5 mm.

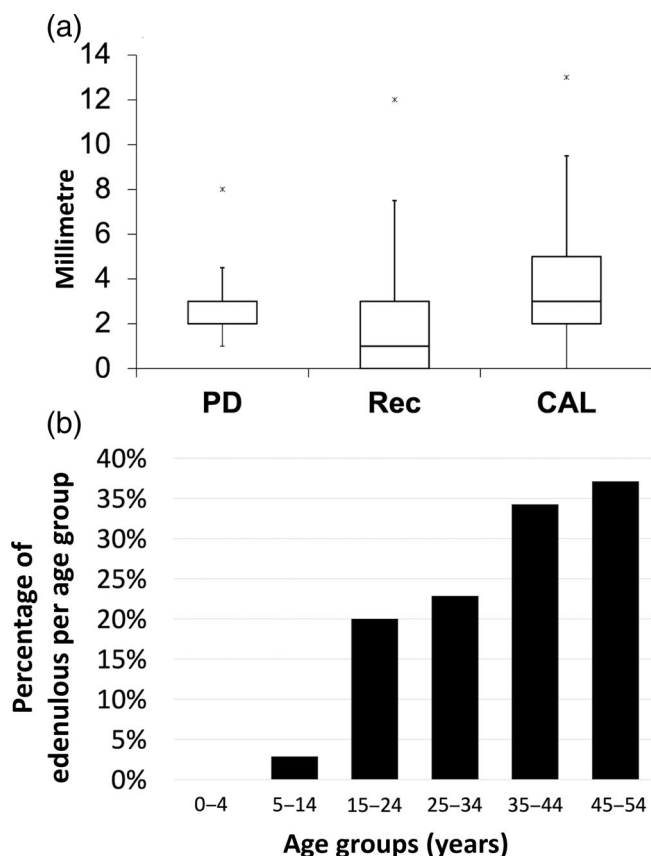


FIGURE 2 Periodontal characteristics of periodontal Ehlers-Danlos syndrome (pEDS). (a) Boxplot showing probing pocket depths (PD), recession (Rec) and clinical attachment loss (CAL) in millimetres. One particular finding of pEDS is relatively low PDs (median of 2 mm) regardless of the occurrence of severe CAL (median 8 mm). (b) Cumulative percentage of edentulous per age range. Analysis was based on the age of complete tooth loss of 13 edentulous individuals in the presented cohort. The probability of being edentate at between the age of 35 and 44 years was found to be 28–47%. In comparison, less than 0.5% of the general UK population aged 35–44 years were edentate in 2009.

3.3 | Soft tissue manifestations

All of the 23 dentate individuals presented with a lack of attached gingiva in all buccal surfaces of maxilla and mandible (Figure 1b). Increased visibility of vessels on the palate, probably due to thin, translucent palatal gingiva, was diagnosed in 18 dentate individuals (Figure 1d); in the remaining, it was not possible to assess this factor due to the palatal soft tissues being obscured by denture adhesive. None of the participants had missing frenula. A secondary finding was a remarkable high pain perception when probing the pockets, which was evident in 16 of 23 dentate individuals. As an additional observation, intra-oral photography was often difficult due to a lack of elasticity of the oral musculature. In most cases, paediatric retractors were required for patient comfort.

3.4 | Dental characterization

The most frequent dental findings were roots that appeared fused in the upper second molars in 9 of 12 individuals who still had teeth in the appropriate region and in one participant also in the lower second molars (Table 2, Figure 3). Radiographs of six individuals (26%) showed taurodontic molars.

The second most common dental finding was hypoplasia of tooth roots, which was present in 13 of 23 (57%) dentate individuals (Table 2, Figure 3). Root hypoplasia mostly affected the upper and/or lower premolars, and in single individuals, additionally, the first molars or second incisors. One individual presented with generalized hypoplastic roots. The crown-to-root ratio for teeth with root hypoplasia was 1:1.08 (range 1:1–1:1.3). Seven individuals presented pulp stones (Figure 3). Six individuals showed abnormalities in the shape of the pulp chamber. In 12 of 20 individuals with teeth in the appropriate region, we found an anatomical abnormality in the lower premolar area, which can be best described as a

TABLE 1 Periodontal characteristics of dentate adult individuals with periodontal Ehlers-Danlos syndrome

Periodontitis staging	Stage 4 (n = 16)	Stage 3 (n = 5)	Stage 2 (n = 1)	Total (n = 22)
Age median (range), years	34.5 (20–73)	24 (21–45)	33	33 (20–73)
Localized periodontitis, n	4	3	1	8
Generalized periodontitis, n	12	2	0	14
Max. RBL median (range), %	90 (20–95)	40 (15–95)	20	90 (15–95)
Max. CAL median (range), mm	9 (4–13)	7 (6–8)	2	8 (4–13)
CAL median (range), mm	4 (0–13)	3 (1–8)	2 (0–6)	3 (0–13)
PD median (range), mm	2 (1–8)	2 (1–4)	2 (1–3)	2 (1–8)
Rec median (range), mm	2 (0–12)	0 (0–6)	0 (0–5)	0 (0–10)

Note: A single individual, aged 45 years, had no CAL and was not included in the table. None of the individuals had received periodontal treatment prior to clinical investigation; seven reported on regular professional tooth cleaning every 3–6 months. Localized periodontitis was defined as <30% of teeth affected by CAL and generalized periodontitis as ≥30% of teeth affected (Caton et al., 2018).

Abbreviations: CAL, clinical attachment loss; Max., maximal; PD, probing pocket depths; RBL, radiographic bone loss; Rec, recession.

TABLE 2 Dental characteristics of 23 adult individuals with periodontal Ehlers-Danlos syndrome

Feature	Number of affected; n (%)	Comment
Root deformities		
Root hypoplasia	13 (57%)	Crown/root ratio = 1:1.08 (range 1:1–1:1.3)
Generalized	1 (4.3%)	All teeth affected
Localized	12 (52.2%)	Mostly affecting the upper and/or lower premolars; in single individuals also affecting the first molars or second incisors
Appearing fused single roots	9 (81%)	Affecting the maxillary second molars; in one individual additionally affecting the lower second molars
Taurodontism	6 (26%)	Affecting single teeth (lower and/or upper molars)
Abnormalities of the pulp		
Abnormalities in shape of the pulp chamber	6 (30%)	Wide pulp shape (single teeth)
Pulp stones	7 (30%)	Mostly affecting upper and/or lower molars
Abnormalities of tooth number or rotation/transposition		
Supernumerary teeth	1	Tooth number 29
Agenesis of one tooth	3 (30%)	Upper/lower premolars; once tooth number 36
Tooth rotation > 45°	10 (62.5%)	Affecting upper and/or lower premolars
Enamel defects		
Hypoplastic enamel defects	6 (30%)	Mostly affecting upper front teeth
White enamel discoloration	3 (15%)	Upper front teeth

Note: Dental features were evaluated clinically and/or radiologically on orthopantomograms. Percentage of affected varied being dependent on whether included individuals were dentate in the relevant region. The following features were not found in any individual: Root aplasia, bulbous roots, pulp obliterations, tooth transposition and agenesis of teeth.

kink between first and second premolars (Figure 3). The kink was sometimes just recognized as a drift of the tooth roots, and in a single case, this was caused by an abnormality of the mandible. A tooth rotation >45° of upper and/or lower premolars was diagnosed in 10 of 16 individuals who still had teeth in the appropriate region.

Abnormalities in tooth number were as follows: one individual had one supernumerary tooth (tooth 29), and 3 of 10 individuals with a full dentition showed agenesis of one tooth, excluding wisdom teeth. The agenic missing teeth were upper and lower premolars, and in one individual, tooth 36.

No individual was diagnosed with root aplasia, exceeding root lengths, bulbous roots or tooth transposition. Mild hypoplastic enamel defects affecting the upper incisors were diagnosed in six individuals. In three additional individuals, white enamel discolorations were noticeable on the buccal surfaces of the upper front teeth.

4 | DISCUSSION

In 2016, the genetic cause of pEDS as well as clinical features from 93 individuals from 17 families with molecularly confirmed pEDS were

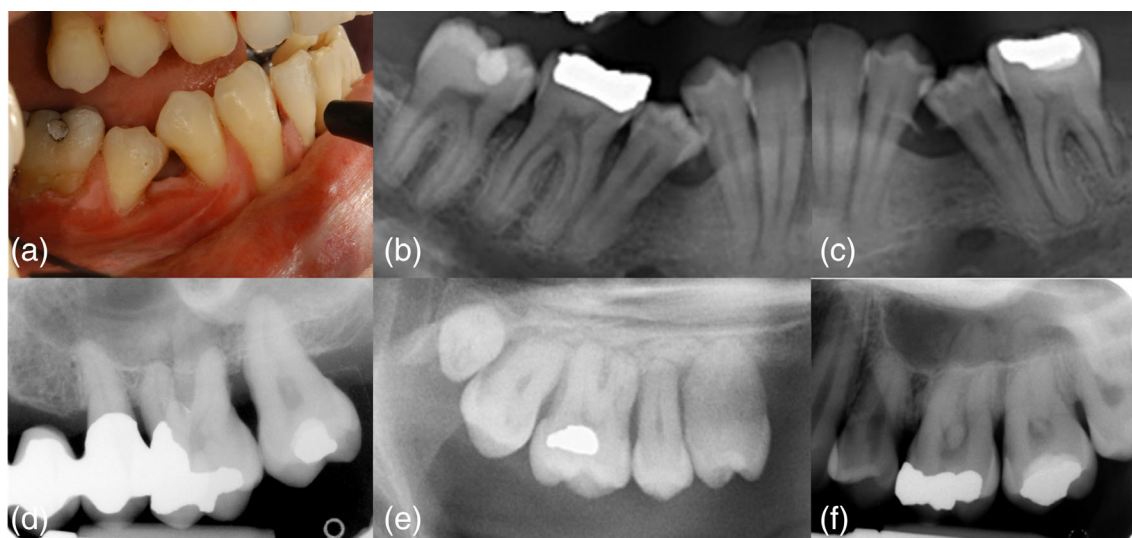


FIGURE 3 Dental characteristics of periodontal Ehlers-Danlos syndrome. (a–c) a characteristic “kink” caused by diverging roots of the lower premolars or by an anatomical abnormality of the mandibula was diagnosed in 12 of 20 of individuals with teeth in the appropriate region. Other common features were as shown in (d) root fusions of the upper molars and shortened roots (e.g., first upper molar). (e) Generalized hypoplastic roots were found in one individual. Tooth rotation was a common finding, mostly affecting first upper premolars. (f) Pulp stones in the first and second upper molar [Colour figure can be viewed at wileyonlinelibrary.com]

reported (Kapferer-Seebacher et al., 2016). Documented oral features were severe periodontitis with early onset and a previously unrecognized lack of attached gingiva that is now considered pathognomonic for this condition (Kapferer-Seebacher et al., 2021). Limitations of the previous study were attributable to retrospective data obtained from patients living in different countries, most of them not available for further clinical evaluation. Therefore, periodontal diagnoses were mainly based on patient reports or index card entries. In the meantime, based on the findings of the 2016 study (Kapferer-Seebacher et al., 2016), several new patients were diagnosed with pEDS, and a clinically and genetically well-characterized patient cohort is now available for structured prospective examination. The aim of the present study was to document a detailed oral phenotype of pEDS.

According to the current classification of EDS, a major criterion of pEDS is “severe and intractable periodontitis of early onset in childhood or adolescence” (Malfait et al., 2017). However, in the literature, severity or intractability of periodontitis has never been defined. In the present cohort, 21 of 23 dentate individuals were diagnosed with periodontitis stage 3 or 4 according to the current classification of periodontal and peri-implant diseases (Table 1; Tonetti et al., 2018). Even young participants aged ≤ 30 years were affected by stage 3 or 4 periodontitis. As most of the patients were not diagnosed with periodontitis prior to recruitment, no statement could be made regarding the onset and progression rate of periodontal destruction. Clinical investigations of 19 children aged 4–13 years related to the present molecular families revealed periodontal destruction only in the oldest child, which further consolidates the age of onset of periodontal destruction to the early teens, probably around puberty (Kapferer-Seebacher et al., 2021). Therefore, we suggest keeping the term “severe periodontitis of early onset in childhood or adolescence” as

major criterion of pEDS but eliminating the term intractable as intervention studies are missing. Longitudinal studies of children’s cohorts may further elucidate the age of onset and progression rate of CAL with pEDS.

Current dental treatment recommendations for pEDS consist of strict biofilm management to stop the hyperinflammatory periodontal reaction and probably the subsequent attachment and tooth loss. This recommendation is based on expert opinions as clinical trials have not taken place. Interestingly, two individuals aged 33 and 45 years from two different families had only mild (stage 2) or no CAL. They were clinically diagnosed with pEDS based on a lack of attached gingiva, pretibial hemosiderin depositions and an affected first-degree relative. Compared with their family members, both individuals had excellent oral hygiene and received professional tooth cleaning on a regular basis. This may have minimized periodontal inflammation and destruction. We were not able to establish a consistent genotype–oral phenotype as other family members with the same genetic cause showed periodontitis stage 3 or 4 or had already become edentulous at an early age.

Periodontal grading was based on indirect evidence of disease progression by measuring radiographic bone loss in percentage of root length divided by the age of the patient being >1 . All individuals with periodontal destruction were classified with grade 3. We suggest classifying individuals with genetically confirmed pEDS always with grade C due to the underlying genetic cause, with periodontitis being the main characteristic of a systemic disease. Performing periodontal risk assessment based on the method by Lang and Tonetti (2003) revealed a high risk of disease progression in 45% of dentate individuals in the present cohort, a middle risk in 45% and a low risk of disease progression in only 10% of dentate individuals (Lang & Tonetti, 2003).

Additionally, there is substantial evidence that an altered complement function plays an important role in the pathogenesis of periodontitis (Patters et al., 1989; Maekawa et al., 2014).

In the present cohort, the probability of being edentate between the age of 35 and 44 years was 28%–47%.

In comparison, less than 0.25% of the general UK population aged 35–44 years were edentate in 2009 (Bernabé & Sheiham, 2014). The median age of reported first permanent tooth loss was 21.5 years (range 13–43 years; mean 20.6 ± 4.7), which is higher than the mean age of 15 years previously reported (Kapferer-Seebacher et al., 2017). These discrepancies are attributable firstly to retrospective data collection, and secondly because in some previous reports primary teeth have been included in the calculation of first periodontal tooth loss.

Apart from the pathognomonic finding of lack of attached gingiva, which was also diagnosed in affected children (Kapferer-Seebacher et al., 2021), a striking characteristic feature of pEDS is the low number of deep periodontal pockets, even in untreated cases. Despite CAL of up to 13 mm and radiologic bone loss of up to 95%, only three probands had single probing PDs larger than 5 mm. The clinical picture mimics severe periodontitis after completed periodontal therapy, but with gingival inflammation. It seems that inflammatory attachment loss progresses mostly in the absence of deep periodontal pockets; however, this should be confirmed in longitudinal studies. Thin and fragile gingiva lead to GR that characterizes the oral image of people affected by pEDS. We previously reported generalized receding gingiva in 87% of adults with pEDS (Kapferer-Seebacher et al., 2017). In the present cohort, 91.3% of dentate individuals presented with GR ≥ 3 mm and 69.6% with recession ≥ 5 mm. GR and the lack of attached gingiva provide a useful and easily assessable oral characteristic in the diagnosis of pEDS and may give initial examiners the opportunity to easily support the suspected diagnosis of pEDS. When there is uncertainty about the diagnosis of pEDS, it makes sense to ask about additional characteristic clinical features such as hoarse voice, pretibial plaques, easy bruising and distal joint hypermobility (Kapferer-Seebacher et al., 2021).

Analyses of dental findings with pEDS had limitations as several dentate individuals presented with a reduced number of teeth. As such, prevalence rates of dental findings are not reliable. Dental features were evaluated clinically and/or radiologically on orthopantomograms. However, this method does not sufficiently allow the assessment of some other factors, such as the prevalence of caries or pulp stones. For future studies, it would be useful to include fully toothed individuals at younger age (teenagers) and to collect additional data with bitewing radiographs.

Nevertheless, based on the present findings, root fusion, taurodontism and hypoplastic roots appear more frequent in individuals with pEDS compared with the general population. Six of 23 dentate individuals (26%) in our cohort had at least one taurodont molar, compared with a prevalence of 0.04%–11.8% in the general Caucasian population (Laganà et al., 2017). Appearing fused single roots were found in 80% of the upper second molars in the cohort presented here, whereas the prevalence for root fusions of the second upper molar in the common population was reported by a recent systematic

review including 26,712 molars to range from 1.6% to 17.7%, with high prevalence rates in Asian populations (Martins et al., 2019). Single rooted permanent molars have also been reported with dentin dysplasia (MIM #125400), dental anomalies and short stature syndrome (MIM #601216), and osteogenesis imperfecta type VIII (MIM #610915) (Alfawaz et al., 2013; Kantaputra et al., 2021, 2022).

Short root anomaly, defined as developmentally short blunt dental roots with root-crown ratios ≤ 1.0 mostly affecting maxillary incisors and mandibular second premolars has incidence rates of 0.49%–2.4% (Jakobsson & Lind, 1973; Apajalahti et al., 2002; Herrera et al., 2021). It was previously reported as a dental feature of rare diseases as Odonto-/Hypophosphatasia, Stevens–Johnson syndrome (MIM #608579), Parry–Romberg syndrome (MIM #141300) and Emanuel syndrome (MIM #609029) (Wang et al., 2016; Puranik & Katechia, 2019; Katyal & Yadav, 2021; Aram et al., 2022). Molecular mechanisms of short root anomaly were previously elucidated, although the connection to complement pathway alterations remains still unclear (Yu et al., 2021). Hypoplastic roots have also been reported with classical EDS probably attributable to disturbances in dentinogenesis (Pope et al., 1992; Kapferer-Seebacher et al., 2020), whereas exceeding root lengths have been reported with vascular EDS (Ferre et al., 2012). An interesting finding in 12 individuals was a kink between the two lower premolars. It was either caused by strongly diverging tooth roots or in one case by an anatomical variation of the mandible (Figure 3a–c). It is unclear how the molecular disturbances in pEDS result in observed anomalies of tooth development.

One of the main limitations of the present study is the small sample size of dentate subjects, which additionally had a reduced number of teeth, so one cannot make a definitive conclusion on prevalence rates and dental findings. A further limitation was that oral investigations in United Kingdom took place in a non-dental setting. Therefore, plaque index measurements without plaque disclosing were not reliable and were excluded. Future studies should include detailed oral assessment in larger cohorts of dentate individuals with pEDS.

5 | CONCLUSION

This is the first systematic and comprehensive clinical study reporting in detail on dental and periodontal findings in pEDS. The main oral characteristic of pEDS is severe, early onset periodontitis (stage 3 or 4) with marked GRs and lack of attached gingiva. The dental findings root hypoplasia, taurodontism, fused appearing single roots, pulp abnormalities and tooth rotation of premolars should be considered for inclusion as common characteristics for pEDS, but not a reliable indicator in the classification of pEDS as these dental abnormalities are found at a higher prevalence than in the general population.

ACKNOWLEDGEMENTS

The authors thank the participating families with periodontal Ehlers–Danlos syndrome (pEDS) for their kind cooperation. The authors are grateful to J. Leary for re-contacting families with a (suspected)

diagnosis of pEDS in the South of the United Kingdom. The authors thank K. Kendall for providing periodontal and radiological data of family G (Australia).

FUNDING INFORMATION

This work was supported by a grant from the Ehlers-Danlos Society (Grant Number 2019.02.PRO05).

CONFLICT OF INTEREST

The authors declare that there are no conflicts of interest.

DATA AVAILABILITY STATEMENT

The data that support the findings of this study are available from the corresponding author upon reasonable request.

ETHICS STATEMENT

The study was approved by the Ethics Committee of the Medical University Innsbruck, Austria (Studies no. UN4501 and no. 1074/2017). It is in accordance with the Declaration of Helsinki of 1975 as revised in 2013. Investigations were only conducted after declaration of the probands' understanding and after given a full verbally explained, written consent. Consent for using patient-specific photos was also obtained.

ORCID

Ulrike Lepperdinger  <https://orcid.org/0000-0003-3584-7650>

Di Milnes  <https://orcid.org/0000-0001-8779-5157>

Pernilla Lundberg  <https://orcid.org/0000-0002-8244-5200>

Ines Kapferer-Seebacher  <https://orcid.org/0000-0001-6169-6812>

REFERENCES

- Alfawaz, S., Fong, F., Plagnol, V., Wong, F. S., Fearne, J., & Kelsell, D. P. (2013). Recessive oligodontia linked to a homozygous loss-of-function mutation in the SMOC2 gene. *Archives of Oral Biology*, 58(5), 462–466. <https://doi.org/10.1016/j.archoralbio.2012.12.008>
- Apajalahti, S., Holttä, P., Turtola, L., & Pirinen, S. (2002). Prevalence of short-root anomaly in healthy young adults. *Acta Odontologica Scandinavica*, 60(1), 56–59. <https://doi.org/10.1080/000163502753472014>
- Aram, A., Cappitelli, A., Dedeoglu, F., Vleugels, R. A., Bruun, R., & Ganske, I. M. (2022). Dental anomalies in Parry-Romberg syndrome: A 40-year retrospective review. *The Cleft Palate-Craniofacial Journal*, 10556656221086174. <https://doi.org/10.1177/10556656221086174>
- Bally, I., Dalonneau, F., Chouquet, A., Grobner, R., Amberger, A., Kapferer-Seebacher, I., Stoiber, H., Zschocke, J., Thielens, N. M., Rossi, V., & Gaboriaud, C. (2019). Two different missense C15 mutations, associated to periodontal Ehlers-Danlos syndrome, lead to identical molecular outcomes. *Frontiers in Immunology*, 10, 2962. <https://doi.org/10.3389/fimmu.2019.02962>
- Bernabé, E., & Sheiham, A. (2014). Tooth loss in the United Kingdom—trends in social inequalities: An age-period-and-cohort analysis. *PLoS One*, 9(8), e104808. <https://doi.org/10.1371/journal.pone.0104808>
- Caton, J. G., Armitage, G., Berglundh, T., Chapple, I. L. C., Jepsen, S., Kornman, K. S., Mealey, B. L., Papapanou, P. N., Sanz, M., & Tonetti, M. S. (2018). A new classification scheme for periodontal and peri-implant diseases and conditions – Introduction and key changes from the 1999 classification. *Journal of Clinical Periodontology*, 45 (Suppl. 20), S1–S8. <https://doi.org/10.1111/jcpe.12935>
- Cortés-Bretón Brinkmann, J., García-Gil, I., Lobato-Peña, D. M., Martínez-Mera, C., Suárez-García, M. J., Martínez-González, J. M., & Rioboo, M. (2021). The key role of the dental practitioner in early diagnosis of periodontal Ehlers-Danlos syndromes: a rare case report of siblings. *Quintessence International*, 52(2), 166–174. <https://doi.org/10.3290/j.qi.a45263>
- El Chehadeh, S., Legrand, A., Stoetzel, C., Geoffroy, V., Billon, C., Adham, S., Jeunemaître, X., Jaussaud, R., Muller, J., Schaefer, E., Benistan, K., Gaertner, S., Bloch-Zupan, A., Courval, A., Manière, M.-C., Petit, C., Bursztejn, A.-C., Bal, L., Reyre, A., ... Lipsker, D. (2021). Periodontal (formerly type VIII) Ehlers-Danlos syndrome: Description of 13 novel cases and expansion of the clinical phenotype. *Clinical Genetics*, 100(2), 206–212. <https://doi.org/10.1111/cge.13972>
- Ferré, F. C., Frank, M., Gogly, B., Golmard, L., Naveau, A., Chérifi, H., Emmerich, J., Gaultier, F., Berdal, A., Jeunemaître, X., & Fournier, B. P. (2012). Oral phenotype and scoring of vascular Ehlers-Danlos syndrome: a case-control study. *BMJ open*, 2(2), e000705. <https://doi.org/10.1136/bmjopen-2011-000705>
- George, S. M., Vandersteen, A., Nigar, E., Ferguson, D. J., Topham, E. J., & Pope, F. M. (2016). Two patients with Ehlers-Danlos syndrome type VIII with unexpected hoarseness. *Clinical and Experimental Dermatology*, 41(7), 771–774. <https://doi.org/10.1111/ced.12911>
- Grobner, R., Kapferer-Seebacher, I., Amberger, A., Redolfi, R., Dalonneau, F., Björck, E., Di Milnes, I. B., Rossi, V., Thielens, N., Stoiber, H., Gaboriaud, C., & Zschocke, J. (2019). C1R mutations trigger constitutive complement 1 activation in periodontal Ehlers-Danlos syndrome. *Frontiers in Immunology*, 10, 2537. <https://doi.org/10.3389/fimmu.2019.02537>
- Hajishengallis, G., Liang, S., Payne, M. A., Hashim, A., Jotwani, R., Eskan, M. A., McIntosh, M. L., Alsam, A., Kirkwood, K. L., Lambris, J. D., Darveau, R. P., & Curtis, M. A. (2011). Low-abundance biofilm species orchestrates inflammatory periodontal disease through the commensal microbiota and complement. *Cell Host & Microbe*, 10(5), 10–506.
- Herrera, C., Rivas-Tumanyan, S., Morales, J., Garcia-Rodriguez, O., & Elias-Boneta, A. R. (2021). Prevalence of short root anomaly in a group of Puerto Ricans. *Puerto Rico Health Sciences Journal*, 40(3), 115–119.
- Jakobsson, R., & Lind, V. (1973). Variation in root length of the permanent maxillary central incisor. *Scandinavian Journal of Dental Research*, 81(4), 335–338. <https://doi.org/10.1111/j.1600-0722.1973.tb00600.x>
- Kantaputra, P., Deikhamron, P., Intachai, W., Ngamphiw, C., Ketudat Cairns, J. R., Kawasaki, K., Ohazama, A., Olsen, B., Tongsim, S., & Angkurawaranon, S. (2021). A novel P3H1 mutation is associated with osteogenesis imperfecta type VIII and dental anomalies. *Oral Surgery, Oral Medicine, Oral Pathology, Oral Radiology*, 132(6), e198–e207. <https://doi.org/10.1016/j.ooolo.2021.01.023>
- Kantaputra, P., Guven, Y., Kalayci, T., Ozer, P. K., Panyarak, W., Intachai, W., Olsen, B., Carlson, B. M., Praditsap, O., Tongsim, S., Ngamphiw, C., Jatoorathawichot, P., Tucker, A. S., & Ketudat Cairns, J. R. (2022). Expanding genotypic and phenotypic spectrums of LTBP3 variants in dental anomalies and short stature syndrome. *Clinical Genetics*, 102, 66–71. <https://doi.org/10.1111/cge.14134>
- Kapferer-Seebacher, I., Lundberg, P., Malfait, F., & Zschocke, J. (2017). Periodontal manifestations of Ehlers-Danlos syndromes: A systematic review. *Journal of Clinical Periodontology*, 44(11), 1088–1100. <https://doi.org/10.1111/jcpe.12807>
- Kapferer-Seebacher, I., Oakley-Hannibal, E., Lepperdinger, U., Johnson, D., Ghali, N., Brady, A. F., Sobey, G., Zschocke, J., & van Dijk, F. S. (2021). Prospective clinical investigations of children with periodontal Ehlers-Danlos syndrome identify generalized lack of attached gingiva as a pathognomonic feature. *Genetics in Medicine*, 23(2), 316–322. <https://doi.org/10.1038/s41436-020-00985-y>
- Kapferer-Seebacher, I., Pepin, M., Werner, R., Aitman, T. J., Nordgren, A., Stoiber, H., Thielens, N., Gaboriaud, C., Amberger, A., Schossig, A., Gruber, R., Giunta, C., Bamshad, M., Björck, E., Chen, C., Chitayat, D., Dorschner, M., Schmitt-Egenolf, M., Hale, C. J., ... Zschocke, J. (2016).

- Periodontal Ehlers-Danlos syndrome is caused by mutations in C1R and C1S, which encode subcomponents C1r and C1s of complement. *American Journal of Human Genetics*, 99(5), 1005–1014. <https://doi.org/10.1016/j.ajhg.2016.08.019>
- Kapferer-Seebacher, I., Waisfisz, Q., Boesch, S., Bronk, M., van Tintelen, P., Gizewski, E. R., Groebner, R., Zschocke, J., & van der Knaap, M. S. (2019). Periodontal Ehlers-Danlos syndrome is associated with leukoencephalopathy. *Neurogenetics*, 20(1), 1–8. <https://doi.org/10.1007/s10048-018-0560-x>
- Katyal, S., & Yadav, V. (2021). Diagnostic and treatment approach in the management of dental anomalies associated with Stevens-Johnson syndrome: A case report. *International Journal of Clinical Pediatric Dentistry*, 14(4), 569–574. <https://doi.org/10.5005/jp-journals-10005-1986>
- Laganà, G., Venza, N., Borzabadi-Farahani, A., Fabi, F., Danesi, C., & Cozza, P. (2017). Dental anomalies: Prevalence and associations between them in a large sample of non-orthodontic subjects, a cross-sectional study. *BMC Oral Health*, 17(1), 62. <https://doi.org/10.1186/s12903-017-0352-y>
- Lang, N. P., & Tonetti, M. S. (2003). Periodontal risk assessment (PRA) for patients in supportive periodontal therapy (SPT). *Oral Health & Preventive Dentistry*, 1(1), 7–16.
- Maekawa, T., Abe, T., Hajishengallis, E., Hosur, K. B., DeAngelis, R. A., Ricklin, D., Lambris, J. D., & Hajishengallis, G. (2014). Genetic and intervention studies implicating complement C3 as a major target for the treatment of periodontitis. *Journal of Immunology*, 192(12), 6020–6027. <https://doi.org/10.4049/jimmunol.1400569>
- Malfait, F. (2018). Vascular aspects of the Ehlers-Danlos syndromes. *Matrix Biology*, 71–72, 380–395. <https://doi.org/10.1016/j.matbio.2018.04.013>
- Malfait, F., Castori, M., Francomano, C. A., Giunta, C., Kosho, T., & Byers, P. H. (2020). The Ehlers-Danlos syndromes. *Nature Reviews. Disease Primers*, 6(1), 64. <https://doi.org/10.1038/s41572-020-0194-9>
- Malfait, F., Francomano, C., Byers, P., Belmont, J., Berglund, B., Black, J., Bloom, L., Bowen, J. M., Brady, A. F., Burrows, N. P., Castori, M., Cohen, H., Colombi, M., Demirdas, S., De Backer, J., De Paepe, A., Fournel-Gigleux, S., Frank, M., Ghali, N., ... Tinkle, B. (2017). The 2017 international classification of the Ehlers-Danlos syndromes. *American Journal of Medical Genetics. Part C, Seminars in Medical Genetics*, 175(1), 8–26. <https://doi.org/10.1002/ajmg.c.31552>
- Martins, J. N. R., Marques, D., Silva, E., Carames, J., & Versiani, M. A. (2019). Prevalence studies on root canal anatomy using cone-beam computed tomographic imaging: A systematic review. *Journal of Endodontia*, 45(4), 372–386 e374. <https://doi.org/10.1016/j.joen.2018.12.016>
- McKusick, V. A. (1972). *Heritable disorders of connective tissue* (4th ed.). Mosby.
- Nakajima, K., Suzuki, H., Yamamoto, M., Yamamoto, T., Kawai, T., Nakabayashi, K., Hata, K., Kosaki, K., Nakajima, H., Sano, S., & Kubo, A. (2022). A familial case of periodontal Ehlers-Danlos syndrome lacking skin extensibility and joint hypermobility with a missense mutation in C1R. *The Journal of Dermatology*, 49, 714–718. <https://doi.org/10.1111/1346-8138.16372>
- Patters, M. R., Niekrash, C. E., & Lang, N. P. (1989). Assessment of complement cleavage in gingival fluid during experimental gingivitis in man. *Journal of Clinical Periodontology*, 16(1), 33–37.
- Pope, F. M., Komorowska, A., Lee, K. W., Speight, P., Zorawska, H., Ranta, H., Coonar, H. S., & MacKenzie, J. L. (1992). Ehlers Danlos syndrome type I with novel dental features. *Journal of Oral Pathology & Medicine*, 21(9), 418–421. <https://doi.org/10.1111/j.1600-0714.1992.tb01031.x>
- Puranik, C. P., & Katechia, B. (2019). Oral and dental findings in emanuel syndrome. *International Journal of Paediatric Dentistry*, 29(5), 677–682. <https://doi.org/10.1111/ipd.12502>
- Roncera, S., Miquel, J., Lucas, A., Pierard, G. E., Hermanns-Le, T., De Paepe, A., & Dupuy, A. (2013). Ehlers-Danlos syndrome type VIII: A rare cause of leg ulcers in young patients. *Case Reports in Dermatological Medicine*, 2013, 469505. <https://doi.org/10.1155/2013/469505>
- Seo, G. H., Kim, Y.-M., Ghang, B., Kim, G.-H., & Lee, B. H. (2019). Ehlers-Danlos syndrome VIII with novel C1R variant accompanying white matter changes. *Journal of Genetic Medicine*, 16(1), 5. <https://doi.org/10.5734/JGM.2019.16.1.43>
- Stewart, R. E., Hollister, D. W., & Rimoin, D. L. (1977). A new variant of Ehlers-Danlos syndrome: An autosomal dominant disorder of fragile skin, abnormal scarring, and generalized periodontitis. *Birth Defects Original Article Series*, 13(3B), 85–93.
- Stock, F., Hanisch, M., Lechner, S., Biskup, S., Bohring, A., Zschocke, J., & Kapferer-Seebacher, I. (2021). Prepubertal periodontitis in a patient with combined classical and periodontal Ehlers-Danlos syndrome. *Bio-molecules*, 11(2), 149. <https://doi.org/10.3390/biom11020149>
- Tonetti, M. S., Greenwell, H., & Kornman, K. S. (2018). Staging and grading of periodontitis: Framework and proposal of a new classification and case definition. *Journal of Periodontology*, 89(12), 1475. <https://doi.org/10.1002/jper.10239>
- Wang, M., Krauss, J. L., Domon, H., Hosur, K. B., Liang, S., Magotti, P., Triantafyllou, M., Triantafyllou, K., Lambris, J. D., & Hajishengallis, G. (2010). Microbial hijacking of complement-toll-like receptor crosstalk. *Science Signaling*, 3(109), ra11. <https://doi.org/10.1126/scisignal.2000697>
- Wang, Z. Y., Zhang, K., Zheng, G. S., Qiao, W., & Su, Y. X. (2016). Current concepts in odontohypophosphatasia form of hypophosphatasia and report of two cases. *BMC Oral Health*, 16(1), 70. <https://doi.org/10.1186/s12903-016-0266-0>
- Wu, J., Yang, J., Zhao, J., Wu, J. R., Zhang, X., Leung, W. K., & Sun, W. B. (2018). A Chinese family with periodontal Ehlers-Danlos syndrome associated with missense mutation in the C1R gene. *Journal of Clinical Periodontology*, 45(11), 1311–1318. <https://doi.org/10.1111/jcpe.12988>
- Yu, M., Jiang, Z., Wang, Y., Xi, Y., & Yang, G. (2021). Molecular mechanisms for short root anomaly. *Oral Diseases*, 27(2), 142–150. <https://doi.org/10.1111/odi.13266>

How to cite this article: Lepperdinger, U., Angwin, C., Milnes, D., Sobey, G., Ghali, N., Johnson, D., Brady, A. F., Kammin, T., Bowen, J. M., Gröbner, R., Lundberg, P., Scott, J., Zschocke, J., van Dijk, F. S., & Kapferer-Seebacher, I. (2022). Oral characteristics in adult individuals with periodontal Ehlers-Danlos syndrome. *Journal of Clinical Periodontology*, 1–9. <https://doi.org/10.1111/jcpe.13698>