



This is a repository copy of *Mitral regurgitation quantified by CMR 4D-flow is associated with microvascular obstruction post reperfused ST-segment elevation myocardial infarction.*

White Rose Research Online URL for this paper:  
<https://eprints.whiterose.ac.uk/186889/>

Version: Published Version

---

**Article:**

Assadi, H., Grafton-Clarke, C., Demirkiran, A. et al. (10 more authors) (2022) Mitral regurgitation quantified by CMR 4D-flow is associated with microvascular obstruction post reperfused ST-segment elevation myocardial infarction. *BMC Research Notes*, 15 (1). 181.

<https://doi.org/10.1186/s13104-022-06063-7>

---

**Reuse**

This article is distributed under the terms of the Creative Commons Attribution (CC BY) licence. This licence allows you to distribute, remix, tweak, and build upon the work, even commercially, as long as you credit the authors for the original work. More information and the full terms of the licence here:  
<https://creativecommons.org/licenses/>

**Takedown**

If you consider content in White Rose Research Online to be in breach of UK law, please notify us by emailing [eprints@whiterose.ac.uk](mailto:eprints@whiterose.ac.uk) including the URL of the record and the reason for the withdrawal request.




[eprints@whiterose.ac.uk](mailto:eprints@whiterose.ac.uk)  
<https://eprints.whiterose.ac.uk/>

RESEARCH NOTE

Open Access



# Mitral regurgitation quantified by CMR 4D-flow is associated with microvascular obstruction post reperfused ST-segment elevation myocardial infarction

Hosamadin Assadi<sup>1,2</sup> , Ciaran Grafton-Clarke<sup>1,2</sup>, Ahmet Demirkiran<sup>3</sup>, Rob J. van der Geest<sup>4</sup>, Robin Nijveldt<sup>5</sup>, Marcus Flather<sup>1,2</sup>, Andrew J. Swift<sup>6</sup>, Vass S. Vassiliou<sup>1,2</sup>, Peter P. Swoboda<sup>7</sup>, Amardeep Dastidar<sup>8</sup>, John P. Greenwood<sup>7</sup>, Sven Plein<sup>7</sup> and Pankaj Garg<sup>1,2,6\*</sup>

## Abstract

**Objectives:** Mitral regurgitation (MR) and microvascular obstruction (MVO) are common complications of myocardial infarction (MI). This study aimed to investigate the association between MR in ST-elevation MI (STEMI) subjects with MVO post-reperfusion. STEMI subjects undergoing primary percutaneous intervention were enrolled. Cardiovascular magnetic resonance (CMR) imaging was performed within 48-hours of initial presentation. 4D flow images of CMR were analysed using a retrospective valve tracking technique to quantify MR volume, and late gadolinium enhancement images of CMR to assess MVO.

**Results:** Among 69 patients in the study cohort, 41 had MVO (59%). Patients with MVO had lower left ventricular (LV) ejection fraction (EF) ( $42 \pm 10\%$  vs.  $52 \pm 8\%$ ,  $P < 0.01$ ), higher end-systolic volume ( $98 \pm 49$  ml vs.  $73 \pm 28$  ml,  $P < 0.001$ ) and larger scar volume ( $26 \pm 19\%$  vs.  $11 \pm 9\%$ ,  $P < 0.001$ ). Extent of MVO was associated with the degree of MR quantified by 4D flow ( $R = 0.54$ ,  $P = 0.0003$ ). In uni-variate regression analysis, investigating the association of CMR variables to the degree of acute MR, only the extent of MVO was associated (coefficient = 0.27,  $P = 0.001$ ). The area under the curve for the presence of MVO was 0.66 ( $P = 0.01$ ) for MR > 2.5 ml. We conclude that in patients with reperfused STEMI, the degree of acute MR is associated with the degree of MVO.

**Keywords:** ST-segment elevation myocardial infarction, Magnetic resonance imaging, Haemodynamics, Mitral regurgitation

## Introduction

Post reperfused ST-elevation myocardial infarction (STEMI), the ventricles undergo structural adaptations both within and outside of the infarct, referred to as left ventricular (LV) remodelling. In some patients, coronary

reperfusion is associated with microvascular obstruction (MVO), seen angiographically as no-reflow. MVO is associated with adverse prognosis, independently of infarct size (IS) [1, 2]. Clinically, the presence and the extent of MVO can be assessed by cardiovascular magnetic resonance imaging [3, 4].

In addition, mitral regurgitation (MR) of any degree is a powerful, independent predictor of mortality in patients undergoing primary percutaneous reperfusion therapy for STEMI. The presence of MR identifies high-risk

\*Correspondence: P.Garg@uea.ac.uk

<sup>1</sup> Department of Cardiovascular and Metabolic Health, Norwich Medical School, University of East Anglia, Colney Lane, Norwich NR4 7UQ, UK  
Full list of author information is available at the end of the article



patients in whom close out-patient follow-up is warranted, and who may benefit from aggressive adjunctive medical or surgical therapies [5–8]. CMR can be used for MR quantification [9]. More recently, four-dimensional (4D) flow imaging has demonstrated better precision for MR quantification than standard methods of MR quantification by CMR [10–12]. These advanced 4D flow CMR methods allow quantification of even a small degree of MR [13].

Even though both MVO and acute MR are associated with adverse outcomes post reperfused STEMI, it remains unknown if both are associated with each other.

We hypothesise that the extent of MVO after reperfused STEMI is associated with the degree of acute MR. Hence, the aim of this study was to investigate if the degree of MR is associated with the degree of MVO. In addition, we aimed to evaluate if the presence of MR can have diagnostic value for the presence of MVO.

## Main text

### Methods

#### *Ethics approval and consent to participate*

This study was conducted as per the principles outlined in the 1964 Declaration of Helsinki. The collection and management of data were approved by the National Research Ethics Service in the United Kingdom (12/YH/0169). Written informed consent was obtained from all individual participants in the study.

#### *Study population*

This was a prospective cohort study in which 69 patients with acute reperfused STEMI were enrolled. The patients were enrolled at the Leeds Teaching Hospitals (University of Leeds, Leeds, United Kingdom). All patients had CMR examination within 48-h of the index event.

Exclusion criteria were prior history of myocardial infarction or any coronary revascularisation procedure, non-ischemic cardiomyopathy, and any contraindication to CMR.

#### *CMR protocol and analysis*

CMR imaging was done on a 1.5T system (Ingenia, Philips, Best, The Netherlands) with a phased-array 28-channel cardiac receiver coil. The CMR protocol included conventional cine imaging, 4D flow and early/late gadolinium enhancement (EGE/LGE) imaging.

Cine imaging, LGE imaging, and 4D flow acquisition methods have been previously published by our group [14–18]. For 4D flow acquisition, three-dimensional, three-directional phase-contrast, and velocity encoded data were acquired within the LV using an Echo-Planar Imaging accelerated, free-breathing sequence with retrospective ECG-triggering. Gradient nonlinearity and

Maxwell correction were automatically performed by the scanner. Typical acquisition parameters were: TE/TR 3.7 ms/11 ms, flip angle 10°, VENC 150 cm/s and voxel size 3.0 × 3.0 × 3.0 mm (30 phases per cardiac cycle).

All CMR analysis was performed using dedicated research software (MASS version 2021-Exp, Leiden University Medical Center, Leiden, the Netherlands). All CMR contour tracings, including volume/function, LGE, and the 4D flow CMR were performed by R.J.G. and controlled by EACVI level-III certified CMR experts (P.G. and R.N.), all with over 10 years of CMR experience.

Infarct size was calculated on the short-axis LGE images using the full-width-at-half-maximum method [14]. MVO was defined visually as the hypointense core within the infarcted zone and planimeted manually. Volumes of infarct and MVO were calculated from planimeted areas across the whole LV stack by the modified Simpson's method [1, 2].

#### *Mitral inflow analysis*

Mitral inflow analysis was performed on the 4D flow CMR images. The mitral valve position was determined on the LV two- and four-chamber cine acquisitions. Manual retrospective valve tracking over the mitral valve was performed. The planes of flow quantification followed the valve plane over the cardiac cycle and were adjusted according to the blood flow direction. On the reformatted valve plane phase-contrast images, the mitral inflow was identified as higher signal intensity during LV diastole and segmented appropriately throughout the complete cardiac cycle to obtain the trans-mitral flow curve. The mitral regurgitation jet was identified during the left ventricular systolic phases. The reformatted plane during systole was planned perpendicular to the MR jet in the left atrium to capture the jet [9]. Mitral valve stroke volume was computed by the following formula: mitral forward flow during left ventricular diastole—mitral backward flow during systole.

#### *Statistical analysis*

Statistical analysis was performed using MedCalc (Version 20.011). Continuous variables are presented as mean ± standard deviation or median with interquartile range, as appropriate. Comparisons between two groups were made with the independent-samples T-test for normally distributed data or Mann-Whitney U test for non-parametric data. Categorical variables are summarised by frequency (percentage), and relationships between categorical variables were tested with the  $\chi^2$  test. Association between continuous variables was quantified by Pearson's correlation. Kruskal–Wallis test was used for one-way ANOVA testing on non-parametric data. Receiver-operating characteristics (ROC)

analysis was performed to assess the performance of MR to predict the presence of MVO. Areas under the ROC curve were calculated, and Youden’s index was used to determine optimal cut-off values. Multivariate linear regression was performed using Enter and Step-wise procedures to evaluate independent association to the extent of MVO. The two-sided significance level was set at 5%.

**Results**

**Patient population**

Baseline characteristics of the study population (n = 69) are summarised in Table 1. Forty-one patients had MVO (59%). Patients with MVO had larger left ventricular volumes and significantly lower left ventricular

ejection fraction. Patients with MVO also had higher scar volume (26 ± 19% vs. 11 ± 9%, P < 0.001).

**Association of standard CMR variables to MVO**

The degree of MVO was associated with all volumetric parameters including left ventricular end-diastolic volume (r = 0.33, P = 0.006), end-systolic volume (r = 0.52, P < 0.001), stroke volume (r = -0.35, P = 0.003), ejection fraction (r = -0.59, P < 0.001) and mass (r = 0.4, P = 0.003). In addition, the degree of left ventricle scar was also linearly associated with the degree of MVO (r = 0.58, P < 0.001).

**4D flow CMR analysis**

Mitral stroke volume was significantly reduced in MVO patients (55 ± 15 ml vs. 66 ± 26 ml, P = 0.001). Degree of MVO demonstrated association with the degree of MR quantified by 4D flow (Pearson correlation = 0.54, 95% CI 0.28–0.73, P = 0.0003) (Fig. 1a–d). The area under the curve for the prediction of MVO by the extent of MR was 0.66 (P = 0.01). An MR greater than 2.5 ml demonstrated 75% sensitivity and 57% specificity for the diagnosis of MVO.

**Association of MR to infarct territory**

In the whole cohort, 37 cases (53%) were anterior infarcts and 21 (30%) were inferior infarcts. Rest 17% were either lateral, anterolateral or inferolateral. The volume of MR was not different in either of these categories (Fig. 1e, P = 0.78).

**Independent predictors of MVO on uni/multi-variate regression**

In univariate regression analysis, all CMR volumetric and tissue characterisation variables demonstrated association to the extent of MVO (Table 2). Using the ‘Step-wise’ multiple linear regression, four CMR variables demonstrated independent association to the extent of MVO: the degree of mitral regurgitation (coefficient 0.44, P = 0.001), left ventricular ejection fraction (coefficient -0.17, P = 0.002), left ventricular end-diastolic mass (coefficient 0.03, P = 0.04) and the extent of LV scar (coefficient 0.12, P = 0.002).

**Table 1** Patient demographics

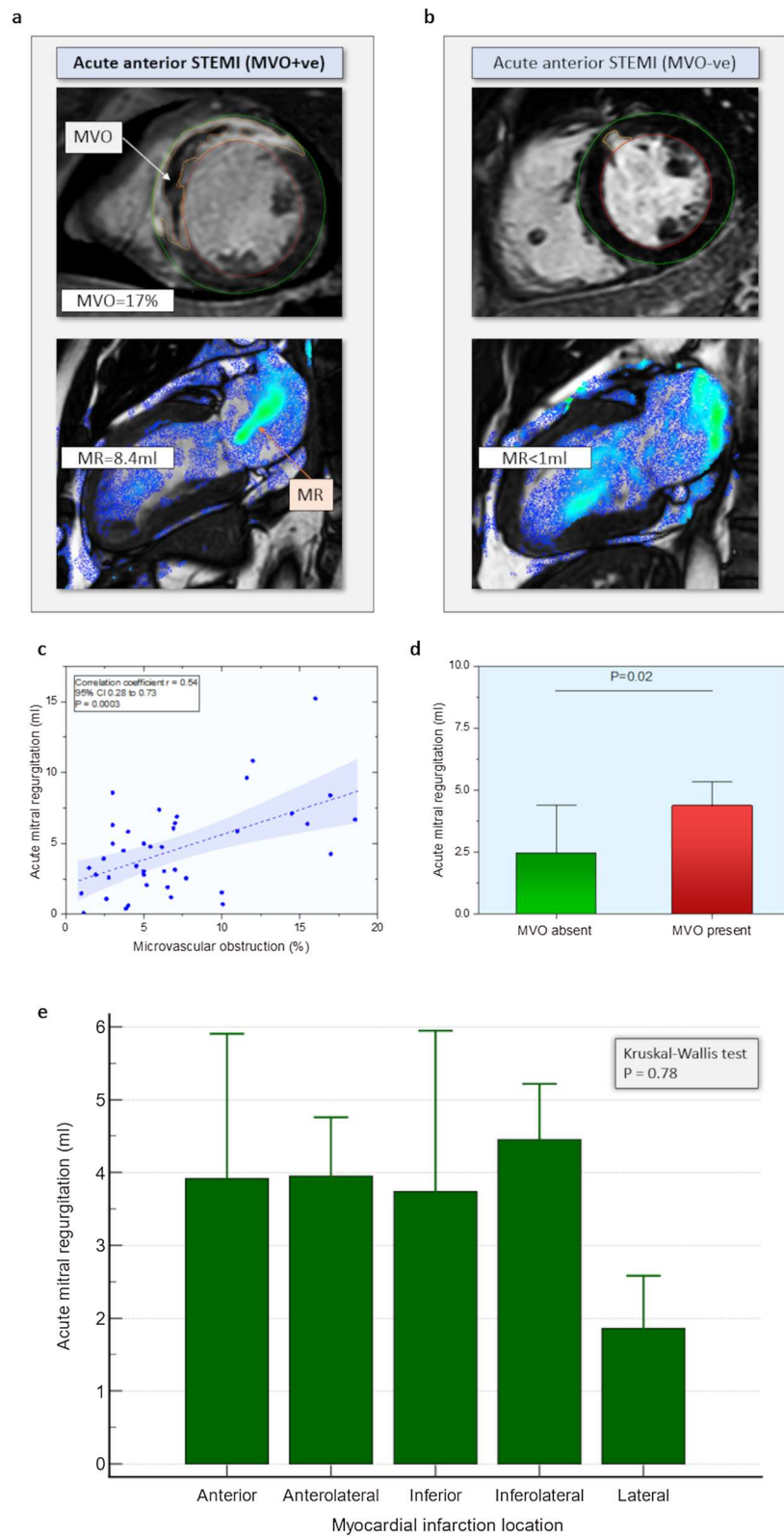
	MVO-ve n = 28	MVO+ve n = 41	P-value
Age (years)	62 ± 13	62 ± 11	0.935
Sex (male)	6 (21)	8 (20)	0.945
Weight (kg)	79 ± 17	83 ± 16	0.321
Height (cm)	172 ± 10	172 ± 8	0.918
BMI	27 ± 5	29 ± 4	0.222
Smoker	23 (79)	18 (45)	0.049
Hypertension	9 (31)	12 (30)	0.392
Hypercholesterolaemia	8 (28)	11 (28)	0.524
Diabetes mellitus	4 (14)	5 (13)	0.877
Family history of CAD	15 (52)	16 (40)	0.91
LVEDV (ml) <sup>a</sup>	147 ± 50	183 ± 48	0.004
LVESV (ml) <sup>a</sup>	73 ± 28	98 ± 49	< 0.001
LVSV (ml)	81 ± 16	73 ± 17	0.053
LV EF (%)	52 ± 8	42 ± 10	< 0.01
LV mass (g)	117 ± 29	129 ± 33	0.13
Scar (% of LV) <sup>a</sup>	11 ± 9	26 ± 19	< 0.001
4D flow mitral SV (ml) <sup>a</sup>	66 ± 26	55 ± 15	0.002
4D flow MR (ml) <sup>a</sup>	2.4 ± 4	4.2 ± 4	0.02

4D four-dimensions, BMI body mass index, CAD coronary artery disease, EF ejection fraction, LV left ventricle, LVEDV left ventricular end-diastolic volume, LVESV left ventricular end-systolic volume, LVSV left ventricular stroke volume, SV stroke volume, MR mitral regurgitation

<sup>a</sup> Non-parametric data (median ± IQR)

(See figure on next page.)

**Fig. 1 a** A case example from the study with a large anterior STEMI with microvascular obstruction and central mitral regurgitation jet with MR volume of 8.4 ml. **b** A case example of a study demonstrating a small infarct with very little evidence of mitral regurgitation. **c** Scatter plot demonstrating an association between the degree of acute MR and MVO. **d** Bar chart demonstrating differences in acute MR and with/without the presence of MVO (median and its standard error, P-value Mann–Whitney). **e** Bar chart of the location of infarct and its association to the extent of acute MR



**Fig. 1** (See legend on previous page.)

**Table 2** Univariate and multi-variate regression of extent of acute MR and MVO to other CMR variables

Independent variables	Univariate			Multivariate		
	Beta	SE	P	Beta	SE	P
Association to extent of MVO						
LV end-diastolic volume (ml)	0.04	0.02	0.01	–	–	–
LV end-systolic volume (ml)	0.08	0.02	<0.0001	–	–	–
LV stroke volume (ml)	–0.11	0.03	0.00	–	–	–
LV ejection fraction (%)	–0.29	0.05	<0.0001	–0.17	0.05	0.002
LV end-diastolic mass (g)	0.05	0.02	0.02	0.03	0.01	0.041
Mitral valve stroke volume (ml)	–0.10	0.03	0.00	–	–	–
LV scar (%)	0.22	0.04	<0.0001	0.12	0.04	0.002
Acute MR (ml)	0.60	0.17	0.00	0.44	0.13	0.001
Association to extent of MR						
LV end-diastolic volume (ml)	0.01	0.01	0.27	–	–	–
LV end-systolic volume (ml)	0.02	0.01	0.14	–	–	–
LV stroke volume (ml)	–0.02	0.02	0.53	–	–	–
LV ejection fraction (%)	–0.04	0.04	0.36	–	–	–
LV end-diastolic mass (gram)	0.01	0.01	0.58	–	–	–
Mitral valve stroke volume (ml)	–0.04	0.02	0.09	–	–	–
LV scar (%)	0.04	0.03	0.15	–	–	–
MVO (%)	0.27	0.07	0.001	–	–	–

ml millilitres, SE standard error, LV left ventricle, CMR cardiovascular magnetic resonance, MR mitral regurgitation, MVO microvascular obstruction

### Independent predictors of acute MR on uni/multi-variate regression

On the contrary, in univariate regression analysis for investigating association to the degree of acute MR, only the extent of MVO was associated (coefficient 0.27,  $P=0.001$ ).

### Discussion

In this study, we report that in reperfused STEMI patients, the extent of acute MR is independently associated with MVO. It is well established that after acute reperfusion therapy in STEMI, both MVO and MR are associated with poorer outcomes [7, 19] and adverse remodelling, leading to heart failure [20, 21]. Importantly, the anatomical and physio-pathological mechanisms from which the acute MR originates have not been fully clarified. For the first time in this study, we have noted the observation that the degree of acute MR immediately after primary percutaneous coronary intervention (PPCI) is independently associated with the extent of MVO.

Prior studies have noted the association between papillary muscle infarction (PapMI) and MR with MVO in patients with STEMI. Lei et al. [22] recruited 209 patients from two centres and demonstrated that patients with PapMI and MR had more MVO when compared with non-PapMI and PapMI only groups ( $P=0.004$ ). These results further support the findings of our study. In an observational study done by Amigoni et al. [20], which

recruited 496 patients, the authors demonstrated that almost 50% of patients did not have any acute MR on colour Doppler, whereas we were able to detect and quantify trivial MR by 4D flow CMR in 100% of cases. In their work, only 10% of patients had moderate MR, and a very limited number of patients had severe MR (2.8%), versus, in our smaller cohort, where none of the patients had moderate or severe MR. We suspect that these observations could be because our study is more contemporary, and PPCI services have significantly evolved since 2006, resulting in lesser ischaemic functional MR. They noted that the degree of MR was associated with ventricular dilatation, whereas we did not see this association. This discrepancy can again be explained by lack of moderate to severe MR in our cohort.

Noting that MVO is associated with larger infarcts and adverse remodelling [21], one could infer from our study that even quantification of milder acute MR is relevant. This is further substantiated by a study that investigated the survival of patients with or without ischaemic MR on colour Doppler and demonstrated that any MR had a significantly worse outcome (log-rank 3.8,  $P=0.05$ ) [23].

Historic study data suggests that ischaemic MR is more seen in inferior MI (61%) versus anterior MI (32%) [24]. However, this is still debated as the data was mainly observational and of a sub-selected patients' cohort with chronic ischaemic MR going for mitral valve surgery versus acute MR. Our study demonstrates that in patients

with trivial to mild acute MR, there remains no association with the location of myocardial infarction. Moreover, the degree of acute MR in this study was not directly associated with any volumetric changes, suggesting that MVO alone, which is a result of a prolonged period of myocardial ischaemia, has a specific pathophysiological process that may be associated with the development of acute MR post-STEMI.

Future studies are warranted to develop a better mechanistic understanding of acute MR in patients with MVO post-reperfusion therapy. In addition, a direct comparison of colour Doppler echocardiography to 4D flow CMR quantified MR is warranted to understand how much MR is needed to be detected by Doppler echocardiography for clinical translation between these two cardiac imaging modalities.

### Conclusions

In patients with reperfused STEMI, the degree of acute MR was associated with the degree of MVO. Future studies are warranted to develop insight into the pathophysiological process of how MVO is associated with acute MR.

### Limitations

Our study has some limitations. The results of our research is hypothesis-generating. Our study results cannot be generalised to all acute myocardial infarction patients. This study did not recruit hemodynamically unstable patients, which potentially introduces selection bias. Additionally, we did not have echocardiographic findings recorded in the study for demonstrating clinical translation between CMR and echocardiography. Prior MR was not exclusion criteria, and we assumed that MR noted on CMR was arising due to the acute myocardial infarction. Finally, this study did not explore the association of other clinical characteristics of acute myocardial infarction presentation and MVO as the sample size was small.

### Abbreviations

4D: Four-dimensional; CMR: Cardiovascular magnetic resonance; EGE: Early Gadolinium Enhancement; IS: Infarct size; LGE: Late gadolinium enhancement; LV: Left ventricle; MR: Mitral regurgitation; MVO: Microvascular obstruction; MI: Myocardial infarction; PPCI: Primary percutaneous coronary intervention; ROC: Receiver-operating characteristics; STEMI: ST-elevation myocardial infarction.

### Acknowledgements

Not applicable.

### Author contributions

PG, SP, JPG, RJvdG and PPS were involved in study conception. HA, CGC, AJS and PG collated the datasets and drafted the manuscript. JPG, SP, PG, AD, RN and PPS were involved in acquisition and analysis, as well as data interpretation. RJvdG assisted with the conception and design of the study, in addition to developing the methods for the study and providing the software for

analysis. SP and JPG supervised the study. AD1, MF, VV, RN, AD2, and AJS provided critical input in methodology, drafting of the manuscript and discussion. PG contributed significantly to the conception, analysis, statistics and writing of this study. All authors read and approved the final manuscript.

### Funding

PG and AJS are funded by Wellcome Trust Clinical Research Career Development Fellowships (220703/Z/20/Z & 205188/Z/16/Z). For the purpose of Open Access, these authors have applied a CC BY public copyright licence to any Author Accepted Manuscript version arising from this submission. The funders had no role in study design, data collection and analysis, decision to publish, or preparation of the manuscript.

### Availability of data and materials

Underlying data: access to the raw images of patients is not permitted since specialised post-processing imaging-based solutions can identify the study patients in the future.

### Declarations

#### Ethics approval and consent to participate

This study was conducted as per the principles outlined in the 1964 Declaration of Helsinki. The collection and management of data were approved by the National Research Ethics Service in the United Kingdom (12/YH/0169). Written informed consent was obtained from all individual participants in the study.

#### Consent for publication

Not applicable.

#### Competing interests

PG has a clinical advisor role with Medis and Pie Medical Imaging. All other authors have no competing interests to declare.

#### Author details

<sup>1</sup>Department of Cardiovascular and Metabolic Health, Norwich Medical School, University of East Anglia, Colney Lane, Norwich NR4 7UQ, UK. <sup>2</sup>Department of Cardiology, Norfolk and Norwich University Hospital, Norwich, UK. <sup>3</sup>Department of Cardiology, Amsterdam UMC, Vrije Universiteit Amsterdam, Amsterdam Cardiovascular Sciences, Amsterdam, The Netherlands. <sup>4</sup>Division of Image Processing, Department of Radiology, Leiden University Medical Center, Leiden, The Netherlands. <sup>5</sup>Department of Cardiology, Radboud University Medical Center, Nijmegen, The Netherlands. <sup>6</sup>Department of Infection, Immunity and Cardiovascular Disease, University of Sheffield, Sheffield, UK. <sup>7</sup>Multidisciplinary Cardiovascular Research Centre & Leeds Institute of Cardiovascular and Metabolic Medicine, University of Leeds, Leeds, UK. <sup>8</sup>Bristol Medical School, University of Bristol, Bristol, UK.

Received: 12 December 2021 Accepted: 5 May 2022

Published online: 15 May 2022

### References

- Garg P, Kidambi A, Foley JRJ, Musa TA, Ripley DP, Swoboda PP, Erhayiem B, Dobson LE, McDiarmid AK, Greenwood JP, Plein S. Ventricular longitudinal function is associated with microvascular obstruction and intramyocardial haemorrhage. *Open Heart*. 2016;3(1): e000337.
- Garg P, Kidambi A, Swoboda PP, Foley JRJ, Musa TA, Ripley DP, Erhayiem B, Dobson LE, McDiarmid AK, Fent GJ, Haaf P, Greenwood JP, Plein S. The role of left ventricular deformation in the assessment of microvascular obstruction and intramyocardial haemorrhage. *Int J Cardiovasc Imaging*. 2017;33(3):361–70.
- Haaf P, Garg P, Messroghli DR, Broadbent DA, Greenwood JP, Plein S. Cardiac T1 mapping and extracellular volume (ECV) in clinical practice: a comprehensive review. *J Cardiovasc Magn Reson*. 2016;18(1):89.
- Garg P, Saunders LC, Swift AJ, Wild JM, Plein S. Role of cardiac T1 mapping and extracellular volume (ECV) in the assessment of myocardial infarction. *Anatol J Cardiol*. 2018;19(6):404.

5. Pellizzon GG, Grines CL, Cox DA, Stuckey T, Tchong JE, Garcia E, Guagliumi G, Turco M, Lansky AJ, Griffin JJ, Cohen DJ, Aymong E, Mehran R, O'Neill WW, Stone GW. Importance of mitral regurgitation inpatients undergoing percutaneous coronary intervention for acute myocardial infarction: the controlled abciximab and device investigation to lower late angioplasty complications (CADILLAC) trial. *J Am Coll Cardiol*. 2004;43(8):1368–74.
6. Cho JS, Youn H-J, Her S-H, Park MW, Kim CJ, Park G-M, Jeong MH, Cho JY, Ahn Y, Kim KH, Park JC, Seung KB, Cho MC, Kim CJ, Kim YJ, Han KR, Kim HS, Korea Acute Myocardial Infarction Registry Investigators. The prognostic value of the left ventricular ejection fraction is dependent upon the severity of mitral regurgitation in patients with acute myocardial infarction. *J Korean Med Sci*. 2015;30(7):903–10.
7. Chung S-Y, Lin F-C, Chua S, Fu M, Wu C-J, Yip H-K, Yeh K-H, Chai H-T, Hsieh Y-K, Hang C-L, Fang C-Y, Chen S-M, Yang C-H, Chen C-J, Lee F-Y, Chen M-C. Clinical profile and outcome of first acute myocardial infarction with ischemic mitral regurgitation. *Chang Gung Med J*. 2008;31(3):268–75.
8. Cavalcante JL, Kusunose K, Obuchowski NA, Jellis C, Griffin BP, Flamm SD, Kwon DH. Prognostic impact of ischemic mitral regurgitation severity and myocardial infarct quantification by cardiovascular magnetic resonance. *JACC Cardiovasc Imaging*. 2020;13(7):1489–501.
9. Garg P, Swift AJ, Zhong L, Carlhäll C-J, Ebberts T, Westenberg J, Hope MD, Bucciarelli-Ducci C, Bax JJ, Myerson SG. Assessment of mitral valve regurgitation by cardiovascular magnetic resonance imaging. *Nat Rev Cardiol*. 2019;17(5):298–312.
10. Fidock B, Barker N, Balasubramanian N, Archer G, Fent G, Al-Mohammad A, Richardson J, O'Toole L, Briffa N, Rothman A, van der Geest R, Hose R, Wild JM, Swift AJ, Garg P. A systematic review of 4D-flow MRI derived mitral regurgitation quantification methods. *Front Cardiovasc Med*. 2019;6:103.
11. Fidock B, Archer G, Barker N, Elhawaz A, Al-Mohammad A, Rothman A, Hose R, Hall IR, Grech E, Briffa N, Lewis N, van der Geest RJ, Zhang J-M, Zhong L, Swift AJ, Wild JM, De Gárate E, Bucciarelli-Ducci C, Bax JJ, Plein S, Myerson S, Garg P. Standard and emerging CMR methods for mitral regurgitation quantification. *Int J Cardiol*. 2021;15(331):316–21.
12. Chew PG, Dobson LE, Garg P, Fairbairn TA, Musa TA, Uddin A, Swoboda PP, Foley JR, Fent GJ, Brown LAE, Onciul S, Plein S, Blackman DJ, Greenwood JP. CMR quantitation of change in mitral regurgitation following transcatheter aortic valve replacement (TAVR): impact on left ventricular reverse remodeling and outcome. *Int J Cardiovasc Imaging*. 2019;35(1):161–70.
13. Juffermans JF, Minderhoud SCS, Wittgren J, Kilburg A, Ese A, Fidock B, Zheng Y-C, Zhang J-M, Blanken CPS, Lamb HJ, Goeman JJ, Carlsson M, Zhao S, Planken RN, van Ooij P, Zhong L, Chen X, Garg P, Emrich T, Hirsch A, Töger J, Westenberg JJM. Multicenter consistency assessment of valvular flow quantification with automated valve tracking in 4D flow CMR. *JACC Cardiovasc Imaging*. 2021;14(7):1354–66.
14. Garg P, Broadbent DA, Swoboda PP, Foley JR, Fent GJ, Musa TA, Ripley DP, Erhayiem B, Dobson LE, McDiarmid AK, Haaf P, Kidambi A, van der Geest RJ, Greenwood JP, Plein S. Acute infarct extracellular volume mapping to quantify myocardial area at risk and chronic infarct size on cardiovascular magnetic resonance imaging. *Circ Cardiovasc Imaging*. 2017;10(7):e006182.
15. Garg P, Crandon S, Swoboda PP, Fent GJ, Foley JR, Chew PG, Brown LAE, Vijayan S, Hassell MECJ, Nijveldt R, Bissell M, Elbaz MSM, Al-Mohammad A, Westenberg JJM, Greenwood JP, van der Geest RJ, Plein S, Dall'Armellina E. Left ventricular blood flow kinetic energy after myocardial infarction—insights from 4D flow cardiovascular magnetic resonance. *J Cardiovasc Magn Reson*. 2018;20(1):61.
16. Mills MT, Grafton-Clarke C, Williams G, Gosling RC, Al Baraikana A, Kyriacou AL, Morris PD, Gunn JP, Swoboda PP, Levelt E, Tsampasian V, van der Geest RJ, Swift AJ, Greenwood JP, Plein S, Vassiliou V, Garg P. Feasibility and validation of trans-valvular flow derived by four-dimensional flow cardiovascular magnetic resonance imaging in patients with atrial fibrillation. *Wellcome Open Res*. 2021;6:73.
17. Barker N, Zafar H, Fidock B, Elhawaz A, Al-Mohammad A, Rothman A, Kiely DG, van der Geest RJ, Westenberg J, Swift AJ, Wild JM, Plein S, Garg P. Age-associated changes in 4D flow CMR derived tricuspid valvular flow and right ventricular blood flow kinetic energy. *Sci Rep*. 2020;10(1):9908.
18. Garg P, van der Geest RJ, Swoboda PP, Crandon S, Fent GJ, Foley JR, Dobson LE, Al Musa T, Onciul S, Vijayan S, Chew PG, Brown LAE, Bissell M, Hassell MECJ, Nijveldt R, Elbaz MSM, Westenberg JJM, Dall'Armellina E, Greenwood JP, Plein S. Left ventricular thrombus formation in myocardial infarction is associated with altered left ventricular blood flow energetics. *Eur Heart J Cardiovasc Imaging*. 2018;20(1):108–17.
19. Klug G, Mayr A, Schenk S, Esterhammer R, Schocke M, Nocker M, Jaschke W, Pachinger O, Metzler B. Prognostic value at 5 years of microvascular obstruction after acute myocardial infarction assessed by cardiovascular magnetic resonance. *J Cardiovasc Magn Reson*. 2012;14:46.
20. Amigoni M, Meris A, Thune JJ, Mangalat D, Skali H, Bourgoun M, Warnica JW, Barvik S, Arnold JMO, Velazquez EJ, Van de Werf F, Ghali J, McMurray JJV, Køber L, Pfeffer MA, Solomon SD. Mitral regurgitation in myocardial infarction complicated by heart failure, left ventricular dysfunction, or both: prognostic significance and relation to ventricular size and function. *Eur Heart J*. 2007;28(3):326–33.
21. Lombardo A, Niccoli G, Natale L, Bernardini A, Cosentino N, Bonomo L, Crea F. Impact of microvascular obstruction and infarct size on left ventricular remodeling in reperfused myocardial infarction: a contrast-enhanced cardiac magnetic resonance imaging study. *Int J Cardiovasc Imaging*. 2012;28(4):835–42.
22. Lei D, Xie J, Dai Q, Huang Y, Wei X, Mu D, Bao X, Li J, Xu B. Prognostic relevance and clinical features of papillary muscle infarction with mitral regurgitation in patients with ST segment elevation myocardial infarction. *J Thorac Dis*. 2021;13(1):334–42.
23. Uchikawa S-I, Ohtaki E, Sumiyoshi T, Hosoda S, Kasegawa H. Impact of mitral regurgitation on long-term survival in patients with ischemic cardiomyopathy: efficacy of combined mitral valve repair and revascularization. *Heart Vessels*. 2004;19(4):172–8.
24. Calafiore AM, Di Mauro M, Gallina S, Di Giammarco G, Iacò AL, Teodorici, Tavarozzi I. Mitral valve surgery for chronic ischemic mitral regurgitation. *Ann Thorac Surg*. 2004;77(6):1989–97.

## Publisher's Note

Springer Nature remains neutral with regard to jurisdictional claims in published maps and institutional affiliations.

### Ready to submit your research? Choose BMC and benefit from:

- fast, convenient online submission
- thorough peer review by experienced researchers in your field
- rapid publication on acceptance
- support for research data, including large and complex data types
- gold Open Access which fosters wider collaboration and increased citations
- maximum visibility for your research: over 100M website views per year

At BMC, research is always in progress.

Learn more [biomedcentral.com/submissions](https://biomedcentral.com/submissions)

