



This is a repository copy of *Abnormal corneal nerve morphology and brain volume in patients with schizophrenia.*

White Rose Research Online URL for this paper:
<https://eprints.whiterose.ac.uk/183737/>

Version: Published Version

Article:

Ponirakis, G., Ghandi, R., Ahmed, A. et al. (17 more authors) (2022) Abnormal corneal nerve morphology and brain volume in patients with schizophrenia. *Scientific Reports*, 12 (1). 1870.

<https://doi.org/10.1038/s41598-022-05609-w>

Reuse

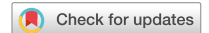This article is distributed under the terms of the Creative Commons Attribution (CC BY) licence. This licence allows you to distribute, remix, tweak, and build upon the work, even commercially, as long as you credit the authors for the original work. More information and the full terms of the licence here:
<https://creativecommons.org/licenses/>

Takedown

If you consider content in White Rose Research Online to be in breach of UK law, please notify us by emailing eprints@whiterose.ac.uk including the URL of the record and the reason for the withdrawal request.



eprints@whiterose.ac.uk
<https://eprints.whiterose.ac.uk/>



OPEN

Abnormal corneal nerve morphology and brain volume in patients with schizophrenia

Georgios Ponirakis¹, Reem Ghandi², Amani Ahmed², Hoda Gad¹, Ioannis N. Petropoulos¹, Adnan Khan¹, Ahmed Elsotouhy^{1,3}, Surjith Vattoth⁴, Mahmoud K. M. Alshawwaf², Mohamed Adil Shah Khoodoruth², Marwan Ramadan⁵, Anjushri Bhagat², James Currie², Ziyad Mahfoud¹, Hanadi Al Hamad⁵, Ahmed Own³, Peter M. Haddad^{2,6,8}, Majid Alabdulla^{2,6}, Rayaz A. Malik^{1,7,10} & Peter W. Woodruff^{1,2,9,10}✉

Neurodevelopmental and neurodegenerative pathology occur in Schizophrenia. This study compared the utility of corneal confocal microscopy (CCM), an ophthalmic imaging technique with MRI brain volumetry in quantifying neuronal pathology and its relationship to cognitive dysfunction and symptom severity in schizophrenia. Thirty-six subjects with schizophrenia and 26 controls underwent assessment of cognitive function, symptom severity, CCM and MRI brain volumetry. Subjects with schizophrenia had lower cognitive function ($P \leq 0.01$), corneal nerve fiber density (CNFD), length (CNFL), branch density (CNBD), CNBD:CNFD ratio ($P < 0.0001$) and cingulate gyrus volume ($P < 0.05$) but comparable volume of whole brain ($P = 0.61$), cortical gray matter ($P = 0.99$), ventricle ($P = 0.47$), hippocampus ($P = 0.10$) and amygdala ($P = 0.68$). Corneal nerve measures and cingulate gyrus volume showed no association with symptom severity ($P = 0.35$ – 0.86 and $P = 0.50$) or cognitive function ($P = 0.35$ – 0.86 and $P = 0.49$). Corneal nerve measures were not associated with metabolic syndrome ($P = 0.61$ – 0.64) or diabetes ($P = 0.057$ – 0.54). The area under the ROC curve distinguishing subjects with schizophrenia from controls was 88% for CNFL, 84% for CNBD and CNBD:CNFD ratio, 79% for CNFD and 73% for the cingulate gyrus volume. This study has identified a reduction in corneal nerve fibers and cingulate gyrus volume in schizophrenia, but no association with symptom severity or cognitive dysfunction. Corneal nerve loss identified using CCM may act as a rapid non-invasive surrogate marker of neurodegeneration in patients with schizophrenia.

Schizophrenia is a major psychosis associated with significant neurocognitive dysfunction and disability. Both neurodevelopmental and neurodegenerative processes may contribute to schizophrenia^{1,2}. Currently, there are no validated surrogate markers of neuronal pathology in schizophrenia.

In patients with schizophrenia, cross-sectional MRI studies have reported a lower brain volume^{3,4} and longitudinal studies have shown a progressive reduction in brain volume⁵. However, both global and regional alterations in brain structure have not been associated with the presence or severity of psychosis⁶. Therefore, brain MRI has not been utilized as a clinical-decision making tool in schizophrenia⁷. Additional studies utilizing electroretinography (ERG) and optical coherence tomography (OCT) have shown a reduction in photoreceptor and bipolar cell activity and retinal nerve fiber layer and macular volumes, respectively⁸, suggesting more widespread neurodegeneration in schizophrenia. Atrophy of ganglion cell axons could be attributed to dopamine dysregulation⁹. However, it is important to note that in schizophrenia; smoking, poor nutritional intake with vitamin B₁₂ and D deficiency as well as physical inactivity and antipsychotic medications can lead to obesity, hypertension, metabolic syndrome and diabetes which may also contribute to neurodegeneration^{10–12}.

¹Department of Medicine, Weill Cornell Medicine-Qatar, Qatar Foundation, Education City, Doha, Qatar. ²Psychiatry Hospital, Mental Health Service, Hamad Medical Corporation, Doha, Qatar. ³Neuroradiology, Hamad General Hospital, Hamad Medical Corporation, Doha, Qatar. ⁴Radiology, University of Arkansas for Medical Sciences, Little Rock, AR, USA. ⁵Geriatric, Rumailah Hospital, Hamad Medical Corporation, Doha, Qatar. ⁶College of Medicine, Qatar University, Doha, Qatar. ⁷Institute of Cardiovascular Science, University of Manchester, Manchester, UK. ⁸Division of Psychology and Mental Health, School of Health Sciences, University of Manchester, Manchester, UK. ⁹Department of Neuroscience, School of Medicine, University of Sheffield, Western Bank, Sheffield S10 2TN, South Yorkshire, UK. ¹⁰These authors jointly supervised this work: Rayaz A. Malik and Peter W. Woodruff. ✉email: p.w.woodruff@sheffield.ac.uk

Corneal nerves in the sub-basal plexus are comprised of unmyelinated C-fibers that convey thermal and mechanical sensation to protect the eye from injury¹³. Corneal confocal microscopy (CCM) is a rapid non-invasive ophthalmic imaging technique that has been utilized to demonstrate corneal nerve loss in a range of peripheral neuropathies including diabetic neuropathy¹⁴, HIV neuropathy¹⁵, and recently long-COVID¹⁶. We and others have also shown corneal nerve fiber loss in patients with dementia¹⁷ and multiple sclerosis¹⁸.

It is hypothesized that patients with schizophrenia will have evidence of corneal nerve loss independent of other risk factors for neuropathy, including metabolic syndrome and diabetes. This is the first study to quantify corneal nerve pathology and regional MRI brain volumes in relation to symptom severity and cognitive function in patients with schizophrenia.

Methods

Study design. This is an exploratory cross-sectional study. Subjects with schizophrenia were enrolled from the Psychiatry Hospital in Qatar and healthy controls were enrolled from Weill Cornell Medicine-Qatar, Rumailah Hospital and the Psychiatry Hospital in Qatar between August 26, 2019 and March 11, 2020. The authors assert that all procedures contributing to this work comply with the ethical standards of the relevant national and institutional committees and with the Helsinki Declaration. All procedures involving human subjects/patients were approved by the Weill Cornell Medicine in Qatar IRB (# 19-00031) and Hamad Medical Corporation IRB (# IRGC-04-SI-17-166). Written informed consent was obtained from all subjects/patients.

Inclusion and exclusion criteria. Subjects with schizophrenia and healthy controls aged 18–65 years old were recruited. Exclusion criteria for schizophrenia included mental illness other than schizophrenia or causes of peripheral neuropathy other than diabetes. Exclusion criteria for controls included mental illness, causes of peripheral neuropathy or diabetes. Other exclusion criteria included substance abuse except nicotine and caffeine, corneal trauma, dystrophy, surgery, severe dry eyes or allergy to local anesthetics.

Diagnosis. The diagnosis of schizophrenia was made by psychiatrists using the Diagnostic and Statistical Manual of Mental Disorders (DSM-5) criteria¹⁹. Each person had two or more core symptoms, one of which was hallucinations, delusions, or disorganized speech for at least one month and gross disorganization and diminished emotional expression. Other DSM-5 criteria for the diagnosis of schizophrenia included (1) level of work, interpersonal relations or self-care significantly below the start of symptoms, (2) signs of disturbance for at least 6 months, (3) schizoaffective disorder and depressive or bipolar disorder with psychotic symptoms ruled out and (4) the disturbance was not caused by substance abuse or another medical condition. Subjects with schizophrenia underwent clinical interview and psychiatric assessment using the Positive and Negative Syndrome Scale (PANSS) English and Arabic version²⁰ and cognitive function assessment using the Montreal Cognitive Assessment (MoCA) English and Arabic version test, whereas healthy controls underwent MoCA only. Both the PANSS and MoCA were administered by one investigator who was an English and Arabic speaker and was trained on the use and interpretation of the PANSS and MoCA. The MoCA was utilized as a continuous variable to assess cognitive function but not to define cognitive impairment in patients with schizophrenia. It assesses a broad range of cognitive domains, including memory, executive functions, attention and visuospatial ability, has a short administration time and widespread international use²¹.

Demographic and clinical characteristics. Age, sex, duration of schizophrenia, presence of diabetes, blood pressure, body mass index (BMI), medical history, HbA1c, lipid profile, creatinine, vitamin B₁₂ and vitamin D were recorded. Hypertension was defined according to the WHO/ISH Guidelines²². Hyperlipidemia was defined according to a total cholesterol level ≥ 6.2 mmol/L and/or triglyceride level of ≥ 2.3 mmol/L or if the patient was treated with a statin. Obesity was classified according to WHO criteria with a BMI ≥ 30 kg/m²²³. Current smoking cigarette was defined as having smoked at least one cigarette every day for ≥ 1 year. Metabolic syndrome was defined using the WHO 1999 criteria²⁴.

Corneal confocal microscopy (CCM) image acquisition and analysis. CCM was performed with the Heidelberg Retinal Tomograph III Rostock Cornea Module (Heidelberg Engineering GmbH, Heidelberg, Germany). A 63 \times objective lens with a numerical aperture of 0.9 and a working distance, relative to the applanating cap (TomoCap, Heidelberg Engineering GmbH, Heidelberg, Germany) of 0.0–3.0 mm was used. The images produced using this lens are 400 $\mu\text{m} \times 400 \mu\text{m}$ with a 15 $^\circ \times 15^\circ$ field of view and 10 $\mu\text{m}/\text{pixel}$ transverse optical resolution. The cornea was locally anesthetized by instilling 1 drop of 0.4% benoxinate hydrochloride (Chauvin Pharmaceuticals, Chefaro, UK) and Viscotears (Carbomer 980, 0.2%, Novartis, UK) was used as the coupling agent between the cornea and the TomoCap and between the TomoCap and objective lens. Images of the sub-basal nerve plexus were captured using the “section” mode. CCM image extraction was performed at a separate time by an investigator who was blinded to the patient diagnosis. Three to five representative images of the sub-basal nerve plexus were selected per eye. CCMetrics, a validated image analysis software²⁵ was used to quantify corneal nerve fiber density (CNFD, fibers/mm²), branch density (CNBD, branches/mm²), fiber length (CNFL, mm/mm²) and CNBD:CNFD ratio.

MRI brain acquisition and volume analysis. MRI was performed on a superconductive magnet operated at 3 T (Skyra, Siemens). A T1-weighted 3D magnetization prepared rapid acquisition gradient echo sequence (MPRAGE) was obtained in the sagittal plane with a 1 mm slice thickness, repetition time of 1900 ms, echo time of 2.67 ms and 2.46 ms, inversion time of 1100 ms and 900 ms, flip angle of 9 $^\circ$ and 15 $^\circ$, and FOV = 240 \times 100. Coro-

nal and axial reformatted MPRAGE images were reconstructed from the sagittal 3D sequence. MRI T1-weighted 3D MPRAGE sequences were processed using NeuroQuant (NQ), an FDA approved fully automated software²⁶ to segment brain structures and measure the intracranial volume (ICV) adjusted percentage of the whole brain, cortical gray matter, ventricle, cingulate gyrus, hippocampi, amygdala, thalamus and entorhinal cortex.

Peripheral neuropathy assessments. Vibration perception threshold (VPT) was measured as volts (V) on the pulp of the large toe using a Neurothesiometer (Horwell, Scientific Laboratory Supplies, Wilford, Nottingham, UK). Sudoscan, was used to measure sudomotor function in the feet expressed as electrochemical skin conductance (ESC) and measured in microSiemens (μS).

Statistical analysis. This was the first exploratory study of CCM in schizophrenia, therefore no power calculation was determined. Continuous and categorical variables between subjects with schizophrenia and healthy controls were compared using the unpaired t-test and chi-square, respectively. Pearson's correlation coefficients were calculated to determine the association between intracranial volume of the cingulate gyrus and corneal nerve branch to fiber density ratio.

Univariate analysis by simple linear regression was performed between independent variables and corneal nerve measures and MRI brain volume as the dependent variable. The multiple linear regression analysis included all variables with $P \leq 0.05$ at the bivariate level. The regression coefficient (beta) and the corresponding 95% confidence intervals (95% CI) are presented. The R-squared values are presented. The model that yielded the highest R-squared value was the preferred one.

Receiver operating characteristic (ROC) curve analysis was used to determine the diagnostic ability of CCM, MRI brain volume and cognitive function to distinguish subjects with schizophrenia from healthy controls. The area under curve (AUC), and cut-off points with the maximal sum of sensitivity and specificity were selected.

Analysis of all data was performed using Statistical Package for the Social Sciences (SPSS). A two-tailed P value of ≤ 0.05 was considered significant.

Results

Demographic and clinical characteristics. Subjects ($n = 36$) with a mean duration of 11.1 ± 8.1 years of schizophrenia and healthy controls ($n = 26$) were studied. The clinical characteristics of these groups are summarized in Supplementary Table 1. Both groups had comparable age (33.7 ± 11.1 years vs 35.3 ± 11.1 years, $t = 0.5$, $P = 0.59$), sex ($P = 0.38$), percentage of cigarette smokers (27.8% vs 15.4% , $\chi^2 = 1.3$, $P = 0.25$), percentage with obesity ($P = 0.21$), systolic and diastolic blood pressure ($P = 0.98$), HbA1c ($P = 0.06$), creatinine ($P = 0.80$), total cholesterol ($P = 0.32$), triglycerides ($P = 0.88$), HDL ($P = 0.64$), LDL ($P = 0.39$), 25OHD ($P = 0.47$) and vitamin B₁₂ ($P = 0.39$). However, subjects with schizophrenia had a higher BMI (32.9 ± 9.1 kg/m² vs 27.5 ± 5.2 kg/m², $t = 2.9$, $P < 0.001$), percentage with hypertension (44.4% vs 11.5% , $\chi^2 = 7.7$, $P < 0.01$), and hyperlipidemia (33.3% vs 7.7% , $\chi^2 = 5.7$, $P < 0.05$) compared to healthy controls. The prevalence of diabetes and metabolic syndrome in patients with schizophrenia was 27.8% ($n = 10/36$) and 30.6% ($n = 11/36$), respectively. The HbA1c of subjects with schizophrenia and diabetes was $6.6 \pm 1.6\%$. The percentage of antipsychotic drug use which was more likely to cause dry eyes (1–10% risk of dry eyes) was lower than those with a 0.1–1% risk of dry eyes (31.7% vs 68.3%).

PANSS total symptom severity ranged from 41 to 100 with a mean of 68.4 ± 12.7 . Cognitive function measured by MoCA was significantly lower in subjects with schizophrenia compared to healthy controls (MoCA: 24.2 ± 3.6 vs 26.8 ± 2.8 , $t = 3.0$, $P \leq 0.01$). After adjusting for creatinine, the association of schizophrenia with reduced cognitive function remained significant (β coefficient: -2.6 , 95% CI -4.7 , -0.6 , $P = 0.01$). The association between schizophrenia and cognitive function also remained significant after adjusting for diabetes, hypertension, hyperlipidemia and BMI, although the adjusted r^2 was lower after adjusting for these imbalances (r^2 : 0.19 vs 0.23).

Peripheral neuropathy assessment (Table 1). Subjects with schizophrenia had comparable vibration perception threshold (VPT) ($P = 0.32$) and sudomotor function ($P = 0.09$) to control subjects.

Corneal nerve fiber measures (Tables 1, 2 and Fig. 1). All subjects completed CCM assessments without expressing any concerns about the eye drop or contact of the cornea with the TomoCap. Subjects with schizophrenia had a significantly lower CNFD (fibers/mm²) (27.9 ± 9.1 vs 37.3 ± 6.7 , $t = 4.6$, $P < 0.0001$), CNBD (branches/mm²) (41.9 ± 28.9 vs 87.6 ± 29.3 , $t = 6.0$, $P < 0.0001$), CNFL (mm/mm²) (16.7 ± 5.4 vs 24.6 ± 3.9 , $t = 6.5$, $P < 0.0001$) and CNBD:CNFD ratio (1.4 ± 0.7 vs 2.4 ± 0.8 , $t = 4.7$, $P < 0.0001$) compared to controls (Fig. 1 and Table 1). Subjects with schizophrenia without diabetes also had a significantly lower CNFD (fibers/mm²) (26.8 ± 7.8 vs 37.3 ± 6.7 , $t = 5.0$, $P < 0.0001$), CNBD (branches/mm²) (40.0 ± 23.5 vs 87.6 ± 29.3 , $t = 6.3$, $P < 0.0001$), CNFL (mm/mm²) (16.2 ± 4.2 vs 24.6 ± 3.9 , $t = 7.2$, $P < 0.0001$) and CNBD:CNFD ratio (1.5 ± 0.7 vs 2.4 ± 0.8 , $t = 4.4$, $P < 0.0001$) compared to controls.

As shown in Table 2, CNFD adjusted for cigarette smoking, BMI, and VPT was significantly and negatively associated with schizophrenia (β coefficient: -5.2 fibers/mm², 95% CI -9.4 , -1.0 , $P < 0.05$). Reduced CNFD remained significantly and independently associated with cigarette smoking ($P < 0.01$), BMI ($P = 0.01$), and VPT ($P = 0.01$). Similarly, CNBD (β coefficient: -41.4 branches/mm², 95% CI -62.0 , -20.8 , $P < 0.0001$) and CNFL (β coefficient -7.1 mm/mm², 95% CI -10.6 , -3.6 , $P < 0.0001$) adjusted for BMI and sleep were significantly and negatively associated with schizophrenia. CNBD:CNFD ratio adjusted for cingulate gyrus and hippocampus volumes and sudomotor function lost its significant association with schizophrenia ($P = 0.33$). In the multiple linear regression analysis, CNBD:CNFD ratio remained significantly and positively associated with cingulate gyrus volume ($P = 0.01$) and sudomotor function ($P < 0.01$). After adjusting for the imbalances between subjects with schizophrenia and healthy controls for diabetes, hypertension, hyperlipidemia and BMI, schizophrenia

	Controls (n = 26)	Schizophrenia (n = 36)	P value	T value
MoCA score	26.8 ± 2.8	24.2 ± 3.6	< 0.01	3.0
Corneal nerve morphology				
CNFD (fibers/mm ²)	37.3 ± 6.7	27.9 ± 9.1	< 0.0001	4.6
CNBD (branches/mm ²)	87.6 ± 29.3	41.9 ± 28.9	< 0.0001	6.0
CNFL (mm/mm ²)	24.6 ± 3.9	16.7 ± 5.4	< 0.0001	6.5
CNBD:CNFD ratio	2.4 ± 0.8	1.4 ± 0.7	< 0.0001	4.7
Volumetric analysis of brain MRI				
Whole brain (ICV %)	76.5 ± 3.8	77.2 ± 2.3	0.61	-0.5
Cortical gray matter (ICV %)	34.2 ± 3.4	34.2 ± 1.7	0.99	-0.001
Ventricle (ICV %)	1.4 ± 0.8	1.6 ± 0.6	0.47	-0.7
Cingulate gyrus (ICV %)	0.89 ± 0.08	0.83 ± 0.07	< 0.05	2.2
Hippocampus (ICV %)	0.54 ± 0.03	0.51 ± 0.05	0.10	1.7
Amygdala (ICV %)	0.24 ± 0.03	0.23 ± 0.03	0.68	0.4
Thalamus (ICV %)	0.92 ± 0.09	0.97 ± 0.08	0.20	-1.3
Entorhinal cortex (ICV %)	0.33 ± 0.05	0.35 ± 0.06	0.26	-1.2
Measures of peripheral neuropathy				
VPT (V)	4.7 ± 2.9	5.9 ± 5.4	0.32	-1.0
ESC feet (μS)	70.1 ± 12.7	62.9 ± 19.9	0.09	1.7

Table 1. Comparison of cognitive function, corneal nerve morphology, volumetric brain MRI and measures of peripheral neuropathy between subjects with schizophrenia and controls. Numeric variables and frequency distribution for categorical variables are summarized as mean ± standard deviation or n (%). Variables were compared using unpaired t-test. Categorical variables were compared using χ^2 . *MoCA* montreal cognitive assessment, *CNFD* corneal nerve fiber density, *CNFL* length, *CNBD* branch density, *VPT* vibration perception threshold, *ESC* electrochemical skin conductance, *ICV* intra cranial volume.

	Adjusted mean difference	95% confidence interval	P value
CNFD (fibers/mm²) (min.-max: 10.4–49.1)			
Schizophrenia	- 5.2	- 9.4, - 1.0	< 0.05
Smoking cigarette	- 6.5	- 11.2, - 1.8	< 0.01
BMI (kg/m ²)	- 0.4	- 0.6, - 0.1	0.01
VPT (V)	- 0.6	- 1.0, - 0.1	0.01
CNBD (branches/mm²) (min.-max: 7.6–142.2)			
Schizophrenia	- 41.4	- 62.0, - 20.8	< 0.0001
BMI (kg/m ²)	- 0.3	- 1.3, 0.8	0.63
Sleep (h)	- 3.0	- 6.4, 0.4	0.08
CNFL (mm/mm²) (min.-max: 5.9–32.9)			
Schizophrenia	- 7.1	- 10.6, - 3.6	< 0.0001
BMI (kg/m ²)	- 0.1	- 0.1, 0.3	0.18
Sleep (h)	- 0.3	- 0.2, 0.9	0.23
CNBD:CNFD ratio (min.-max: 0.4–4.1)			
Schizophrenia	- 0.3	- 0.9, 0.3	0.33
Cingulate gyrus (ICV %)	4.6	1.2, 8.1	0.01
Hippocampus (ICV %)	3.1	- 2.5, 8.6	0.26
ESC feet (μS)	0.02	0.01, 0.03	< 0.01
Cingulate gyrus (ICV %) (min.-max: 0.70–1.04)			
Schizophrenia	- 0.07	- 0.13, - 0.01	< 0.05

Table 2. The association of cognitive function, corneal nerve fiber measures, cingulate gyrus volume with schizophrenia after adjustment for cofounders. All the variables considered in the fitted model had $P < 0.05$. The cingulate gyrus volume includes Rostral Anterior Cingulate Gyrus and Caudal Anterior Cingulate Gyrus. *CNFD* corneal nerve fiber density, *CNFL* length, *CNBD* branch density, *VPT* vibration perception threshold, *ESC* electrochemical skin conductance, *ICV* intra cranial volume.

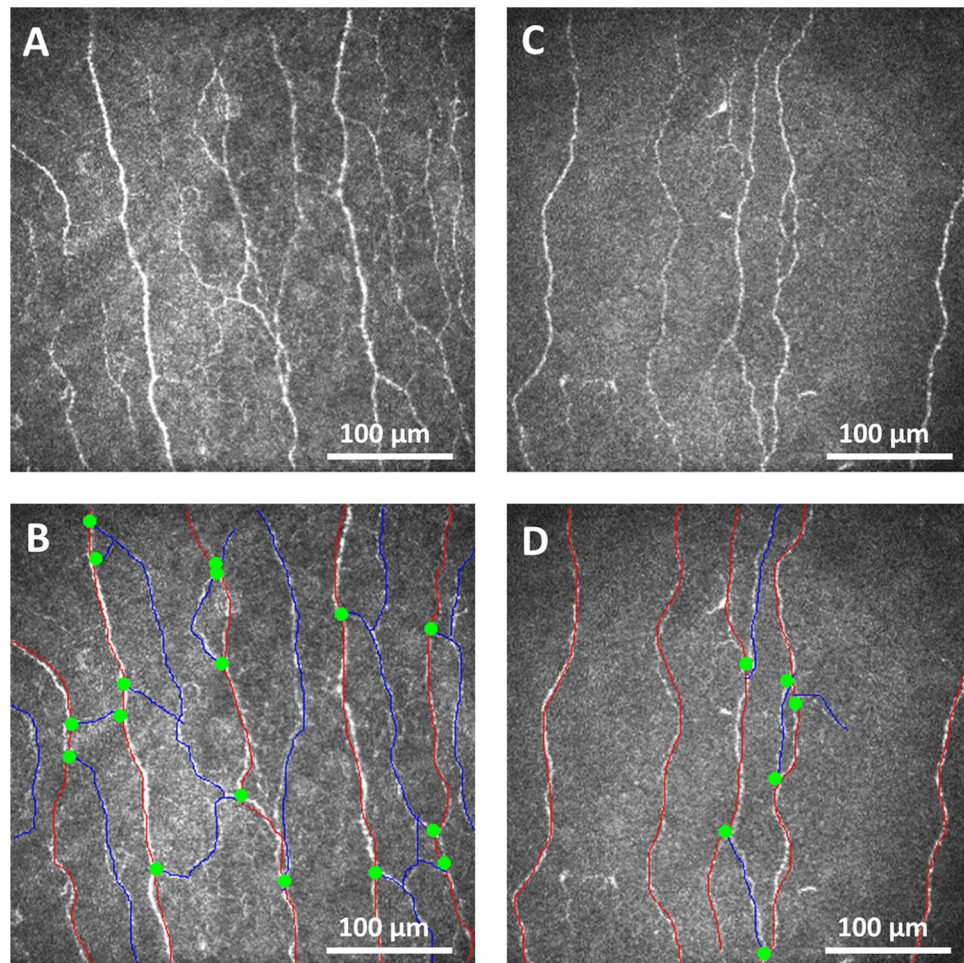


Figure 1. Corneal nerve fiber morphology in a healthy control and subject with schizophrenia. Corneal confocal microscopy (CCM) images of the sub-basal nerve plexus from a health control subject (**A**) with the nerves traced (**B**) and a subject with schizophrenia (**C**) with nerves traced (**D**) showing reduced corneal nerve fiber density (red lines), branch density (green dots) and length (red and blue lines) in the subject with schizophrenia compared to the healthy control.

remained a significant independent variable for corneal nerve measures but the r^2 was lower for CNFD (r^2 : 0.40 vs 0.43), CNBD (r^2 : 0.37 vs 0.41) and CNFL (r^2 : 0.41 vs 0.42).

Corneal nerve measures had no significant association with metabolic syndrome ($P=0.61-0.64$), diabetes ($P=0.057-0.54$) (Supplementary Table 2), antipsychotic drugs with the highest risk of dry eyes (1–10%) ($P=0.48-0.78$), symptom severity of schizophrenia ($P=0.35-0.86$), hemoglobin ($P=0.32-0.50$), cognitive function ($P=0.051-0.67$), antidepressants ($P=0.18-0.92$) and treatment for movement disorders ($P=0.28-0.51$). Supplementary Table 2 shows that there was a small non-significant loss of corneal nerves in those with ($n=10$) compared to without ($n=52$) diabetes.

Volumetric brain MRI (Tables 1 and 2). Whole brain ($P=0.61$), cortical gray matter ($P=0.99$), ventricle ($P=0.47$), hippocampus ($P=0.10$), amygdala ($P=0.68$), thalamus ($P=0.20$) and entorhinal cortex ($P=0.26$) volumes did not differ, but the mean cingulate gyrus volume was significantly lower in subjects with schizophrenia compared to healthy controls (0.83 ± 0.07 vs 0.89 ± 0.08 , $P < 0.05$, Cohen's $d = 0.80$).

Cingulate gyrus volume was significantly and negatively associated with schizophrenia (β coefficient: -0.07 , 95% CI $-0.13, -0.01$, $P < 0.05$). Adjustment for imbalances between subjects with schizophrenia and healthy controls resulted in a sharp drop in the adjusted r^2 (r^2 : 0.13 vs 0.08) with minimal change for the β coefficient (-0.08) and thus the earlier model was adopted.

Cingulate gyrus volume showed no association with symptom severity of schizophrenia ($P=0.50$), hemoglobin ($P=0.64$), cognitive function ($P=0.49$), antidepressants ($P=0.85$), and treatment for movement disorders ($P=0.89$).

Diagnostic utility for schizophrenia (Table 3 and Fig. 2). The AUC to distinguish subjects with schizophrenia from healthy controls was 88% for CNFL ($P < 0.0001$), 84% for CNBD ($P < 0.0001$), 84% for

	AUC % (95% CI)	Cutoff value	Sensitivity %	Specificity %	P-value
MoCA score	70 (57–84)	≤27	73	58	<0.01
CNFD (fibers/mm ²)	79 (68–91)	≤36	79	58	<0.0001
CNBD (branches/mm ²)	88 (79–97)	≤61	82	85	<0.0001
CNFL (mm/mm ²)	88 (79–96)	≤21	79	81	<0.0001
CNBD:CNFD ratio	84 (74–95)	≤1.9	85	81	<0.0001
Cingulate gyrus (ICV %)	73 (54–92)	≤0.84	61	80	<0.05

Table 3. Diagnostic accuracy of montreal cognitive assessment (MoCA), corneal confocal microscopy (CCM) and cingulate gyrus volume for schizophrenia. AUC area under the curve, CNFD corneal nerve fiber density, CNBD branch density, CNFL fiber length.

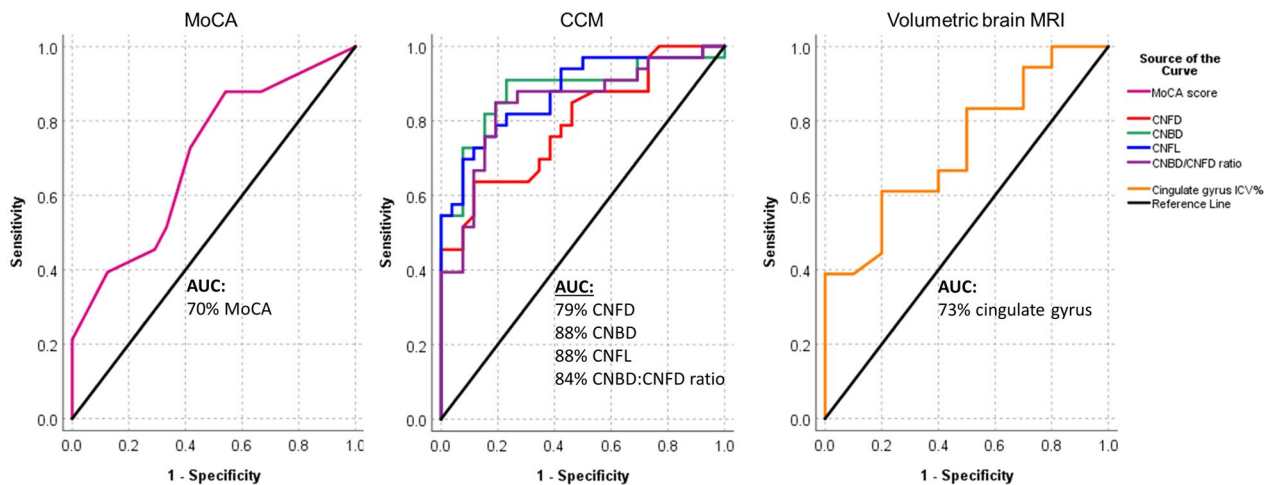


Figure 2. ROC curves showing the diagnostic accuracy of MoCA, corneal nerve fiber measures and cingulate gyrus volume for schizophrenia. ROC analysis expressed as area under the curve (AUC) to determine the effectiveness of MoCA, corneal nerve fiber measures and cingulate gyrus volume to discriminate subjects with schizophrenia from healthy controls.

CNBD:CNFD ratio ($P < 0.0001$), 79% for CNFD ($P < 0.0001$), 73% for the cingulate gyrus ICV% ($P < 0.05$) and 70% for MoCA ($P < 0.01$). The sensitivity and specificity for schizophrenia was 82% and 85% with a CNBD cut-off of ≤ 61 branches/mm², 79% and 81% with a CNFL cut-off of ≤ 21 mm/mm², 85% and 81% with a CNBD:CNFD ratio cut-off of ≤ 1.9 , 79% and 58% with a CNFD cut-off of ≤ 36 fibers/mm², 61% and 80% with a cingulate gyrus volume cut-off of ≤ 0.84 ICV%, and 73% and 58% with a MoCA cut-off of ≤ 27 .

Discussion

This study shows evidence of reduced corneal nerve fibers and cingulate gyrus volume in patients with schizophrenia. Furthermore, corneal nerve fiber loss in patients with schizophrenia was not associated with diabetes or metabolic syndrome. We cannot differentiate whether the axonal loss is neurodevelopmental or neurodegenerative in origin^{1,2}. However our results provide insights into the neuropathology in schizophrenia²⁷. A key feature is the reduced corneal nerve branch density and branch to fiber density ratio, which also have the highest diagnostic ability to distinguish patients with schizophrenia from healthy controls, indicating a greater impact on more distal nerves.

Neuroimaging studies have identified a pattern of MRI brain abnormalities related to schizophrenia^{28,29}. The ENIGMA consortium²⁸ assessed 2028 patients with schizophrenia and reported a reduced volume of hippocampus, amygdala, thalamus and nucleus accumbens and a higher volume of the pallidum and lateral ventricles. Kong et al. reported subtle neurological abnormalities of motor and sensory function and associated them with abnormal organization of structural brain networks in schizophrenia³⁰. However, other studies³ have reported no difference in the volume of the whole brain, hippocampus, amygdala, caudate and ventricles between patients with schizophrenia and healthy controls. The current study confirms no change in the volume of the hippocampus, amygdala, thalamus, entorhinal cortex, ventricles, cortical gray matter or whole brain, but does show a reduced volume of the cingulate gyrus which has been reported in schizophrenia²⁹. These conflicting findings might be attributed to differing cohort size and study populations as well as different software used to quantify the brain volume (NeuroQuant vs Freesurfer), which have low intraclass correlation coefficient for some brain structures. Whilst a lower cingulate gyrus volume correlated with an increased number of perseverative errors on cognitive testing³¹, increased anterior cingulate volume correlated with greater improvement in positive symptoms³². Furthermore, longitudinal MRI studies^{5,31,32} have shown a progressive reduction in the volume of

the cingulate gyrus, thalamus, frontal, temporal and parietal lobe, and ventricular enlargement in patients with schizophrenia over 1–7 years, particularly 2–3 years after the onset of disease³². However, a meta-analysis of 80 studies on brain MRI in schizophrenia found no conclusive evidence to support its diagnostic or prognostic validity³³. Indeed, structural brain MRI has not been recommended as a diagnostic marker of neuronal pathology in schizophrenia based on the lack of both an established pattern of neuronal pathology^{7,33} and unequivocal association with psychosis⁶.

Studies using CCM have reported corneal neurodegeneration in dementia, multiple sclerosis, Parkinson's disease and Friedreich's ataxia³⁴. This study found a significant reduction in corneal nerve fiber density, length, and branch density as well as branch to fiber density ratio in patients with schizophrenia. A postmortem study has shown that patients with schizophrenia have a comparable pyramidal neuron density but reduced branching and cell size in layer 3 of the primary visual cortex compared to healthy controls³⁵. Impaired neuronal branching^{35,36} might have a negative impact on the transition of the neuronal network from a child- to an adult-brain and the development of higher-order cognition³⁷. This study also shows that corneal nerve branch to fiber density ratio correlated positively with the volume of the cingulate gyrus after adjusting for confounders.

This study shows that CCM had a higher accuracy than cingulate gyrus volume and cognitive function for distinguishing patients with schizophrenia from healthy controls with a sensitivity and specificity exceeding 80%. Studies that have assessed the retina of patients with schizophrenia utilizing electroretinography (ERG) and optical coherence tomography (OCT) have also shown a reduction in retinal nerve fiber layer and macular volume and a reduction in photoreceptor and bipolar cell activity compared to controls⁸. It is possible that dopamine dysregulation⁹, systemic inflammation and hypoxia³⁸ may affect not only the brain but also the retina and cornea.

The association between neuronal pathology and symptom severity in schizophrenia has a conflicting literature. Indeed, we show that corneal nerve fiber measures and cingulate gyrus volume were not associated with symptom severity or cognitive function, although, this may reflect the effect of ongoing treatment. Nevertheless, some studies have shown that a reduction of gray matter volume, including the cingulate gyrus volume was associated with worsening³² or less improvement³⁹ of symptoms, whereas other studies have found no association⁴.

Some patients with schizophrenia experience distorted colour or brightness, hallucinations, or altered contrast sensitivity, which has been attributed to cortical, subcortical and retinal dysfunction⁴⁰, but our findings also suggest that the loss of corneal nerves may impact on ocular surface health through reduced tearing and blinking. Corneal nerves also release various trophic factors, which maintain epithelial integrity⁴¹. Diabetes and obesity are associated with corneal nerve fiber loss and the severity of peripheral neuropathy³⁴. In this cohort of patients with schizophrenia, there was a small non-significant loss of corneal nerves in those with diabetes, but no association with metabolic syndrome. This may be attributed to the excellent glycemic control in patients with diabetes (HbA1c 6.6%). Although diabetes is associated with corneal nerve loss¹⁴, this study shows that the loss of corneal nerve fibers in patients with schizophrenia remained significant after excluding those with diabetes. Indeed, there was no abnormality in vibration perception or sudomotor function, indicating no evidence of peripheral neuropathy in these patients.

We acknowledge the small sample size is a limitation of the current study and hence, the diagnostic accuracy of CCM and MRI brain volume for schizophrenia should be interpreted with caution. We have also not assessed for severe dry eye, which can be caused by antipsychotic drug use and is associated with corneal nerve abnormalities⁴¹. However, this study shows that corneal nerve measures had no association with antipsychotic drugs with the highest risk of dry eyes, antidepressants or treatment for movement disorders. Nevertheless, this is the first study to show a loss of corneal nerves in patients with schizophrenia and warrants a larger longitudinal cohort study to (1) confirm the current findings, (2) assess whether the disproportionately lower nerve branch to fiber density ratio is a distinctive neuropathological characteristic of schizophrenia, and (3) establish the predictive ability of CCM for worsening schizophrenia or relapses.

Data availability

The data that support the findings of this study are available on request from the corresponding author.

Received: 14 October 2021; Accepted: 13 January 2022

Published online: 03 February 2022

References

- Kochunov, P. & Hong, L. E. Neurodevelopmental and neurodegenerative models of schizophrenia: White matter at the center stage. *Schizophr. Bull.* **40**, 721–728. <https://doi.org/10.1093/schbul/sbu070> (2014).
- Falkai, P. *et al.* Kraepelin revisited: Schizophrenia from degeneration to failed regeneration. *Mol. Psychiatry* **20**, 671–676. <https://doi.org/10.1038/mp.2015.35> (2015).
- Haukvik, U. K. *et al.* No progressive brain changes during a 1-year follow-up of patients with first-episode psychosis. *Psychol. Med.* **46**, 589–598. <https://doi.org/10.1017/S003329171500210X> (2016).
- Jorgensen, K. N. *et al.* Brain volume change in first-episode psychosis: An effect of antipsychotic medication independent of BMI change. *Acta Psychiatr. Scand.* **135**, 117–126. <https://doi.org/10.1111/acps.12677> (2017).
- Lee, S. H. *et al.* Initial and progressive gray matter abnormalities in insular gyrus and temporal pole in first-episode schizophrenia contrasted with first-episode affective psychosis. *Schizophr. Bull.* **42**, 790–801. <https://doi.org/10.1093/schbul/sbv177> (2016).
- Sommer, I. E. *et al.* How frequent are radiological abnormalities in patients with psychosis? A review of 1379 MRI scans. *Schizophr. Bull.* **39**, 815–819. <https://doi.org/10.1093/schbul/sbs037> (2013).
- Peter, F., Andrea, S. & Nancy, A. Forty years of structural brain imaging in mental disorders: Is it clinically useful or not?. *Dialogues Clin. Neurosci.* **20**, 179–186 (2018).
- Silverstein, S. M., Fradkin, S. I. & Demmin, D. L. Schizophrenia and the retina: Towards a 2020 perspective. *Schizophr. Res.* **219**, 84–94. <https://doi.org/10.1016/j.schres.2019.09.016> (2020).

9. Lee, W. W., Tajunisah, I., Sharmilla, K., Peyman, M. & Subrayan, V. Retinal nerve fiber layer structure abnormalities in schizophrenia and its relationship to disease state: Evidence from optical coherence tomography. *Invest. Ophthalmol. Vis. Sci.* **54**, 7785–7792. <https://doi.org/10.1167/iops.13-12534> (2013).
10. Bora, E., Akdede, B. B. & Alptekin, K. The relationship between cognitive impairment in schizophrenia and metabolic syndrome: A systematic review and meta-analysis. *Psychol. Med.* **47**, 1030–1040. <https://doi.org/10.1017/S0033291716003366> (2017).
11. Davison, J., O’Gorman, A., Brennan, L. & Cotter, D. R. A systematic review of metabolite biomarkers of schizophrenia. *Schizophr. Res.* **195**, 32–50. <https://doi.org/10.1016/j.schres.2017.09.021> (2018).
12. Tzur Bitan, D., Krieger, I., Berkovitch, A., Comaneshter, D. & Cohen, A. Chronic kidney disease in adults with schizophrenia: A nationwide population-based study. *Gen. Hosp. Psychiatry* **58**, 1–6. <https://doi.org/10.1016/j.genhosppsych.2019.01.007> (2019).
13. Eguchi, H., Hiura, A., Nakagawa, H., Kusaka, S. & Shimomura, Y. Corneal nerve fiber structure, its role in corneal function, and its changes in corneal diseases. *Biomed. Res. Int.* **2017**, 3242649. <https://doi.org/10.1155/2017/3242649> (2017).
14. Malik, R. A. *et al.* Corneal confocal microscopy: A non-invasive surrogate of nerve fibre damage and repair in diabetic patients. *Diabetologia* **46**, 683–688. <https://doi.org/10.1007/s00125-003-1086-8> (2003).
15. Dorsey, J. L. *et al.* Loss of corneal sensory nerve fibers in SIV-infected macaques: An alternate approach to investigate HIV-induced PNS damage. *Am. J. Pathol.* **184**, 1652–1659. <https://doi.org/10.1016/j.ajpath.2014.02.009> (2014).
16. Bitirgen, G. *et al.* Corneal confocal microscopy identifies corneal nerve fibre loss and increased dendritic cells in patients with long COVID. *Br. J. Ophthalmol.* <https://doi.org/10.1136/bjophthalmol-2021-319450> (2021).
17. Ponirakis, G. *et al.* Association of corneal nerve fiber measures with cognitive function in dementia. *Ann. Clin. Transl. Neurol.* **6**, 689–697. <https://doi.org/10.1002/acn3.746> (2019).
18. Petropoulos, I. N. *et al.* Corneal confocal microscopy: An imaging endpoint for axonal degeneration in multiple sclerosis. *Invest. Ophthalmol. Vis. Sci.* **58**, 3677–3681. <https://doi.org/10.1167/iops.17-22050> (2017).
19. Association, A. P. *Diagnostic and Statistical Manual of Mental Disorders* 5th edn. (American Psychiatric Publishing, 2013).
20. Andreasen, N. C., Arndt, S., Miller, D., Flaum, M. & Nopoulos, P. Correlational studies of the scale for the assessment of negative symptoms and the scale for the assessment of positive symptoms: An overview and update. *Psychopathology* **28**, 7–17 (1995).
21. Rosca, E. C., Cornea, A. & Simu, M. Montreal Cognitive Assessment for evaluating the cognitive impairment in patients with schizophrenia: A systematic review. *Gen. Hosp. Psychiatry* **65**, 64–73. <https://doi.org/10.1016/j.genhosppsych.2020.05.011> (2020).
22. Moser, M. World Health Organization-International Society of Hypertension Guidelines for the management of hypertension-do these differ from the US recommendations? Which guidelines should the practicing physician follow?. *J. Clin. Hypertens. Greenwich.* **1**, 48–54 (1999).
23. WHO Consultation on Obesity (1999: Geneva, S. W. H. O.). Obesity: Preventing and managing the global epidemic. Report of a WHO consultation. *World Health Organ Tech. Rep. Ser.* **894**(1), 1–253 (2000).
24. Alberti, K. G. & Zimmet, P. Z. Definition, diagnosis and classification of diabetes mellitus and its complications. Part 1: Diagnosis and classification of diabetes mellitus provisional report of a WHO consultation. *Diabet. Med.* **15**, 539–553. [https://doi.org/10.1002/\(SICI\)1096-9136\(199807\)15:7%3C539::AID-DIA668%3e3.0.CO;2-S](https://doi.org/10.1002/(SICI)1096-9136(199807)15:7%3C539::AID-DIA668%3e3.0.CO;2-S) (1998).
25. Dabbah, M. A., Graham, J., Petropoulos, I. N., Tavakoli, M. & Malik, R. A. Automatic analysis of diabetic peripheral neuropathy using multi-scale quantitative morphology of nerve fibres in corneal confocal microscopy imaging. *Med. Image Anal.* **15**, 738–747. <https://doi.org/10.1016/j.media.2011.05.016> (2011).
26. Stelmokas, J. *et al.* Translational MRI volumetry with NeuroQuant: Effects of version and normative data on relationships with memory performance in healthy older adults and patients with mild cognitive impairment. *J. Alzheimers Dis.* **60**, 1499–1510. <https://doi.org/10.3233/JAD-170306> (2017).
27. Keshavan, M. S., DeLisi, L. E. & Seidman, L. J. Early and broadly defined psychosis risk mental states. *Schizophr. Res.* **126**, 1–10. <https://doi.org/10.1016/j.schres.2010.10.006> (2011).
28. van Erp, T. G. *et al.* Subcortical brain volume abnormalities in 2028 individuals with schizophrenia and 2540 healthy controls via the ENIGMA consortium. *Mol. Psychiatry* **21**, 547–553. <https://doi.org/10.1038/mp.2015.63> (2016).
29. Torres, U. S. *et al.* Patterns of regional gray matter loss at different stages of schizophrenia: A multisite, cross-sectional VBM study in first-episode and chronic illness. *Neuroimage Clin.* **12**, 1–15. <https://doi.org/10.1016/j.nicl.2016.06.002> (2016).
30. Kong, L., Herold, C. J., Cheung, E. F. C., Chan, R. C. K. & Schroder, J. Neurological soft signs and brain network abnormalities in schizophrenia. *Schizophr. Bull.* **46**, 562–571. <https://doi.org/10.1093/schbul/sbz118> (2020).
31. Prasad, K. M. *et al.* Progressive gray matter loss and changes in cognitive functioning associated with exposure to herpes simplex virus 1 in schizophrenia: A longitudinal study. *Am. J. Psychiatry* **168**, 822–830. <https://doi.org/10.1176/appi.ajp.2011.10101423> (2011).
32. Andreasen, N. C. *et al.* Progressive brain change in schizophrenia: A prospective longitudinal study of first-episode schizophrenia. *Biol. Psychiatry* **70**, 672–679. <https://doi.org/10.1016/j.biopsych.2011.05.017> (2011).
33. Fusar-Poli, P. & Meyer-Lindenberg, A. Forty years of structural imaging in psychosis: Promises and truth. *Acta Psychiatr. Scand.* **134**, 207–224. <https://doi.org/10.1111/acps.12619> (2016).
34. Petropoulos, I. N. *et al.* Corneal confocal microscopy: Ready for prime time. *Clin. Exp. Optom.* **103**, 265–277. <https://doi.org/10.1111/cxo.12887> (2020).
35. Glantz, L. A. & Lewis, D. A. Decreased dendritic spine density on prefrontal cortical pyramidal neurons in schizophrenia. *Arch. Gen. Psychiatry* **57**, 65–73. <https://doi.org/10.1001/archpsyc.57.1.65> (2000).
36. Mukai, J. *et al.* Molecular substrates of altered axonal growth and brain connectivity in a mouse model of schizophrenia. *Neuron* **86**, 680–695. <https://doi.org/10.1016/j.neuron.2015.04.003> (2015).
37. Oldham, S. & Fornito, A. The development of brain network hubs. *Dev. Cogn. Neurosci.* **36**, 100607. <https://doi.org/10.1016/j.dcn.2018.12.005> (2019).
38. Carrier, M., Guilbert, J., Levesque, J. P., Tremblay, M. E. & Desjardins, M. Structural and functional features of developing brain capillaries, and their alteration in schizophrenia. *Front. Cell Neurosci.* **14**, 595002. <https://doi.org/10.3389/fncel.2020.595002> (2020).
39. Takahashi, T. *et al.* Longitudinal MRI study of the midline brain regions in first-episode schizophrenia. *Psychiatry Res.* **212**, 150–153. <https://doi.org/10.1016/j.psychres.2012.12.001> (2013).
40. Park, J. K., Charlson, E. S., Leyngold, I. & Kossler, A. L. Corneal neurotization: A review of pathophysiology and outcomes. *Ophthalmol. Plast. Reconstr. Surg.* **36**, 431–437. <https://doi.org/10.1097/IOP.0000000000001583> (2020).
41. Cruzat, A., Qazi, Y. & Hamrah, P. In Vivo Confocal Microscopy Of Corneal Nerves In Health And Disease. *Ocul. Surf.* **15**, 15–47. <https://doi.org/10.1016/j.jtos.2016.09.004> (2017).

Acknowledgements

We thank Dr. Sahar A. Hamuda and Dr. Fareeha Khan for their help and all the participants for their efforts and commitment to be involved in the study.

Author contributions

Study concept and design: R.A.M., P.W.W. and G.P. Acquisition, analysis, or interpretation of data: all authors. Drafting of the manuscript: G.P., P.W.W. and R.A.M. Literature search: G.P. and R.A.M. Figures: G.P. Critical

revision of the manuscript for important intellectual content: all authors. Statistical analysis: G.P. and Z.M. Obtained funding: G.P., P.W.W. and R.A.M. Administrative, technical or material support: all authors.

Funding

This work was supported by the Qatar National Research Fund (RAM, Grant number BMRP-5726113101) and the Hamad Medical Corporation (PWW, Grant number IRGC-04-SI-17-166). The publication of this article was funded by the Weill Cornell Medicine – Qatar Distributed eLibrary.

Competing interests

PMH has received lectures fees from Otsuka, Newbridge Pharmaceuticals and Janssen outside the submitted work.

Additional information

Supplementary Information The online version contains supplementary material available at <https://doi.org/10.1038/s41598-022-05609-w>.

Correspondence and requests for materials should be addressed to P.W.W.

Reprints and permissions information is available at www.nature.com/reprints.

Publisher's note Springer Nature remains neutral with regard to jurisdictional claims in published maps and institutional affiliations.



Open Access This article is licensed under a Creative Commons Attribution 4.0 International License, which permits use, sharing, adaptation, distribution and reproduction in any medium or format, as long as you give appropriate credit to the original author(s) and the source, provide a link to the Creative Commons licence, and indicate if changes were made. The images or other third party material in this article are included in the article's Creative Commons licence, unless indicated otherwise in a credit line to the material. If material is not included in the article's Creative Commons licence and your intended use is not permitted by statutory regulation or exceeds the permitted use, you will need to obtain permission directly from the copyright holder. To view a copy of this licence, visit <http://creativecommons.org/licenses/by/4.0/>.

© The Author(s) 2022