



Deposited via The University of Leeds.

White Rose Research Online URL for this paper:

<https://eprints.whiterose.ac.uk/id/eprint/182699/>

Version: Accepted Version

Article:

Bertham, DP, Tan, AL, Booth, A et al. (2022) Repeatability of quantitative MRI in patients with rheumatoid arthritis. *Radiography*, 28 (3). pp. 831-837. ISSN: 1078-8174

<https://doi.org/10.1016/j.radi.2022.01.004>

© 2022 The College of Radiographers. Published by Elsevier Ltd. All rights reserved. This manuscript version is made available under the CC-BY-NC-ND 4.0 license <http://creativecommons.org/licenses/by-nc-nd/4.0/>.

Reuse

This article is distributed under the terms of the Creative Commons Attribution-NonCommercial-NoDerivs (CC BY-NC-ND) licence. This licence only allows you to download this work and share it with others as long as you credit the authors, but you can't change the article in any way or use it commercially. More information and the full terms of the licence here: <https://creativecommons.org/licenses/>

Takedown

If you consider content in White Rose Research Online to be in breach of UK law, please notify us by emailing eprints@whiterose.ac.uk including the URL of the record and the reason for the withdrawal request.

Title page

Full title: Repeatability of quantitative MRI in patients with rheumatoid arthritis.

Type of manuscript: Full length article

Author names:

Dominic Bertham, MSc⁽¹⁾

Ai Lyn Tan, MD^(1,2)

Alison Booth, PhD⁽³⁾

Lewis Paton, PhD⁽³⁾

Paul Emery, MD^(1,2)

John Biglands, PhD⁽¹⁾

Matthew Farrow, PhD^(4,5)

¹NIHR Leeds Biomedical Research Centre, Chapel Allerton Hospital, Leeds Teaching Hospitals NHS Trust, Leeds, United Kingdom

²Leeds Institute of Rheumatic and Musculoskeletal Medicine, Chapel Allerton Hospital, University of Leeds, Leeds, United Kingdom

³Department of Health Sciences, University of York, York, United Kingdom

⁴School of Pharmacy and Medical Sciences, University of Bradford, Bradford, United Kingdom

⁵Wolfson Centre for Applied health research, Bradford, United Kingdom

Abstract

Introduction: Rheumatoid arthritis (RA) affects 1% of the population and is principally associated with joint inflammation. It is suggested however that muscle involvement may be one of the earliest clinical features of RA. It is therefore important that techniques exist to accurately assess muscle health in those with RA to enable successful treatment. This study assesses the inter-rater and intra-rater repeatability of Diffusion Tensor MRI (DTI), 2-Point Dixon fat fraction, and T2 relaxation of the thigh muscle in patients with RA using manual regions of interest (ROI).

Methods: Nineteen patients (10/19 males; mean age 59; range 18-85) diagnosed with RA had an MRI scan of their hamstrings and quadriceps muscles to obtain fat fraction (FF), mean diffusivity (MD), fractional anisotropy (FA), and T2 quantitative measurements. Two raters (R#1 & R#2) (*initials removed for review*) independently contoured ROIs for each patient. R#1 repeated the ROI for the same 19 patients after a 6-month hiatus to assess intra-rater repeatability. Inter-rater and intra-rater repeatability for the ROI measurements were compared using Inter Class Correlation (ICC) and Bland-Altman plots.

Results: There was excellent agreement for both inter-rater and intra-rater repeatability. ICC results ranged from 0.900-0.998 ($P < 0.001$), and intra-rater ICC results ranged from 0.977-0.999 ($P < 0.001$). Bland-Altman plots also showed excellent agreement.

Conclusions: ICC measurements and Bland-Altman plots showed excellent repeatability and agreement with no statistically significant differences when assessing the inter-rater and intra-rater repeatability of FF, MD, FA, and T2 relaxation of the thigh muscle using manual regions of interest in patients with RA.

Implications for practice: Manual ROI drawing does not introduce significant errors obtaining FF, MD, FA, and T2 MRI measurements in an RA population.

Introduction

Rheumatoid arthritis (RA) is a chronic systemic inflammatory disease affecting approximately 1% of the population. RA is principally associated with joint inflammation, however, RA is also accompanied by broad-ranging anatomical and molecular alterations in skeletal muscle¹ with muscle weakness commonly reported by patients². A reduction in quality of life for patients with RA has been demonstrated in association with clinical presentation of muscle inflammation, fat infiltration into muscle (myosteatorsis), fibrosis, and muscle atrophy³⁻⁶. It has been found that muscle pathology is present in patients with newly diagnosed and treatment naïve RA and those in clinical remission⁶. This suggests that muscle involvement may be one of the earliest clinical features of RA and persists despite achieving clinical remission. Earlier identification of RA with appropriate treatment can improve RA disease outcomes, increasing remission rates and structural damage⁷. However, if muscle involvement persists having achieved remission, as previously demonstrated by Farrow et al⁶, it is important that techniques exist to accurately assess muscle health in those with RA to enable successful treatment.

Magnetic resonance imaging (MRI) is a non-invasive imaging modality that enables in vivo evaluation of muscle volume, microstructure and myosteatorsis, which can all be signs of rheumatoid cachexia (RC)^{3,8}. Quantitative MRI (qMRI) techniques are increasingly being recognised as beneficial for the early diagnosis and treatment of many pathologies and muscular disease^{9,10}. Furthermore, it has previously been demonstrated that qMRI measurements may detect changes in the muscle related to conditions such as RA⁶, myositis¹¹, and ageing¹² compared to matched healthy controls. Appropriate use of diagnostic imaging modalities and accurate image interpretation adds significant value to the diagnosis and treatment process of musculoskeletal disease^{13,14}, with MRI considered to be the gold standard imaging modality for detecting changes in muscle tissue¹⁵. This has been demonstrated in studies of the relationship between muscle inflammation and degeneration in musculoskeletal diseases such as RA, where muscle involvement is known to occur¹⁶. However, qualitative evaluation and analysis of conventional MR imaging for skeletal muscle disease is subjective and dependent on the readers' skill¹⁷. Therefore, there is a need for objective evaluation of alterations to skeletal muscle using quantitative imaging¹⁸. DTI measurements related to anisotropic tissues are used to acquire information about the orientation and architectural organisation of the muscle tissue^{19,20}. DTI sequences may provide a unique non-invasive technique for studying muscle fibre orientation²¹. Parameters used to assess diffusion in the muscle were: mean diffusivity (MD), displayed as

[$\times 10^{-3} \text{mm}^2 \text{s}^{-1}$], and fractional anisotropy (FA) displayed on a scale between [0-1]. Dixon FF imaging is a technique that exploits the differences in the resonant frequencies between fat and water in order to separate them in the image and produce fat fraction measurements. T2, or the transverse relaxation time, is one of the fundamental contrast mechanisms in MRI. Quantitative T2 measurements are sensitive to fluid related to physiological or pathological changes at the macromolecular level. Longer T2 relaxation times are often interpreted as increased fluid due to oedema or inflammation.

Repeatability of qMRI measurements, including FF and DTI imaging, has already been established in a healthy control population²². However, it is yet to be elucidated if these measures are repeatable in patients with musculoskeletal disease where it may be challenging to demarcate the muscle due to the disease process. If qMRI is found to be repeatable in an RA patient population, this would support the integration of qMRI into the routine assessment of muscle health to assess muscular changes and identify pathology in a range of musculoskeletal diseases and potentially earlier than currently identified. This study is an extension of elements of a previously published work by Farrow et al (2019)²² which found that qMRI measurements were reproducible in a healthy control population. The aims of this research study were to determine the repeatability of quantitative MRI measurements of FF, DTI, and T2 in the thigh muscles of 19 patients with RA using manual ROI.

Methods

The MRI scans used in this study were undertaken for the MUSCLE II study at the NIHR Leeds Musculoskeletal Biomedical Research Centre, Chapel Allerton Hospital, Leeds, in 2017 and 2018²². Ethical approval was obtained, and patients gave written informed consent (REC:17/EM/0079). The anonymised scans of nineteen participants (mean age 59 years, range 18-85, 10 males) with a diagnosis of RA were included in the study. The sample size of 19 was based on guidelines recommending between 12 and 30 participants for powering future clinical trials²³. All images and patient data were anonymised.

Eligibility criteria

Patients aged 18 years or over who had a diagnosis of RA based on the ACR/EULAR criteria²⁴ and could give written informed consent were eligible. Exclusion criteria included previous history of spinal disease, neuropathy, and contraindications to MRI.

MRI measurements

In vivo muscular analysis of the patient's dominant thigh was performed on a 3 Tesla (T) MRI scanner (Magnetom Verio, Siemens Healthcare, Erlangen, Germany) at the Leeds Biomedical Research Centre, Chapel Allerton Hospital. Localisation of thigh muscle comprised of a series of scout images in three orthogonal directions of the thigh. After localisation to ensure good positioning of the field-of-view (FOV), axial slices were fixed centrally to the thigh with the cordial edge of the FOV in line and level with the insertion of the quadriceps muscle at the tibial tuberosity.

This study utilised three qMRI sequences to enable accurate comparisons as a base for the measurement of repeatability and agreement of manual ROIs in thigh muscle:

1. VIBE-Dixon technique (two-point Dixon fat quantification)
2. Stimulated echo acquisition mode (STEAM) echo-planar imaging (EPI) (diffusion)
3. T2 Multi-echo spin echo (MESE) measurements (T2 measurement)

Fat quantification

Fat quantification is understood to be simplified by employing quantitative imaging, with fat fraction mapping believed to become a mainstay of clinical radiology in the future^{25,26}. Fat fraction (FF) was measured using a 2-point VIBE-Dixon sequence (Table 1), which provides a quantitative measure of myosteatorsis and is displayed as a percentage.

Diffusion tensor imaging (DTI)

Previous studies investigating the use of DTI in muscle have utilised spin-echo DTI measurements. However, rather than spin echo, this study used a STEAM prototype sequence with an echo-planar imaging (EPI) readout (Table 1)²². This methodology choice was due to STEAM having a longer sequence time and therefore having more time to diffuse in muscle and thus should be more sensitive to diffusion within muscle tissue. Therefore, imaging acquired using STEAM are not affected by susceptibility artefacts to the same degree

9,21,22,27,28

T2 relaxation

T2 measurements were obtained by fitting a mono-exponential decay curve to the signal intensities taken from the ROIs across the 16 acquisition echo times (Table 1) ^{29,30}. Spectral attenuated inversion recovery (SPAIR) fat suppression technique was used as most existing T2 mapping techniques are sensitive to the fat content in muscle ¹⁸.

Table 1 Quantitative MRI sequence parameters

	Fat Quantification	Diffusion	T2 Relaxation
Imaging sequences (acquired in axial plane)	VIBE-Dixon	STEAM-EPI	T2 MESE (multi-echo spin-echo) 16 echoes
TR: Repetition Time (ms)	11	6300	1500
TE: Echo Time(s) (ms)	2.45 and 3.675	42.4	9.5; 19.2; 28.8; 38.4; 48; 57.6; 67.2; 76.8; 86.4; 96; 105.6; 115.2; 124.8; 134.4; 144; 153.6
Field of View (mm)	300*300	300*300	300*300
Slice Thickness (mm)	5.0	5.0	5.0
Fat suppression	None	SPAIR	SPAIR
Acquisition Matrix	256*256	128*128	256*256
Number of slices	40	4	4
Number of averages	1	8	1
Receiver bandwidth (Hz/pixel)	510	1502	201
Flip Angle (°)	15	N/A	180
B-Values	N/A	0 and 500 mm ² s ⁻¹	N/A
Diffusion directions	N/A	6	N/A
Echo spacing (ms)	N/A	0.75	N/A
EPI factor	N/A	128	N/A
Diffusion mixing time (ms)	N/A	980	N/A
Acquisition time (min: secs)	01:47	06:12	04:05

ROI placement

Osirix (v.4.0; open-source DICOM viewer, www.osirix-viewer.com) was used to contour individual muscles of the thigh:

Quadriceps: Rectus femoris, vastus lateralis, vastus intermedius and vastus lateralis.

Hamstrings: Biceps femoris, semitendinosus and semimembranosus.

ROIs were drawn around the individual muscles by the two raters independently on the middle slice (20 of 40) of the in-phase VIBE-Dixon volume (Figure 1). This slice was chosen as a consistent anatomical location. ROIs were drawn slightly within the muscle belly to avoid contamination with fascia and adipose tissue. In-phase VIBE images were selected to contour the muscles as anatomical structures, including muscle and fat, are well demonstrated on these images and they are advocated for use in muscle imaging^{9,31-33}. The same FOV was used for all quantitative sequences to enable cross-propagation of the ROI to the different MRI images without interpolation.

Mean values for FF, MD, FA, and T2 were obtained by combining the ROIs of the individual muscles that make up the hamstrings and quadriceps muscle groups. The inter-rater and intra-rater measurements for the hamstrings and quadriceps were then calculated. Both researchers were blinded to the name, age, and sex of the patient population before and during the contouring of the ROI. For inter-rater reproducibility, the 19 MRI data sets were independently contoured by the two raters at different time points (R#1 and R#2) (*initials removed for review*). For intra-rater repeatability, the same 19 MRI data sets were contoured twice by R1, with a 6-month interval between measurements to reduce rater and measurement bias^{34,35}.

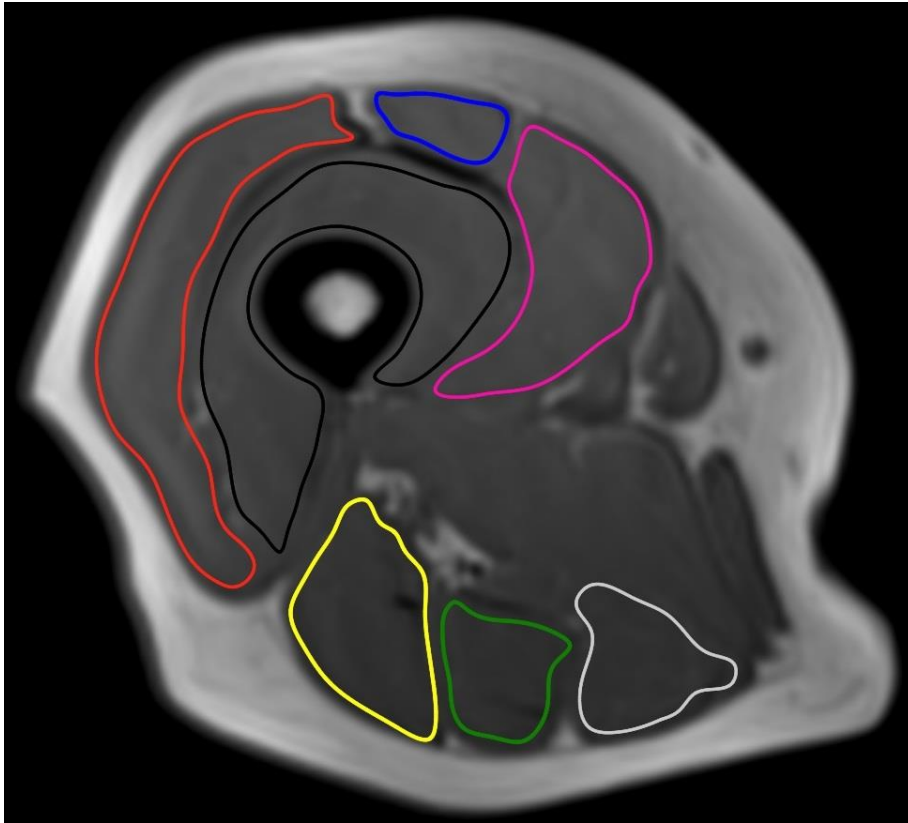


Figure 1. Example of ROI placement of hamstring and quadriceps muscle groups on VIBE Dixon image. (Red= Vastus Lateralis; Black=Vastus Intermedius; Blue= Rectus Femoris; Pink= Vastus Medialis; Yellow=Biceps Femoris; Green=Semitendinosus; Silver= Semimembranosus).

Data analysis

Data analysis for quantitative MR image sequences calculated from the ROI volume was performed using MatLab (R2018a, MathWorks, Nattick, MA). T1 correction between fat and water was accomplished by using the assumed values for fat (T1=1420ms) and water (T1=371ms)³⁶. FF was calculated from the corrected fat (Sf) and water (Sw) signals using the equation:

$$FF = Sf / (Sf+Sw) \times 100\%.$$

MD ($\times 10^{-3}$ mm² s⁻¹) and FA maps were produced by the scanner software, T2 mapping was produced from the MatLab software program. To calculate T2 values, the signal intensity versus echo time decay curves from each ROI were fitted using a mono-exponential decay function^{11,37}.

Statistical analysis

Statistical analysis was performed in SPSS (IBM SPSS Statistics for Windows, v. 25.0. Armonk, NY: IBM Corp.) and MedCalc, (MedCalc Software bvba, Ostend, Belgium; <http://www.medcalc.org>; 2019). ICCs, with 95% confidence intervals (CI) was calculated to compare inter-rater and intra-rater repeatability. ICC is a widely used index in inter-rater, and intra-rater analyses³⁸. The ICC measured ROI repeatability with a two-way mixed-effects model with absolute agreement. ICC values above 0.60 were classed as good, and above 0.75 were classed as excellent^{38,39}. Agreement between ROIs was measured using Bland-Altman plots. As there is no current clinical practice for the methodology used in this study, an *a priori* benchmark of acceptability was set as 95% of the plots to fall within the limits of agreement (LoA), based on previous thigh muscle ROI studies^{11,22}.

Results

Figures 2 and 3 depict Bland-Altman agreement plots for inter-rater and intra-rater repeatability for the hamstrings muscle group. ICCs ranged from 0.900 to 0.989 and 0.977 to 0.994 respectively (Table 2), indicating excellent agreement.

Figures 4 and 5 depict Bland-Altman agreement plots for inter-rater and intra-rater repeatability for the quadriceps muscle group. ICCs ranged from 0.972 to 0.998 and 0.992 to 0.999, respectively (Table 3), indicating excellent agreement.

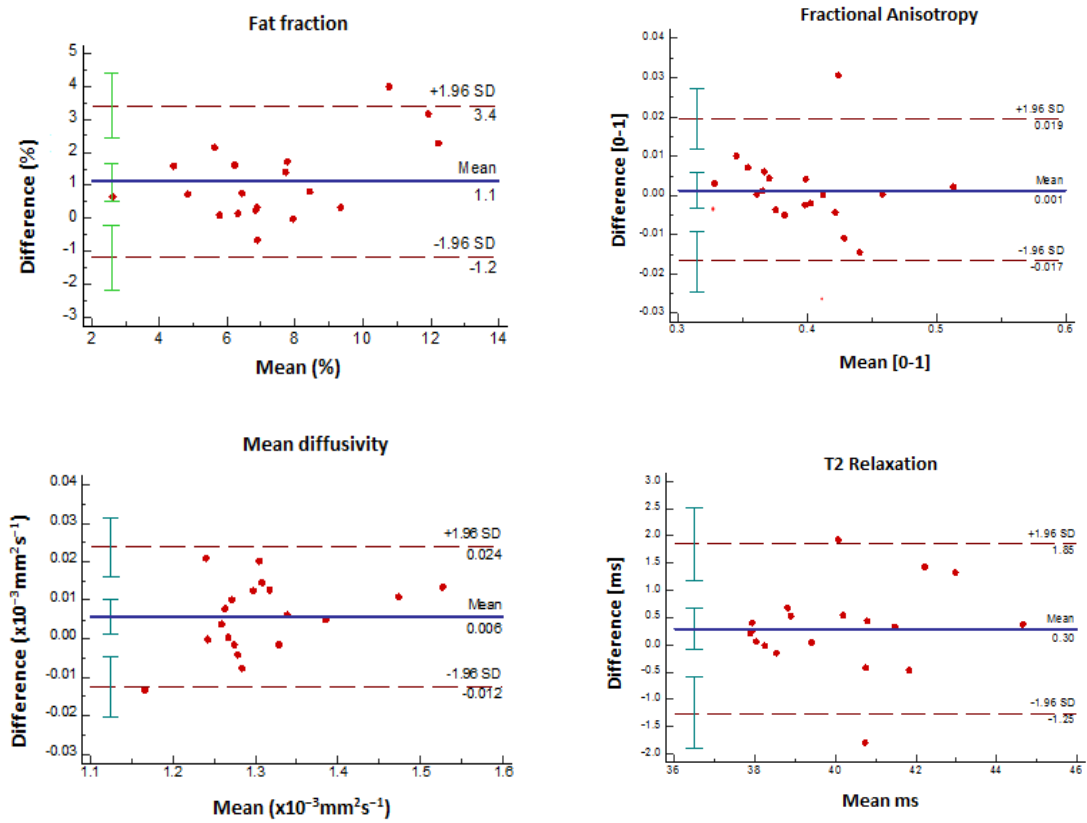


Figure 2. Inter-rater Bland-Altman agreement plots for FF, MD, FA, & T2 relaxation for the hamstrings.

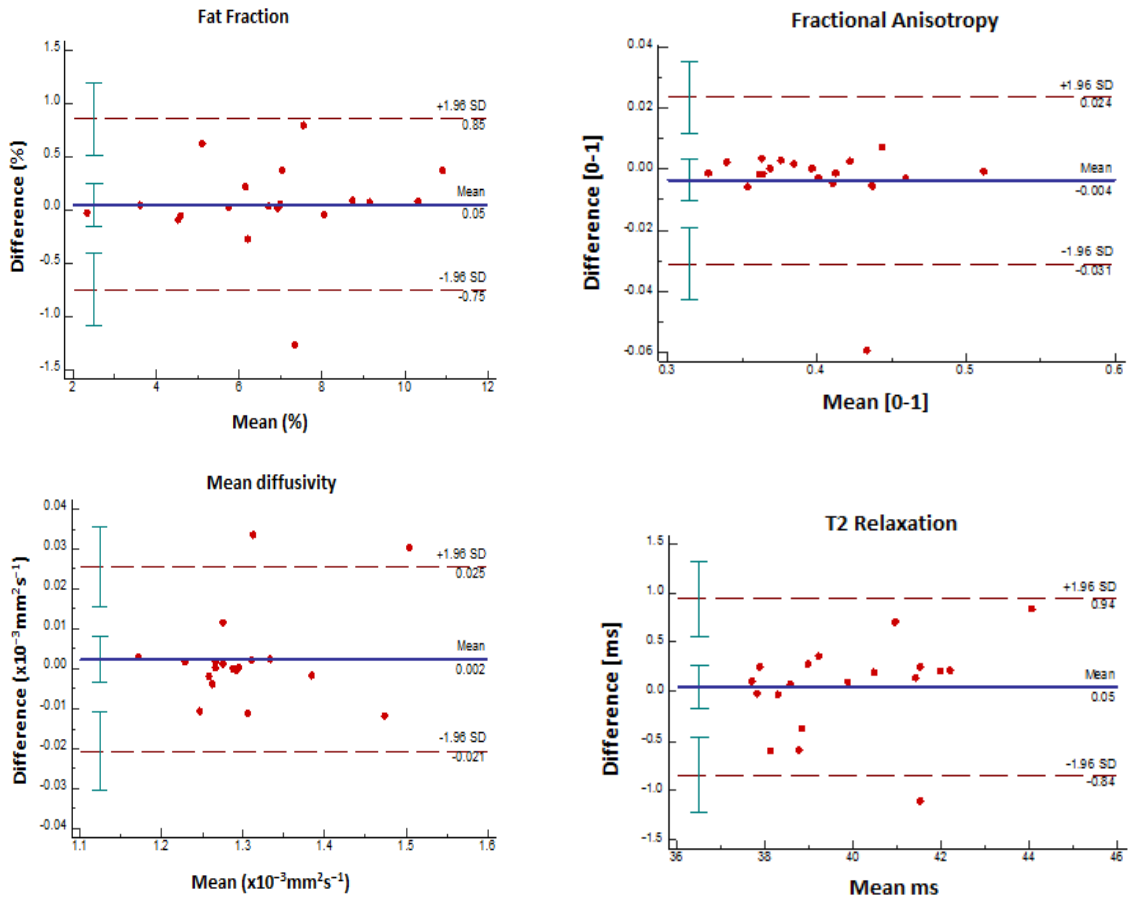


Figure 3. Intra-rater Bland-Altman agreement plots for FF, MD, FA, & T2 relaxation for the hamstrings.

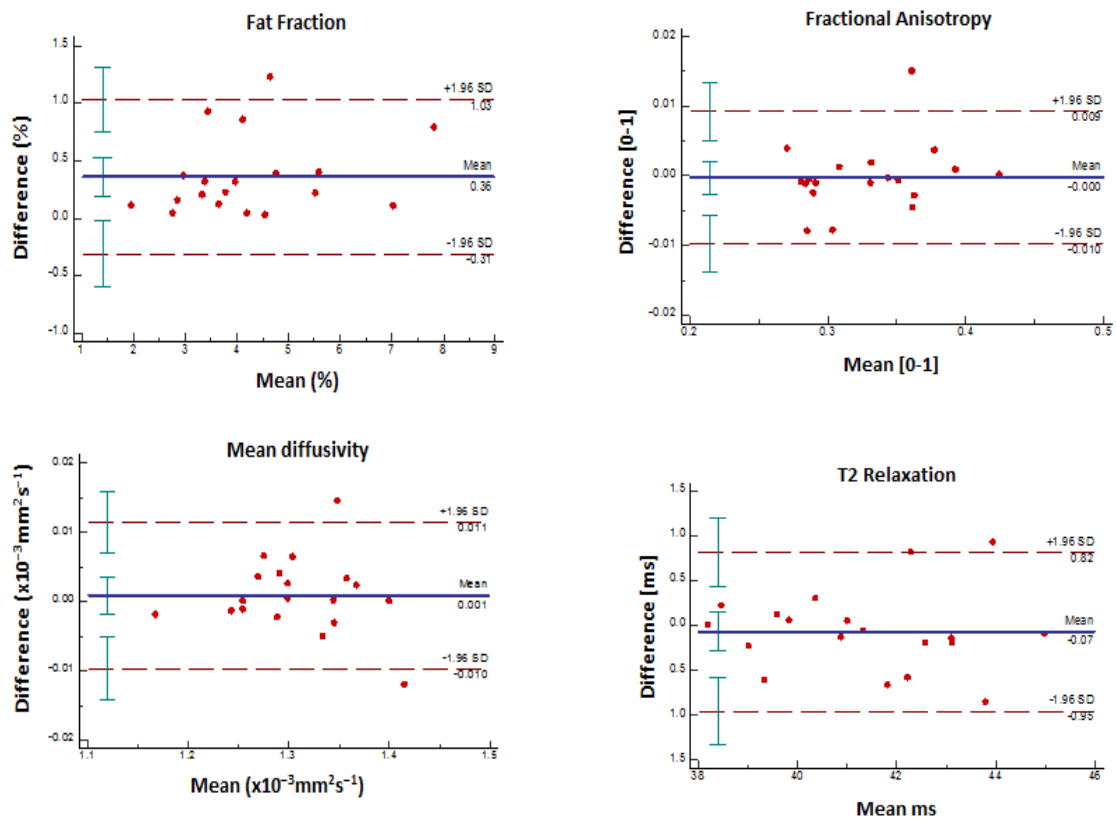


Figure 4. Inter-rater Bland-Altman agreement plots for FF, MD, FA, & T2 relaxation for the quadriceps.

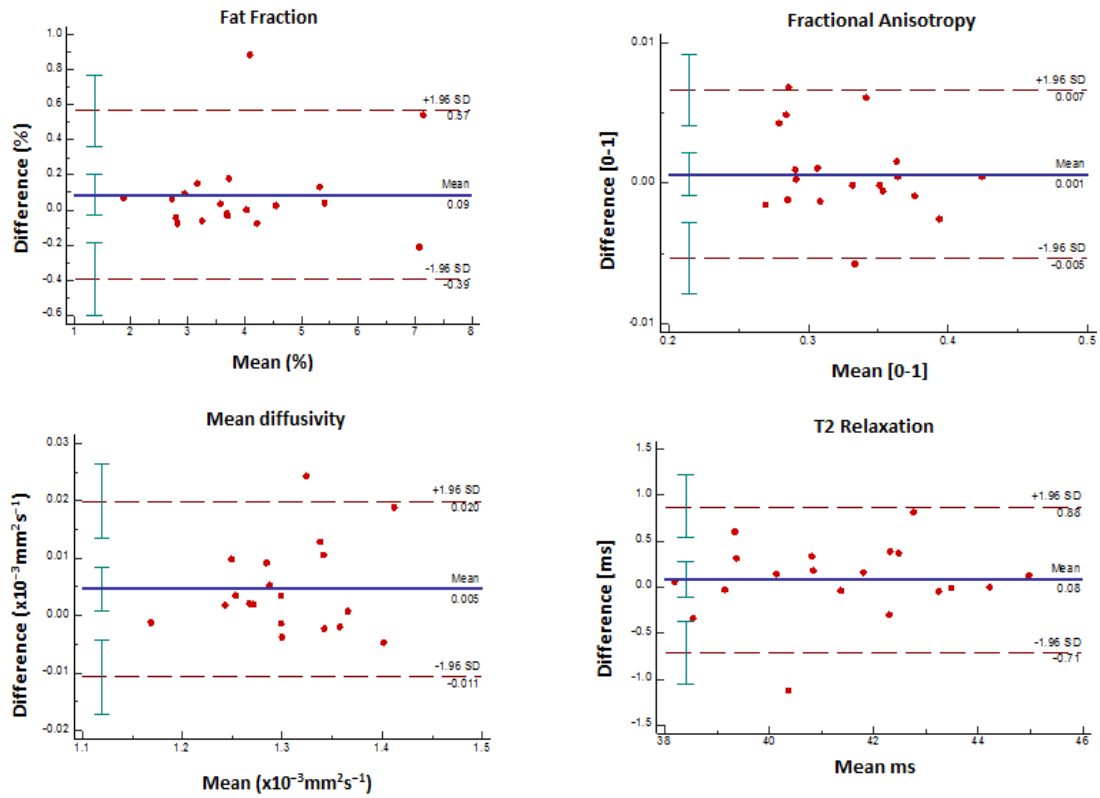


Figure 5. Bland-Altman agreement plots for FF, MD, FA, & T2 relaxation for the quadriceps.

Table 2. Repeatability ICC values for inter-rater and intra-rater qMRI measures in the hamstring

Inter-rater	FF	MD	FA	T2
ICC values	0.900	0.996	0.989	0.955
Hamstrings	(0.423,0.970)	(0.985,0.999)	(0.973,0.996)	(0.882,0.983)
Intra-rater				
ICC values	0.992	0.994	0.977	0.985
Hamstrings	(0.978,0.997)	(0.986,0.998)	(0.941,0.991)	(0.962,0.9949)

Table 3. Repeatability ICC values for inter-rater and intra-rater qMRI measures in the quadriceps

Inter-rater	FF	MD	FA	T2
ICC values	0.972	0.998	0.997	0.987
Quadriceps	(0.730,0.993)	(0.995,0.999)	(0.993,0.999)	(0.967,0.995)
Intra-rater				
ICC values	0.992	0.994	0.999	0.989
Quadriceps	(0.978,0.994)	(0.980,0.998)	(0.997,1.00)	(0.973,0.996)

Discussion

MRI is the preferred imaging modality for skeletal muscle imaging due to high soft-tissue contrast and visualisation of pathophysiological changes such as fatty infiltration, inflammation, and intramuscular oedema⁴⁰. This study demonstrates excellent repeatability and levels of agreement in FF, DTI, and T2 relaxation time qMRI measurements in patients with RA using manual ROIs. ICC values for inter-rater and intra-rater repeatability were excellent³⁹ and ranged from 0.900-0.998 and 0.977-0.999 respectively for the hamstring and quadriceps muscle groups (Tables 2&3). Evidence from the Bland-Altman plots demonstrated a mean bias close to zero on the y-axis, which suggests that manual ROIs in qMRI has high accuracy in patients with musculoskeletal disease and is sufficiently precise to allow the study of subtle changes to muscle due to RA⁴¹⁻⁴³. These findings are promising and are consistent with a previous study²² that measured the repeatability of manual ROI of qMRI measurements in a healthy control population. This paper demonstrates that the variation in measures due to operator bias is substantially smaller than the differences observed in the muscle between patients with RA and healthy controls⁶. This suggests that qMRI measurements using manual ROI are suitable to be used in patients with musculoskeletal diseases and may be able to identify early changes in the muscle in the initial stages of RA.

To the authors' knowledge, there is no standardised MRI procedure for measuring manual ROI in muscle volume of the thigh. Although standardisation would be a major step to help ensure repeatability in manual contouring muscle volume of the thigh in a clinical setting, it is beyond the scope of this paper to advocate a particular methodology for using manual ROI of the thigh for quantitative measurements. Precise and consistent technique in contouring manual ROI in muscle is an important consideration when extracting qMRI measurements and would suggest a definitive training program and a higher number of raters would be needed before being used in any clinical application.

This study was subject to limitations. 'The sample size of two researchers is too small, future larger studies are required to confirm these findings'. It was only known that participants had a diagnosis of RA, not whether they were newly diagnosed, were undergoing treatment, or were in clinical remission. Future research is needed to explore if there are any quantitative differences in the repeatability of measurements during different stages of RA. It could be hypothesised that qMRI could be used as an effective diagnosis during the early stages of muscle disease, which could improve clinical management and monitoring of disease progression^{7,44}.

Rather than the average taken of the muscle groups of hamstring and quadriceps to identify potential areas of agreement errors, individual muscles could be assessed for agreement instead. The individual adductor muscles (adductor magnus, adductor brevis and adductor longus muscles) were not contoured within this study. It was presumed that if included, the adductor muscle group would provide exaggerated muscle fat percentage and therefore present potentially false-positive FF results that may have been skewed by inter fascia fat. The three separate eigenvalues within the MD measurements could be individually examined for a greater in-depth analysis of the diffusion of water molecules within muscles of the thigh. Acquisition of T2-mapping techniques can be lengthy, and patient movement during the scan can result in inaccurate mapping. In MESE, T2 mapping is sensitive to B1 inhomogeneity and is mainly prominent at high field strengths, such as 3T (which was used in this study) and can lead to inaccuracies in quantification,¹⁷.

The sample size, despite meeting the requirements for guidelines in powering future studies, was small.

There is a potential to explore further muscle groups other than the thigh in future studies.

Conclusion

This study has demonstrated excellent intra-rater and inter-rater repeatability of contouring regions of interest in the muscles of patients with RA in terms of the resulting FF, FA, MD, and T2 measurements. This illustrates that manual ROIs are fit for purpose in the assessment and management of musculoskeletal disease using quantitative MRI and justifies further investigation.

Conflict of interest

The authors declare no conflict of interest.

Funding statement

This research is funded by the NIHR infrastructure at Leeds. The views expressed are those of the authors and not necessarily those of the NHS, the NIHR or the Department of Health.

References

1. Huffman, K. M. *et al.* Molecular alterations in skeletal muscle in rheumatoid arthritis are related to disease activity, physical inactivity, and disability. *Arthritis Res. Ther.* **19**, 12 (2017).
2. Guo, Q. *et al.* Rheumatoid arthritis: pathological mechanisms and modern pharmacologic therapies. *Bone Res.* **6**, (2018).
3. Hausman, G. J., Basu, U., Du, M., Fernyhough-Culver, M. & Dodson, M. V. Intermuscular and intramuscular adipose tissues: Bad vs. good adipose tissues. *Adipocyte* **3**, 242–255 (2014).
4. Masuko, K. Rheumatoid Cachexia Revisited: A Metabolic Co-Morbidity in Rheumatoid Arthritis. *Front. Nutr.* **1**, 20 (2014).
5. Filippin, L. I. *et al.* Temporal development of muscle atrophy in murine model of arthritis is related to disease severity. *J. Cachexia. Sarcopenia Muscle* **4**, 231–238 (2013).
6. Farrow, M. *et al.* Muscle deterioration due to rheumatoid arthritis: assessment by quantitative MRI and strength testing. *Rheumatology (Oxford)*. **60**, 1216–1225 (2021).
7. Heidari, B. Rheumatoid arthritis: Early diagnosis and treatment outcomes. *Casp. J. Intern. Med.* **2**, 161–170 (2011).
8. Pons, C. *et al.* Quantifying skeletal muscle volume and shape in humans using MRI: A systematic review of validity and reliability. *PLoS One* **13**, e0207847 (2018).
9. Kalia, V., Leung, D. G., Sneag, D. B., Grande, F. Del & Carrino, J. A. Advanced MRI Techniques for Muscle Imaging. *Semin. Musculoskelet. Radiol.* **21**, 459–469 (2017).
10. Cashmore, M. T. *et al.* Clinical quantitative MRI and the need for metrology. <https://doi.org/10.1259/bjr.20201215> **94**, 20201215 (2021).
11. Farrow, M. *et al.* Quantitative MRI in myositis patients: comparison with healthy volunteers and radiological visual assessment. *Clin. Radiol.* (2020). doi:10.1016/j.crad.2020.08.022
12. Farrow, M. *et al.* The effect of ageing on skeletal muscle as assessed by quantitative MR imaging: an association with frailty and muscle strength. *Aging Clin. Exp. Res.* (2020). doi:10.1007/s40520-020-01530-2
13. Farrow, M., Biglands, J., Alfuraih, A. M., Wakefield, R. J. & Tan, A. L. Novel Muscle Imaging in Inflammatory Rheumatic Diseases—A Focus on Ultrasound Shear Wave Elastography and Quantitative MRI. *Front. Med.* **7**, 434 (2020).

14. Shiraishi, M. *et al.* Differentiating Rheumatoid and Psoriatic Arthritis of the Hand: Multimodality Imaging Characteristics. *Radiographics* **40**, 1339–1354 (2020).
15. Olsen, N. J., Qi, J. & Park, J. H. Imaging and skeletal muscle disease. *Curr. Rheumatol. Rep.* **7**, 106–114 (2005).
16. Morley, J. E., Thomas, D. R. & Wilson, M.-M. G. Cachexia: pathophysiology and clinical relevance. *Am. J. Clin. Nutr.* **83**, 735–743 (2006).
17. de Mello, R., Ma, Y., Ji, Y., Du, J. & Chang, E. Y. Quantitative MRI Musculoskeletal Techniques: An Update. *Am. J. Roentgenol.* **213**, 524–533 (2019).
18. Klupp, E. *et al.* B1-insensitive T2 mapping of healthy thigh muscles using a T2-prepared 3D TSE sequence. *PLoS One* **12**, (2017).
19. Kermarrec, E. *et al.* In Vivo Diffusion Tensor Imaging and Tractography of Human Thigh Muscles in Healthy Subjects. *AJR. Am. J. Roentgenol.* **195**, 352–6 (2010).
20. Budzik, J. F. *et al.* In vivo MR tractography of thigh muscles using diffusion imaging: initial results. *Eur. Radiol.* **17**, 3079–3085 (2007).
21. Heemskerk, A. M. & Damon, B. M. Diffusion Tensor MRI Assessment of Skeletal Muscle Architecture. *Curr. Med. Imaging Rev.* **3**, 152–160 (2007).
22. Farrow, M. *et al.* Normal values and test–retest variability of stimulated-echo diffusion tensor imaging and fat fraction measurements in the muscle. *Br. J. Radiol.* **92**, 20190143 (2019).
23. Lancaster, G. A., Dodd, S. & Williamson, P. R. Design and analysis of pilot studies: recommendations for good practice. *J. Eval. Clin. Pract.* **10**, 307–312 (2004).
24. Aletaha, D. *et al.* 2010 Rheumatoid arthritis classification criteria: An American College of Rheumatology/European League Against Rheumatism collaborative initiative. *Arthritis Rheum.* **62**, 2569–2581 (2010).
25. Borga, M. MRI adipose tissue and muscle composition analysis—a review of automation techniques. *Br. J. Radiol.* **91**, (2018).
26. Bray, T. J. P., Chouhan, M. D., Punwani, S., Bridge, A. & Hall-Craggs, M. A. Fat fraction mapping using magnetic resonance imaging: Insight into pathophysiology. *Br. J. Radiol.* **91**, (2018).
27. Suter, L. G., Fraenkel, L. & Braithwaite, R. S. Role of magnetic resonance imaging in the diagnosis and prognosis of rheumatoid arthritis. *Arthritis Care Res. (Hoboken)*. **63**, 675–88 (2011).
28. Damon, B. M. *et al.* Skeletal muscle diffusion tensor-MRI fiber tracking: rationale, data acquisition and analysis methods, applications and future directions. *NMR Biomed.* **30**,

- (2017).
29. Kim, H. S., Yoon, Y. C., Choi, B. O., Jin, W. & Cha, J. G. Muscle fat quantification using magnetic resonance imaging: case-control study of Charcot-Marie-Tooth disease patients and volunteers. *J. Cachexia. Sarcopenia Muscle* **10**, 574–585 (2019).
 30. Dekkers, I. A. & Lamb, H. J. Clinical application and technical considerations of T1 & T2 (*) mapping in cardiac, liver, and renal imaging. *Br. J. Radiol.* **91**, 20170825 (2018).
 31. Lins, C. F., Salmon, C. E. G. & Nogueira-Barbosa, M. H. Applications of the Dixon technique in the evaluation of the musculoskeletal system. *Radiol. Bras.* (2020). doi:10.1590/0100-3984.2019.0086
 32. Engelke, K., Museyko, O., Wang, L. & Laredo, J. D. Quantitative analysis of skeletal muscle by computed tomography imaging—State of the art. *Journal of Orthopaedic Translation* **15**, 91–103 (2018).
 33. Nozaki, T. *et al.* Predicting Retear after Repair of Full-Thickness Rotator Cuff Tear: Two-Point Dixon MR Imaging Quantification of Fatty Muscle Degeneration—Initial Experience with 1-year Follow-up. *Radiology* **280**, 500–509 (2016).
 34. Schlager, A. *et al.* Inter- and intra-rater reliability for measurement of range of motion in joints included in three hypermobility assessment methods. *BMC Musculoskelet. Disord.* **19**, 1–10 (2018).
 35. Tripepi, G., Jager, K. J., Dekker, F. W. & Zoccali, C. Selection Bias and Information Bias in Clinical Research. *Nephron Clin. Pract.* **115**, c94–c99 (2010).
 36. Liu, C.-Y., McKenzie, C. A., Yu, H., Brittain, J. H. & Reeder, S. B. Fat quantification with IDEAL gradient echo imaging: Correction of bias from T1 and noise. *Magn. Reson. Med.* **58**, 354–364 (2007).
 37. Milford, D., Rosbach, N., Bendszus, M. & Heiland, S. Mono-Exponential Fitting in T2-Relaxometry: Relevance of Offset and First Echo. *PLoS One* **10**, e0145255 (2015).
 38. Koo, T. K. & Li, M. Y. A Guideline of Selecting and Reporting Intraclass Correlation Coefficients for Reliability Research. *J. Chiropr. Med.* **15**, 155–163 (2016).
 39. Cicchetti, D. V. Guidelines, criteria, and rules of thumb for evaluating normed and standardized assessment instruments in psychology. *Psychol. Assess.* **6**, 284–290 (1994).
 40. ten Dam, L., van der Kooi, A. J., Verhamme, C., Wattjes, M. P. & de Visser, M. Muscle imaging in inherited and acquired muscle diseases. *Eur. J. Neurol.* **23**, 688–703 (2016).
 41. Odor, P. M., Bampoe, S. & Cecconi, M. Cardiac Output Monitoring: Validation Studies—how Results Should be Presented. *Curr. Anesthesiol. Rep.* **7**, 410–415 (2017).
 42. Ludbrook, J. Confidence in Altman-Bland plots: A critical review of the method of

- differences. *Clin. Exp. Pharmacol. Physiol.* **37**, 143–149 (2010).
43. Bland, M. J. & Altman, D. G. Statistical methods for assessing agreement between two methods of clinical measurement. *Lancet* (1986). doi:10.1016/S0140-6736(86)90837-8
 44. Monti, S., Montecucco, C., Bugatti, S. & Caporali, R. Rheumatoid arthritis treatment: The earlier the better to prevent joint damage. *RMD Open* **1**, e000057 (2015).