



This is a repository copy of *High bone mass phenotype in a cohort of patients with Osteogenesis Imperfecta caused due to BMP1 and C-propeptide cleavage variants in COL1A1.*

White Rose Research Online URL for this paper:
<https://eprints.whiterose.ac.uk/176213/>

Version: Published Version

Article:

Campanini, E.H., Baker, D., Arundel, P. et al. (9 more authors) (2021) High bone mass phenotype in a cohort of patients with Osteogenesis Imperfecta caused due to BMP1 and C-propeptide cleavage variants in COL1A1. *Bone Reports*, 15. 101102.

<https://doi.org/10.1016/j.bonr.2021.101102>

Reuse

This article is distributed under the terms of the Creative Commons Attribution-NonCommercial-NoDerivs (CC BY-NC-ND) licence. This licence only allows you to download this work and share it with others as long as you credit the authors, but you can't change the article in any way or use it commercially. More information and the full terms of the licence here: <https://creativecommons.org/licenses/>

Takedown

If you consider content in White Rose Research Online to be in breach of UK law, please notify us by emailing eprints@whiterose.ac.uk including the URL of the record and the reason for the withdrawal request.



eprints@whiterose.ac.uk
<https://eprints.whiterose.ac.uk/>



High bone mass phenotype in a cohort of patients with Osteogenesis Imperfecta caused due to *BMP1* and C-propeptide cleavage variants in *COL1A1*

E.H. Campanini^a, D. Baker^b, P. Arundel^c, N.J. Bishop^{c,d}, A.C. Offiah^{c,d}, S. Keigwin^b, S. Cadden^b, E. Dall'Ara^d, N. Nicolaou^e, S. Giles^e, J.A. Fernandes^e, M. Balasubramanian^{c,d,f,*}

^a Medical School, University of Sheffield, Sheffield, UK

^b Sheffield Diagnostic Genetics Service, Sheffield Children's NHS Foundation Trust, Sheffield, UK

^c Highly Specialised OI Service, Sheffield Children's NHS Foundation Trust, Sheffield, UK

^d Department of Oncology & Metabolism, University of Sheffield, Sheffield, UK

^e Department of Orthopaedic Surgery, Sheffield Children's NHS Foundation Trust, Sheffield, UK

^f Sheffield Clinical Genetics Service, Sheffield Children's NHS Foundation Trust, Sheffield, UK

ARTICLE INFO

Keywords:

High bone mineral density

Bone fragility

Fractures

BMP1

C-propeptide

ABSTRACT

Objectives: Osteogenesis Imperfecta (OI) is a heterogeneous condition mainly characterised by bone fragility; extra-skeletal features in OI include blue sclerae, dentinogenesis imperfecta, skin laxity and joint hyper-extensibility. Most patients with OI are thought to have a low bone mass but contrary to expectations there are certain forms of OI with high bone mass which this study explores in further detail.

Method: A cohort of $n = 6$ individuals with pathogenic variants in *BMP1* and the C-propeptide cleavage variants in *COL1A1* were included in this study. Detailed clinical and radiological phenotyping was done and correlated with genotype to identify patterns of clinical presentation and fracture history in this cohort of patients. This data was compared to previously reported literature in this group.

Results: 2 patients with *BMP1* and 4 patients with pathogenic variants in C-propeptide region in *COL1A1* were deep-phenotyped as part of this study and 1 patient with C-propeptide variant in *COL1A1*, showed low bone mineral density. In those with an elevated bone mineral density, this became even more apparent on bisphosphonate therapy. Patients in this cohort had variable clinical presentation ranging from antenatal presentation to more of an insidious course resulting in later confirmation of genetic diagnosis up to 19 years of age.

Conclusions: Patients with pathogenic variants in the C-propeptide region of *COL1A1/A2* and *BMP1* appear to have a high bone mass phenotype with increased sensitivity to bisphosphonate therapy. It is important to closely monitor patients with these genotypes to assess their response to therapy and tailor their treatment regime accordingly.

1. Introduction

Osteogenesis Imperfecta (OI), also known as brittle bone disease, is an inherited disorder of the connective tissues causing bone fragility and leading to a high fracture risk (Marini et al., 2017). It is a rare disorder, present in 1 in 15–20,000 births (Forlino and Marini, 2016), yet it is the most common form of inherited bone fragility (Marshall et al., 2016).

An initial diagnosis of OI is typically made from a combination of clinical and radiological findings. Key features on presentation include: fractures, growth deficiency, and skeletal deformities, in particular

bowing of the long bones (other deformities include: flat midface and triangular facies, chest wall deformities and scoliosis) (Forlino and Marini, 2016). The fractures characteristically present following minimal trauma, in atypical locations and are recurrent (Marom et al., 2020). The fracture risk also involves the increased likelihood of vertebral compressions (Marini et al., 2017). The severity of the disease can range greatly, from mild forms with very few or no fractures, to very severe forms presenting with *in utero* fractures and perinatal death (Sangsin et al., 2017).

There are also common secondary features, which include: blue

* Corresponding author at: Sheffield Clinical Genetics Service, Sheffield Children's Hospital NHS Foundation Trust, Western Bank, Sheffield S10 2TH, UK.

E-mail address: meena.balasubramanian@nhs.net (M. Balasubramanian).

<https://doi.org/10.1016/j.bonr.2021.101102>

Received 13 June 2021; Accepted 27 June 2021

Available online 1 July 2021

2352-1872/© 2021 Published by Elsevier Inc. This is an open access article under the CC BY-NC-ND license (<http://creativecommons.org/licenses/by-nc-nd/4.0/>).

sclerae, relative macrocephaly, dentinogenesis imperfecta (DI), and hearing loss. It has been noted that these secondary features are commonly absent in the recessive forms of OI (Forlino and Marini, 2016). Other potential features include short stature, joint laxity (Sangsin et al., 2017), basilar invagination, and cardiac/pulmonary problems (Marini et al., 2017).

The revised Sillence Classification recognises OI types I to V (Van Dijk and Sillence, 2014). This describes the different presentations caused by variants in the *COL1A1* and *COL1A2* genes, the *IFITM5* gene, and some of the recessive forms of the condition (Barnes et al., 2019). This classification has since been adapted to include OI types V-XX of OI which are associated with variants in other genes. Variants in the *BMP1*, as seen in this cohort, cause Type XII OI (Marini and Dang Do, 2020).

Type I OI is caused by a null allele in *COL1A1* (Barnes et al., 2019) and presents with mild features, with infants typically fractures at the time they begin mobilising, but these decrease in frequency after puberty. They may have some bowing of the long bones, and commonly have blue sclerae. Type II OI is lethal in the perinatal period, commonly presenting with many skeletal deformities *in utero*. Type III OI (progressive deforming type) is the most severe survivable form, patients may sustain hundreds of fractures throughout their life mainly following minimal trauma. Other common features in type III OI include dentinogenesis imperfecta (DI), chest wall abnormalities and severe scoliosis. Type IV OI presents with mild to moderate bone deformity and patients typically have white sclerae although they may have been lightly blue at birth. Variants in *BMP1* cause a moderate to severe presentation and patients often have early recurrent fractures and possible long bone bowing, despite having a high bone mass (Marini and Dang Do, 2020).

The most common genes associated with OI are those which encode Type 1 collagen (*COL1A1* and *COL1A2*) (Syx et al., 2015); however, variants in other genes account for up to 15% of cases (Marom et al., 2020). This paper discusses 18 genes (from Online Mendelian Inheritance in Man (OMIM)) with variants associated with OI, including: *BMP1*, *COL1A1*, *COL1A2*, *CREB3L1*, *CRTAP*, *FKBP10*, *IFITM5*, *MBTPS2*, *MESD*, *P3H1*, *PPIB*, *SERPINF1*, *SERPINH1*, *SP7*, *SPARC*, *TENT5A*, *TMEM38B*, *WNT1*. These genes are associated with different types of OI and have a variety of proposed pathways and mechanisms. Variants in *COL1A1*, *COL1A2* and *IFITM5* have an autosomal dominant pattern of inheritance. Variants in other genes, including *BMP1*, are responsible for autosomal recessive forms of OI, except for *MBTPS2* which has an X-linked recessive inheritance (Marom et al., 2020).

Type 1 collagen is made up of two alpha1 chains (encoded for by *COL1A1*) and one alpha2 chain (encoded for by *COL1A2*). As these genes are involved in the synthesis, structure and assembly of type 1 collagen, variants can decrease the production (e.g., type I OI) or alter the structure (e.g., types II to IV OI) (Marini and Dang Do, 2020). Research has shown that ~6.5% of patients with OI have variants in the C-propeptide (carboxyl terminal propeptide) of type I procollagen (Barnes et al., 2019). The C-propeptide is important during the synthesis of procollagen and is cleaved extracellularly before the fibril assembly of mature collagen (Barnes et al., 2019). A high bone mass has been associated with variants involved with the cleavage of C-propeptide (Rolvien et al., 2018). *BMP1* is involved in the processing of type I collagen, cleaving the C-propeptide moiety; variants in this gene have been associated with high bone mineral density (Marini and Dang Do, 2020).

A high bone mass form of OI could require a different management approach due to the paradigm of clinical presentation. Bisphosphonate treatment is the standard treatment for patients with OI and is known to increase bone mineral density. However, in the context of high bone mass, it is difficult to be precise regarding dosing of bisphosphonate treatment. In addition, surgical interventions may be complicated by the quality of bone and risk of further fractures thereafter. It is also possible that background genetic variants can have an influence on certain OI phenotypes, especially with the dominant C-propeptide cleavage variants.

This paper describes the clinical data of patients with variants in the

BMP1 and C-propeptide of *COL1A1/A2* genes, with a focus on those with OI associated with high bone mass.

2. Materials and methods

2.1. Clinical information

A cohort of six patients with OI and variants in *BMP1* or *COL1A1/A2* was examined in this study. With their informed consent (and their parent's where necessary), relevant clinical data were extracted from the patients' medical records to put together a history and phenotype.

2.2. DNA extraction

Standard extraction methods were used to collect 2 to 5 ml of peripheral blood from the patients and their parents. In one instance, a blood sample was also extracted from the umbilical cord. The *QIAmp* DNA Blood Midi kit (Qiagen, Venlo, The Netherlands) was used to extract the DNA from these samples.

2.3. DNA sequencing

The samples were then prepared for analysis using Next Generation Sequencing. Osteogenesis Imperfecta autosomal dominant and autosomal recessive panels were used, containing: NM_006129.5 (*BMP1*); NM_000088.3 (*COL1A1*); NM_000089.3 (*COL1A2*); NM_052854.3 (*CREB3L1*); NM_006371.4 (*CRTAP*); NM_001025295.1 (*IFITM5*); NM_022356.3 (*P3H1*); NM_000942.4 (*PPIB*); NM_021939.3 (*FKBP10*); NM_152860.1 (*SP7*); NM_002615.4 (*SERPINF1*); NM_001235.2 (*SERPINH1*), NM_182943.2 (*PLOD2*); NM_018112.1 (*TMEM38B*); NM_005430.3 (*WNT1*), NM_000918.2 (*P4HB*); NM_005032.6 (*PLS3*); NM_014822.2 (*SEC24D*); NM_003118.3 (*SPARC*); NM_153365.2 (*TAPT1*); NM_022167.3 (*XYLT2*).

2.4. Library preparation

The Covaris E220 sonicator was used for the shearing of genomic DNA. The SureSelectCT library system (Agilent Technologies) was used to perform the end repair, A tailing and ligation of adaptors. SureSelect target enrichment (Agilent Technologies) performed target enrichment using custom in house designed probes. Sequencing was performed on the Illumina HiSeq using the HiSeq Rapid SBS Kit v2 performing 2 × 108 base pair paired end reads.

2.5. Data analysis

Data analysis was carried out using the Best Practice Guidelines from Broad Institute.

BWA alignment was used in order to map the reads to the human reference sequence (GRCH37/hg19) (for additional information see <http://www.broadinstitute.org/gatk/guide/best-practices>).

A read depth of 30-fold was set as a minimum threshold for exonic sequences and intronic sequences up to and including 5 bp from the ends of each exon. A read depth of 18-fold was set as the minimum threshold for intronic sequences from 6 to 25 bp from the ends of each exon. Haplotype Caller (Broad Institute) was used to identify variants and the variants were filtered against this in-house polymorphism list.

2.6. Variant reporting

Once identified, the variants were compared to cDNA reference sequences NM_003118.3 and then assessed with Alamut Visual version 2.11 QT v5.5.1 (Interactive Biosoftware, Rouen, France). The sequence variants were all classified using guidelines for variant interpretation: ACMG/AMP (Richards et al., 2015) and ACGS Best Practice Guidelines for variant classification 2020 (<https://www.acgs.uk.com/quality/>

best-practice-guidelines/). As necessary, clinically significant sequence variants were confirmed using Sanger sequencing.

2.7. Clinical reports

2.7.1. Patient 1

Patient 1 is a 19-year-old female, born to non-consanguineous parents. She was born at term following an uncomplicated pregnancy and a normal vaginal delivery. Her birth weight was 2400 g and her length was 62 cm. She is the youngest of three children and both siblings are well. Despite frequent fractures, her general health has been fine. She was investigated several times for possible cardiac problems, including heart murmur and episodes of tachycardia and palpitations, but all tests were negative. She has normal intelligence and attended mainstream school; she reached menarche at age 13.

She was diagnosed with type I OI by the Genetics service in Poland. She presented with a history of multiple fractures, not consistent with injury which had increased in frequency once she became independently mobile. It was also reported that she had hypermobile joints and a blue tinge to her sclerae. Her first fracture was to her right lower leg at 14 months old, and by the time she was 5 years old, she had sustained more than 10 fractures including multiple fractures to both lower limbs. And at age 6, she had bilateral tibial Sheffield rodding.

She arrived in the United Kingdom with her family at the age of 4 and was referred to the paediatric bone disease specialists due to her diagnosis. On examination, she had white sclerae and no evidence of dentinogenesis imperfecta. She did have bilateral tibial bowing and genu valgum with an intermalleolar distance of 10 cm. There was normal bone densitometry, and the spinal films had no major findings, although three vertebrae in the thoracic spine showed a slight decrease in anterior height.

She was started on pamidronate at age 7 (1 mg/kg/day on 3 successive days every 3 months) following a finding of an increasingly deformed crush fracture to the thoracic vertebrae. She was also found to have Grade I spondylolisthesis at the L5/S1 level. Around this time, she was also advised to take over-the-counter supplements to treat vitamin D deficiency. Due to the recurrent fractures, she was anxious to stand and mainly mobilising by crawling and being carried around the house. For longer distances, she was using an attendant propelled wheelchair. A few months after commencing pamidronate treatment, her BMD lumbar spine had increased from 75th percentile to between the 75th and 98th percentile and the BMD for the total body was between the 50th and 75th. This was deemed to be increasing at a reasonable rate.

6 months later she was no longer needing a walking aid for the home or classroom. She was also now using a manual wheelchair for longer distances and becoming more independent with daily activities. She was noted to have some hyperextension in distal joints, but this was not impacting her functioning and she was able to swim and ride a trike. She continued to have valgus at the knees, with an angle of approximately 20°. Areal bone mineral density (BMD) by dual energy x-ray absorptiometry (DXA) continued to rise and, at the time of her 4th cycle of pamidronate, was above the normal range in lumbar spine (LS) and close to the upper limit in the total body less head (TBLH).

At age 8, she tripped and suffered her first fracture in over a year, to her right tibia, which was held in place by the rod. 3 months later, she was given a decreased dose of pamidronate (1 mg/kg on 2 successive days) as it was noticed that the BMDs of lumbar spine and total body were now both above the normal range and it was decided to further reduce the dose of pamidronate for the next cycle. After her 8th cycle of pamidronate, her DXA scan showed +4.4 and +4.5 standard deviation scores (z scores) above the mean for total body less head and lumbar spine respectively. Densitometric vertebral analysis showed a good vertebral shape and spine radiographs showed mild vertebral height loss in two thoracic vertebrae. There was no increase in growth plate width, no deformity of the skull bone and there was no evidence to explain the large increase in BMD. Pamidronate therapy was continued on the basis

that the vertebral crush fractures had not completely resolved.

At age 9, her BMD was still high and it was decided to reduce the pamidronate further to 0.75 mg/kg once, every 3 months. The dose was reduced again (to 0.5 mg/kg once every 6 months) just before she turned 12 as the bone density was still above normal with the z score in her lumbar spine at +3.0 and total body less head at +1.4. She was switched to oral risedronate at 12 years old beginning with 35 mg weekly, reducing to alternate weeks a year later.

At 13 years and 9 months, her lumbar spine BMD z score was +4.3 (previously +4.7) and TBLH was unchanged at +3.1. By this age, she had scoliosis concave to right, believed to be a result of a leg length discrepancy (at age 15, her left leg was 3 cm shorter than the right). She also had increased lumbar lordosis thought to be due to a low sacral kyphosis with a bony shelf. Due to the persisting high BMD despite reducing the bisphosphonate to low levels, it was decided to consider testing for rarer gene mutations causing OI. Fig. 1 shows her BMD trend with age and dense bones on radiographs.

At 14 years, genetic testing identified that she was homozygous for a pathogenic variant in *BMP1* and familial testing showed that both her mother and father were carriers of a variant each.

Patient 1 continued to have occasional fractures and at age 14½, she fractured her distal left humerus after her wheelchair tipped over. By 17 years old, she had both femurs treated with locked, intramedullary nails and both tibiae had telescopic rods which were somewhat bent. There was some metalwork in the left elbow remaining from a previous fixation. There were hemiepiphyseodesis plates *in situ* in medial distal femora bilaterally and proximal medial tibia on the left.

She was discharged from the bone clinic age 17 and 8 months, taking vitamins but no bisphosphonate treatment since age 14½. She was mainly mobilising with a wheelchair but was able to walk short distances if needed. She was seeing a dentist every 6 months, but had no DI.

2.7.2. Patient 2

Patient 2 is a 12-year-old female, the only child of non-consanguineous parents. She was born at 39 weeks following an uncomplicated IVF pregnancy and had a birth weight of 6 lb. 9 oz. She was well at birth and breast fed without any problems. She had one episode of pneumonia at 8 months but was otherwise well. Other than both parents having some degree of hypermobility, there is no other family history of note.

Through her first year of life, she met all developmental milestones. The first concerns did not arise until around 16 months when she was still not walking; however, this followed her mother's development who did not start walking until 18 months, so the parents were not overly concerned. The patient was bottom shuffling at 17 months and, at this time, it was noted that she was very hypermobile. At 21 months, she was still not walking and so was referred to the paediatric clinic. She was found clinically to have bilateral dislocated hips.

She had three operations for her hips, the first of which was at 25 months, and each operation led to at least 6 weeks of cast immobilisation. On her third birthday, she had her first fracture to her fibula and was casted. Within a week, she presented to A&E with a fracture to the left tibia having slipped while leaning against the sofa. Over the next 8 months, she suffered a further 3 fractures to her lower limbs following minimal trauma. Her speech and fine motor development were both normal for her age.

It was initially thought that the fractures were most likely due to osteopenia secondary to long periods of immobilisation; however, she had extensive investigations and was referred to genetics for a possible diagnosis of Ehlers Danlos syndrome due to her joint hypermobility and skin laxity. Treatment with pamidronate was offered, but her parents declined.

Investigations included an MRI head and spine, urine amino-organic acid, acylcarnitine and Prader Willi Screen; all of which were normal. Blood results from FBC, U&E, bone profile, PTH, vitamin D showed that PTH was 0.8 pmol/l and vitamin D was 58 nmol/l but the rest were

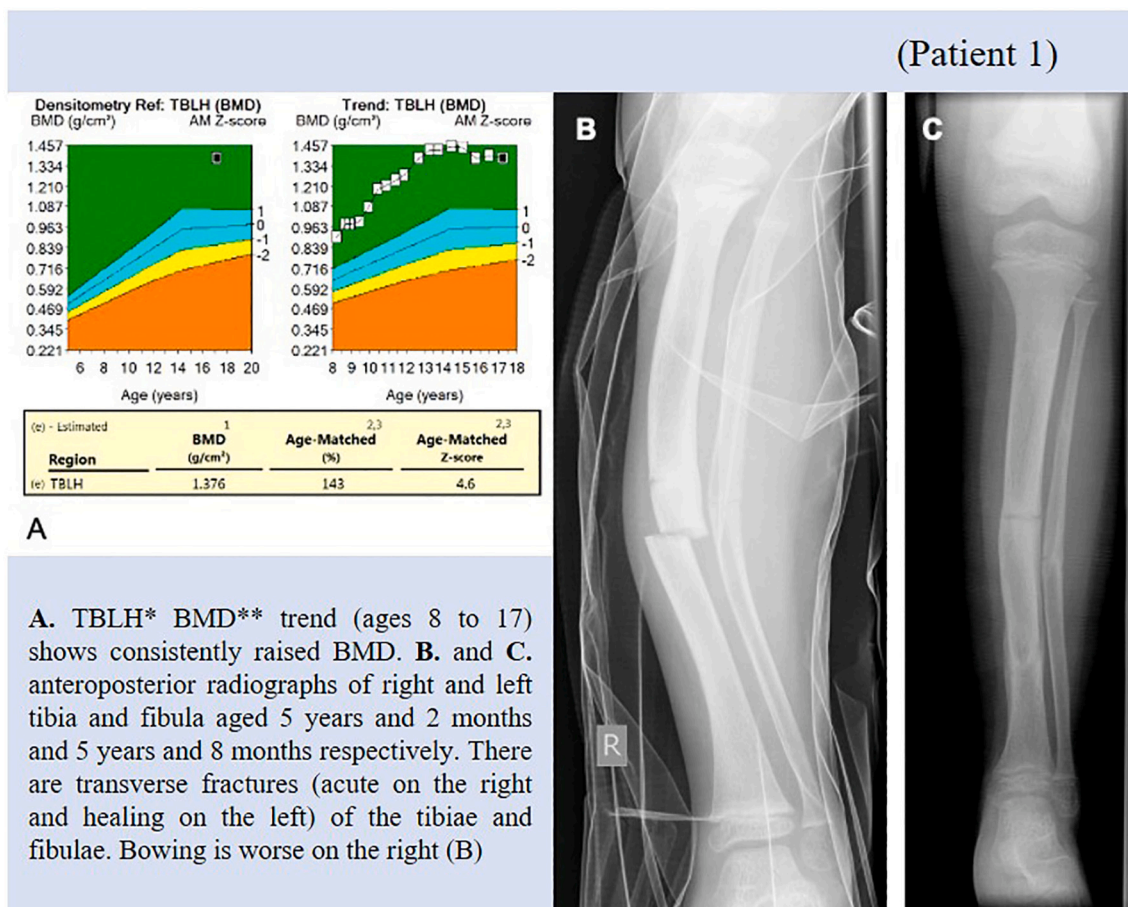


Fig. 1. A. TBLH* BMD** trend (ages 8 to 17) shows consistently raised BMD.

B. Anteroposterior radiographs of right (B) and left (C) tibia and fibula aged 5 years and 2 months and 5 years and 8 months respectively. There are transverse fractures (acute on the right and healing on the left) of the tibiae and fibulae. Bowing is worse on the right (B).

*TBLH = total body less head.

**BMD = bone mineral density.

normal. She also had a DXA scan at this time. It showed L2–4 BMD: 0.728 g/cm² and TBLH BMD: 0.577 g/cm², the latter scan included numerous metal pins. There was no paediatric reference data but at the time it was thought that the lumbar result was likely high for her age.

At age 4, she was started on pamidronate infusions for about 12 months. After 3 cycles, her BMD increased considerably, and she had chalk stick fractures of the tibiae and fibulae. A clinical diagnosis of osteopetrosis was considered; however, bone biopsy findings did not support this and showed active osteoclasts and ok bone resorption. On examination, she was found to have a high forehead and light blue sclerae. She also had generalised joint hypermobility and her skin was lax over her abdomen.

By age 6 and ½, she had had a total of 16 fractures. She was just above the 50th centile for weight and between the 50th and 75th centiles for height. She had also had dislocations of her left shoulder while swimming, on three separate occasions, all with spontaneous reduction. She was able to walk with a stander and was attending mainstream school regularly, also mobilising with a wheelchair. She was having weekly hydrotherapy sessions.

She was referred to Genetics Clinic at 6 years and 9 months in order to rule out a possible diagnosis of OI. She had previously tested negative for variants in type I collagen genes (*COL1A1* and *COL1A2*), but went onto to have further testing which identified her to be compound heterozygous for variants in *BMP1*. Subsequently, familial testing showed her parents were carriers of one variant each.

1 year later, she had had only one further fracture. She was, however,

still having regular dislocations of her shoulder and hypermobile. She was lax at both large and small joints with skin hyperlaxity. She also had increased range of movement in both hips and a leg length discrepancy which led to scoliosis on standing.

Quantitative CT imaging showed very high values in the peripheral skeleton with a radius z score of +8.7 and a trabecular z score at distal radius +9.2. Her lumbar spine BMAD Z score was +4.02 and her lumbar spine QCT Z score was +3.6. Fig. 2 shows her BMD trend with age and dense bones on imaging.

Throughout her education, she attended mainstream school, with one-to-one help for physical education (PE) and later use of writing aids including an angled board and Y shaped pencils as she was tired easily when writing. She was able to walk short distances independently but preferred to wear splints and used her wheelchair for longer distances. By 9 years and 8 months, she had 25° curvature of the spine and had also had recent correction of genu valgum by hemi-epiphysiodesis. She was wearing new AFOs and using a recumbent bike for exercise.

By age 10 ½, she had bilateral intramedullary rods *in situ* and had not had any fractures or dislocations for 2 years, since before her tibial rods and her most recent DXA scan (6 months previously), showed the lumbar spine Z score to be +1.8. She was taking multivitamins and cholecalciferol, but no other medications. On examination, she had scoliosis concave to the right with the left scapula higher than the right, which was confirmed radiologically with no suggestion of segmentation anomaly, no syrinx, and no focal marrow oedema. Recent hip films showed coxa valga with the right femoral head significantly more

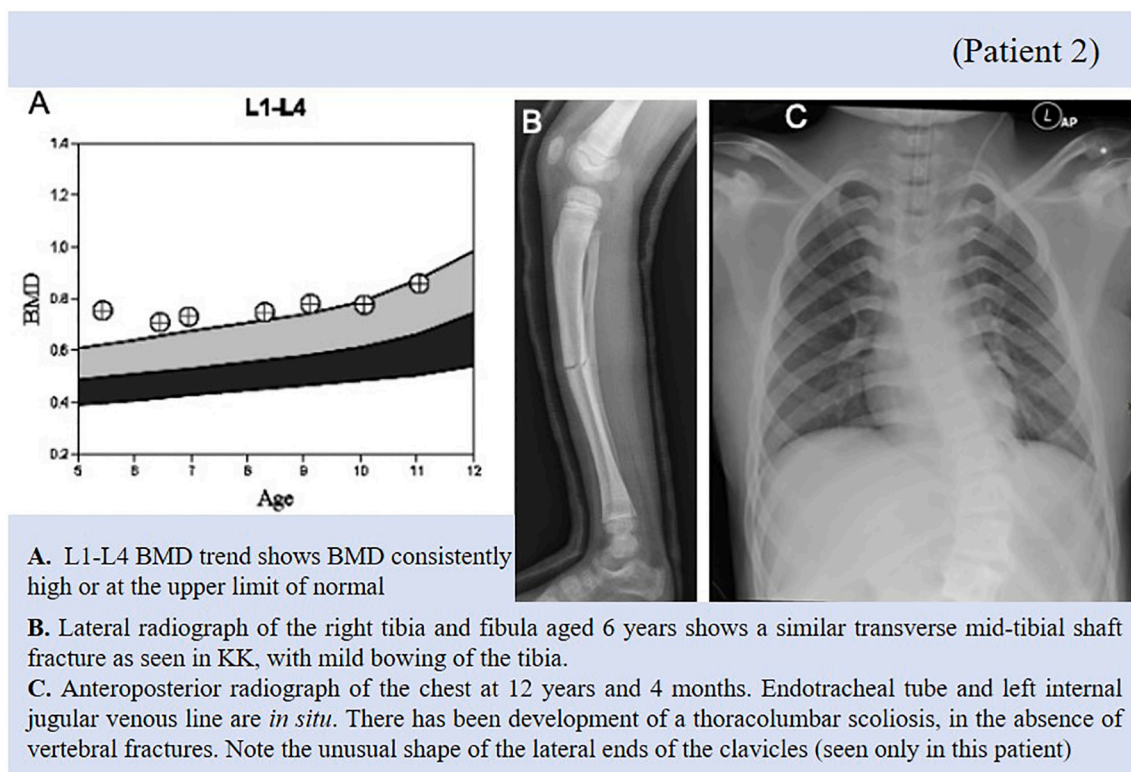


Fig. 2. A. L1-L4 BMD trend shows BMD consistently high or at the upper limit of normal.

B. Lateral radiograph of the right tibia and fibula aged 6 years shows a similar transverse mid-tibial shaft fracture as seen in Patient 1, with mild bowing of the tibia.

C. Anteroposterior radiograph of the chest at 12 years and 4 months. Endotracheal tube and left internal jugular venous line are *in situ*. There has been development of a thoracolumbar scoliosis, in the absence of vertebral fractures. Note the unusual shape of the lateral ends of the clavicles (seen only in this patient).

uncovered than the left.

By age 12, she was walking independently again, however her scoliosis was worsening. She was also receiving psychology input due to increasing frustration with her condition. 3 months later, she underwent correction of her scoliosis. She had slow tooth eruption and dental crowding but no DI.

2.7.3. Patient 3

Patient 3 is a 12-year-old male who was diagnosed antenatally with a severe form of OI and it was believed he would not survive for long postnatally. He had 2 older siblings including a half-sister with a history of fractures, and he was born following a dichorionic, diamniotic twin pregnancy with the female twin unaffected. The labour was induced at 27 weeks and both babies were born well by normal vaginal delivery and no resuscitation was required. Patient 3 had a birth weight of 2440 g and was born with multiple fractures of almost every bone in his body.

He was initially given analgesia to help with discomfort and on the day of delivery, he had cast immobilisation applied to four limbs to stabilise fractures for pain relief. Initially he was demand fed but had been vomiting after feeds and so was given an NG tube.

He did not die shortly after birth as expected and instead was transferred from the neonatal unit to a hospice. He continued to be managed with the expectation that he would die; however, a week later, he was still alive. It was decided that a palliative approach was not appropriate for his phenotype and he would benefit from bisphosphonate treatment. He was then transferred to the HDU where he was given 2 infusions of pamidronate on successive days. At 17 days, he had a skeletal survey and clinical phenotyping. He had multiple Wormian bones, but a normal head shape and no mid-face hypoplasia. His skeletal phenotype was reported to be unusual; he had a mixture of wider, slightly crumpled femora and thinner distal segments. Despite multiple rib fractures, he did not have any vertebral crush fractures. The high

number of fractures was thought to be a possible consequence of sharing the uterine space with an unaffected twin.

He had several health complications over the first few months of life, including ventilation problems meaning he was still requiring oxygen at 9 months of age. He was also found to have a patent foramen ovale although this had spontaneously closed by the age of 5. His feeding was also complicated by gastroesophageal reflux. He was discharged home at 7 months, although this late discharge was largely due to the family finding suitable housing. At 4 ½ years old, genetic testing showed he had a *de novo* variant in the C-propeptide region in *COL1A1*.

As a consequence of his diagnosis, his gross motor skills were delayed; he was able to roll from side to side in lying position by age 1 and was crawling on his hands and knees at age 4. While his gross motor skills development was delayed, in all other areas, he was meeting milestones. There were no concerns regarding his intelligence, and he was able to attend mainstream school with 1:1 support.

By age 5 ½, he had undergone multiple surgeries including osteotomies and telescopic rodding bilaterally to the femora and tibiae, to attempt to straighten the long bones. By this age he was confident in using a wheelchair for mobilising. He was also wearing glasses due to astigmatism and was under the dentists for a diagnosis of dentinogenesis imperfecta. A year later he was investigated for possible sleep apnoea following reported lengthy pauses in breathing with associated pallor; however, this was found to not be an issue.

His BMD was constantly low, with a DXA scan at age 5 ½ showing the lumbar spine BMD to be 0.483 g/cm² (Z score of -2.0) and the total body less head to be 0.443 g/cm² (Z score of -1.1). This further decreased to -2.2 and -1.8 respectively a year later and at 7 years old, the L2-4 BMD Z score was -2.7 (BMAD Z score -3.3) and the TBLH Z score was -1.6.

At 7 years and 3 months, while in plaster following a recent revision surgery for the tibia rodding, he was able to stand with the support of the

therapist for the first time and was able to take some steps with a walker. 3 months later, he was switched from pamidronate to zoledronic acid (0.04 mg/kg for one day every 6 months) as there were difficulties around cannulation and it was thought he would benefit from fewer infusions. It had also been noted that he had been developing blisters on the tips of his fingers following the treatments. However, the zoledronic

acid was found to not be as effective and so he was switched back again shortly afterwards. The dose was later changed to 1.5 mg/kg on one day to minimise the cannulation required.

He began to encounter problems where he had outgrown the previous corrective surgeries. At 8 years of age, he was found to have outgrown the intramedullary wire in his right forearm which had begun

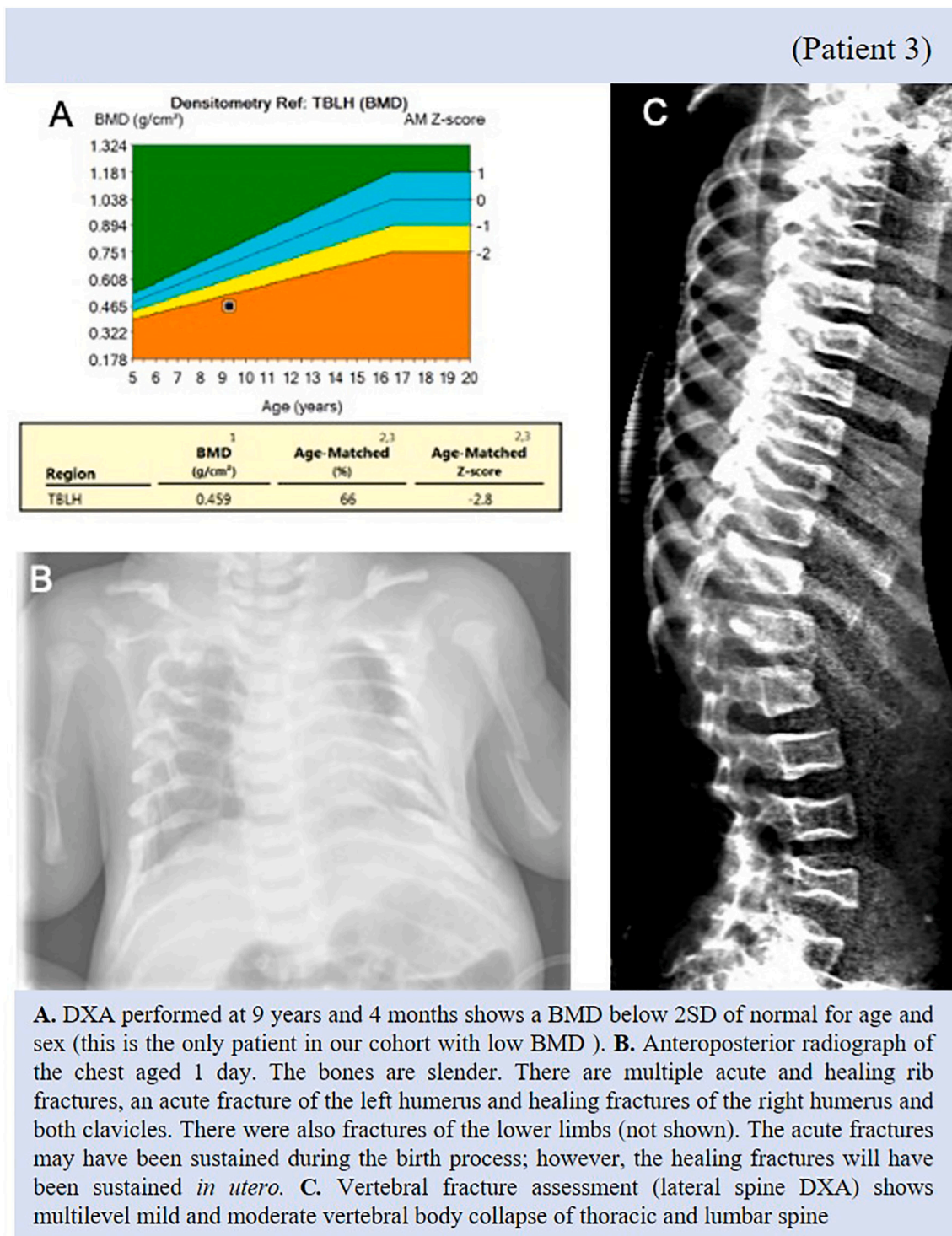


Fig. 3. A. DXA performed at 9 years and 4 months shows a BMD below 2SD of normal for age and sex (this is the only patient in our cohort with low BMD). B. Anteroposterior radiograph of the chest aged 1 day. The bones are slender. There are multiple acute and healing rib fractures, an acute fracture of the left humerus and healing fractures of the right humerus and both clavicles. There were also fractures of the lower limbs (not shown). The acute fractures may have been sustained during the birth process; however, the healing fractures will have been sustained *in utero*. C. Vertebral fracture assessment (lateral spine DXA) shows multilevel mild and moderate vertebral body collapse of thoracic and lumbar spine.

to irritate the soft tissue, causing him significant pain. At 9 years and 3 months, pain in his left buttock showed a palpable rod which required revision rodding. Just before he turned 10, he was having slight pain over his right proximal humerus and a radiograph confirmed that the telescopic rod had cut out. He subsequently underwent removal of the rod and diaphyseal osteotomy with revision rodding.

Patient 3 also had bone local mechanical properties assessed on a bone specimen mainly of cortical bone, obtained from the upper limb (hardness and elastic modulus) assessed using nano-indentation tests (Pepe et al., 2020) tested in different locations (192 tests within different regions of the specimen). The results showed high heterogeneity in the local material properties of the bone in different locations, with coefficient of variations in the range of 43–48% (Elastic modulus equal to 11.20 ± 5.39 GPa; Hardness equal to 0.49 ± 0.21 GPa). The elastic modulus measured in the bone was 30–40% lower than the average values found in bones extracted from the lower limb or iliac crest of OI type I or type III young patients (3–18 years old) (Albert et al., 2013; Fan et al., 2007). This difference could be due to the different disease, the tested anatomical site and/or the age of the patients. Nevertheless, given absence of normative paediatric literature and analysis of only one sample, it was difficult to draw any firm conclusions from this data.

At 9 ½ years, his DXA scan showed a TBLH BDM of -2.8 (previously -1.5) (Fig. 3). Densitometric vertebral fracture assessment (VFA) showed little change, but possible worsening of shape of L2 and L3 vertebrae and there were still multiple vertebrae with loss of height. At this age, he was mobilising using a walking frame and his spine was straight with no obvious tenderness.

At 10 years and 3 months, he was noted to have bilateral thyroid nodules however they appeared benign and microcystic and it was decided that there was no need for further investigations unless indicated by a change in biochemistry results. At this age, his BMD was still at the lower range of normal. His L2–4 BMD z score was -2.1 (BMAD -2.0) and his total body less head BMD z score was -0.6 (BMAD -2.6). VFA showed a continued mild-moderate loss of height of several thoracic vertebral bodies, moderate loss of height of L2, and marked loss of height of L3 and L4. His weight was 17.95 kg and his length was 97.5 cm and 102 cm (due to leg length discrepancy). His spine was straight.

By age 11, he had further interventions including trimming and reinsertion of the K wire which was eroding at the elbow following revision rodding of the right ulna. This rod was later removed. He had pain in the left hip due to left migration of the femoral telescopic rod which required readjustment. Recent scans had shown no spondylolysis, but an almost parallel sacrum and a further significant bend in the lower sacrum coccyx.

At 11 ½ years old, he had radiological investigations following a possible finding of hyperextension of C2 and C3 on a skull radiograph a year previously. He was also occasionally having pain at the back of the neck, associated with some headaches. It was reported that the tip of the dens was at C2 and he had a wide anterior gap. It was decided that there was no need for neurosurgical intervention at that time.

A month later, he suffered an undisplaced horizontal fracture through his right radius while reaching out for a video game controller and he was placed in a below the elbow soft cast. 12 weeks later, radiograph showed fractures to the distal 1/3 shaft of radius and ulna which were not uniting and causing deformity and required a splint. By 11 years and 10 months, the deformity had worsened although the non-union was painless. His arm was neurovascularly intact and so surgical correction was planned for.

2.7.4. Patient 4

Patient 4 is a 9 year old male born to non-consanguineous parents. He was born at 40 + 4 weeks following an uncomplicated pregnancy and normal vaginal delivery. His birth weight was 3855 g and he had no clinical evidence of fractures. His father had recently been diagnosed with type 1 OI following familial genetic testing due to a diagnosis in his nephew. Therefore, Patient 4 had pre-symptomatic testing of the cord

blood at birth which showed him to be heterozygous for a variant in *COL1A1*, like others in his family including his father and grandfather. Affected members of the family appeared to follow a similar pattern of fractures at birth and then none until age 15.

At 3 days old, the patient was referred with swelling to the right thigh and was found to have a fracture of the right femur, which was confirmed on radiographs and managed conservatively. At 4 weeks old, he attended hospital again with a fracture of the left distal humerus after his left arm had got caught in his vest sleeve. At this time, he also had a skeletal survey which showed an old fracture to the right femur with no callus, a fracture to the right radius with some callus and a fracture to the 6th rib with some callus, as well as two new fractures, including the one to the left humerus and one to the right femur (Fig. 4). He was admitted and placed in gallows traction for 11 days and then a pelvic harness. At 6 weeks, he was started on pamidronate at the standard dose of 0.5 mg/kg.

At 6 months, he had sustained no further fractures. He was now sitting unsupported for short periods, was comfortable pushing up from prone, but was not yet pulling to stand. He was fully weaned and growing well with a weight of 8.8 kg (50th centile) and a length of 69 cm (75th centile). On examination, he had blue sclerae and some flattening of the left side of the occiput. His teeth, that had erupted appeared normal, he had normal shaped facies, normal chest shape and a straight spine with no tenderness. Lateral spine films showed minor loss of height in two of the thoracic vertebrae and he had a mild degree of bowing of both femora, but no other long bone deformities.

Other than a single skull fracture at 11 months, Patient 4 had no further fractures until he was 2 years old; he fractured his right femur while at soft play and was treated with a fixed rod. He was standing and cruising around furniture at 11 months and by 16 months, his development was age appropriate. A DXA scan at 13 months showed his lumbar spine BMD to be 0.405 g/cm². There was little change in the appearance of the vertebrae and persisting loss of height in two thoracic vertebrae. At 22 months, his spine was straight, he had good muscle bulk and there was no evidence of long bone deformity. A lateral radiograph showed that the appearance of the spine had improved although there was still mild reduction in the vertebral body height in the thoracic vertebrae and L3. There was also spondylolysis at L5/S1 but no spondylolisthesis.

At age 2 ½ he was speaking words, but no sentences. He lacked approximately 5° knee extension on the right following the rodding. He also lacked end of range supination at the elbows bilaterally. He was switched to zoledronic acid with a dose of 0.025 mg/kg as a single infusion once every 6 months. This was due to the lower frequency of infusions as there were difficulties with cannulation; at 4 years, this was switched again to oral risenedronate 35 mg once fortnightly.

At 4 years old, he had another DXA scan which showed L2–4 BMD to be 0.743 g/cm² (increased from 0.663 g/cm² 10 months previously) and TBLH BMD to be 0.592 g/cm² including a metal rod in the right femur (increased from 0.561 g/cm²). He had undergone removal of fixed rods and telescopic rodding of the right femur 7 months previously. Lateral spine radiography showed no definite loss of height of any vertebrae and lateral skull radiography showed no basilar invagination. It was soon noted that his bone density was relatively high for his age and the surgeons had commented that his bones were particularly dense. He also had delayed healing of the osteotomy and it was also noted that the patient's father had had problems with delayed healing and it had taken 14 surgeries to get his right femur to heal properly. It was confirmed that patient 4 had a paternally inherited *COL1A1* C-propeptide variant.

After a repeat DXA scan showed further increase in BMD, the decision was made to discontinue the risenedronate. He had had no further fractures having been off risenedronate for 3 months following surgery for femoral de-rotation on the right side with plate fixation, and the surgeons again commented that his bone was difficult to drill through due to hardness. It was decided to consider reintroduction of bisphosphonates approaching growth spurt given the family history of femoral

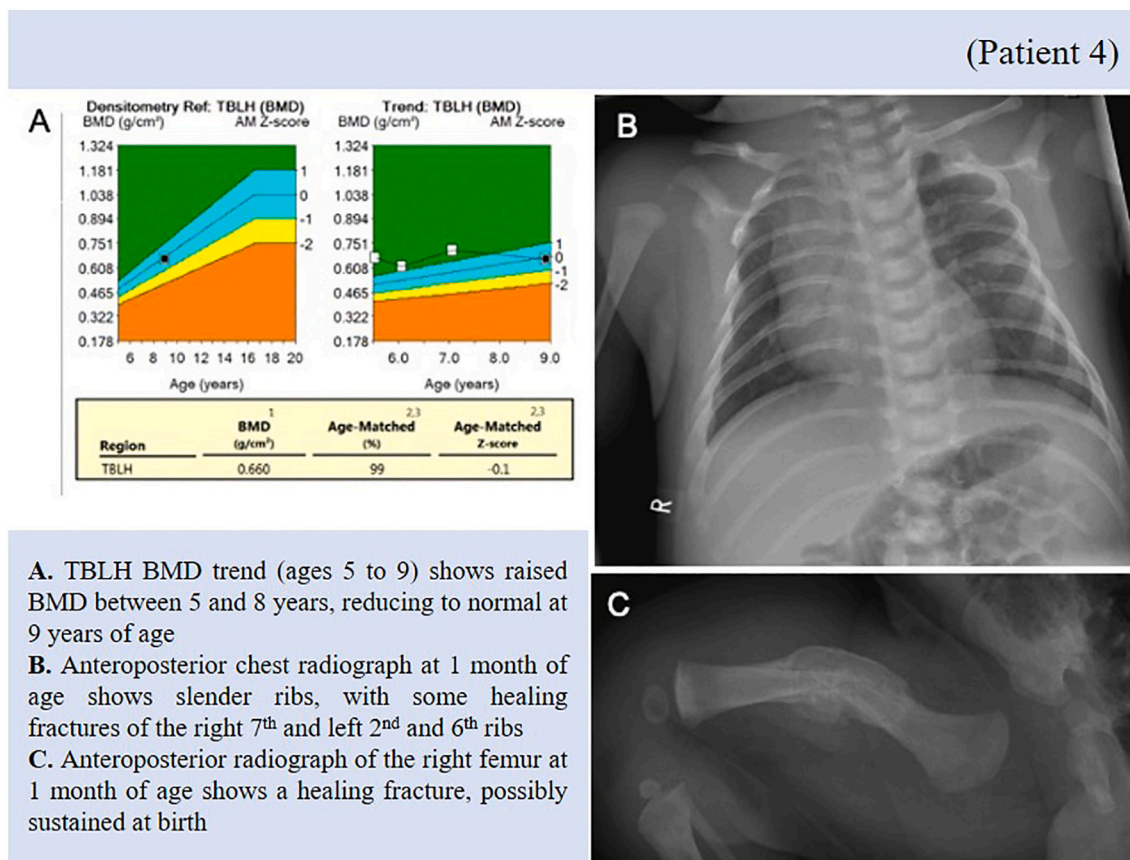


Fig. 4. A. TBLH BMD trend (ages 5 to 9) shows raised BMD between 5 and 8 years, reducing to normal at 9 years of age. B. Anteroposterior chest radiograph at 1 month of age shows slender ribs, with some healing fractures of the right 7th and left 2nd and 6th ribs. C. Anteroposterior radiograph of the right femur at 1 month of age shows a healing fracture, possibly sustained at birth.

fractures in teenage years. At 5 years, his DXA scan showed another increase in BMD with L2–4 at 0.792 g/cm² and TBLH at 0.674 g/cm².

By 5 ½ years old, Patient 4 had had a stress fracture in the right subtrochanteric area with malunion and de-rotation osteotomy subsequently. Medial cortical healing was almost complete after removal of the de-rotation plate, but there was still a lateral cortical defect. He was not in any pain but was walking with a short leg gait with segment deficient being on the contralateral side. On examination, he was short in the left tibia by an estimated 15 mm which accounted for his limp when walking and his right knee had a small, fixed flexion contracture of about 10°. His hip exam was normal and he was able to play football with his father and participate in school PE. His DXA scan showed a slight decrease in BMD; L2–4 was 0.777 g/cm² (Z score +1.8) and TBLH was 0.662 g/cm² (Z score +3.1). VFA showed preservation of vertebral height.

Patient 4 continued to have repeat DXA scans (Fig. 4): At 6 years old the L2–4 and TBLH Z scores were +1.9 and +1.5 and at 7 years old they were +1.9 and +2. He had no further fractures and continued to show L4 and L5 Grade I spondylolysis. There was good disc height, slip angle was acceptable, sacral promontory was reasonable and it was decided to observe for symptoms and risk of slip progression. 1 month later, he underwent revision rodding of the right proximal femur with the plan being to start graded weight bearing 2 months later.

At 8 years and 3 months, he had a recent re-fracture of his right femur with rod *in situ*. He tripped and fell at school onto his right knee and bent the intramedullary rod. He underwent right revision rodding of the femur with corrective osteotomy and plating a few months later and was mobilising with crutches 6 weeks later. By 8 years and 11 months, he was healing well, walking inside the house without support; using crutches for short distances outside the house and his wheelchair for

longer distances. His most recent DXA scan showed L2–4 +0.6 (previously +1.9), TBLH +2.0 (previously –0.1). VFA showed persistent loss of height in at least two thoracic and two lumbar vertebrae but there was probable minor improvement in one thoracic vertebra. He had occasional discomfort in his back after prolonged sitting where leaning forward and he had a recent fracture to his toe, but on clinical examination his spine was straight. The decision was made to restart the risedronate at a dose of 35 mg once weekly due to the persistent loss of vertebral height and the fact that the BMD was now decreasing.

2.7.5. Patient 5

Patient 5 is a 10 year old male born following an uncomplicated pregnancy to a 19 year old mother with known OI with an identified *COL1A1* variant. She contacted the genetics service at 6–7 weeks pregnant, aware that there would be a 50% chance of passing on the condition and unsure of whether or not to continue with the pregnancy. She was offered a test to find out whether the baby had OI but declined, and decided to continue with the pregnancy.

Patient 5 was born *via* c-section at 38 weeks. He was healthy at birth and weighed 3400 g. He was active and alert with no external stigmata of OI. Examination at 1 month showed that he had blue sclerae and there was laxity of the small joints, but rest of his examination was normal. 2 months later, he had normal range of active movements although he had mild head lag in the sitting position. His weight was tracking around the 25th centile. By 10 months, he was meeting most developmental milestones. He had some reluctance to crawl but this was put down to spending so much time in a walker. He had had no fractures or dislocations. There was no deformity of long bones, his spine was straight, and a previous lateral spine film showed no crush fractures. He had some flattening at the back of his head and hyperlaxity of joints, especially the

wrist, ankle and hips, but had reasonable trunk control. He still had blue sclerae and it was thought that he most likely had inherited the familial OI variant.

At 16 months, he had a DXA of his Lumbar Spine (LS) which showed a BMD of 0.334 g/cm². He was also noted to have a degree of pronation in ankles and his joints were hypermobile. He was walking by 21 months. He sustained his first fracture at 2 years and 2 months following an accident while playing with his parents. He fractured his left femur and in a cast for 5 weeks (Fig. 5). Soon after, he sustained a possible hairline fracture of the 2nd metatarsal. About 2 years later, he sustained a metadiaphyseal fracture of his 5th right metatarsal. He sustained no other fractures until he was 5 years and 8 months, when he fractured his left tibia.

At 2 ½ years old, he was seen to have an increase in BMD of lumbar spine and a deterioration in vertebral morphology, with at least 3 vertebrae having lost some height. He was started on pamidronate a few months later at a dose of 1 mg/kg on each of 3 successive days.

By 3 ½ years old, he was noted to have very pronated feet and hyperextension of the knees (20°), with poor lower limb alignment. His most recent DXA scan showed LS BMD to be 0.531 g/cm² (increased from 0.461 g/cm² 6 months previously) and TBLH BMD to be 0.432 g/cm² (increased from 0.392 g/cm²). Lateral skull radiography showed no basilar invagination. Possible fusion of the posterior elements of C2 and C3 was noted as an incidental finding. Lateral spine radiography showed anterior loss of height in several thoracic vertebrae. He was also complaining of back pain in the weeks leading up to his pamidronate infusion.

At 4 years old, he was able to cycle his bike independently with stabilisers; however, he had some degree of limitation of activity compared to his peers and his general wellbeing had been impacted by frequent tonsillitis and ear infections. He also had bilateral foot calcaneovalgus deformity and was wearing orthotics regularly.

He started mainstream primary school at age 5. VFA showed a continuing decrease in anterior height of 3 or 4 thoracic vertebrae. His lumbar spine z score was +0.9 and his total body less head z score was +2.1. 6 months later, following his 12th cycle of pamidronate, a repeat DXA scan showed his lumbar spine z score had increased to +1.3, but his TBLH had decreased to +1.6. VFA showed a decrease in anterior height

of vertebrae at T4, T7 and T10 without any evidence of a slip in the lumbo-sacral region and it was thought that the vertebral shape was slowly improving.

At 5 years 8 months, he suffered a left tibial fracture, for which he had a closed reduction and insertion of telescopic rods. 2 months later, he had a unicortical re-fracture of the osteotomy site left middle 1/3rd tibia with no bend in the rod.

At 6 years and 2 months, he sustained a mid-shaft fracture to his right tibia after tripping over a carpet edge at school. He underwent telescopic rodding of the right tibia.

He had trialled switching to zoledronic acid, but this had less symptomatic benefit, so he reverted back to pamidronate. His DXA scans continued to show slightly fluctuating z scores and pamidronate was decreased to 1.5 mg/kg at 7 years 3 months. His z scores for L2–4 at 6 ½ years, 7 years, 7 ½ years and 8 years were +1.1, +1.7, +1.5, and +1.5 respectively and scores for TBLH were +2.5, +2.7, +2.7, and +2.2. Over this time, lateral spinal radiography continued to show minimal loss of height in T5–T7 and L3, although there had been slight improvement in the height of T4.

At 8 years and 1 month, he underwent a right tibia rod exchange as it was failing to telescope. 1 month later, he had a left mid shaft femoral fracture and was treated with an intramedullary rod. At 8 years 7 months, Patient 5 was found to be heterozygous for c.3584del pathogenic variant in *COL1A1*, like his mother. His younger brother was also tested for the variant, but was found to be negative. He continued on the pamidronate until he was 10, when he was switched to oral risedronate at a dose of 35 mg once fortnightly. This was due to need to reduce unnecessary visits to the hospital.

By 10 years and 3 months, his rods were no longer telescoping. He was using insoles for fallen arches and had a slight limb length discrepancy of the right leg being 1.5 cm shorter than the left. It was also noted that he had subtle genu valgum, like his mother and had lost some internal rotation of his left hip which was noticeable on walking but was not causing him any pain. His most recent DXA scans showed z scores for the Lumbar Spine of +2.0 (from +1.6) and total body less head of +2.3 (from +1.8). VFA showed mild loss of height and his spine was straight.

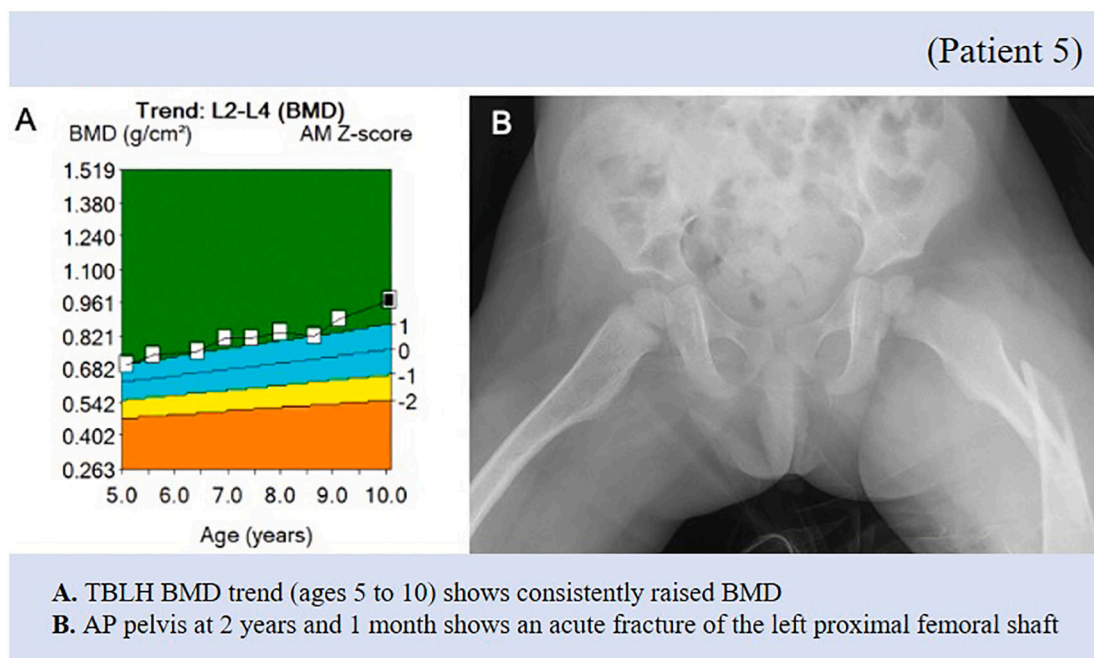


Fig. 5. A. TBLH BMD trend (ages 5 to 10) shows consistently raised BMD.

B. AP pelvis at 2 years and 1 month shows an acute fracture of the left proximal femoral shaft.

2.7.6. Patient 6

Patient 6 is the 30-year-old mother of Patient 5. At age 13, she was found to have a *COL1A1* variant along with a clinical diagnosis of OI. There is also a more significant family history of OI. It was understood that there was a history of fractures on her father's side involving her father, aunt and cousin, but there was limited information on this.

Unfortunately, there was not much information available on her early history and presentation of OI. She has had many fractures in her life and while her eldest son (Patient 5) was growing up, she frequently encountered problems regarding her ability to carry him and push his buggy due her own diagnosis.

At 10 months, it was noted that she had congenital musculoskeletal anomalies, but these were not otherwise specified. At 4 years and 5 months, she fractured her tibia and fibula, and 6 months later she fractured her radius and ulna. Since then, she has suffered multiple fractures to bones in her foot including recurrent fractures to her right and left 5th metatarsals.

She had a routine echocardiogram just before she turned 29 due to a perceived risk of valve and aortic root diseases associated with OI but this was normal, and she was scheduled for a repeat in 5 years-time. She was being administered pamidronate from age 10 to 18 and stopped

when she found out that she was pregnant. When she was 19 ½ years old her son (Patient 5) was born following an elective caesarean section. Her most recent fracture was 2 years previously to the 5th metatarsal. The most recent imaging of her lumbar spine (at 18 years and 10 months) showed no crush fracturing deformity, spondylosis or spondylolisthesis below T10. She had suffered with severe back pain for a long time and found that this was much worse following the lumbar puncture she had for the caesarean section.

Over the following years, she continued to have severe back pain requiring analgesia. At 20 years old, she was noted to have no spinal tenderness, but had exaggerated lordosis and the movement of her lumbar spine was limited. She had no reduction in the height of vertebrae and her BMD was stable (Fig. 6). At 21 years, her lumbar spine and total hip scores were 0.8 and 1.4, which had showed no significant change from the results 2 years previously. She had a long-standing problem of not consuming enough dairy in her diet and so was regularly taking calcium and vitamin D supplements since the birth of her first son.

She suffered another fracture to her left 5th metatarsal at age 22 after stumbling; she decided that she wanted to restart bisphosphonates and was started on zoledronate at 5 mg. This was not continued as it only

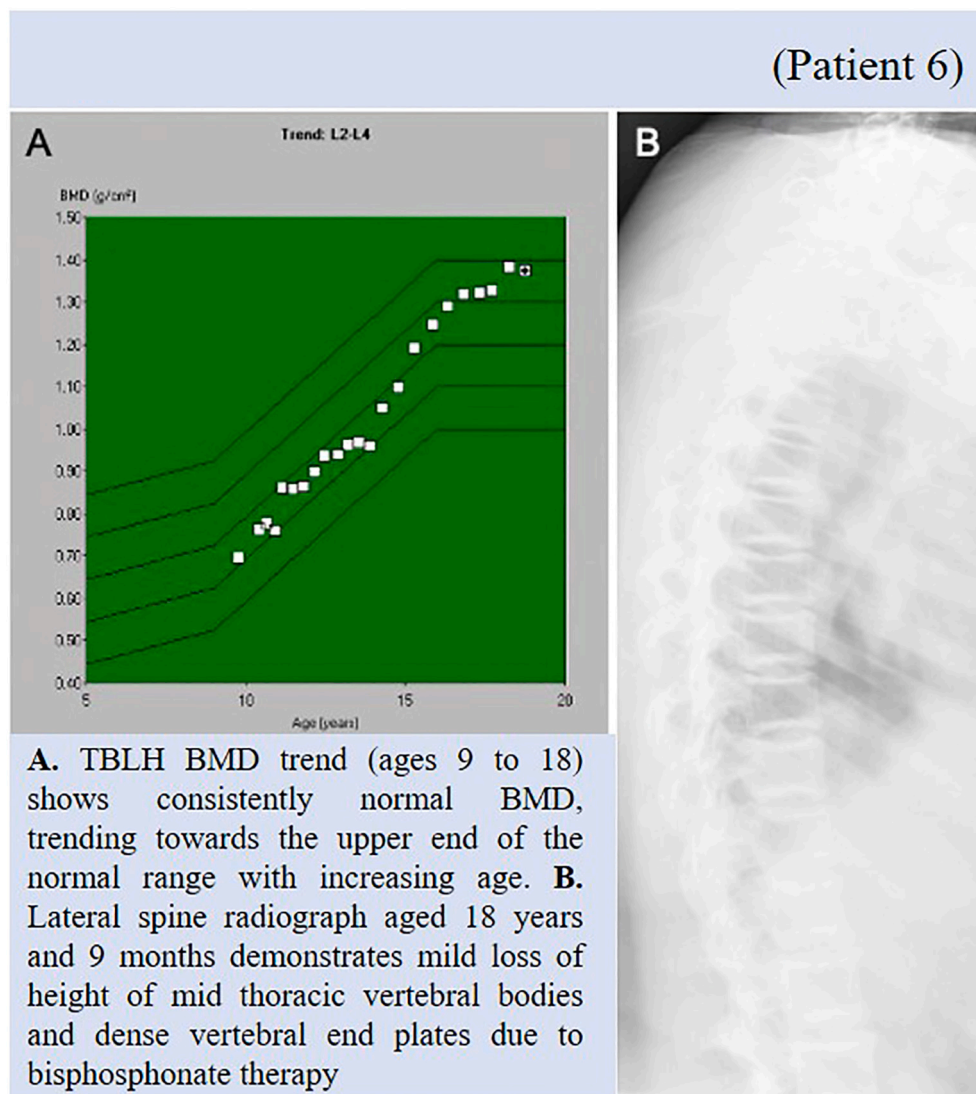


Fig. 6. A. TBLH BMD trend (ages 9 to 18) shows consistently normal BMD, trending towards the upper end of the normal range with increasing age. B. Lateral spine radiograph aged 18 years and 9 months demonstrates mild loss of height of mid thoracic vertebral bodies and dense vertebral end plates consistent with bisphosphonate therapy.

improved her symptoms for a few weeks. She later decided not to start on other bisphosphonates as was having problems finding a method of contraception that worked for her and did not want to risk getting pregnant while on bisphosphonates.

At 27 years of age, she gave birth to her second son following a caesarean section. He was well at birth with no signs of OI and was found to be negative for the familial variant for OI. In both cases, she found that her back pain increased following the pregnancy. 10 weeks after delivery, her lumbar spine and total hip z scores were 1.0 and 1.8 respectively, which showed no significant change from the results three years previously.

By age 30, she continued to have frequent generalised aches and pains (which was improving following regular physiotherapy exercises), as well as problems with her left knee when kneeling, and her left foot around the site of previous stress fractures. Her most recent lumbar spine and total hip scores were 0.8 and 1.7 respectively, which again showed no significant change from 18 months previously.

3. Results

3.1. Patient 1

Genetic testing identified Patient 1 to be homozygous for the c.355C>T missense variant, predicted to result in a p.Arg119Trp amino acid change in exon 3 of *BMP1*. Further testing showed that both her mother and father were heterozygous for the c.355C>T variant.

3.2. Patient 2

Genetic testing showed Patient 2 to be compound heterozygous for variants in *BMP1*. She had a c.1148G>A missense variant in exon 9 predicted to result in the p.Arg383Gln protein change and a c.1293C>G nonsense variant in exon 10 predicted to result in the replacement of the tyrosine at position 431 with a premature termination codon. These mutations had not previously been reported but other mutations in this gene were known to be associated with OI.

Subsequently, her parents were also tested for the variants. Her father was found to be heterozygous for the c.1148G>A variant and her mother was found to be a heterozygous for c.1293C>G variant.

3.3. Patient 3

Patient 3 was found to be heterozygous for a c.4160C>T variant in the C-propeptide region of *COL1A1* predicted to result in a p.Ala1387Val missense amino acid change. This variant had been previously reported in one family with a recurrence of type IIC OI although the functional effect was undetermined and *in silico* analysis did not support the pathogenicity. Further familial testing showed that this variant to be *de novo*.

3.4. Patient 4

Pre-symptomatic testing of the cord blood, showed Patient 4 to be heterozygous for the familial c.4343G>A, p.Gly1448Asp pathogenic missense variant in exon 51 of *COL1A1*.

3.5. Patient 5

Patient 5 was found to be heterozygous for a c.3584delG deletion variant, predicted to result in a p.Gly1195fs frameshift in *COL1A1*. This is the same variant found in his mother (Patient 6).

3.6. Patient 6

Patient 6 was found to be heterozygous for a c.3584delG deletion variant located in the C terminal telopeptide domain of *COL1A1*, not

previously reported in literature. It was predicted to generate a shift in the reading frame (resulting in a p.Gly1195fs) and produce premature termination codon 44 amino acids downstream. Similar variants have been associated with OI of variable phenotype.

4. Discussion

COL1A1 and *COL1A2* genes (located on chromosomes 17q21.33 and 7q21.3 respectively (*OMIM*)) encode for three peptide chains: two pro α 1 chains and one pro α 2 chain. Together, these make up the type I procollagen molecule, which is the precursor for type I collagen. Each of the chains has a central triple helix and they combine into a trimeric structure (Cundy et al., 2018). The amino (N) and carboxyl (C) terminal propeptides are then cleaved and the collagen molecules are arranged into fibrils (Sangsin et al., 2017). The *BMP1* gene (found on chromosome 8p21.3) encodes BMP1 and mTLD which are two of the four proteins involved in the cleavage of C-propeptide from procollagen (the others are mTLL1 and mTLL2) of which, BMP1 was found to have the greatest cleavage activity (Sangsin et al., 2017). In addition, it also affects regulation of TGF β and activins which impact osteoclastogenesis. Inactivating variants in *BMP1* have been shown to decrease the levels of both BMP1 and mTLD and therefore impairing the cleavage of the C-propeptide (Cundy et al., 2018).

It has been explained that the type I procollagen C-propeptides are involved in both the intracellular procollagen assembly and the extracellular assembly of collagen fibrils (Symoens et al., 2014). It is needed for the regulation of bone mineralisation (Syx et al., 2015) and is involved in regulating the expression of collagen genes via negative feedback (Barnes et al., 2019). One study found that where there was C-propeptide retention, the structure of type I collagen fibrils was less organized (Syx et al., 2015). The C-propeptide domains are also important in the selection and association of pro α chains (Symoens et al., 2014).

Variants in the collagen I genes (*COL1A1* and *COL1A2*) are the most common in OI (Marshall et al., 2016). With the most common variant being glycine substitutions in the helical domain (Marshall et al., 2016). This variant is known to cause problems with the structure of collagen and has been associated with the more severe forms of OI. The other main variants are nonsense mutation which causes there to be less normal collagen (Hoyer-Kuhn et al., 2015). C-propeptide variants account for only ~5% (as of 2014) of the variants that have been identified in type I collagen (Symoens et al., 2014).

Variants in the *COL1A1/A2* genes have been shown to lead to varying phenotypes. These have been classified into OI types I–IV and these vary from lethal in the neonatal period (type II) to more mild forms (types I and IV) (Marini and Dang Do, 2020). The phenotypes of patients with a C-propeptide variant in these genes can also be very varied, which is shown in the patient descriptions of this cohort. This is also supported in the literature, with examples of mild to lethal types of OI in patients with heterozygous variants in the C-propeptide regions (Lindahl et al., 2011). There are also examples of patients with variants in the type I procollagen C-propeptide domain or in the C-propeptide cleavage sites of the pro α 1 and α 2 chains who have high bone mass (Syx et al., 2015).

The cohort reported here includes descriptions of 4 patients from 3 different families with C-propeptide variants in the *COL1A1* and 2 patients with *BMP1* variants. Table 1 describes the clinical phenotype of *BMP1* patients in this cohort in comparison to published literature. Table 2 describes the cohort of patients here with *COL1A1* variants in comparison to previously published literature on C-propeptide variants in association with high bone mass while Table 3 gives an overview of their genotype and variant classification based on ACMG criteria (Richards et al., 2015; ACGS Best Practice Guidelines for variant classification 2020 <https://www.acgs.uk.com/quality/best-practice-guidelines/>).

The severity of their phenotypes was very different from case to case. Patient 3, who was *de novo* heterozygous for variant in *COL1A1*, had a

Table 1
Clinical phenotype in patients with *BMP1* variants and comparison to published literature.

Patient	1	2	7	8	9	10	11	12	13
Family	1	2	6	7	7	8	9	10	10
Source	This cohort		(Sangsin et al., 2017)	(Pollitt et al., 2016)	(Syx et al., 2015)				
Age (at time of publication)	19	12	6	14	5.2	43	31	47	45
Sex	F	F	M	M	F	M	M	M	M
Ethnicity	Polish	Northern European	Thai	Asian	Asian	Caucasian	Portuguese	Scottish	Scottish
Consanguinity	No	No	No	Yes	Yes	No	No	No	No
Family history	None	Parents have hypermobility	no	Sister (patient C)	Brother (patient B)	no	Younger brother	Brother (patient G)	Brother (patient F)
Pregnancy	Uncomplicated	IVF Uncomplicated	Data unavailable	Data unavailable	Data unavailable	Data unavailable	Data unavailable	Data unavailable	Data unavailable
Gestation	Term	39 weeks	Term	37 weeks	36 weeks	Full term	Data unavailable	Data unavailable	Data unavailable
Birth weight	2400 g	2900 g	3600 g	2500 g	2420 g	3650 g	Data unavailable	Data unavailable	Data unavailable
1st fracture	14 months Right lower leg	3rd birthday Femur	3 months Right arm	12 months Right wrist	7 months Bilateral ulnar and radius	8 months Femur	Birth	Long bone fractures shortly after walking	Long bone fractures shortly after walking
Bisphosphonates started (age)	7 years	4 years	8 months	~6.5 years	3 years	None	Not reported	Not reported	Not reported
Genotype	c.355C>T	c.1148G>A c.1293C>G	c.796_797delTT c.2108-2A>G	c.2188dupC	c.2188dupC	c.925delG c.1492G>A	c.34G>C c.1839delC	c.34G>C c.2188dupC	c.34G>C c.2188dupC
Protein Change	p.Arg119Trp	p.Arg383Gln & p.Tyr431*	p.Phe266Argfs*25	p.Gln730Profs*294	p.Gln730Profs*294	p.Asp309Thrfs*54 p.Gly498Arg	p.Gly12Arg p.Asn614Thrfs*188	p.Gly12Arg p.Gln730Profs*294	p.Gly12Arg p.Gln730Profs*294
Homozygous/ compound heterozygous	Homozygous	Compound heterozygous	Compound heterozygous	Homozygous	Homozygous	Compound heterozygous	Compound heterozygous	Compound heterozygous	Compound heterozygous
Cognitive development	Normal	Normal	Normal	Not reported	Normal	Normal	Not reported	Not reported	Not reported
Motor development	Normal	Delayed – not walking at 21 months	Early development was normal	Not reported	Normal	Delayed	Not reported	Not reported	Not reported
Motor skills	Mainly using wheelchair, but can walk for short distances	Able to walk independently	Able to walk until 6 years	Not reported	Not reported	Never able to walk.	Dependent on wheelchair for all mobility	Wheelchair dependent at around 14y	Able to walk very short distances supported
Age matched DXA Z score (pre-bisphosphonates)	None measured	0.728 g/cm ² (aged 4 years, no Z score available)	Not reported	-0.9 (aged 6 years)	Not reported	Not reported	Not reported	Not reported	Not reported
Age matched DXA Z score (post-bisphosphonates)	+4.3 (aged 13 years 9 months)	+4.02 (aged 7 years 9 months)	Not reported	0.3 (aged 14 years)	0.95 (BMAD aged 2 years)	No bisphosphonates	Not reported	Not reported	Not reported
Sclerae	Blue then white	Light blue then white	White	White	Grey	Blue then white	White	White	White
Teeth	No DI	Dental crowding and slow tooth eruption. No DI	No DI	No DI but dental decay	No DI	Opalescent teeth	Translucent and fragile with brown discoloration	Not reported	Not reported
Hearing	Normal	Normal	Not reported	Normal	Normal	Normal	Normal	Normal	Normal
Vision	No problems	No problems	Not reported	Not reported	Not reported	Mild myopia	Not reported	Not reported	Not reported
Hypermobility	+	+++	Not reported	Fingers	Fingers	Mild in fingers	No	Not reported	Not reported
Scoliosis	Concave to right due to leg length discrepancy – age 13 Lumbar lordosis	Requiring surgical correction at age 12	Not reported	Not reported	Not reported	Severe kyphoscoliosis	Mild kyphosis	Moderate	Very mild
Vertebrae	Minimal height loss in two thoracic vertebrae		Not reported	Compression fracture	No vertebral compression fractures	Multiple vertebral fractures	Multiple vertebral fractures	Not reported	Not reported

Patient	14	15	16	17	18	19	20	21	22	23	24	25
Family	11	12	13	14	14	15	15	16	17	18	19	20
Source	(Xu et al., 2019)	(Cho et al., 2015)	(Choksi et al., 2021)	(Asharani et al., 2012)		(Martínez-Glez et al., 2012)		(Valencia et al., 2014)	(Fahiminiya et al., 2015)			
Age (at time of publication)	15		7	11	7	15	5	2.8	17.4	28.8	22.6	8.1
Sex	M	F	M	M	F	F	M	M	F	F	M	F
Ethnicity	Chinese	Korean	Hispanic	Turkish	Turkish	Egyptian	Egyptian	Pakistani	French Canadian	French Canadian	French Canadian	French Canadian
Consanguinity	No	No	No	Yes	Yes	Yes	Yes	Yes	No	No	No	No
Family history	No	No	No	Sister (Patient 18)	Brother (Patient 17)	Brother (Patient 20)	Sister (Patient 19)	No	No	No	No	No
Pregnancy	Not reported	Not reported	Uncomplicated	Not reported	Not reported	Not reported	Femoral bowing detected intrauterine	Unremarkable	Not reported	Not reported	Not reported	Not reported
Gestation	Full term	NVD at 37 weeks	Full term	Not reported	Not reported	NVD full term	Not reported	Not reported	Not reported	Not reported	Not reported	NVD at term
Birth weight	3300 g	3400 g	Not reported	Not reported	Not reported	Not reported	Not reported	2935 g	Not reported	Not reported	Not reported	3460 g
1st fracture	22 months left femur	Immediately after birth left humerus	2.5 years right tibia	23 months	14 months	Immediately after birth left tibia	At birth, both femora	4 months	4 years	0.8 years	2.5 years	Birth
Bisphosphonates started (age)	Treated for 12 months. Not reported when.	None	None	5.4 years	2.8 years	Not reported	Not reported	2 years	None	None	9.6 years	4 years
Genotype	c.1324G>T c.148+1G>A p.Asp442Tyr	c.808A>G c.1297G>T p.Met270Val p.Ala433Ser	c.C505T	c.34G>C	c.34G>C	c.747C>G	c.747C>G	c.34C>G	c.*241T>C	c.*241T>C	c.*241T>C	c.*241T>C c.2107G>C p. Val643Lysfs*99
Protein change			p.Arg169Cys	p.Gly12Arg	p.Gly12Arg	p.Phe249Leu	p.Phe249Leu	p.Gly12Arg				
Homo/heterozygous	Compound heterozygous	Compound heterozygous	Homozygous	Homozygous	Homozygous	Homozygous	Homozygous	Homozygous	Homozygous	Homozygous	Homozygous	Compound Heterozygous
Cognitive development	Not reported	Normal	Mild speech delay	Normal intelligence	Normal intelligence	Normal	Normal	Normal	Not reported	Not reported	Not reported	Normal
Motor development	Sit at 7 months Walk at 15 months	Delayed. Not able to sit unsupported at 12 months	Moderately delayed	Not reported	Not reported	Delayed	Delayed	Delayed	Not reported	Not reported	Not reported	Delayed. Walking at 20 months
Motor skills	Not reported	Not reported	Not reported	Not reported	Not reported	Not able to stand unsupported	Not able to stand unsupported	Not reported	Not reported	Not reported	Not reported	Not reported
Age matched DXA Z score (pre-bisphosphonates)	+2.1 (aged 15.7 years) +4.6 (aged 16.7 years) +1.4 (aged 18 years)	Not reported	Total hip 1.76 (aged 7 years)	High above normal	High above normal	-2.13 (aged 15 years)	-1.3 (aged 5 years)	Normal	-0.4 (aged 11.5 years) 1.0 (aged 17.4 years)	1.7 (aged 5.7 years) 4.2 (aged 28.8 years)	0.0 (aged 9.4 years)	-3.0 (aged 3.7 years)
Age matched DXA Z score (post-bisphosphonates)	Increased by 27% following bisphosphonate treatment	No bisphosphonates	No bisphosphonates	Increased further	Increased further				No bisphosphonates	No bisphosphonates	1.1 (aged 22.6 years)	0.1 (aged 8.1 years)
Sclerae	White	White	Blue-grey	White	White	Blue	Blue	White	White	White	White	White
Teeth	No DI	No DI	No DI	No DI	No DI	No DI	No DI	No DI	No DI	No DI	No DI	No DI
Hearing	Normal	Not reported	Not reported	Normal	Normal	Not reported	Not reported	Not reported	Not reported	Not reported	Not reported	Not reported
Vision	Not reported	Not reported	Not reported	Not reported	Not reported	Not reported	Not reported	Not reported	Not reported	Not reported	Not reported	Not reported
Hypermobility	Hyperlaxity	Elbow, wrist, interphalangeal joints	No	No	No	Elbow, wrist, interphalangeal joints	Yes	Slightly hypermobile	Not reported	Not reported	Not reported	Joint hyperlaxity

(continued on next page)

Table 1 (continued)

Patient	14	15	16	17	18	19	20	21	22	23	24	25
Family	11	12	13	14	14	15	15	16	17	18	19	20
Scoliosis	Mild	Mild	Not reported	Not reported	Not reported	S-curve scoliosis of thoracic and lumbar spine	Kyphoscoliosis	Not reported	Mild curvature of spine	Not reported	Not reported	Not reported
Vertebrae	Not reported	Not reported	Vertebral compression fractures	Vertebral compression fractures	Vertebral compression fractures	Not reported	Not reported	Not reported	Not reported	Not reported	Vertebral compression fractures	Grades 2-3 vertebral compression fractures in thoracic spine

very severe form of the disease, initially being diagnosed with the lethal type antenatally. He has continued to have fractures and problems with deformities throughout his life. He was also the only patient from this cohort to have a significantly low BMD. In contrast to this, patients 5 and 6 (son and mother respectively) had much milder forms of the condition. Bone biopsies were taken from patient 3 (Pepe et al., 2018) and nano-indentation was performed. The study was limited as the exact location that the specimen was extracted from was not comparable to published normative paediatric literature. The results showed that the elastic modulus and hardness of the bone specimen were lower than those in healthy adult bone and the elastic modulus was lower than results from other paediatric patients with type III and type I OI. The results also showed that the mechanical properties were very heterogeneous across different regions of the specimen, and one side of the bone specimen showed a larger proportion of denser cortical bone compared to the other side. Further bone biopsy samples from this group were difficult to obtain, limiting the possibility of generalising the findings. Nevertheless, future analysis on a larger sample size should shed more light into bone material properties in this group of patients with OI. In addition, evidence of enhanced osteoclastic activity through analyses of urinary collagen derived crosslinks and studying osteoclastic activity in bone fragments from surgical bone tissue may provide further data on those patients that might benefit from bisphosphonate therapy and those that may become hypermineralised.

Patients 4 and 5 were both found to have significantly raised BMD. In patient 4 this was significant enough to be remarked upon by the operating surgeons who were finding that the bones were particularly difficult to drill in to due to their high density. While patients 5 and 6 shared the same familial variant, Patient 6 did not have a high BMD, instead it was consistently normal.

The phenotypes of patients with mutations in the *BMP1* has been described as high mineral bone density associated bone fragility (Pollitt et al., 2016), but the phenotypes do differ in the literature. It has been noted that some patients with milder phenotypes had a homozygous variant (c.*241T>C) which only affected the transcription of the *BMP1* protein, leaving the mTLN protein functional. There were also milder phenotypes demonstrated in patients with the p.Gly12Arg signal peptide variants and 2, out of the 3 patients with this variant, had high bone mass. This was thought to be due to a higher mineral incorporation in the bone matrix following a delay in bone mineralisation (Syx et al., 2015). Biopsies that were carried out from patients with *BMP1* variants and high BMD demonstrated that there was a simultaneous excess of osteoid (hyperosteoidosis) and increased mineralisation (hypermineralisation). This was the same as was seen in those with variants in the C-propeptide cleavage site (Cundy et al., 2018).

This cohort of patients included 2 patients with variants in the *BMP1* gene. Despite differing initial presentations, where patient 2 had a fairly complicated path to diagnosis, they both did have many similarities. They both began getting fractures once they were independently mobilising, although in patient 2 this did not occur until later largely due to problems with hip dislocation and hypermobility. They also both began with light blue sclerae which became white with age and had notable scoliosis when older. Both had increased BMD; however, this was a more significant finding in Patient 2 who was investigated for osteopetrosis early on in her presentation.

Bisphosphonates are the main pharmacological treatment used in children with OI. They work by inhibiting the activity of osteoclasts and inducing apoptosis. They have been shown to increase bone mass and improve the internal structure of bone tissue, thereby helping to reduce the incidence of fractures (Rossi et al., 2019). There is some suggestion of delayed healing following surgery in patients having bisphosphonate therapy (Marom et al., 2020). Studies have shown that along with reducing the rate of fractures, it increases the bone mineral density (Bradbury et al., 2012); but does not alter bone mineralisation density distribution *i.e.* tissue bone density (Boyde et al., 1999).

All the patients in this cohort were started on intravenous

Table 2
Clinical phenotype in patients with *COL1A1/A2* C-propeptide variants and comparison to published literature.

Patient	3	4	5	6	26	27	28	29	30	31	32
Family	3	4	5	5	21	22	23	24	24	25	25
Source	This cohort				(Lindahl et al., 2011)		(McInerney- Leo et al., 2015)	(Rolvien et al., 2018)		(Le Quesne Stabej et al., 2017)	
Age (at time of publication)	12	9	10	30	13.5	14	Not reported	80	56	Not reported	Not reported
Sex	M	M	M	F	F	M	F	F	F	F	M
Ethnicity	Caucasian	Caucasian	Caucasian	Caucasian	Swedish	Caucasian American	Not reported	Not reported	Not reported	Pakistani	Pakistani
Consanguinity	No	No	No	No	Not reported	No	Not reported	Not reported	Not reported	Yes	Yes
Family history	History of #s in half sister	Paternal side	Mother (6)	Son (5) Possibly on paternal side	Not reported	Not reported	Son	Daughter (30)	Mother (29)	Brother (32) Paternal mosaicism	Sister (31) Paternal mosaicism
Pregnancy	Diagnosed antenatally, twin pregnancy	Uncomplicated	Uncomplicated	Data unavailable	Uncomplicated	Uncomplicated	Not reported	Not reported	Not reported	Not reported	Not reported
Gestation	37 weeks	40 + 4 weeks	38 weeks	Data unavailable	Full term NVD	Full term NVD	Not reported	Not reported	Not reported	Not reported	Not reported
Birth weight	2440 g	3855 g	3400 g	Data unavailable	2950 g	3690 g	Not reported	Not reported	Not reported	Not reported	Not reported
1st fracture	<i>In utero</i> /birth	3 days	2 years 2 months Left femur	Data unavailable	3.5 years right tibia and fibula	2 years	Early childhood	Early childhood	Early childhood	23 months 4th and 5th proximal phalanges	Perinatal right humerus
Bisphosphonates started (age)	1 week	6 weeks–5 years Restarted at 8 years 11 months	2.5–3 years	10–18 years	None	6 years	Not reported	Stopped following development of osteonecrosis of the jaw	Not reported	Not reported	Not reported
Gene	<i>COL1A1</i>	<i>COL1A1</i>	<i>COL1A1</i>	<i>COL1A1</i>	<i>COL1A1</i>	<i>COL1A2</i>	<i>COL1A1</i>	<i>COL1A2</i>	<i>COL1A2</i>	<i>COL1A1</i>	<i>COL1A1</i>
Genotype	c.4160C>T	c.4343G>A	c.3584delG	c.3584delG	c.3655G>A	c.3355G>A	c.G3652A	c.3359A>G	c.3359A>G	c.3652A>G	c.3652A>G
Protein change	p.Ala1387Val	p.Gly1448Asp	p.Gly1195fs	p.Gly1195fs	p.Asp1219Asn	p.Ala1119Thr	p.Ala1218Thr	p.Asp1120Gly	p.Asp1120Gly	p.Ala1218Thr	p.Ala1218Thr
Heterozygous	Heterozygous	Heterozygous	Heterozygous	Heterozygous	Heterozygous	Heterozygous	Heterozygous	Heterozygous	Heterozygous	Heterozygous	Heterozygous
Cognitive development	Normal	Normal	Normal	Data unavailable	Normal	Not reported	Not reported	Not reported	Not reported	Not reported	Not reported
Motor development	Very delayed	Age appropriate by 16 m	Delayed Walking at 21 m	Data unavailable	Normal	Not reported	Not reported	Not reported	Not reported	Not reported	Not reported
Motor skills	Using a walking frame at 9 ½ years	Mixture of no support, crutches and wheelchair	Walking independently with insoles	Walking independently	Not reported	Not reported	Not reported	Not reported	Not reported	Not reported	Not reported
Age match DXA Z-score (pre-bisphosphonates)	None measured	None measured	0.334 g/cm ² (aged 16 months, no Z score available)	Data unavailable	+3.9 (aged 12.5 years)	Not reported	7.7 (aged 28)	Not reported	Not reported	BMAD 0.45 (aged 5 years) 2.63 (aged 7 years)	Data not available
Age matched DXA Z score (post-bisphosphonates)	–2.1 (aged 10 years 3 months)	+0.6 (aged 8 years 11 months)	+2.0 (aged 10 years)	LS 0.8 (aged 30 years)	No bisphosphonates	0.00 (aged 12 years)	Not reported	Hip +3.9 Spine normal No significant change since on bisphosphonates	Hip +3.7 Spine normal No significant change since on bisphosphonates	Not reported	Not reported
Sclerae	Grey	Blue	Blue	Blue	White	Light grey	White	White	White	White	Not reported
Teeth	Dentinogenesis imperfecta	No DI	Normal	Data unavailable	No DI	No DI	No DI Delayed eruption	No DI	No DI	No DI but dental caries	Not reported
Hearing	Normal	Normal	Normal	Normal	Normal	Not reported	Normal	Normal	Normal	Non-syndromic sensorineural hearing loss	Normal
Vision		Normal	Normal	Normal	Not reported	Not reported		Not reported	Not reported	Not reported	Not reported

(continued on next page)

Table 2 (continued)

Patient	3	4	5	6	26	27	28	29	30	31	32
Family	3	4	5	5	21	22	23	24	24	25	25
Hypermobility	Glasses for astigmatism	Hypermobile	Hypermobile	Data unavailable	No	Generalised joint hyperextensibility	Marked joint laxity	Not reported	Not reported	Not reported	Not reported
Scoliosis	Some hypermobility affecting hands	Spine straight	Spine straight	Exaggerated lordosis	Straight spine	Mild S-curved scoliosis	Scoliosis	Not reported	Not reported	Not reported	Not reported
Vertebrae	Persistent flattening and loss of height of L2-4 at age 10y 3 m	Persistent loss of height in some thoracic and lumbar vertebrae	2 ½ years - 3 verts had lost some height, but was improving by age 5	Mild loss of height of mid-thoracic vertebrae and dense vertebral end plates	'Cone-in-bone' appearance in lumbar and cervical vertebrae	No vertebral compressions	Not reported	Vertebral fractures	Vertebral fractures	Pars defects of 5th lumbar vertebra with grade I spondylololsthesis	Not reported

Table 3

Genotype of reported patients in this cohort.

Patient	Variants	Classification	Variant interpretation
1	<i>BMP1</i> c.355C>T p. (Arg119Trp)	Likely pathogenic	PM2, PM3, PP4_mod, BP4 = Class 4.
2	<i>BMP1</i> c.1148G>A p. (Arg383Gln)	Likely pathogenic	PM2, PM3, PP4_mod = Class 4.
	c.1293C>G p. (Tyr431 ^{*)})	Pathogenic	PM2, PVS1 = Class 5
3	<i>COL1A1</i> c.4160C>T p. (Ala1387Val)	Likely pathogenic	PM2, PP3, PP2, PS2 = Class 4.
4	<i>COL1A1</i> c.4343G>A p.(Gly1448Asp)	Likely pathogenic	PM2, PM5_sup, PP3, PP2, PP1_str = Class 4
5	<i>COL1A1</i> c.3584del p. (Gly1195fs)	Pathogenic	PM2, PVS1 = Class 5
6	<i>COL1A1</i> c.3584del p. (Gly1195fs)	Pathogenic	PM2, PVS1 = Class 5

ACMG criterion applied: PS2: *De novo* (both maternity and paternity confirmed) in a patient with the disease and no family history, used at strong level; PVS1: null variant (nonsense, frameshift, canonical ±1 or 2 splice sites, initiation codon, single or multiexon deletion) in a gene where LOF is a known mechanism of disease; PM1: Located in a critical functional domain without benign variation, used at moderate level; PM2: Absent from controls in gnomAD database; PM3: Detected *in trans* with a pathogenic variant; PP3: Multiple lines of computational evidence support a deleterious effect on the gene or gene product, used at supporting level; PP4: Highly specific for a single genetic aetiology; PM4-M: Protein length changes as a result of in-frame deletions/insertions in a non-repeat region or stop-loss variants, used at moderate level; BP4: Multiple lines of computational evidence suggest no impact on gene or gene product, used at supporting level.

^a No corresponds to patient number.

bisphosphonate treatment, all started on pamidronate and most showed an increase in BMD following this. It is expected that there would be some increase with treatment (Bradbury et al., 2012) and patient 6 showed dense vertebral end plates, consistent with bisphosphonate use. However, in the cohort described above patient 2 increased much more significantly following the start of bisphosphonate treatment compared to the others. In this cohort, it was often found that the treatment was helping with back pain and multiple patients noticed increased discomfort in the period leading up to the next treatment session. Most of the patients appeared to have a reduced rate of fractures following the treatment, but it is not clear whether treatment actually reduced fracture risk, or whether fractures just decreased with age. Many of the cohort had their dose reduced or stopped altogether as their BMD continued to increase. Others were stopped when, after a period of having to stop them for surgical/pregnancy related reasons, it was noticed that they had not had any increase in fractures.

5. Conclusions

This project aimed to establish whether there was a common phenotype in OI patients with *BMP1* or C-propeptide variants, particularly in regards to a high bone mass presentation in order to aid decision making when considering treatment in this cohort of patients.

This cohort shows that 2/2 *BMP1* patients and 2/4 C-propeptide patients have a high bone mass phenotype; however, it remains unclear why some patients do not have high bone mass and why the phenotypes can range so greatly.

We show that some patients with these variants have a significant increase in BMD following bisphosphonate treatment that often exceed the upper limit of the normal range. Further work is required in a larger cohort of patients to establish whether this increase would have occurred due to the clinical presentation with high bone mass

phenotype, regardless of bisphosphonate treatment or whether these genotypes give the patients an increased susceptibility and elevated sensitisation to treatment with bisphosphonates and if this may be agent-specific. A more systematic phenotyping of this group of patients from early clinical presentation with close monitoring of response to treatment is required to draw further conclusions regarding timing of intervention and whether alternate modalities of emerging treatment options for OI needs to be considered in this cohort.

CRedit authorship contribution statement

EC collected patient data and collated all genetic and radiology information; MB supervised data collection and write-up; all authors contributed to patient data collection and approved manuscript.

Declaration of competing interest

The authors declare that they have no known competing financial interests or personal relationships that could have appeared to influence the work reported in this paper.

Acknowledgements

We would like to thank the families for consenting to publication of their details; Newlife Foundation for Disabled Children Grant Reference: SG/17-18/01 for their generous funding to this study.

Statement

This study has been approved by the South Yorkshire Research Ethics Committee (REC reference: 249448) and appropriate institutional boards and the research has been performed in accordance with the 1964 Helsinki Declaration. All authors contributed to this manuscript.

References

- Albert, C., Jameson, J., Toth, J.M., Smith, P., Harris, G., 2013. Bone properties by nanoindentation in mild and severe osteogenesis imperfecta. *Clin. Biomech.* 28, 110–116.
- Asharani, P.V., Keupp, K., Semler, O., Wang, W., Li, Y., Thiele, H., Yigit, G., Pohl, E., Becker, J., Frommolt, P., Sonntag, C., Altmüller, J., Zimmermann, K., Greenspan, D. S., Akarsu, N.A., Netzer, C., Schönau, E., Wirth, R., Hammerschmidt, M., Carney, T. J., 2012. Attenuated BMP1 function compromises osteogenesis, leading to bone fragility in humans and Zebrafish. *Am. J. Hum. Genet.* 90 (4), 661–674. <https://doi.org/10.1016/j.ajhg.2012.02.026>.
- Barnes, A.M., Ashok, A., Makareeva, E.N., Brusel, M., Wayne, A., Weis, M., Moali, J.C., Bettler, E., Eyre, D.R., John, P., Leikin, S., Hulmes, D.J.S., Kessler, E., Marini, J.C., Matrix, E., Section, G., Genomics, M., Branch, M.G., Unit, T.E., Science, C., 2019. COL1A1 C-propeptide mutations cause ER mislocalization of procollagen and impair C-terminal procollagen processing. *Biochim. Biophys. Acta Mol. Basis Dis.* 1865 (9), 2210–2223. <https://doi.org/10.1016/j.bbdis.2019.04.018>.
- Boyd, A., Travers, R., Glorieux, F.H., Jones, S.J., 1999. The mineralization density of iliac crest bone from children with osteogenesis imperfecta. *Calcif. Tissue Int.* 64 (3), 185–190. <https://doi.org/10.1007/s002239900600>.
- Bradbury, L.A., Barlow, S., Geoghegan, F., Hannon, R.A., Stuckey, S.L., Wass, J.A.H., Russell, R.G.G., Brown, M.A., Duncan, E.L., 2012. Risedronate in adults with osteogenesis imperfecta type I: increased bone mineral density and decreased bone turnover, but high fracture rate persists. *Osteoporos. Int.* 23 (1), 285–294. <https://doi.org/10.1007/s00198-011-1658-2>.
- Cho, S.Y., Asharani, P.V., Kim, O.H., Iida, A., Miyake, N., Matsumoto, N., Nishimura, G., Ki, C.S., Hong, G., Kim, S.J., Sohn, Y.B., Park, S.W., Lee, J., Kwun, Y., Carney, T.J., Huh, R., Ikegawa, S., Jin, D.K., 2015. Identification and in vivo functional characterization of novel compound heterozygous BMP1 variants in osteogenesis imperfecta. *Hum. Mutat.* 36 (2), 191–195. <https://doi.org/10.1002/humu.22731>.
- Choksi, I.N., Cox, A., Robinson, C., Bale, A., Carpenter, T.O., 2021. Novel homozygous variant in BMP1 associated with a rare osteogenesis imperfecta phenotype. *Osteoporos. Int.* <https://doi.org/10.1007/s00198-021-05838-1>.
- Cundy, T., Dray, M., Delahunt, J., Hald, J.D., Langdahl, B., Li, C., Szybowska, M., Mohammed, S., Duncan, E.L., McInerney-Leo, A.M., Wheeler, P.G., Roschger, P., Klaushofer, K., Rai, J., Weis, M.A., Eyre, D., Schwarze, U., Byers, P.H., 2018. Mutations that alter the carboxy-terminal-propeptide cleavage site of the chains of type I procollagen are associated with a unique osteogenesis imperfecta phenotype. *J. Bone Miner. Res.* 33 (7), 1260–1271. <https://doi.org/10.1002/jbmr.3424>.
- Fahiminiya, S., Al-Jallad, H., Majewski, J., Palomo, T., Moffatt, P., Roschger, P., Klaushofer, K., Glorieux, F.H., Rauch, F., 2015. A polyadenylation site variant causes transcript-specific BMP1 deficiency and frequent fractures in children. *Hum. Mol. Genet.* 24 (2), 516–524. <https://doi.org/10.1093/hmg/ddu471>.
- Fan, Z., Smith, P.A., Harris, G.F., Rauch, F., Bajorunaitė, R., 2007. Comparison of nanoindentation measurements between osteogenesis imperfecta type III and type I (femur/tibia versus iliac crest). *Connect. Tissue Res.* 48, 70–75.
- Forlino, A., Marini, J.C., 2016. Osteogenesis imperfecta. *Lancet* 387 (10028), 1657–1671. [https://doi.org/10.1016/S0140-6736\(15\)00728-X](https://doi.org/10.1016/S0140-6736(15)00728-X).
- Hoyer-Kuhn, H., Netzer, C., Semler, O., 2015. Osteogenesis imperfecta: pathophysiology and treatment. *Wien. Med. Wochenschr.* 165 (13–14), 278–284. <https://doi.org/10.1007/s10354-015-0361-x>.
- Le Quesne Stabej, P., James, C., Ocaka, L., Tekman, M., Grunewald, S., Clement, E., Stanescu, H.C., Kleta, R., Morrogh, D., Calder, A., Williams, H.J., Bitner-Glindzic, M., 2017. An example of the utility of genomic analysis for fast and accurate clinical diagnosis of complex rare phenotypes. *Orphanet J. Rare Dis.* 12 (1), 1–8. <https://doi.org/10.1186/s13023-017-0582-8>.
- Lindahl, K., Barnes, A.M., Fratzl-Zelman, N., Whyte, M.P., Hefferan, T.E., Makareeva, E., Brusel, M., Yaszemski, M.J., Rubin, C., Kindmark, A., Roschger, P., Klaushofer, K., McAlister, W.H., Mumm, S., Leikin, S., Kessler, E., Boskey, A.L., Ljunggren, Ö., Marini, J.C., 2011. COL1 C-propeptide cleavage site mutations cause high bone mass osteogenesis imperfecta. *Hum. Mutat.* 32 (6), 598–609. <https://doi.org/10.1002/humu.21475>.
- Marini, J.C., Dang Do, A.N., 2020. In: Feingold, K., Anawalt, B., Boyce, A., et al. (Eds.), *Osteogenesis Imperfecta*. MDText.com, Inc. <https://www.ncbi.nlm.nih.gov/ncbi/doi/10.1530/EJE-20-0299>.
- Marini, J.C., Forlino, A., Bächinger, N.P., Bishop, N.J., Byers, P.H., De Paepe, A., Fassier, F., Fratzl-Zelman, N., Kozloff, K.M., Krakow, D., Montpetit, K., Semler, O., 2017. Osteogenesis imperfecta. *Nat. Rev. Dis. Primers.* 3, 1–19. <https://doi.org/10.1038/nrdp.2017.52>.
- Marom, R., Rabenhorst, B.M., Morello, R., 2020. Osteogenesis imperfecta: an update on clinical features and therapies. *Eur. J. Endocrinol.* 183 (4), R95–R106. <https://doi.org/10.1530/EJE-20-0299>.
- Marshall, C.J., Arundel, P., Mushtaq, T., Offiah, A.C., Pollitt, R.C., Bishop, N.J., Balasubramanian, M., 2016. Diagnostic conundrums in antenatal presentation of a skeletal dysplasia with description of a heterozygous C-propeptide mutation in COL1A1 associated with a severe presentation of osteogenesis imperfecta. *Am. J. Med. Genet. A* 170 (12), 3303–3307. <https://doi.org/10.1002/ajmg.a.37943>.
- Martínez-Glez, V., Valencia, M., Caparrós-Martín, J.A., Aglan, M., Temtamy, S., Tenorio, J., Pulido, V., Lindert, U., Rohrbach, M., Eyre, D., Giunta, C., Lapunzina, P., Ruiz-Perez, V.L., 2012. Identification of a mutation causing deficient BMP1/mTLD proteolytic activity in autosomal recessive osteogenesis imperfecta. *Hum. Mutat.* 33 (2), 343–350. <https://doi.org/10.1002/humu.21647>.
- McInerney-Leo, A.M., Duncan, E.L., Leo, P.J., Gardiner, B., Bradbury, L.A., Harris, J.E., Clark, G.R., Brown, M.A., Zankl, A., 2015. COL1A1 C-propeptide cleavage site mutation causes high bone mass, bone fragility and jaw lesions: a new cause of gnathodiaphyseal dysplasia? *Clin. Genet.* 88 (1), 49–55. <https://doi.org/10.1111/cge.12440>.
- Pepe, V., Cristofolini, L., Dall'Ara, E., Oliviero, S., Balasubramanian, M., 2018. Development of Procedures to Perform Nanoindentation Tests on Different Bone Structures.
- Pepe, V., Oliviero, S., Cristofolini, L., Dall'Ara, E., 2020. Regional nanoindentation properties in different locations on the mouse tibia from C57BL/6 and Balb/C female mice. *Front Bioeng. Biotechnol.* 8, 478. May 15.
- Pollitt, R.C., Saraff, V., Dalton, A., Webb, E.A., Shaw, N.J., Sobey, G.J., Mughal, M.Z., Hobson, E., Ali, F., Bishop, N.J., Arundel, P., Högl, W., Balasubramanian, M., 2016. Phenotypic variability in patients with osteogenesis imperfecta caused by BMP1 mutations. *Am. J. Med. Genet. A* 170 (12), 3150–3156. <https://doi.org/10.1002/ajmg.a.37958>.
- Richards, S., Aziz, N., Bale, S., Bick, D., Das, S., Gastier-Foster, J., Grody, W.W., Hegde, M., Lyon, E., Spector, E., Voelkerding, K., Reh, H.L., ACMG Laboratory Quality Assurance Committee, 2015. Standards and guidelines for the interpretation of sequence variants: a joint consensus recommendation of the American College of Medical Genetics and Genomics and the Association for Molecular Pathology. *Genet. Med.* 17 (5), 405–424.
- Rolvien, T., Kornak, U., Stürznickel, J., Schinke, T., Amling, M., Mundlos, S., Oheim, R., 2018. A novel COL1A2 C-propeptide cleavage site mutation causing high bone mass osteogenesis imperfecta with a regional distribution pattern. *Osteoporos. Int.* 29 (1), 243–246. <https://doi.org/10.1007/s00198-017-4224-8>.
- Rossi, V., Lee, B., Marom, R., 2019. Osteogenesis imperfecta: advancements in genetics and treatment. *Curr. Opin. Paediatr.* 31 (6), 708–715. <https://doi.org/10.1097/MOP.0000000000000813>.
- Sangsin, A., Kuptanon, C., Srichomthong, C., Pongpanich, M., Suphapeetiporn, K., Shotlersuk, V., 2017. Two novel compound heterozygous BMP1 mutations in a patient with osteogenesis imperfecta: a case report. *BMC Med. Genet.* 18 (1), 4–8. <https://doi.org/10.1186/s12881-017-0384-9>.
- Symoens, S., Hulmes, D.J.S., Bourhis, J.M., Coucke, P.J., De Paepe, A., Malfait, F., 2014. *Hum. Mutat.* 35 (11), 1330–1341. <https://doi.org/10.1002/humu.22677>.
- Syx, D., Guillemin, B., Symoens, S., Sousa, A.B., Medeira, A., Whiteford, M., Hermanns-Lê, T., Coucke, P.J., De Paepe, A., Malfait, F., 2015. Defective proteolytic processing of fibrillar procollagens and prodecorin due to biallelic BMP1 mutations results in a severe, progressive form of Osteogenesis imperfecta. *J. Bone Miner. Res.* 30 (8), 1445–1456. <https://doi.org/10.1002/jbmr.2473>.
- Valencia, M., Caparrós-Martín, J.A., Sirerol-Piquer, M.S., García-Verdugo, J.M., Martínez-Glez, V., Lapunzina, P., Temtamy, S., Aglan, M., Lund, A.M., Nikkels, P.G. J., Ruiz-Perez, V.L., Ostergaard, E., 2014. Report of a newly identified patient with

- mutations in BMP1 and underlying pathogenetic aspects. *Am. J. Med. Genet. A* 164 (5), 1143–1150. <https://doi.org/10.1002/ajmg.a.36427>.
- Van Dijk, F.S., Sillence, D.O., 2014. Osteogenesis imperfecta: clinical diagnosis, nomenclature and severity assessment. *Am. J. Med. Genet. A* 164 (6), 1470–1481. <https://doi.org/10.1002/ajmg.a.36545>.
- Xu, X.Jie, Lv, F., Song, Y.Wen, Li, L.Jiao, Asan, Wei, X.Xiu, Zhao, X.Li, Jiang, Y., Wang, O., Xing, X.Ping, Xia, W.Bo, Li, M., 2019. Novel mutations in BMP1 induce a rare type of osteogenesis imperfecta. *Clin. Chim. Acta* 489 (November 2018), 21–28. <https://doi.org/10.1016/j.cca.2018.11.004>.