



This is a repository copy of *A mild case of acromesomelic dysplasia, type Maroteaux with novel natriuretic peptide receptor B (NPR2) variants.*

White Rose Research Online URL for this paper:
<https://eprints.whiterose.ac.uk/175386/>

Version: Published Version

Article:

Murch, O., Jain, V. and Offiah, A.C. orcid.org/0000-0001-8991-5036 (2021) A mild case of acromesomelic dysplasia, type Maroteaux with novel natriuretic peptide receptor B (NPR2) variants. *Radiology Case Reports*, 16 (8). pp. 2240-2243. ISSN 1930-0433

<https://doi.org/10.1016/j.radcr.2021.05.011>

Reuse

This article is distributed under the terms of the Creative Commons Attribution-NonCommercial-NoDerivs (CC BY-NC-ND) licence. This licence only allows you to download this work and share it with others as long as you credit the authors, but you can't change the article in any way or use it commercially. More information and the full terms of the licence here: <https://creativecommons.org/licenses/>

Takedown

If you consider content in White Rose Research Online to be in breach of UK law, please notify us by emailing eprints@whiterose.ac.uk including the URL of the record and the reason for the withdrawal request.



eprints@whiterose.ac.uk
<https://eprints.whiterose.ac.uk/>

Available online at www.sciencedirect.com

ScienceDirect

journal homepage: www.elsevier.com/locate/radcr

Case Report

A mild case of acromesomelic dysplasia, type Maroteaux with novel natriuretic peptide receptor B (NPR2) variants [☆]

Oliver Murch, BSc, MRes, MBBCh, PhD^{a,*}, Vani Jain, BSc, MBChB^a, Amaka C. Offiah, BSc, MBBS, PhD^b

^a All Wales Medical Genomics Service, Institute of Medical Genetics, University Hospital of Wales, Cardiff, CF14 4XW, UK

^b Paediatric Musculoskeletal Imaging, Academic Unit of Child Health, University of Sheffield and Sheffield Children's NHS Foundation Trust, Western Bank, Sheffield, S10 2TH UK

ARTICLE INFO

Article history:

Received 21 March 2021

Revised 3 May 2021

Accepted 4 May 2021

Available online 14 June 2021

Keywords:

Acromesomelic dysplasia, type

Maroteaux

AMDM

Natriuretic peptide receptor B

NPR2

ABSTRACT

Acromesomelic dysplasia, type Maroteaux is caused by variants in *NPR2*. It is a severe chondrodysplasia resulting in shortening of the middle and distal segments of the limbs. Limb length at birth may be normal but decreased growth becomes obvious in the first 2 years of life. Here we present an 11-year-old male with mild but typical skeletal features of acromesomelic dysplasia, type Maroteaux. Whole exome sequencing has identified two likely pathogenic variants in *NPR2* which have not previously been reported in individuals with acromesomelic dysplasia, type Maroteaux. Given these findings, a diagnosis of AMDM should be considered in individuals with characteristic radiological findings, even if stature is only modestly affected.

Crown Copyright © 2021 Published by Elsevier Inc. on behalf of University of Washington.

This is an open access article under the CC BY-NC-ND license

(<http://creativecommons.org/licenses/by-nc-nd/4.0/>)

Introduction

Acromesomelic dysplasia, type Maroteaux (AMDM, OMIM 602875) is a rare skeletal dysplasia. It is characterized by disproportionate short stature, primarily affecting the middle and distal segments of the limbs. The axial skeleton can also be affected and facial features can include a prominent forehead with a short nose [1]. Usually all skeletal elements are

present but show abnormal rates of linear growth [1–3]. At birth, children with AMDM generally have weight, length and head circumference measurements within the normal range. Postnatal skeletal growth is reduced and final height is usually below 120 cm [1–3]. Some individuals with AMDM have been treated with recombinant human growth hormone therapy with a variable response [4]. Intelligence in patients with AMDM is reported to be normal.

[☆] Competing Interest: The authors declare that they have no known competing financial interests or personal relationships that could have appeared to influence the work reported in this paper.

* Corresponding author.

E-mail address: oliver.murch@wales.nhs.uk (O. Murch).

<https://doi.org/10.1016/j.radcr.2021.05.011>

1930-0433/Crown Copyright © 2021 Published by Elsevier Inc. on behalf of University of Washington. This is an open access article under the CC BY-NC-ND license (<http://creativecommons.org/licenses/by-nc-nd/4.0/>)

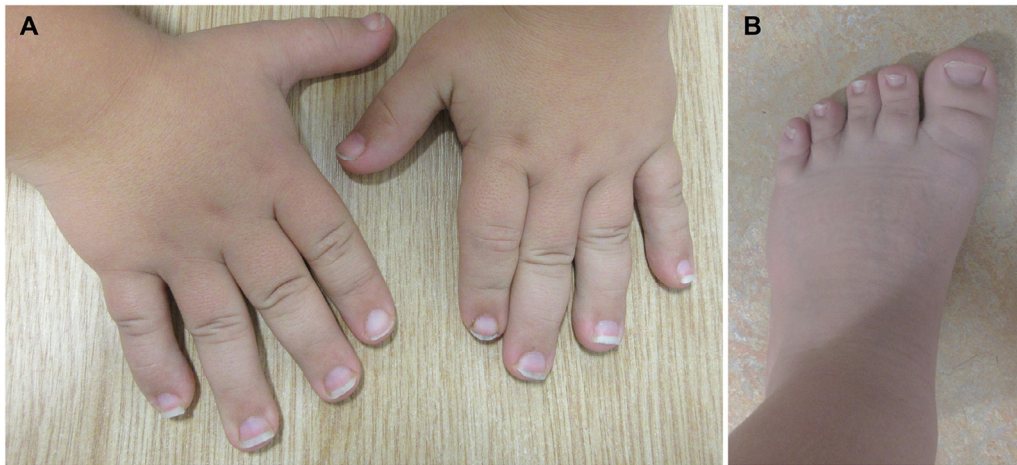


Fig. 1 – Photographs showing brachydactyly with broad fingers (A) and short, broad toes and feet (B).

AMDM is caused by biallelic variants in *NPR2* [2,3,5]. The gene encodes for the natriuretic peptide receptor B (NPR-B) that acts as an endogenous receptor for C-type natriuretic peptide (CNP). Both CNP and NPR-B are considered important regulators of longitudinal bone growth [3].

This report highlights two novel *NPR2* variants in a child with relatively mild but phenotypically consistent skeletal features of AMDM. He also has a degree of learning difficulty and other features which do not fit with a diagnosis of AMDM, possibly suggesting an additional, as yet unknown, diagnosis.

Case Report

The proband is the second child of non-consanguineous Caucasian parents. Antenatal scans were normal, and his birth weight was 3.48 Kg (25th–50th centile). By the time he was two and a half years old, he had developmental delay and pectus excavatum. His height was on the ninth centile and head circumference on the 75th centile. An echocardiogram was reported to be normal. He went on to have multiple hospital admissions for breathing difficulties, including one admission to intensive care due to a Grade 1 subglottic stenosis. He was later diagnosed with asthma and moderate obstructive sleep apnoea. The sleep apnoea did not improve despite adenotonsillectomy and he continues to require nocturnal CPAP. He has also developed extropia following correction for hyperopia. His hair is coarse and becomes wiry as it grows longer. He has a mild to moderate degree of learning difficulty.

At age 11 years, his height is on the second centile and he has relative macrocephaly, with a head circumference on the 91st centile and weight between the 75th to 91st centiles. Clinically he has mild mesomelic shortening, more evident in his upper limbs, and brachydactyly (Fig. 1). Maternal height is on the 25th centile and paternal height is on the second centile. On examination, neither parent has limb shortening or brachydactyly.

Due to his short stature, a skeletal survey (Fig. 2, Table 1) was requested. Imaging of the upper limbs revealed mild

mesomelic shortening, short and broad phalanges and metacarpals with typical cone shaped epiphyses. Vertebral bodies were pear shaped with a shorter posterior versus anterior height. Mild supra-acetabular notching was identified. The radiological appearances were thought to be consistent with a mild form of AMDM. Bone biochemistry was normal.

Previous chromosomal testing, including copy number analysis did not show any significant findings. A virtual skeletal dysplasia gene panel was arranged. Due to his extra-skeletal features, the family were also recruited to the Deciphering Developmental Disorders (DDD) study which performed trio whole exome sequencing. Both the DDD study and clinical testing identified two *NPR2* (NM_003995.04) missense variants c.1825G > A p.(Glu609Lys) and c.2512C > G p.(Leu838Val) which were maternally and paternally inherited, respectively. This would be in keeping with the known autosomal recessive pattern of inheritance of AMDM. Variants were confirmed by Sanger sequencing. Neither variant has previously been reported in patients with AMDM. They were both classified as likely pathogenic according to the American College of Medical Genetics and Genomics and the Association for Molecular Pathology (ACMG-AMP) guidelines and the 2020 Association for Clinical Genomic Science (ACGS) guidelines. No other significant variants have been identified.

Discussion

This case shows radiological features consistent with a clinical diagnosis of mild AMDM, although other forms of acromesomelic dysplasia should also be considered. Unlike AMDM, in both acromesomelic dysplasia, Hunter–Thompson type (AMDH) and Grebe type (AMDG) the craniofacial and axial skeleton is unaffected [3]. Both AMDH and AMDG have been reported to be caused by variants in *GDF5* and *BMP1B* [3,6,7]. However, there are radiological differences between them. In AMDH the lower limbs are more severely affected, phalanges tend to square and there may be a single phalangeal bone in the fifth digit. Ankle dislocation is common and radial head

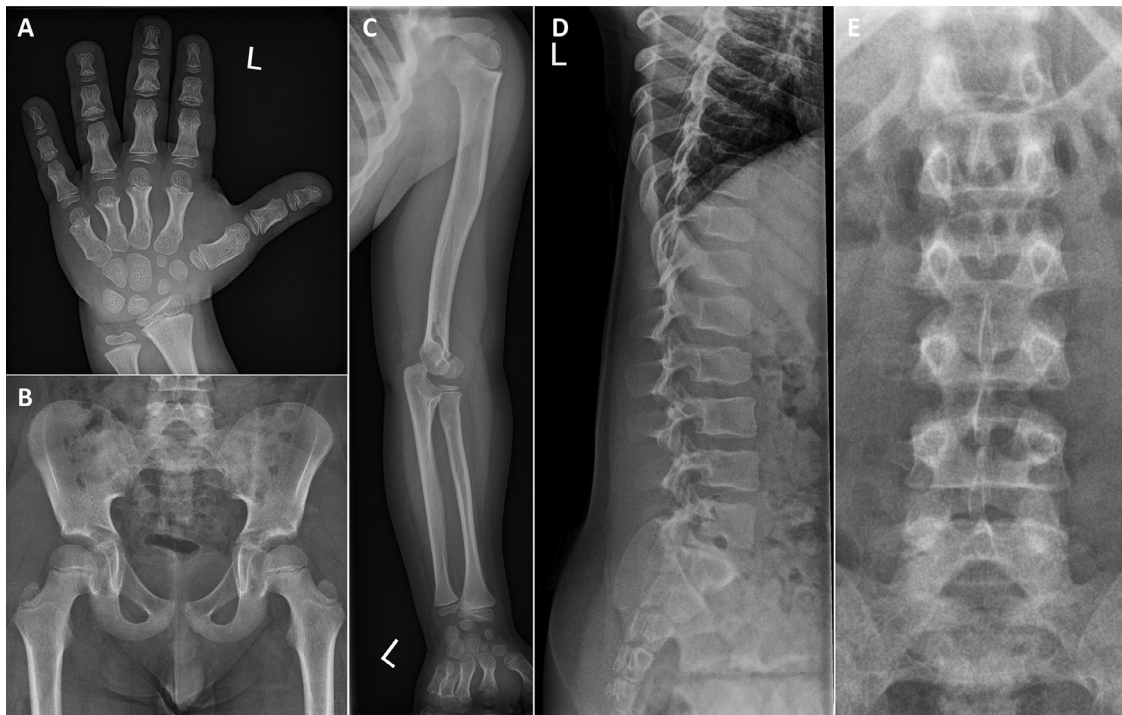


Fig. 2 – Radiographs aged nine years four months. DP left hand (A) with broadening and shortening of the bones, and significant coned appearance of the epiphyses. Anteroposterior radiograph of the pelvis (B) showing mild acetabular notching. DP left upper limb (C) showing mild mesomelic shortening. Lateral (D) and anteroposterior (E) radiographs of the lower spine with pear shaped vertebral bodies with shorter posterior than anterior heights and failure of widening of the lumbar interpedicular distances with some shortening of the pedicles.

Table 1 – Comparison of features AMDM and this patient

	Typical findings in AMDM [1–3,5]	This patient
Axial Skeleton	Head: Frontal prominence with or without a relatively short nose Spine: Wedging of vertebral bodies with shorter posterior versus anterior height, and later vertebral beaking Pelvis: Irregular ossification of superior acetabular region in childhood, hypoplasia of the base of the iliac bone	Head: Prominent forehead with midface hypoplasia and short nose Spine: Pear shaped vertebral bodies with a shorter posterior versus anterior height Pelvis: Mild supra-acetabular notching
Limbs	Mesomelic shortening. Radial bowing, flared metaphysis and occasional hypoplasia of the distal radius	Mild mesomelic shortening
Hands/Feet	Typical cone-shaped epiphyses, short and broad phalanges, metacarpal and metatarsal bones	Premature fusion and cone-shaped epiphyses of the middle phalanges of fingers and thumbs, cone-shaped epiphyses of the distal phalanges of the middle and ring fingers and thumbs. Short metacarpals

dislocation may be present [3,7]. AMDG is characterized by severe micromelia. Fusion of the carpals and/or metacarpals and tarsals and/or metatarsals maybe present. Metacarpal, metatarsal or proximal and/or middle phalanges may be absent. Postaxial polydactyly has also been reported. Significant femoral shortening is present in AMDG, as well as absent tibial and fibular diaphysis, hypoplasia of the ulna and a mal-

formed radial head [3,6]. A milder form with fibular hypoplasia and complex brachydactyly (acromesomelic dysplasia, du Pan type) has also been reported [8].

Whole exome sequencing through the DDD project did not find an additional genetic cause for this patient's other clinical features. The p.(Glu609Lys) variant is found at very low levels in gnomAD, with a mean allele frequency of 2.23×10^{-5} .

Homozygotes have not been reported. It is an evolutionary conserved amino acid residue located in the PKinase domain. The p (Leu838Val) variant is absent from population databases and is located in the CYCc functional domain at a conserved residue. NPR2 is relatively intolerant of missense variants with a DECIPHER missense constraint of 0.58 (250 observed vs 429 predicted missenses). Multiple computer predictions (including SIFT, PolyPhen, CADD, REVEL) indicate both are likely to be deleterious.

This patient is already taller than would be expected for an individual with AMDM. Also, his growth did not fall off sharply after birth. His mild AMDM features, along with his complex phenotype, probably contributed to his delayed diagnosis of AMDM. It is possible that one or both variants has less of a phenotypic effect than other reported variants in the gene, although to date there are no reported genotype-phenotype correlations. Carriers of NPR2 variants are reported to be shorter than average (height 1.4 SD below non carrier relatives) and can have non-specific skeletal abnormalities (brachydactyly and mild mesomelic shortening) [9]. The proband's father is also on the second centile for height, but does not have mesomelia or brachydactyly, compared to the proband, whose radiological features are more typical of AMDM.

As this is the first report of a patient with AMDM with other significant health and learning problems, at present we hesitate to link the NPR2 variants to his extra-skeletal features. It is not unusual to find two rare genetic conditions in the same individual, although in this case the patient has been extensively investigated and no other causative variants have been identified.

In summary this report describes a child with radiological findings consistent with a mild form of AMDM due to two novel NPR2 variants, therefore expanding the phenotypic and mutational spectrum of the condition. This suggests that a diagnosis of AMDM should be considered in individuals with typical radiological findings, even if stature is only mildly affected.

Patient consent

Both parents have consented for the child to be published in this article. This includes the use of both photographs and x-rays.

REFERENCES

- [1] Langer LO, Garrett RT. Acromesomelic dysplasia. *Radiology* 1980;137:349–55 Doi: [doi:10.1148/radiology.137.2.7433666](https://doi.org/10.1148/radiology.137.2.7433666).
- [2] Ain NU, Iqbal M, Valta H, Emerling CA, Ahmed S, Makitie O, et al. Novel variants in natriuretic peptide receptor 2 in unrelated patients with acromesomelic dysplasia type Maroteaux. *Eur J Med Genet* 2019;62:103554 Doi: [doi:10.1016/j.ejmg.2018.10.006](https://doi.org/10.1016/j.ejmg.2018.10.006).
- [3] Khan S, Basit S, Khan MA, Muhammad N, Ahmad W. Genetics of human isolated acromesomelic dysplasia. *Eur J Med Genet* 2016;59:198–203 Doi: [doi:10.1016/j.ejmg.2016.02.011](https://doi.org/10.1016/j.ejmg.2016.02.011).
- [4] Arya VB, Raj M, Younes M, Chapman S, Irving M, Kapoor RR, et al. Acromesomelic dysplasia, type maroteaux: impact of long-term (8 years) high-dose growth hormone treatment on growth velocity and final height in 2 siblings. *Horm Res Paediatr* 2020;93:335–42 Doi: [doi:10.1159/000511874](https://doi.org/10.1159/000511874).
- [5] Bartels CF, Bükülmez H, Padayatti P, Rhee DK, van Ravenswaaij-Arts C, Pauli RM, et al. Mutations in the transmembrane natriuretic peptide receptor NPR-B impair skeletal growth and cause acromesomelic dysplasia, type Maroteaux. *Am J Hum Genet* 2004;75:27–34 Doi: [doi:10.1086/422013](https://doi.org/10.1086/422013).
- [6] Umair M, Rafique A, Ullah A, Ahmad F, Ali RH, Nasir A, et al. Novel homozygous sequence variants in the GDF5 gene underlie acromesomelic dysplasia type-grebe in consanguineous families. *Congenit Anom (Kyoto)* 2017;57:45–51 Doi: [doi:10.1111/cga.12187](https://doi.org/10.1111/cga.12187).
- [7] Ullah A, Umair M, Muhammad D, Bilal M, Lee K, Leal SM, et al. A novel homozygous variant in BMP1B underlies acromesomelic dysplasia Hunter-Thompson type. *Ann Hum Genet* 2018;82:129–34 Doi: [doi:10.1111/ahg.12233](https://doi.org/10.1111/ahg.12233).
- [8] Stange K, Désir J, Kakar N, Mueller TD, Budde BS, Gordon CT, et al. A hypomorphic BMP1B mutation causes du Pan acromesomelic dysplasia. *Orphanet J Rare Dis* 2015;10:84 Doi: [doi:10.1186/s13023-015-0299-5](https://doi.org/10.1186/s13023-015-0299-5).
- [9] Jacob M, Menon S, Botti C, Marshall I. Heterozygous NPR2 mutation in two family members with short stature and skeletal dysplasia. *Case Rep Endocrinol* 2018;2018 Doi: [doi:10.1155/2018/7658496](https://doi.org/10.1155/2018/7658496).