



This is a repository copy of *Economic, clinical and social impact of simple limbal epithelial transplantation for limbal stem cell deficiency*.

White Rose Research Online URL for this paper:

<https://eprints.whiterose.ac.uk/172548/>

Version: Published Version

Article:

Thokala, P. orcid.org/0000-0003-4122-2366, Singh, A., Singh, V.K. et al. (5 more authors) (2022) Economic, clinical and social impact of simple limbal epithelial transplantation for limbal stem cell deficiency. *British Journal of Ophthalmology*, 106 (7). ISSN 0007-1161

<https://doi.org/10.1136/bjophthalmol-2020-318642>

Reuse

This article is distributed under the terms of the Creative Commons Attribution-NonCommercial (CC BY-NC) licence. This licence allows you to remix, tweak, and build upon this work non-commercially, and any new works must also acknowledge the authors and be non-commercial. You don't have to license any derivative works on the same terms. More information and the full terms of the licence here: <https://creativecommons.org/licenses/>

Takedown

If you consider content in White Rose Research Online to be in breach of UK law, please notify us by emailing eprints@whiterose.ac.uk including the URL of the record and the reason for the withdrawal request.






eprints@whiterose.ac.uk
<https://eprints.whiterose.ac.uk/>



OPEN ACCESS

Economic, clinical and social impact of simple limbal epithelial transplantation for limbal stem cell deficiency

Praveen Thokala,¹ Aastha Singh,² Vijay Kumar Singh,^{3,4} Varsha M Rathi ,⁵ Sayan Basu ,^{3,6} Vivek Singh ,^{3,4} Sheila MacNeil,⁷ Virender Singh Sangwan⁸

► Additional material is published online only. To view please visit the journal online (<http://dx.doi.org/10.1136/bjophthalmol-2020-318642>).

For numbered affiliations see end of article.

Correspondence to

Dr Sheila MacNeil, Department of Materials Science & Engineering, The University of Sheffield Koro Research Institute, Sheffield, UK; s.macneil@sheffield.ac.uk, Dr Vivek Singh, Center for Ocular Regeneration, Prof. Brien Holden Eye Research Center, LV Prasad Eye Institute, Hyderabad, Telangana, India; viveksingh@lvpei.org and Dr Virender Singh Sangwan, Dr Shroff's Charity Eye Hospital Delhi, New Delhi, India; virender.sangwan@sceh.net

Received 15 December 2020
Revised 21 January 2021
Accepted 5 February 2021

ABSTRACT

Aims To report the global uptake of simple limbal epithelial transplantation (SLET) and compare the economic, clinical and social outcomes of SLET with those of cultured limbal epithelial transplantation (CLET).

Methods A comprehensive literature review and an online survey of eye surgeons were conducted to understand the efficacy and current uptake of SLET surgery. A de novo economic model was developed to estimate the cost savings with SLET compared with CLET. Our economic analysis is conducted from an Indian perspective, as this is where the technique originated. A scenario analysis using the UK cost data and a user-friendly Excel model is included to allow users to input the costs from their setting to estimate the cost savings with using SLET compared with using CLET.

Results The anatomical success with SLET in adults (72.6% (range 62%–80%)) was the same as CLET (70.4% (range 68%–80.9%)). For children, the outcome for SLET (77.8% (range 73%–83%)) was better than with CLET (44.5% (range 43%–45%)). In response to our informal questionnaire, 99 surgeons reported to have performed SLET on 1174 patients in total. They appreciated that SLET negates the requirement for costly tissue engineering facilities. Results of economic analysis suggested that SLET provided an estimated cost-savings of US\$6470.88 for adults and US\$6673.10 for children. In broad terms, the cost of SLET is approximately 10% of the cost of CLET for adults and 8% for children.

Conclusion SLET offers a more accessible and financially attractive alternative to CLET to treat limbal stem cell deficiency.

INTRODUCTION

Limbal epithelial stem cells play a critical role in preserving the health of the corneal epithelium. In addition to refreshing the cells, they act as a barrier to prevent conjunctivalisation and vascularisation of the cornea that may result in loss of clarity. Damage or loss of these epithelial cells can thus lead to potentially severe visual impairment due to a condition termed limbal stem cell deficiency (LSCD).^{1,2}

Cultivated limbal epithelial transplantation (CLET) is a procedure of transplanting autologous laboratory-expanded limbal epithelial stem cells to replace conjunctivalised cornea with cultured epithelial cells. After 2–3 weeks of cell expansion, the cultured cells are transplanted onto the patient's affected eye, most commonly using human donor

amniotic membrane which often integrates into the corneal stroma without completely disappearing leaving the cultured cells attached to the underlying corneal stroma. Recently, a fibrin scaffold has been used for the delivery of cultured cells.³

CLET has an impressive success rate, however, it requires highly specialised tissue culture expertise and Good Manufacturing Practice facilities for the ex vivo expansion of the cells incurring significant costs for establishing specialist facilities/equipment, consumables and highly skilled labour. These facilities used for ex vivo expansion of cells must also operate under a strict set of regulations that require considerable ongoing investment. It is also a two-stage procedure, wherein after retrieving the donor cells from the patient, cells are expanded over 2–3 weeks in the laboratory after which they are transplanted to the affected eye.

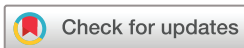In 2012, a novel procedure termed simple limbal epithelial transplantation (SLET) was proposed for patients with LSCD, where small pieces of tissue from the limbus of the healthy eye of the patient are directly transplanted into the affected eye, after surgically removing abnormal tissue, in a single surgery.⁴ SLET still needs the use of amniotic membrane to support the cell outgrowth from the pieces of limbal tissue but does not require any ex vivo tissue expansion nor a second surgery. Several SLET training workshops have now been conducted both in India and internationally, and as a result, SLET is now beginning to be used around the world.

It is suggested that SLET can overcome the challenges of establishing CLET and reach more patients as it does not require regulatory approval related to ex vivo expansion of cells and only requires a single surgery (compared with two surgeries in CLET) alleviating demands on the healthcare system and the patient. However, to our knowledge, no study has comprehensively estimated the clinical, economic and social impact of using SLET versus CLET for patients with LSCD.

The aim of this study is to estimate and report the economic, clinical and social impact of SLET in comparison with CLET.

MATERIALS AND METHODS

A multidisciplinary approach using mixed methods was used to estimate the clinical, economic and social impact of using SLET versus CLET for patients with LSCD. The clinical impact relates



© Author(s) (or their employer(s)) 2021. Re-use permitted under CC BY-NC. No commercial re-use. See rights and permissions. Published by BMJ.

To cite: Thokala P, Singh A, Singh VK, et al. *Br J Ophthalmol* Epub ahead of print: [please include Day Month Year]. doi:10.1136/bjophthalmol-2020-318642

Table 1 Clinical outcomes of cultured limbal epithelial transplantation and simple limbal epithelial transplantation

Author	Year	Country	N	Anatomic success (%)	Functional success (%)	Mean follow-up in years (range)
Cultured limbal epithelial transplantation outcomes						
Rama <i>et al</i> ⁴⁰	2010	Italy	107	68	54	2.9 (1–9.4)
Paulkin <i>et al</i> ⁴¹	2010	Italy	30	77	73	2.4 (0.8–6)
Sangwan <i>et al</i> ⁴	2011	India	200	71.4	60.3	3 (1–7.6)
Sejpal <i>et al</i> ³⁵	2012	India	107	37	NA	3.4 (1–9.8)
Ganger <i>et al</i> ³⁶	2015	India	54	72	23	1.8 (0.3–3.3)
Fasolo <i>et al</i> ⁴²	2017	Italy	59	42	NA	6 (1–13)
Simple limbal epithelial transplantation outcomes						
Basu <i>et al</i> ¹³	2016	India	125	76	75	1.5 (1–4)
Vazirani <i>et al</i> ¹⁷	2016	Multicentre	68	84	65	1 (0.5–4.9)
Gupta <i>et al</i> ²³	2018	India	30	70	50	1.1 (0.5–3.4)
Basu <i>et al</i> ²²	2018	India	30	80	NA	2.3 (0.8–3.8)

to the efficacy and current uptake of SLET surgery around the world; the economic impact relates to the costs associated with both procedures, and the social impact relates to the benefits to the patients and the healthcare system.

Methods for the estimation of clinical impact

Literature review

A literature review using search terms related to SLET in PubMed and Cochrane Library was conducted in May 2020 by two researchers (AS and VijayS) working independently to minimise the possibility of relevant studies being missed. From the studies identified in the review, data on the clinical effectiveness of SLET, the country/setting and the number of patients treated with SLET were extracted. To compare the clinical outcomes, we purposefully selected clinical studies with at least 30 patients and at least 1 or more years follow-up (table 1).

Questionnaire-based survey

In addition to surveying the published peer-reviewed literature, we obtained institutional permission to survey surgeons concerning their use of SLET (Ethics ref no LEC BHR-P-04-20-414). An iterative process was used in developing the set of questions regarding the surgeons' country/setting, the number of years of experience of conducting eye surgery, experience with SLET and CLET, availability of cell culture facilities and their opinions on SLET. The questionnaire was converted into an online survey specifically to target surgeons who attended a SLET workshop in recent years. The data gathered from the survey were collated and analysed to understand the uptake of SLET.

Estimation of the economic impact

Pathways of both surgeries were developed, and bottom-up costing was used to populate a de novo economic model to estimate the total costs of each procedure from a healthcare system perspective.

An iterative approach using process mapping techniques was used to understand the pathways involved in SLET and CLET. First, draft pathways were specified, based on the findings of the literature review, by researchers with knowledge of SLET and CLET. These were presented to clinical experts for feedback, and a final list of steps associated with SLET and CLET was put together (figure 3). A brief description of each of the steps was also presented to the clinicians to ensure the validity of resource use and costs associated with each step.

The total costs for SLET and CLET were estimated using bottom-up costing that is, by capturing and aggregating the costs associated with each of the steps. The costs were estimated from an Indian perspective, using the costs from the LV Prasad Eye Institute (LVPEI), Hyderabad, India for the base case analyses. A de novo economic model was developed in Microsoft Excel to estimate the total costs associated with SLET and CLET. Uncertainty in the costs was captured using parametric distributions and probabilistic sensitivity analyses were performed to estimate the robustness of the total cost estimates. Scenario analyses were also performed using costs from India and UK.

Estimation of the social impact

To understand the health system impact of SLET surgery compared with CLET, the lead clinicians involved in this study were interviewed and we also solicited comments, both good and bad, from surgeons who responded to our questionnaire.

RESULTS

Clinical impact of LSCD

Literature review

The literature searches identified 83 studies in which SLET outcomes were measured. After screening at the title and abstract level, 79 articles remained and of these 30 articles remained after a full-text examination. The Preferred Reporting Items for Systematic Reviews and Meta-Analyses diagram is presented in figure 1. An overview of the included studies and the data extracted is presented in online supplemental appendix 1.

The review identified 30 studies,^{4–33} covering 8 countries and a total of 432 patients reported as receiving SLET. The median follow-up in the largest case series (125 cases, Basu *et al*) was 1.5 years (range 1–4 years)¹³ and the longest reported follow-up period was 4.9 years.¹⁷ The number of patients who received SLET surgery estimated from the questionnaire is 1315 which is much higher than those reported in the peer-reviewed literature as expected. The cumulative number of published studies and patients treated with SLET are shown in figure 2A,B, respectively.

The clinical outcome of SLET/CLET is reported as anatomical success which refers to re-establishment of a completely epithelialised, stable and avascular corneal surface and functional success which refers to improvement in best-corrected visual acuity of two-lines or greater.³⁴ Anatomical and functional success in six studies of CLET and four studies of SLET, which involved at least 30 patients with a clinical follow-up of at least 1 year, is summarised in table 1. The mean anatomic success of cases

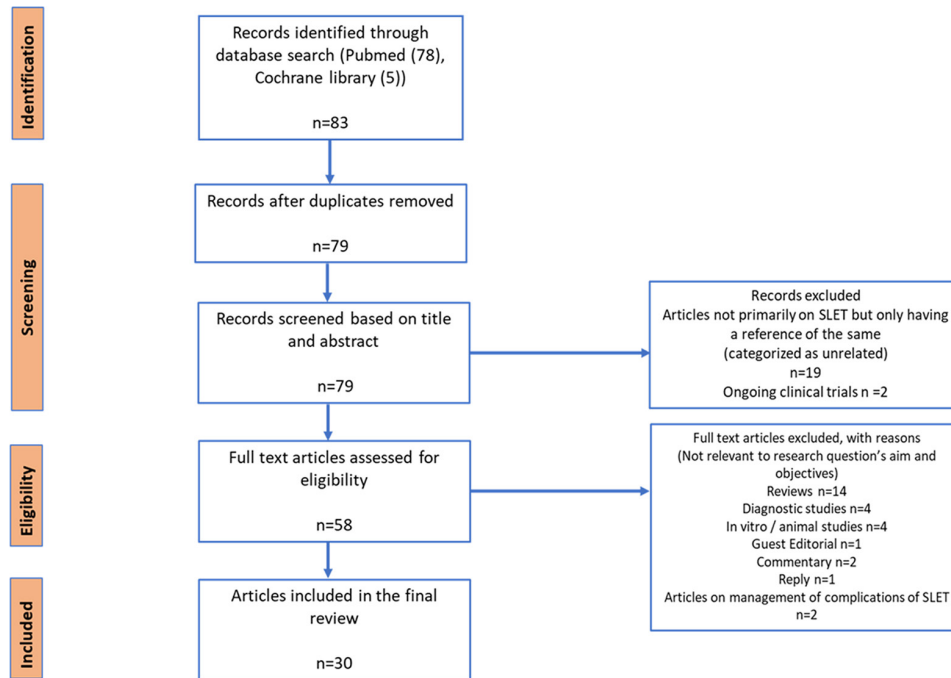


Figure 1 Preferred Reporting Items for Systematic Reviews and Meta-Analyses diagram for the simple limbal epithelial transplantation literature review.

was 78% (range 76%–84%) and the mean functional success of cases was 68.6% (range 50%–75%) which demonstrated clinical equivalence to CLET which has been reported to have anatomic success in 61.4% cases (range 37%–77%) and functional success in 51.5% cases (range 17%–70%).³⁴ Four studies reported a greater clinical benefit of using SLET instead of CLET when assessing outcomes for paediatric patients.^{5 13 14 24}

Questionnaire survey

Out of the 294 members of the Ocular Surface group of ophthalmologists (<http://www.corneasociety.org>), 99 belonging to different institutes, hospitals and individual clinics responded to this questionnaire. As SLET was discovered in India and most of the SLET workshops/Wet-labs/Training Courses were conducted in India, the majority of the surgeons were from India (91) but we also had the participation of surgeons from the USA (1), Mexico (3), Oman (1), Austria (1), Colombia (1), and Greece (1).

Of these 87% of surgeons had undertaken SLET surgery for the treatment of 1174 patients with LSCD, with 29% of surgeons undertaking the surgery in less than 5 patients, 35% in

5–10 patients, 32% in 11–50 patients and 2% with experience of SLET in more than 50 patients.

In response to the clinical experience of SLET, 1% surgeons were unhappy, 56% reasonably happy and 43% were very happy with the SLET procedure. Surgeon's comments regarding their experience with SLET were that the procedure is convenient, easy, cost-effective, scientific, efficient, reliable and reproducible. A few surgeons stated that there is a learning curve for SLET and there are issues of acceptance, vascularisation from the edges and unusual responses in paediatric cases. The detailed analysis of the results from the questionnaire-based survey is shown in online supplemental appendix 2.

Economic analysis

A brief description of the steps involved in SLET and CLET is presented in figure 3, and a summary of the costs is presented in table 2, and these are described in more detail in online supplemental appendix 3.

Cost data

The costs in Indian rupee (INR) associated with each of the steps involved in SLET and CLET established in the running of one large Indian hospital are presented in table 2 and described in detail in online supplemental appendix 3. The costs from a UK perspective are also presented as a scenario analysis.

Costs of SLET versus CLET

The total cost savings are provided as a breakdown of the individual cost differences as shown in table 3. The costs of SLET are approximately 10% of the costs of CLET for adults and 8% of the costs of CLET for children, with SLET providing an estimated cost savings of INR 480 000 for adults and INR 495 000 for children.

A comparison of the total costs of SLET versus CLET is also presented in figure 4A,B, for adults and children, respectively. Most of the savings associated with SLET are due to a reduction

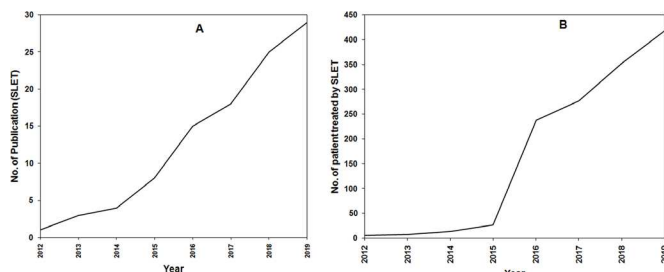


Figure 2 Publication pattern of SLET studies over the years 2012–2019. (A) Number of published papers over years. (B) Number of patients treated with SLET estimated from published studies. SLET, simple limbal epithelial transplantation.

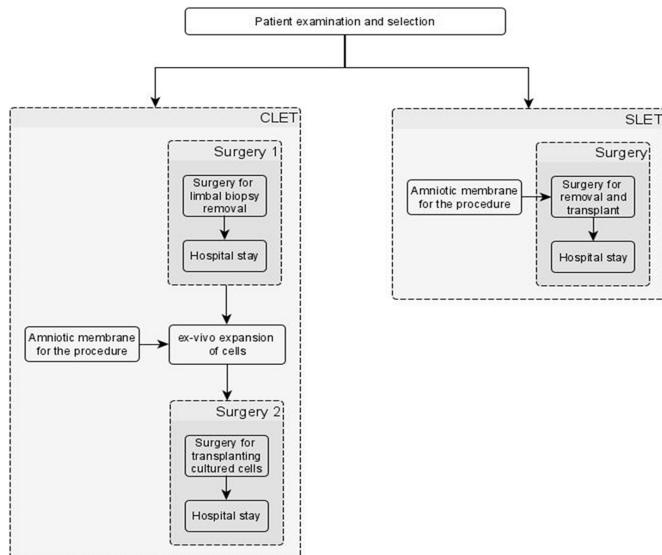


Figure 3 Flow chart of steps and procedures in CLET and SLET. CLET, cultured limbal epithelial transplantation; SLET, simple limbal epithelial transplantation.

in the need for cell culturing and the second surgery required for CLET. For children, the cost savings are higher due to the additional reduction in the anaesthesia costs.

Costs of surgery and cell culture were identified as the key cost drivers, the lower the costs of cell culture and surgery the lower the cost savings. Similarly, the higher the costs of cell culture and surgery the higher the average cost savings. This suggests that the cost savings are likely to be greater in developed countries where the costs associated with cell culture and surgery are higher. This is explored as a scenario analysis using the UK costs, which demonstrated cost savings of £54 061 for each adult patient (approximately INR 5 million using an exchange rate of 1 GBP=INR 94 from xe.com), as reported in online supplemental file 2.

Table 2 Costs associated with steps in CLET and SLET

Item	Mean value in INR	Range (lower 95% CI to upper 95% CI)
Costs associated with CLET		
First CLET surgery (biopsy)	34 800	10 300 to 86 700
General anaesthesia*	3600	2400 to 9300
Hospital stay*	3000 per day	1200 to 11 000
Amniotic membrane	2500	–
Cell culture	437 500	350 000 to 525 000
Second CLET surgery (transplantation)	34 800	10 300 to 86 700
Hospital stay*	3000 per day	1200 to 11 000
General anaesthesia*	3600	2400 to 9300
Fibrin glue	5900	1800 to 14 600
Costs associated with SLET		
Amniotic membrane	2500	–
Single SLET surgery	34 800	10 300 to 86 700
Hospital stay*	3000 per day	1200 to 11 000
General anaesthesia*	3600	2400 to 9300
Fibrin glue	5900	1800 to 14 600

*Only for children.

CLET, cultured limbal epithelial transplantation; INR, Indian rupee; SLET, simple limbal epithelial transplantation.

Table 3 Breakdown of cost results in Indian rupees (INR), with costs converted to US dollars in the brackets*

	CLET	SLET	Percentage average savings
Adult patients			
Surgery	INR 93 958 (US\$1253)	INR 51 022 (US\$680)	46
Cell culture	INR 439 226 (US\$5856)	INR 2496 (US\$33)	99
Total costs	INR 533 184 (US\$7110)	INR 53 518 (US\$714)	90
Children			
Surgery	INR 94 523 (US\$1260)	INR 51 199 (US\$683)	46
Hospitalisation*	INR 30 147 (US\$402)	INR 15 443 (US\$206)	51
Cell culture	INR 439 667 (US\$5862)	INR 2494 (US\$33)	99
Total costs	INR 564 337 (US\$7525)	INR 69 136 (US\$922)	88

*Using an exchange rate of US\$1=INR 75, from xe.com.

Social impact

Interviews with the two clinicians involved in this study highlighted several benefits associated with SLET such as low-cost procedure, requirement of single surgery can be performed in simple clinical setting and lower risk of contamination. The details are given in online supplemental appendix 4.

DISCUSSION

Peer-reviewed studies provide evidence from several groups that SLET has comparable clinical efficacy to CLET for adults and is slightly better for children.²⁴ The anatomical success with SLET in adults is 72.6% (range 62%–80%) and in children is 77.8% (range 73%–83%).^{13 24} For CLET, the anatomical success in adults is 70.4% (range 68%–80.9%) and in children is 44.5% (range 43%–45%).^{35 36}

The figures from the recent reviews of the two techniques suggest that the number of patients that have been treated over nearly 20 years by CLET is comparable to those treated with SLET in just over 7 years.^{34 37–39} The numbers from our informal survey suggest that the number of SLET surgeries has crossed the 1000 mark which, as expected, is higher than estimates from the published literature.

Our analyses suggest that SLET surgery is a cost-saving strategy when implemented for the care of patients with LSCD. A specialist eye hospital such as LVPEI is estimated to treat approximately 85 patients each year, and the estimated cost saving for replacement of CLET with SLET in such a hospital is

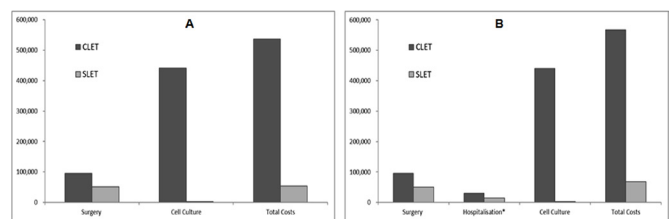


Figure 4 Graph showing the cost details of performing CLET and SLET in Indian rupees. (A) Cost for adults. (B) Cost for children. CLET, cultured limbal epithelial transplantation; SLET, simple limbal epithelial transplantation.

therefore around INR 40 million per annum. We have provided a user-friendly Excel tool for the readers to input costs related to their setting to estimate the economic impact of SLET compared with CLET.

The results of the current analysis have important implications for eye hospitals facing rising demand. The evidence suggests that the use of SLET may substantially reduce the number of surgeries which may also alleviate pressure on beds and associated costs. Indeed, SLET has replaced CLET as the preferred surgery option for patients with LSCD and several other hospitals around the world have now established SLET.

We present a strong case for SLET likely to be more commonly adopted in the future due to issues associated with CLET such as difficulty in setting up cell culture facilities, lack of commercial cell culture services, the prohibitive cost of cell culture and the many advantages offered by SLET.

To culture cells to a standard required for regulatory approval requires highly trained cell culture staff specialised premises and an invisible, but real burden of keeping these funded and regulatory compliant year on year. All such ventures begin with research funding and indeed quite successful clinically, however, there are very few cases where these endeavours become adopted as a routine clinical service with the full cost. To the best of our knowledge, there is currently only one organisation providing laboratory expansion of autologous limbal epithelial cells as a commercial clinical service (Chiesi Farmaceutica of Palermo, Italy). In 2015, they received European Medicines Agency approval for their autologous cell therapy Holoclar (the first stem cell product to be approved in European Union), where laboratory-expanded autologous cells are grown and delivered to the patient on a fibrin mat.³ In 2018, The National Institute of Health and Care Excellence (NICE) in England and Wales gave provisional approval for the use of Holoclar based on a confidential discount, as it was acknowledged that there was no other commercially approved methodology for culturing corneal cells in the UK for clinical use (<https://www.nice.org.uk/guidance/ta467/chapter/5-Implementation>).

Even when the service is set up to take on the culture of cells for clinical use, the economics of doing this meant that cost of each cell culture is prohibitive. Our costing model (online supplemental file 2) highlights the substantial costs of cell culturing (many times higher than the cost of the surgery itself). We were unable to find any such published figures in the UK or Europe, except for Holoclar as described above, where the price for culture service is listed as £80 000 per eye. Provisional approval by NICE is at a confidential discount price (at a discount not disclosed) on the understanding that long-term follow-up studies are required to be published when available. At the time of writing, we have not been able to find any information on the numbers of patients treated using this approach.

On the contrary, introduction of in situ cornea regeneration on the cornea offered by SLET is immediately attractive in economic terms. It can be done in institutes that do not have access to facilities for cell culture and surgeons can be trained to undertake the SLET procedure in less than a week (and then in turn to pass on the training). From the patient's perspective, there is one rather than two surgeries so less time to be spent in hospital, and a factor of 8-fold/10-fold savings in the costs of undertaking SLET versus CLET.

CONCLUSIONS

The published clinical data suggest that SLET is advantageous over CLET. The economic argument for using SLET rather than CLET is demonstrated in this study in a way that other centres can access it and run their analysis. In summary, simplification of

SLET technique so that cells slowly grow out of the small tissue explants to form a new cornea offers a viable, financially attractive and much more accessible approach to treat loss of vision.

Author affiliations

¹Health Economics and Decision Science, The University of Sheffield School of Health and Related Research, Sheffield, UK

²Cornea and Anterior Segment Services, Dr Shroff's Charity Eye Hospital Delhi, New Delhi, India

³Brien Holden Eye Research Center, LV Prasad Eye Institute, Hyderabad, Telangana, India

⁴Centre for Ocular Regeneration, LV Prasad Eye Institute, Hyderabad, Telangana, India

⁵Gullapalli Pratibha Rao International Centre for Advancement of Rural Eyecare, The Cornea Institute, LV Prasad Eye Institute, Hyderabad, Telangana, India

⁶Cornea and Anterior Segment Services, LV Prasad Eye Institute, Hyderabad, Telangana, India

⁷Department of Materials Science & Engineering, The University of Sheffield Koro Research Institute, Sheffield, UK

⁸Innovation Department, Dr Shroff's Charity Eye Hospital Delhi, New Delhi, Delhi, India

Twitter Aastha Singh @aastha314

Acknowledgements We are very grateful to surgical colleagues for returning questionnaires, providing evidence of the uptake of the technique beyond the hospital of its origin and showing that it has now been practised across several countries.

Funding The study was supported by Strategic Research Fund 2020 from the Faculty of Engineering, University of Sheffield, which provided support for PT and AS, and SERB core grant (CRG/2018/003514) which provided financial support to VKS and VS to devote some of their time to find and collate the information required for this study.

Competing interests None declared.

Patient consent for publication Not required.

Provenance and peer review Not commissioned; externally peer reviewed.

Data availability statement All data relevant to the study are included in the article or uploaded as supplementary information.

Supplemental material This content has been supplied by the author(s). It has not been vetted by BMJ Publishing Group Limited (BMJ) and may not have been peer-reviewed. Any opinions or recommendations discussed are solely those of the author(s) and are not endorsed by BMJ. BMJ disclaims all liability and responsibility arising from any reliance placed on the content. Where the content includes any translated material, BMJ does not warrant the accuracy and reliability of the translations (including but not limited to local regulations, clinical guidelines, terminology, drug names and drug dosages), and is not responsible for any error and/or omissions arising from translation and adaptation or otherwise.

Open access This is an open access article distributed in accordance with the Creative Commons Attribution Non Commercial (CC BY-NC 4.0) license, which permits others to distribute, remix, adapt, build upon this work non-commercially, and license their derivative works on different terms, provided the original work is properly cited, appropriate credit is given, any changes made indicated, and the use is non-commercial. See: <http://creativecommons.org/licenses/by-nc/4.0/>.

ORCID iDs

Varsha M Rathi <http://orcid.org/0000-0002-5422-0290>

Sayan Basu <http://orcid.org/0000-0001-5030-5003>

Vivek Singh <http://orcid.org/0000-0003-3958-5635>

REFERENCES

- Sehic A, Utheim Øygunn Aass, Ommundsen K, et al. Pre-Clinical cell-based therapy for limbal stem cell deficiency. *J Funct Biomater* 2015;6:863–88.
- Vemuganti GK, Sangwan VS. Interview: affordability at the cutting edge: stem cell therapy for ocular surface reconstruction. *Regen Med* 2010;5:337–40.
- Pellegrini G, Ardigò D, Milazzo G, et al. Navigating market authorization: the path Holoclar took to become the first stem cell product Approved in the European Union. *Stem Cells Transl Med* 2018;7:146–54. doi:10.1002/sctm.17-0003
- Sangwan VS, Basu S, MacNeil S, et al. Simple limbal epithelial transplantation (SLET): a novel surgical technique for the treatment of unilateral limbal stem cell deficiency. *Br J Ophthalmol* 2012;96:931–4. doi:10.1136/bjophthalmol-2011-301164
- Bhalekar S, Basu S, Lal I, et al. Successful autologous simple limbal epithelial transplantation (SLET) in previously failed paediatric limbal transplantation for ocular surface burns. *BMJ Case Rep* 2013;2013:bcr2013009888.

- 6 Vazirani J, Basu S, Sangwan V. Successful simple limbal epithelial transplantation (SLET) in lime injury-induced limbal stem cell deficiency with ocular surface granuloma. *BMJ Case Rep* 2013;2013:bcr2013009405.
- 7 Amescua G, Atallah M, Nikpoor N, et al. Modified simple limbal epithelial transplantation using cryopreserved amniotic membrane for unilateral limbal stem cell deficiency. *Am J Ophthalmol* 2014;158:469–75.
- 8 Das S, Basu S, Sangwan V. Molten metal ocular burn: long-term outcome using simple limbal epithelial transplantation. *BMJ Case Rep* 2015;2015:bcr2014209272.
- 9 Hernández-Bogantes E, Amescua G, Navas A, et al. Minor ipsilateral simple limbal epithelial transplantation (mini-SLET) for pterygium treatment. *Br J Ophthalmol* 2015;99:1598–600. doi:10.1136/bjophthalmol-2015-306857
- 10 Nair D, Mohamed A, Sangwan VS. Outcome of cataract surgery following simple limbal epithelial transplantation for lime injury-induced limbal stem cell deficiency. *BMJ Case Rep* 2015;2015:bcr2015212613.
- 11 Vazirani J, Lal I, Sangwan V. Customised simple limbal epithelial transplantation for recurrent limbal stem cell deficiency. *BMJ Case Rep* 2015;2015:bcr2015209429. doi:10.1136/bcr-2015-209429
- 12 Arya SK, Bhatti A, Raj A, et al. Simple limbal epithelial transplantation in acid injury and severe dry eye. *J Clin Diagn Res* 2016;10:ND06–7–7.
- 13 Basu S, Sureka SP, Shanbhag SS, et al. Simple limbal epithelial transplantation: long-term clinical outcomes in 125 cases of unilateral chronic ocular surface burns. *Ophthalmology* 2016;123:1000–10–10.
- 14 Mittal V, Jain R, Mittal R, et al. Successful management of severe unilateral chemical burns in children using simple limbal epithelial transplantation (SLET). *Br J Ophthalmol* 2016;100:1102–8.
- 15 Mittal V, Narang P, Menon V, et al. Primary simple limbal epithelial transplantation along with excisional biopsy in the management of extensive ocular surface squamous neoplasia. *Cornea* 2016;35:1650–2.
- 16 Queiroz AG, Barbosa MMO, Santos MS, et al. Assessment of surgical outcomes of limbal transplantation using simple limbal epithelial transplantation technique in patients with total unilateral limbal deficiency. *Arq Bras Oftalmol* 2016;79:116–8–8.
- 17 Vazirani J, Ali MH, Sharma N, et al. Autologous simple limbal epithelial transplantation for unilateral limbal stem cell deficiency: multicentre results. *Br J Ophthalmol* 2016;100:1416–20.
- 18 Arora R, Dokania P, Manudhane A, et al. Preliminary results from the comparison of simple limbal epithelial transplantation with conjunctival limbal autologous transplantation in severe unilateral chronic ocular burns. *Indian J Ophthalmol* 2017;65:35–40–40. doi:10.4103/0301-4738.202312
- 19 Iyer G, Srinivasan B, Agarwal S, et al. Outcome of allo simple limbal epithelial transplantation (alloSLET) in the early stage of ocular chemical injury. *Br J Ophthalmol* 2017;101:828–33.
- 20 Kaliki S, Mohammad FA, Tahiliani P, et al. Concomitant simple limbal epithelial transplantation after surgical excision of ocular surface squamous neoplasia. *Am J Ophthalmol* 2017;174:68–75.
- 21 Singh D, Vanathi M, Gupta C, et al. Outcomes of deep anterior lamellar keratoplasty following autologous simple limbal epithelial transplant in pediatric unilateral severe chemical injury. *Indian J Ophthalmol* 2017;65:217–222–22.
- 22 Basu S, Mohan S, Bhalekar S, et al. Simple limbal epithelial transplantation (SLET) in failed cultivated limbal epithelial transplantation (CLET) for unilateral chronic ocular burns. *Br J Ophthalmol* 2018;102:1640–5.
- 23 Gupta N, Farooqui JH, Patel N, et al. Early results of penetrating keratoplasty in patients with unilateral chemical injury after simple limbal epithelial transplantation. *Cornea* 2018;37:1249–54.
- 24 Gupta N, Joshi J, Farooqui JH, et al. Results of simple limbal epithelial transplantation in unilateral ocular surface burn. *Indian J Ophthalmol* 2018;66:45–52.
- 25 Mednick Z, Boutin T, Einan-Lifshitz A, et al. Simple limbal epithelial transplantation for recurrent pterygium: a case series. *Am J Ophthalmol Case Rep* 2018;12:5–8.
- 26 Narang P, Mittal V, Menon V, et al. Primary limbal stem cell transplantation in the surgical management of extensive ocular surface squamous neoplasia involving the limbus. *Indian J Ophthalmol* 2018;66:1569–1573–73.
- 27 Vasquez-Perez A, Nanavaty MA. Modified allogenic simple limbal epithelial transplantation followed by keratoplasty as treatment for total limbal stem cell deficiency. *Ocul Immunol Inflamm* 2018;26:1189–91.
- 28 Boutin T, Mednick Z, Zhou TE, et al. Simple limbal epithelial transplantation to treat recurring kissing pterygium. *Can J Ophthalmol* 2019;54:e54–7.
- 29 Gupta N, Singh A, Mathur U. Scleral ischemia in acute ocular chemical injury: long-term impact on rehabilitation with limbal stem cell therapy. *Cornea* 2019;38:198–202.
- 30 Hu XD, Yu J, Li SY, et al. [Clinical observation of autologous simple limbal epithelial transplantation for unilateral limbal stem cell deficiency]. *Zhonghua Yan Ke Za Zhi* 2019;55:923–7.
- 31 Sati A, Banerjee S, Kumar P, et al. Mini-Simple limbal epithelial transplantation versus conjunctival autograft fixation with fibrin glue after pterygium excision: a randomized controlled trial. *Cornea* 2019;38:1345–50.
- 32 Shah SG, Shah SM, Agarwal J, et al. Feasibility and outcome of simple limbal epithelial transplantation (SLET) in unilateral total limbal stem cell deficiency (LSCD) following chemical injury, in a semiurban location in Western India. *Indian J Ophthalmol* 2019;67:1382–3.
- 33 Riedl JC, Musayeva A, Wasielica-Poslednik J, et al. Allogenic simple limbal epithelial transplantation (alloSLET) from cadaveric donor eyes in patients with persistent corneal epithelial defects. *Br J Ophthalmol* 2021;105:180–5.
- 34 Shanbhag SS, Nikpoor N, Rao Donthineni P, et al. Autologous limbal stem cell transplantation: a systematic review of clinical outcomes with different surgical techniques. *Br J Ophthalmol* 2020;104:247–53.
- 35 Sejal K, Ali MH, Maddileti S, et al. Cultivated limbal epithelial transplantation in children with ocular surface burns. *JAMA Ophthalmol* 2013;131:731–6.
- 36 Ganger A, Vanathi M, Mohanty S, et al. Long-Term outcomes of cultivated limbal epithelial transplantation: evaluation and comparison of results in children and adults. *Biomed Res Int* 2015;2015:1–6.
- 37 Shanbhag SS, Patel CN, Goyal R, et al. Simple limbal epithelial transplantation (SLET): review of indications, surgical technique, mechanism, outcomes, limitations, and impact. *Indian J Ophthalmol* 2019;67:1265–1277–77.
- 38 Jackson CJ, Myklebust Ernø IT, Ringstad H, et al. Simple limbal epithelial transplantation: current status and future perspectives. *Stem Cells Transl Med* 2020;9:316–27.
- 39 Shukla S, Shanbhag SS, Tavakkoli F, et al. Limbal epithelial and mesenchymal stem cell therapy for corneal regeneration. *Curr Eye Res* 2020;45:265–77.
- 40 Rama P, Matuska S, Paganoni G, et al. Limbal stem-cell therapy and long-term corneal regeneration. *N Engl J Med* 2010;363:147–55.
- 41 Pauklin M, Fuchsluger TA, Westekemper H, et al. Midterm results of cultivated autologous and allogeneic limbal epithelial transplantation in limbal stem cell deficiency. *Dev Ophthalmol* 2010;45:57–70.
- 42 Fasolo A, Pedrotti E, Passilongo M, et al. Safety outcomes and long-term effectiveness of ex vivo autologous cultured limbal epithelial transplantation for limbal stem cell deficiency. *Br J Ophthalmol* 2017;101:640–9.

Appendix 1:

Supplementary Table 1: Summary of published literature on outcomes of Simple Limbal Epithelial Transplantation (SLET)

S. No.	Author	Country	Institute/Research group	Year	Type of article	Title	N	Indication	Anatomic Success (%)	Functional Success (%)	Mean Follow up (Years)
1	Sangwan <i>et al</i> [4]	India	LVPEI	2012	Clinical Study	Simple limbal epithelial transplantation (SLET): a novel surgical technique for the treatment of unilateral limbal stem cell deficiency.	6	Chemical injury	100	66.6	2.1
2	Bhalekar <i>et al</i> [5]	India	LVPEI	2013	Case Report	Successful autologous simple limbal epithelial transplantation (SLET) in previously failed paediatric limbal transplantation for ocular surface burns.	1	Chemical injury	100	100	1
3	Vazirani <i>et al</i> [6]	India	LVPEI	2013	Case Report	Successful simple limbal epithelial transplantation (SLET) in lime injury-induced limbal stem cell deficiency with ocular surface granuloma.	1	Chemical injury	100	100	0.50
4	Amescua <i>et al</i> [7]	USA	Bascom Palmer Eye Institute	2014	Case Series	Modified simple limbal epithelial transplantation using cryopreserved amniotic membrane for unilateral limbal stem cell deficiency.	6	Chemical injury LSCD secondary to treatment for Melanoma	100	100	0.63
5	Das <i>et al</i> [8]	India	LVPEI	2015	Case Report	Molten metal ocular burn: long-term outcome using simple limbal epithelial transplantation.	1	Thermal Injury	100	100	2.3

6	Hernández-Bogantes <i>et al</i> [9]	Mexico	Instituto de Oftalmología, Fundación Conde de Valenciana, Bascom Palmer Eye Institute	2015	Clinical Study	Minor ipsilateral simple limbal epithelial transplantation (MILE) for pterygium treatment.	10	Presbyopia	100	NA	0.67
7	Nair <i>et al</i> [10]	India	LVPEI	2015	Case Report	Outcome of cataract surgery following simple limbal epithelial transplantation for lime injury-induced limbal stem cell deficiency	1	Chemical Injury	100	100	0.42
8	Vazirani <i>et al</i> [11]	India	LVPEI	2015	Case Report	Customised simple limbal epithelial transplantation for recurrent limbal stem cell deficiency.	1	Chemical Injury	100	NA	0.42
9	Arya <i>et al</i> [12]	India	Government Medical College, Chandigarh	2016	Case Report	Simple Limbal Epithelial Transplantation in Acid Injury and Severe Dry Eye.	2	Chemical Injury, Severe Dry Eye due to Ocular surface Disease	100	50 (Case 2- cause of poor vision -Optic atrophy secondary to pre-existing glaucoma)	0.50
10	Basu <i>et al</i> [13]	India	LVPEI	2016	Clinical Study	Simple Limbal Epithelial Transplantation: Long-Term Clinical Outcomes in 125 Cases of Unilateral Chronic Ocular Surface Burns.	125	Chemical Injury	76	75	1.5

11	Mittal <i>et al</i> [14]	India	Sanjivni Eye care, DrishtiC one Eye Care	2016	Case Series	Successful management of severe unilateral chemical burns in children using simple limbal epithelial transplantation (SLET).	4	Chemical Injury	100	75	5
12	Mittal <i>et al</i> [15]	India	Sanjivni Eye Care Hospital , Centre for Sight, Hyderabad	2016	Case Report	Primary Simple Limbal Epithelial Transplantation Along With Excisional Biopsy in the Management of Extensive Ocular Surface Squamous Neoplasia.	1	OSSN	100	NA	2
13	Queiroz <i>et al</i> [16]	Brazil	Universidade Federal de São Paulo	2016	Clinical Study	Assessment of surgical outcomes of limbal transplantation using simple limbal epithelial transplantation technique in patients with total unilateral limbal deficiency.	4	Chemical Injury	50	25	0.5
14	Vazirani <i>et al</i> [17]	India USA Mexico	LVPEI, SCEH, AIIMS, Sanjivni Eye Care Hospital , Disha Eye Hospitals, MEEI, Bascom Palmer Eye Institute, Instituto	2016	Clinical Study	Autologous simple limbal epithelial transplantation for unilateral limbal stem cell deficiency: multicentre results.	68	Chemical Injury	83.8	64.7	1

			de Oftalmologia, Fundación Conde de Valenciana								
15	Arora <i>et al</i> [18]	India	Guru Nanak Eye Centre	2017	Clinical Study	Preliminary results from the comparison of simple limbal epithelial transplantation with conjunctival limbal autologous transplantation in severe unilateral chronic ocular burns.	10	Chemical Injury	100	100	0.5
16	Iyer <i>et al</i> [19]	India	Sankara Nethralaya	2017	Clinical Study	Outcome of allo simple limbal epithelial transplantation (alloSLET) in the early stage of ocular chemical injury.	18	Chemical Injury	94.1	72.2	0.86
17	Kaliki <i>et al</i> [20]	India	LVPEI	2016	Clinical Study	Concomitant Simple Limbal Epithelial Transplantation After Surgical Excision of Ocular Surface Squamous Neoplasia.	7	OSSN	100	NA	1
18	Singh <i>et al</i> [21]	India	AIIMS	2017	Clinical Study	Outcomes of deep anterior lamellar keratoplasty following autologous simple limbal epithelial transplant in pediatric unilateral severe chemical injury.	11	Chemical Injury	81.8	63.6	1.3
19	Basu <i>et al</i> [22]	India	LVPEI	2018	Clinical Study	Simple limbal epithelial transplantation (SLET) in failed cultivated limbal epithelial transplantation (CLET) for unilateral chronic ocular burns.	30	Failed CLET	80	NA	2.3
20	Gupta <i>et al</i> [23]	India	SCEH	2018	Clinical Study	Early Results of Penetrating Keratoplasty in Patients With Unilateral Chemical Injury After Simple Limbal Epithelial Transplantation.	7	Chemical Injury	100	57.1 (Reasons for poor vision in 3)	1.3

										cases - glaucoma, amblyopia, graft failure)	
21	Gupta <i>et al</i> [24]	India	SCEH	2018	Clinical Study	Results of simple limbal epithelial transplantation in unilateral ocular surface burn.	30	Chemical Injury	70	50	1.1
22	Mednick Z <i>et al</i> [25]	Canada	University of Toronto	2018	Case Series	Simple limbal epithelial transplantation for recurrent pterygium: A case series	4	Recurrent Pterygium	100	75 (Case3 – cause of poor vision – epiretinal membrane)	0.67
23	Narang <i>et al</i> [26]	India	LJ Eye Institute, Centre for Sight Hyderabad, CMRI Hospital, Kolkata	2018	Clinical Study	Primary limbal stem cell transplantation in the surgical management of extensive ocular surface squamous neoplasia involving the limbus.	3	OSSN	100	NA	NA
24	Vasquez - Perez <i>et al</i> [27]	UK	Sussex Eye Hospital, Brighton	2018	case report	ModifiedAllogenic Simple Limbal Epithelial Transplantation Followed by Keratoplasty as Treatment for Total Limbal Stem Cell Deficiency.	1	Post Mitomycin treatment for Melanoma	100	100	0.92
25	Boutin <i>et al</i> [28]	Canada	University of Toronto	2018	case report	Simple limbal epithelial transplantation to treat recurring kissing pterygium.	1	Pterygium	100	100	0.67
26	Gupta <i>et al</i>	India	SCEH	2019	Clinical	Scleral Ischemia in Acute Ocular Chemical Injury:	15	Chemical	53.3	NA	1.3

	<i>al</i> [29]				1 Study	Long-Term Impact on Rehabilitation With Limbal Stem Cell Therapy.		Injury			
27	Hu XD <i>et al</i> [30]	China	Beijing Tongren Eye Center	2019	Clinical Study	Clinical observation of autologous simple limbal epithelial transplantation for unilateral limbal stem cell deficiency	7	Chemical Injury	100	100	0.50
28	Sati <i>et al</i> [31]	India	Armed Forces Medical College	2019	Clinical Study	Mini-Simple Limbal Epithelial Transplantation Versus Conjunctival Autograft Fixation With Fibrin Glue After Pterygium Excision: A Randomized Controlled Trial.	40	Recurrent Pterygium	100	NA	0.50
29	Shah <i>et al</i> [32]	India	Drashti Nethralaya Eyelife Netra Mandir	2019	Clinical Study	Feasibility and outcome of simple limbal epithelial transplantation (SLET) in unilateral total limbal stem cell deficiency (LSCD) following chemical injury, in a semiurban location in Western India.	3	Chemical Injury	66.1	66.7	0.36
30	Reidl <i>et al</i> [33]	Germany	University Medical Center of the Johannes Gutenberg-University Mainz	2020	Clinical Study	Allogenic simple limbal epithelial transplantation (alloSLET) from cadaveric donor eyes in patients with persistent corneal epithelial defects	14	Persistent Epithelial defect	92.9	78.6	1

LVPEI- LV Prasad Eye Institute, Hyderabad, India; SCEH- Dr. Shroff's Charity Eye Hospital, New Delhi, India; AIIMS- All India Institute of Medical Sciences, New Delhi, India; MEE- Massachusetts Eye and Ear Infirmary, Boston, USA, OSSN – Ocular Surface Squamous Neoplasia

Appendix 2: Responses from the SLET survey questionnaire

In addition to surveying the published peer-reviewed literature we obtained institutional permission (Clinical, economic and social impact of Simple limbal epithelial transplantation [SLET] vs Cultivated limbal epithelial transplantation [CLET]-DrSayanBasu, DrVivek Singh- Ethics Ref No LEC BHR-P-04-20-414) to undertake questionnaires of surgeons concerning their use of SLET. The details of the questionnaire can be found in Appendix 1. The questionnaire was converted to an online format using Google form and the link was sent to The Ocular Surface group of ophthalmologists.

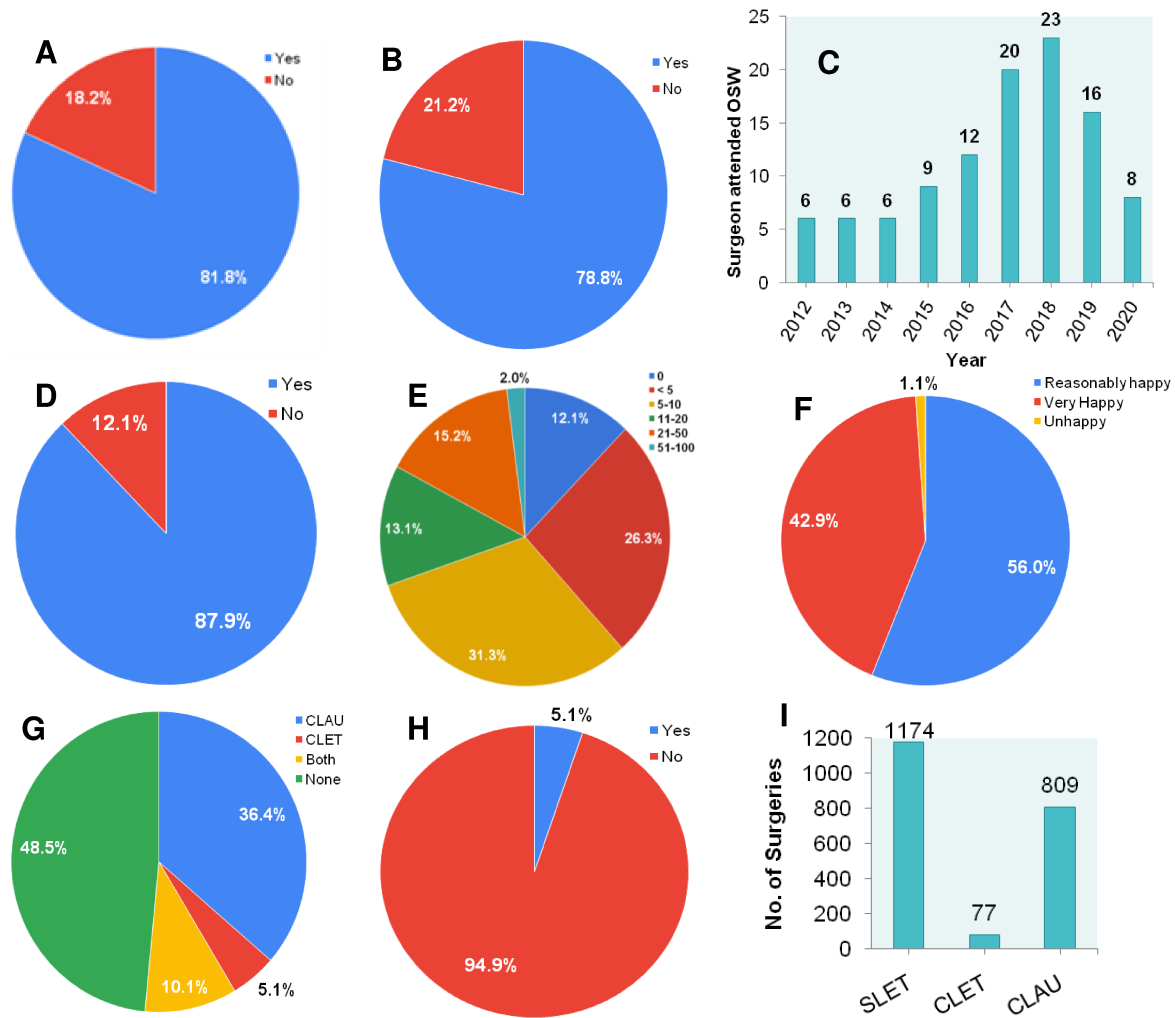
Out of the 294 members of The Ocular Surface group of ophthalmologists, 99 members belonging to different institutes, hospitals and individual clinics responded to this questionnaire. As SLET was conceptualized in India and most of the SLET workshops/wet-lab/ training courses were conducted in India, the majority of the surgeons who participated in the survey were from India (91), however we also had participation of surgeons from USA (1), Mexico (3), Oman (1), Austria (1), Colombia (1), and Greece (1). Out of these 99 surgeons, 81% were happy to share their contact details (**Fig 1A**).

More than 78% of these surgeons had participated in SLET workshops/ Wet-lab/ Training Courses conducted by surgeons specialized in the SLET procedure (**Fig 1B**). The number of participants in ocular surface workshops was constant in the initial years of SLET inception (2012 to 2014) with a slight increase seen thereafter till 2016 and peaking observed in 2018 (**Fig 1C**).

Of these 87% surgeons had undertaken SLET surgery for treatment of 1174 LSCD patients (**Fig 1D**). The responses were further categorized based on the number of surgeries. 29% of surgeons had undertaken the surgery in less than 5 patients, 35% in 5 to 10 patients, 32% in 11 to 50 patients and only 2% had experience of SLET in more than 50 patients (**Fig 1E**).

In response to the clinical experience of SLET, 1% were unhappy, 56% reasonably happy and 42% were very happy with the SLET procedure (**Fig 1F**). Surgeons comments regarding their experience with SLET were that the procedure is convenient, easy, cost effective, scientific, efficient, reliable and reproducible. A few surgeons stated that there is a learning curve for SLET and there are issues of graft acceptance, vascularization from the edges post surgery and unusual responses in pediatric cases.

More than 50% of surgeons had undertaken other procedures such as CLAU and CLET for treatment of LSCD (**Fig 1G**). CLAU was practiced by 36% of surgeons, both CLET and CLAU by 10% of the surgeons and CLET by only 5% of surgeons due to the fact that only 5% of surgeons had cell culture facilities for CLET (**Fig 1H**). A total of 77 and 809 LSCD patients were treated using CLET and CLAU respectively (**Fig 1I**). In response to if they were given a choice of SLET or CLET 100% of these surgeons responded that they would prefer SLET.



Supplementary figure 1. The quantitative analysis of responses to the questionnaire sent to surgeons who attended an Ocular Surface Workshop (OSW). (A) % of surgeons happy to share contact details (B) % of surgeons who participated in ocular surface workshop. (C) Participation of surgeons in ocular surface workshops. (D) % of surgeons who have undertaken SLET. (E) Number of SLET surgeries performed.. (F) Assessment of clinical experience of SLET procedures. (G) % of surgeons undertaken CLET and CLAU. (H) % of surgeons having cell culture facilities of CLET. (I) Number of surgeries performed using SLET, CLET and CLAU.

Appendix 3: Costs of SLET and CLET Pathways

Cost data from LVPEI, Hyderabad, India

The costs for India were estimated from the actual tariff costs of the different steps identified from the LVPEI costing database. Because of the mission of L V Prasad Eye Institute (LVPEI) to provide equitable and quality eye care to all sections of society (www.lvpei.org), around 50% of its services are provided free and fee-paying patients can choose between six categories of service as listed in the Table below.

There is no difference in the surgical procedures offered between these categories, but there is a difference in the provision of the associated non-surgical facilities such as the quality of hospital accommodation (please see the discussion for further details). For the base case deterministic analysis, we used the "Private" tariff but the least expensive the "Economy" and the most expensive the "Exclusive" were used to specify the lower and upper bounds for parametric distributions.

Supplementary table 2: Price schedule for fee-paying patients at LVPEI (in Indian Rupees)

Procedure name	Economy	Semi-Private	Private	Deluxe	Premium	Exclusive
Amniotic Membrane Graft Large	10300	17100	34800	53400	53400	86700
Limbal Biopsy	10300	17100	34800	53400	53400	86700
Limbal Transplantation	11700	19400	38900	58500	58500	98300
Stem Cell Transplant	18500	30700	63200	97400	97400	156000
Fibrin Glue	1800	2900	5900	8200	8200	14600
Simple Limbal Epithelial Transplant	19200	31900	67200	100200	100200	161700
General Anesthesia 1 - 15 Minutes	2400	3600	3600	3600	3600	9300
General Anesthesia 31 - 60 Minutes	4700	8200	8200	8200	8200	11600
Room Rent Per Day	1200	2000	3000	4000	4000	11000

Costs for patients receiving CLET

Stay in hospital

For adults receiving CLET, a local anaesthetic is used for the procedure and patients can leave hospital on the same day. As such, we assumed that there is no hospital stay for adults. For children, however, a general anaesthetic needs to be used which requires 1 to 3 days of overnight stay, at a cost of INR 3000 per day (range INR 1200 to INR 11000). Therefore, separate analyses were performed for adults and children.

First Surgery for CLET

At this first surgery, a small section of the limbus is taken for the laboratory expansion of cells. This is done under local anaesthetic for adults (included in surgery costs) and general

anaesthetic for children (mean INR 3600 with a range of INR 2400 to INR 9300). The procedure generally takes less than 30 minutes and the adult patients are discharged from hospital on the same day while the children need hospital stay (see above). The mean costs of this surgery are INR 34,800 with a range of INR 10,300 to INR 86,700. All patients are requested to return when the cells are ready for transplantation, typically two to three weeks later. They are also seen next for a follow up visit, if admitted or not.

Use of amniotic membrane

The amniotic membrane is used as a substrate on which to grow the cells from the limbal biopsy in the laboratory. This is sourced from a tissue bank run to international standards in LVPEI. While human tissue is donated for free clinical use, tissue banks charge a cost to cover the processing and storage of the tissues to help recoup the costs of running the bank. The processing costs associated with the tissue bank used by LVPEI is estimated as INR 2500.

Laboratory expansion of cells

In the case of CLET, cells are expanded on the amniotic membrane prior to transplantation to the eye. The time taken to expand a single biopsy ready for clinical use averages from two to three weeks. Using the daily costs associated with cell culturing of INR 25000 and assuming 17.5 days of cell culture (i.e. average of 2 to 3 weeks), the mean costs were estimated as INR 437,500 with a range of INR 350,000 (estimated assuming 2 weeks) and INR 525,000 (estimated assuming 3 weeks).

Second Surgery for CLET

At this second surgery, the cells that underwent laboratory expansion are transplanted back into the patient's eye after removal of the scar tissue. This is done under local anaesthetic for adults (included in the surgical cost) and general anaesthetic for children (mean INR 8200, range INR 4700 to 11600). The amniotic membrane is held in place with fibrin glue (mean INR 5900, range INR 1800 to INR 14600). A bandage contact lens is applied over the cultured cells at the end of procedure. The mean costs of this surgery are INR 34800 with a range of INR 10300 to INR 86700.

Stay in hospital

This is generally not required for adults where a local anaesthetic is used for the procedure. For children, however, a general anaesthetic needs to be used which is associated with overnight stays of 1 to 3 nights (at a cost of 3000 per day, range 1200 to 11000).

Costs for patients receiving SLET

Stay in hospital

This is not generally required for adults. For children, however, a general anaesthetic needs to be used which requires 1 to 3 days of overnight stays (at a cost of INR 3000 per day, range INR 1200 to INR 11000). As such, separate analyses were performed for adults and children.

Use of amniotic membrane

The amniotic membrane used is the same as for CLET, which is sourced from a tissue bank run to international standards, and the processing costs associated with the tissue bank used by LVPEI is estimated as INR 2500. When used in SLET the membrane provides a biodegradable substrate which is placed on the denuded eye held in place with fibrin glue.

SLET Surgery

At this surgery, the scar tissue from the affected eye is removed and a small piece of tissue from the healthy eye (1-2 mm) is taken and cut into approximately eight pieces. An amniotic

membrane is placed over the denuded eye and held in place with fibrin (as above) and then the pieces of corneal explant are placed on the membrane and held in place with a very small amount of fibrin glue and a bandage contact lens is placed over these. The costs of amniotic membrane and the fibrin glue are the same as for CLET.

This is done under local anaesthetic for adults (costs included in the surgery) and general anaesthetic for children (mean INR 8200, range 4700 to 11600). The procedure generally takes 30 minutes and the mean costs associated with the surgery are INR 34800, and a range of INR 10300 to INR 86700. Adult patients are discharged from hospital on the same day while the children need a hospital stay (see above).

Supplementary table 3: SLET cost data from Dr. Shroff's Charity Eye Hospital, New Delhi, India

Item	Most likely Value (in INR)	Lower estimate	Upper estimate
Costs associated with SLET			
Amniotic membrane	₹ 2,500	₹ 2,400	₹ 2,600
Single SLET Surgery	₹ 50,500	₹ 25,500	₹ 120,500
Fibrin Glue	₹ 10,000	₹ 9,900	₹ 10,100
Bandage contact lens	₹ 2,300	₹ 2,200	₹ 4,500
General anaesthesia*	₹ 5,000	₹ 4,900	₹ 5,100
Hospital stay (in days)*	2	1	3
Hospital costs per day*	₹ 3,000	₹ 1,500	₹ 6,000

*Only for children

Supplementary table 4: Cost data sourced from NICE assessment of Holoclar in England and Wales

Item	Most likely Value	Lower estimate	Upper estimate	Source
Costs associated with CLET				
First CLET Surgery (biopsy)	£864	£750	£950	<u>Minor, Cornea or Sclera Procedure for Biopsy; Day case BZ65Z</u>
General anaesthesia*	£220	£150	£334	<u>Assumed to two thirds as much as private costs</u>
Hospital stay (in days)*	2	1	3	Assumption
Hospital costs per day*	£340	£300	£380	<u>Daily bed cost of excess stay with Very Complex, Cornea or Sclera Procedures with CC Score 0-1 BZ61B</u>
Amniotic membrane	£220	£180	£250	<u>Frozen Amniotic Membrane 2x2cm NHS Blood and</u>

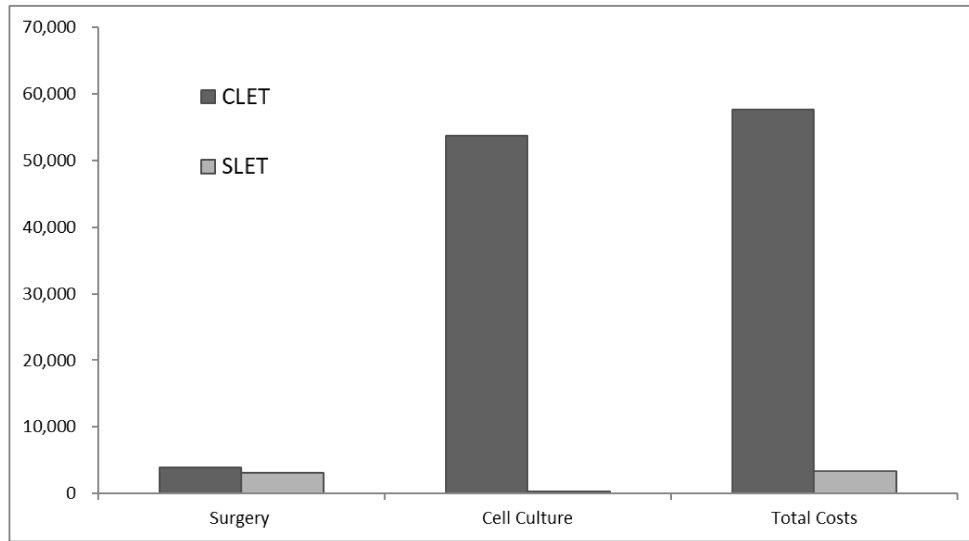
				<u>Transplant</u>
Cell culture	£50,000	£30,000	£80,000	Holoclax
Second CLET Surgery (transplantation)	£3,099	£2,600	£3,500	<u>Very Complex, Cornea or Sclera Procedures with CC Score 0-1, Elective BZ60B</u>
Fibrin Glue	£10	£8	£12	Assumption
Bandage contact lens	£4	£3	£5	Bandage contact lens applied by ophthalmologist
General anaesthesia*	£220	£150	£334	<u>Assumed to two thirds as much as private costs</u>
Hospital stay (in days)*	2	1	3	Assumption
Hospital costs per day*	£340	£300	£380	<u>Daily bed cost of excess stay with Very Complex, Cornea or Sclera Procedures with CC Score 0-1 BZ61B</u>
Costs associated with SLET				
Amniotic membrane	£220	£180	£250	<u>Frozen Amniotic Membrane 2x2cm NHS Blood and Transplant</u>
Single SLET Surgery	£3,099	£2,600	£3,500	<u>Very Complex, Cornea or Sclera Procedures with CC Score 0-1, Elective BZ60B</u>
Fibrin Glue	£10	£8	£12	Assumption
Bandage contact lens	£4	£3	£5	Bandage contact lens applied by ophthalmologist
General anaesthesia*	£220	£150	£334	<u>Assumed to two thirds as much as private costs</u>
Hospital stay (in days)*	2	1	3	Assumption
Hospital costs per day*	£340	£300	£380	<u>Daily bed cost of excess stay with Very Complex, Cornea or Sclera Procedures with CC Score 0-1 BZ61B</u>

*Only for children

Results of the economic analysis in UK

Supplementary table 5: Estimated costs of SLET and CLET in the UK

	CLET	SLET	Average Savings
Surgery	£3,921	£3,076	-845
Cell Culture	£53,432	£216	-53,216
Total Costs	£57,353	£3,292	-54,061



Supplementary figure 2: Estimated costs of SLET and CLET in the UK

Appendix 4: Social impact of SLET

The surgeons suggested that SLET negates the requirement for costly tissue engineering facilities which means it can be offered by more surgeons who do not have access to the specialist laboratories required for the cell-based technique. Hence, it is accessible to more patients who have been treated at clinics that would otherwise lack the expertise, facilities, and approval necessary for the cell culture treatment. Also, they highlighted that SLET requires only a single surgery and is quicker - whereas CLET demands a separate biopsy and transplantation, with surgeries that are separated by at least two weeks for the cells to be expanded in a laboratory. Furthermore, they suggested SLET avoids the risk of contamination associated with ex vivo tissue expansion, involving the use of bovine serum.

Less than 10% of surgeons made specific comments about the technique-the most common comment was that it was less expensive than the previous CLET technique and another comment shared by several was that it was comparatively easy to do .One surgeon made the point that they would like to see longer-term follow-up data before deciding, which is always a consideration with novel techniques (e.g. the same comment was made by NICE about the use of Holoclar) but as Table 1 shows there are now studies with up to 2 years follow-up for SLET. (<https://www.nice.org.uk/guidance/ta467>)