



● *Review Article*

CONTRAST-ENHANCED HIGH-FRAME-RATE ULTRASOUND IMAGING OF FLOW PATTERNS IN CARDIAC CHAMBERS AND DEEP VESSELS

HENDRIK J. VOS,^{*,†} JASON D. VOORNEVELD,^{*} ERIK GROOT JEBBINK,^{‡,§} CHEE HAU LEOW,[¶] LUZHEN NIE,^{||}
ANNEMIE E. VAN DEN BOSCH,[#] MENG-XING TANG,[¶] STEVEN FREEAR,^{||} and JOHAN G. BOSCH^{*}

^{*} Biomedical Engineering, Department of Cardiology, Erasmus University Medical Center, Rotterdam, The Netherlands; [†] Medical Imaging, Department of Imaging Physics, Applied Sciences, Delft University of Technology, Delft, The Netherlands; [‡] M3i: Multimodality Medical Imaging Group, Technical Medical Centre, University of Twente, Enschede, The Netherlands; [§] Department of Vascular Surgery, Rijnstate Hospital, Arnhem, The Netherlands; [¶] Department of Bioengineering, Imperial College London, London, United Kingdom; ^{||} School of Electronic and Electrical Engineering, University of Leeds, Leeds, United Kingdom; and [#] Department of Cardiology, Erasmus University Medical Center, Rotterdam, The Netherlands

(Received 27 November 2019; revised 17 July 2020; in final form 20 July 2020)

Abstract—Cardiac function and vascular function are closely related to the flow of blood within. The flow velocities in these larger cavities easily reach 1 m/s, and generally complex spatiotemporal flow patterns are involved, especially in a non-physiologic state. Visualization of such flow patterns using ultrasound can be greatly enhanced by administration of contrast agents. Tracking the high-velocity complex flows is challenging with current clinical echographic tools, mostly because of limitations in signal-to-noise ratio; estimation of lateral velocities; and/or frame rate of the contrast-enhanced imaging mode. This review addresses the state of the art in 2-D high-frame-rate contrast-enhanced echography of ventricular and deep-vessel flow, from both technological and clinical perspectives. It concludes that current advanced ultrasound equipment is technologically ready for use in human contrast-enhanced studies, thus potentially leading to identification of the most clinically relevant flow parameters for quantifying cardiac and vascular function. (E-mail: H.Vos@ErasmusMC.nl) © 2020 The Author(s). Published by Elsevier Inc. on behalf of World Federation for Ultrasound in Medicine & Biology. This is an open access article under the CC BY-NC-ND license. (<http://creativecommons.org/licenses/by-nc-nd/4.0/>).

Key Words: Cardiac function, Echography, Echo particle image velocimetry, High frame rate, Particle image velocimetry, Ultrafast, Ultrasound contrast agent, Vascular function, Vortex.

INTRODUCTION

Blood flow in large arteries and the left ventricle is known to be an important determinant of cardiovascular function. Both the magnitude and spatiotemporal patterns of flow play a significant role in the diagnosis of vascular abnormalities such as stenosis and aneurysm formation. Moreover, shear stress on the vascular wall appears to have significant effects on endothelial cells, and flow-disturbing or -perturbing geometry such as bifurcations, stenoses and stents could all induce modified shear stress or flow reversion caused by vortices (Ku et al. 1985; Langille and O'Donnell 1986; Malek et al. 1999). Superficial vessels such as the

carotids and jugular veins have been extensively studied with Doppler-based echography because of the easy access and good visibility on conventional echography. However, detailed imaging of flow patterns in cardiac cavities as well as in deeper vessels such as the abdominal aorta, the renal artery or the coronaries is more difficult. We are considering deep vessels located 3–10 cm from the skin that can be imaged with external ultrasound probes, albeit with disturbing factors such as limited acoustic windows and bowel gas. In such vessels, although local magnitudes of flow velocity can be measured over time with echographic pulsed wave Doppler, spatially complex patterns cannot be resolved with current clinical techniques because of the limited signal levels of the blood scattering.

In more recent years, the use of ultrasound contrast agents (UCAs) and dedicated flow imaging technology has been proposed as a method for quantifying and

Address correspondence to: Hendrik J. Vos, Department of Cardiology, Biomedical Engineering, Erasmus MC University Medical Center, Room Ee2302, Erasmus MC, PO Box 2040, 3000-CA Rotterdam, The Netherlands. E-mail: H.Vos@ErasmusMC.nl

visualizing flow dynamics in deep vessels and cardiac applications. This review presents the state of the art on such flow imaging applied to high-frame-rate (HFR) recordings of UCAs in cardiac chambers and deep vessels. We discuss herein the technology, technical realization, hardware systems and imaging considerations specific to this new technology. We also discuss the benefits of HFR imaging of contrast agents to the clinical needs and the future perspective of full 3-D flow quantification and visualization.

BLOOD FLOW PATTERNS

Cardiac flow

In cardiac ventricles, flow patterns play a role in the assessment of valvular (dys)function and the efficiency of contraction. In a healthy heart, the kinetic energy of the left ventricular (LV) inflow is conserved by a large vortex such that upon ejection, blood is more easily expelled into the aortic root (Kilner et al. 2000; Pedrizzetti et al. 2014) (Fig. 1). In a diseased heart, these flow dynamics may be disturbed in a variety of ways, including reduced vortex strength, reduction in kinetic energy or even a complete change of rotational direction (Hong et al. 2008; Abe et al. 2013; Agati et al. 2014). Moreover, valve leakage can result in high-energy regurgitation jets that disturb vortex formation (Morisawa et al. 2018).

Echocardiography is an important clinical modality for the assessment of different aspects of cardiac function, including the effects of a broad range of

cardiovascular diseases. In current clinical routine, LV systolic and diastolic function is assessed by myocardial wall motion and deformation and by measuring the mitral inflow, aortic valve outflow and valvular leakage, in an apical view. These flows are quantified with spectral, pulsed wave and color Doppler echography, which are techniques that can only provide the flow velocity along the axial direction and in a limited field of view. As such, these conventional Doppler techniques fit, in apical view, the dominant direction of these conventional flow parameters. However, to represent more complex ventricular blood flows such as listed above, the unidirectional sensitivity presents limited information with the possibility of misinterpretation and/or insufficient sensitivity for detecting abnormal flow.

A potentially complementary approach is to analyze the full intraventricular blood flow for the assessment of LV function. Such flow might be parameterized by assessment of vortex parameters, kinetic energy, pressure gradients and/or principal force axes (Pedrizzetti 2019). However, there is no clear understanding of which parameter should be measured in cardiac diseases and what the incremental value of, for example, vortex and energy evaluation is over other echocardiographic indices and biomarkers. Some studies suggest that intraventricular vortex evaluation could determine the presence of an abnormal cardiac function (Abe et al. 2013; Pedrizzetti et al. 2014; Arvidsson et al. 2016). In dilated cardiomyopathy, where the LV geometry is altered and the intraventricular vortex is located at the center of the left ventricle during diastole, is wider and rounder and persists longer than in healthy patients (Eriksson et al. 2012). In patients with acute myocardial infarction, measurements of kinetic energy of the flow might help in differentiation of left ventricles with different infarct extension (Agati et al. 2014). It is also known that valvular heart disease changes the vortex configuration and increases dissipative energy loss. For example, diastolic energy loss increases in aortic regurgitation proportionally to its severity, and the energy loss index provides independent and prognostic information additional to that derived from conventional measures of aortic stenosis severity (Pedrizzetti et al. 2010; Stugaard et al. 2015). Although the intraventricular vortex and the energetic efficiency seem to affect the patient's outcome, no clear views on the underlying mechanisms have yet been presented.

The above calls for accurate imaging and quantification of blood flow, such that several characteristic parameters can be determined from the velocity fields. Most suitable candidates appear to be vortex position (the location inside the chamber of the center of the main vortex); vortex morphology (width, height, sphericity); vortex strength; vortex direction (clockwise or

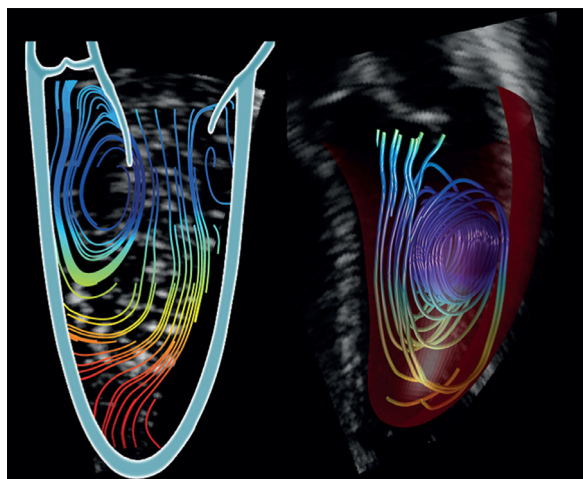


Fig. 1. Left ventricular flow patterns as obtained by echocardiographic recordings of intraventricular swirling flow in healthy individuals. Left: Streamlines during late diastolic filling. The vortex is visible behind the anterior mitral leaflet. Right: 3-D streamlines reconstructed from multiplane acquisition at the onset of systole. The streamlines spiral out from the vortex and are directed toward the outflow tract. Reprinted with permission from Pedrizzetti et al. (2014).

anti-clockwise in a particular view); kinetic energy (system energy stored in moving blood); kinetic energy dissipation (kinetic energy lost to heat); and local pressure gradients. However, the currently insufficient frame rates of clinical machines cause the absolute velocities to be underestimated. How the sensitivity of these flow parameters is affected by this velocity underestimation during filling and ejection has yet to be evaluated. Important information relating to clinical outcome may be hindered by the inaccurate velocity estimation, thus reducing sensitivity to disease initiation or progress.

Vascular flow

Another important area in which flow visualization using ultrasound is a trusted tool is within the field of vascular surgery. The technique is heavily applied throughout the pre-, peri- and post-operative stages, and treatment decisions are in part based on the outcome of ultrasound measurements; however, the limitations of cardiac ultrasound also apply to the vascular setting, hampering a detailed analysis. For the flow in the vascular system, the relation between hemodynamic forces and (patho)physiologic remodeling has been known for more than a century (Langille and O'Donnell 1986). Pathophysiology is attributed mainly to the development of aneurysms and atherosclerosis (Zarins *et al.* 1983). Atherosclerosis is associated with multiple systemic risk factors, but it is geometrically predisposed, that is, more likely to occur in regions with complex geometries such as bifurcations (Malek *et al.* 1999). Blood flow creates a frictional force (because of its viscous properties) on the vessel wall, known as wall shear stress (WSS). Low and oscillatory values of WSS are atherogenic and thrombogenic, while high values are atheroprotective. Mapping between atherosclerotic lesions and areas of low and oscillatory WSS have confirmed this link throughout the vascular tree, including the abdominal aorta (Ku *et al.* 1985). Identifying and monitoring these areas in patients could help to optimize localized-treatment planning. Furthermore, monitoring WSS post-intervention could indicate areas vulnerable to restenosis. While pioneering lab work has been done using invasive measurement methods, a reliable clinically applicable method (at low cost per scan) for obtaining WSS values before or after treatment is required. Measurement of WSS *in vivo* is vulnerable to errors, as sampling of low blood flow velocities near the walls is a challenge (Poelma 2017). Therefore, as an intermediate step, surrogate measures such as blood residence time, recirculation and platelet activation potential could serve as indicators for lesion progression or stent failure. In addition, blood flow quantification could play a substantial role in predicting the development of thrombus formation in abdominal aortic aneurysms. Thrombus formation has recently been introduced as a predictor for increased risk of aneurysm rupture, because

oxygenated arterial blood cannot reach the inner layer of the vessel wall, in turn creating vessel wall hypoxia and further weakening of the vessel wall. The formation of thrombus has been linked to a combination of vessel geometry and blood flow perturbations (Hathcock 2006). Therefore, quantifying blood flow in patients at an early stage is of high value while it can provide risk assessment for developing thrombus formation and in turn increased rupture risk at an early stage. This requires blood flow visualization (preferably in three dimensions) with a high spatial and temporal resolution.

NATIVE BLOOD FLOW IMAGING

Currently, non-contrast ultrasound techniques are being developed to depict the flow structure in the lateral direction in the left ventricle (Garcia *et al.* 2018) and in larger, superficial vessels (Jensen *et al.* 2016a, 2016b). For clarity, in the course of this review, we refer to any technique that supplies two- or three-component velocities (2-C or 3-C) over a plane (2-D) or volume (3-D) as a *vector flow imaging technique*; these are differentiated from standard ultrasound Doppler approaches in which only the axial component (1-C) is measured, even if this component is measured over a whole 2-D plane (Bercoff *et al.* 2011) or 3-D volume (Provost *et al.* 2014; Holbek *et al.* 2018).

For vector flow imaging, currently, there is one non-contrast technique using magnetic resonance imaging (MRI) based on phase contrast MRI (PC-MRI) and four primary non-contrast echographic techniques: vector Doppler, transverse oscillations, vector flow mapping (VFM) and blood speckle tracking (BST).

MRI-based flow measurements are the reference standard for assessing intracardiac and vascular flow patterns and velocities without contrast medium. It can provide detailed flow fields over time in both two dimensions (usually referred to as PC-MRI) and three dimensions (called 4-D-flow MRI), and the blood flow velocities can be measured in all three spatial dimensions. However, its temporal resolution is usually limited (~20–30 phases per heartbeat) and patterns are averaged over many (100+) cardiac cycles.

Vector Doppler, in its initial form (Kripfgans *et al.* 2006; Tortoli *et al.* 2015; Jensen *et al.* 2016a), uses two steered ultrasound beams to measure the blood flow velocity components along these two directions. The vector field can then be triangulated using the different angled Doppler estimates (Tortoli *et al.* 2015; Au *et al.* 2019; Saris *et al.* 2019). Vector Doppler has also been extended to use an arbitrary number of transmit/receive angles, where a least-squares fitting of the computed directional Doppler velocities is used to generate the 2-D (Yiu and Yu 2016) or 3-D (Correia *et al.* 2016) velocity fields. However, vector

Doppler is limited in depth because of loss of lateral velocity accuracy as the depth of interest increases relative to the limited aperture size, reducing the angle between different directional Doppler acquisitions. Human blood flow imaging studies have been performed in the femoral artery (Au et al. 2019) and the carotid artery (in two dimensions [Tortoli et al. 2015; Saris et al. 2019; Au et al. 2020] and three dimensions [Correia et al. 2016]). Vector Doppler has also been used in combination with ultrasound contrast agent microbubbles to image urinary flow dynamics (Ishii et al. 2020).

A similar technique is called transverse oscillations, which transmits a single beam and then generates a transversely oscillating field by applying two separated apodization functions in receive (Jensen and Munk 1998). Both the axial and lateral velocity components can then be extracted based on axial and lateral phase changes. In principle, the technique requires a relatively large transducer aperture to allow sufficient distance between the separate virtual apertures. Transverse oscillations has been reported to achieve accurate results in superficial vessels and has been used to study flow in varicose veins (Bechsgaard et al. 2018), the ascending aorta (peri-operatively) (Hansen et al. 2013, 2020), the carotid artery (in two dimensions [Jensen et al. 2018] and three dimensions [Holbek et al. 2016, 2017]) and the femoral artery (Hansen et al. 2019). The smaller footprint of phased array transthoracic probes might hamper its use in echocardiography, although phased array implementations have been developed but use focused transmit beams, reducing the achievable frame rate (Pihl et al. 2012; Holbek et al. 2018).

Vector flow mapping (VFM) in echocardiography uses standard color Doppler acquisitions and (optionally) LV wall motion segmentations, and assumes various continuity assumptions, such as fluid incompressibility and mass conservation (Assi et al. 2017) to calculate the lateral velocity components in the left ventricle (Ohtsuki and Tanaka 2006; Garcia et al. 2010; Uejima et al. 2010). VFM has the advantage that data can be acquired using standard clinical ultrasound scanners and post-processed offline. However, an important limitation is the assumption of minimal out-of-plane flow, which only holds for certain planes (three-chamber view [Garcia et al. 2010]) in non-disease situations. Furthermore, careful attention must be paid when choosing wall filter and velocity cutoff settings of the color Doppler data to prevent erroneous VFM results. VFM is sensitive not only to out-of-plane flow but also to boundary conditions (wall motion and blood–wall interaction) (Assi et al. 2017).

Blood speckle tracking (BST) estimates 2-D or 3-D blood velocities by tracking blood speckle patterns over time, generally by block matching (Jensen et al. 2016a; Poelma 2017). Blood speckle consists of the weak

interference pattern caused by the summation of the scattering of the red blood cells, acting as sub-resolution scatterers (Wagner et al. 1983). The displacement of the speckle pattern is assumed to reflect the underlying motion of the blood cells (Swillens et al. 2010). BST has been used to image cardiac blood flow patterns in neonates (Fadnes et al. 2014), pediatric patients (Fadnes et al. 2017) and even adults (Takahashi et al. 2014), and to image flow patterns in the great saphenous vein (Lee et al. 2018). BST has also been performed in three dimensions in the left ventricles of volunteers using a matrix transducer (Wigen et al. 2018). However, BST is challenging because the use of HFR imaging results in poor signal-to-noise ratio (SNR) (Ekroll et al. 2018) and increased clutter levels (high-intensity signal in the blood arising from surrounding tissues) (Fadnes et al. 2015). The lower SNR is a result of the spreading of the acoustic energy over the wider field of view. BST has been implemented commercially as “blood speckle imaging” in the GE Vivid E95 system, but it is recommended that depth be limited to <8 cm (Nyrmes et al. 2020), reducing its value for adult cardiac imaging.

The ability to perform vector flow imaging has been accompanied by new methods of visualization, such as *vector projectile imaging* (Yiu et al. 2014) and *flow path* (Yiu and Yu 2016; Wigen et al. 2018) visualization, which aid with interpretation of the complex spatiotemporal flow measurements.

ULTRASOUND CONTRAST-ENHANCED BLOOD FLOW IMAGING

Ultrasound contrast agents as tracers

To overcome clutter and improve visualization of the blood pool, UCAs have been developed. These agents consist of micrometer-sized coated bubbles that are injected intravenously. The gas inside has much larger compressibility than blood and tissue, and the microbubbles respond to ultrasound with resonant volumetric oscillations, thus strongly scattering the ultrasound as a secondary source. As microbubbles respond non-linearly to the ultrasound field, contrast detection sequences have been developed to further separate the microbubble signals from tissue. In this way, ultrasound systems can enhance the contrast signals and provide a clear opacification of the LV cavity or vascular lumen (Whittingham 2005; Averkiou et al. 2020). At lower contrast agent concentrations, the contiguously enhanced area of contrast signal breaks up into a rough pattern or even isolated scatterers. These intensity patterns flow with the blood, thus providing a potential mechanism to qualify and quantify blood velocity vectors in the left ventricle (Fig. 1) and vessels. This idea has led to automated tracking of these patterns through application of

echo particle image velocimetry (echoPIV, also called echo-PIV, e-PIV or ultrasound image velocimetry) over the past 15 y (Kim *et al.* 2004; Zheng *et al.* 2006; Sengupta *et al.* 2007; Hong *et al.* 2008; Liu *et al.* 2008; Westerdale *et al.* 2011; Poelma *et al.* 2011; Zhang *et al.* 2011; Piro *et al.* 2012; Prinz *et al.* 2012; Poelma and Fraser 2013).

Echo-particle image velocimetry

Echo particle image velocimetry or speckle tracking estimates the local flow motion *via* optical flow (Quénot *et al.* 1998; Ruhnau *et al.* 2005) or block matching (Trahey *et al.* 1987). The latter is most commonly used as it performs better for larger displacements. The basic principle of echoPIV tracking is illustrated in Figure 2. Two subsequent images are divided into small interrogation windows (sub-images) and a similarity measure is computed between subsequent windows to reveal the average displacement in each window. The similarity measure used differs from study to study, but 2-D cross-correlation is most often performed because of its computationally efficient implementation in the frequency domain (sum of square differences is another popular measure). Although

the average displacement (in pixels) between two windows can be determined by locating the peak in the correlation map, subpixel displacement estimation is normally achieved by a peak fitting algorithm based on a parabolic, Gaussian or centroid profile (Raffel *et al.* 2007). This is essentially the PIV algorithm in its most basic form, which considers only a linear translation and no rotation. The flow directions can be recovered by this first-order estimation. To refine the tracking accuracy and deal with higher-order deformation, several advanced techniques developed in Optical PIV (Scarano 2002) have been adapted to ultrasound, including multigrid and/or multipass interrogation, window deformation and ensemble correlation (Liu *et al.* 2008; Zhang *et al.* 2011; Leow *et al.* 2015; Leow and Tang 2018). Other techniques that involve flow-field regularization through Navier–Stokes regularization (Gao *et al.* 2015) or mass conservation assumption (Zhou *et al.* 2019a) have also been reported to enhance the robustness of speckle tracking.

Conventional echoPIV

Originally, echoPIV was applied to ultrasound images acquired using line scanning of focused

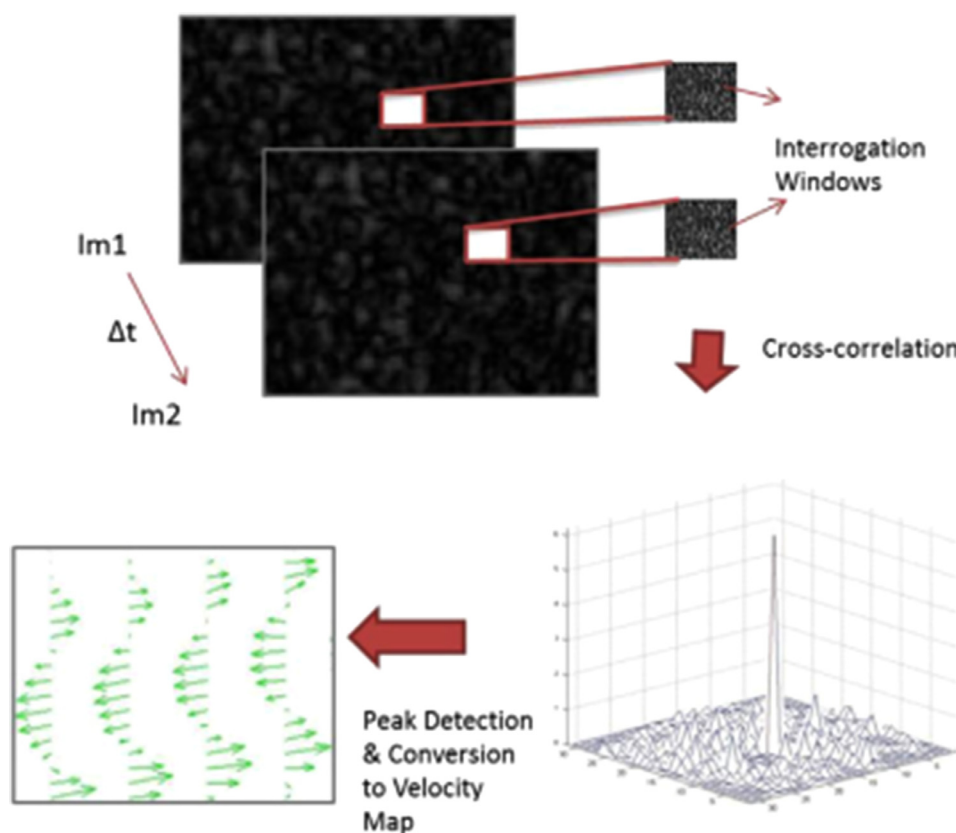


Fig. 2. Principle underlying conventional particle image velocimetry: Two consecutive ultrasound images are divided into several interrogation windows. For each window, cross-correlation analysis is performed to compute a local velocity displacement. The location of the peak within the correlation map is identified and displayed on the velocity map.

Reprinted with permission from Leow *et al.* (2015).

transmissions. This limited the maximum frame rates attainable and hence the maximum measurable velocities (as discussed in the next section). There are several review articles dealing with echoPIV using current clinically achievable frame rates of up to 100 frames/s (Sengupta et al. 2012; Rodriguez Muñoz et al. 2013; Pedrizzetti et al. 2014; Poelma 2017; Mele et al. 2019).

There currently are two commercial echoPIV packages for analyzing the images of LV flow: the Omega Flow (Siemens, Mountain View, CA, USA) and Hyper-Flow software (Advanced Medical Imaging Development, Sulmona, Italy) (Abe et al. 2013; Goliasch et al. 2013; Agati et al. 2014; Kutty et al. 2014; Pedrizzetti et al. 2014; Mele et al. 2019). They have been validated in several studies (Kheradvar et al. 2010; Gao et al. 2012; Prinz et al. 2012). In these validation studies, one of the main results was the underestimation of high velocity values, especially >40 cm/s (cf. Fig. 3), present during the filling and ejection periods of the cardiac cycle. The most accurate results were obtained with a compromise between frame rate and image quality, with a recommended frame rate ≥ 60 frames per cardiac cycle. Moreover, the imaging parameters should be set such that the contrast microbubbles appear homogeneously distributed within the region of interest.

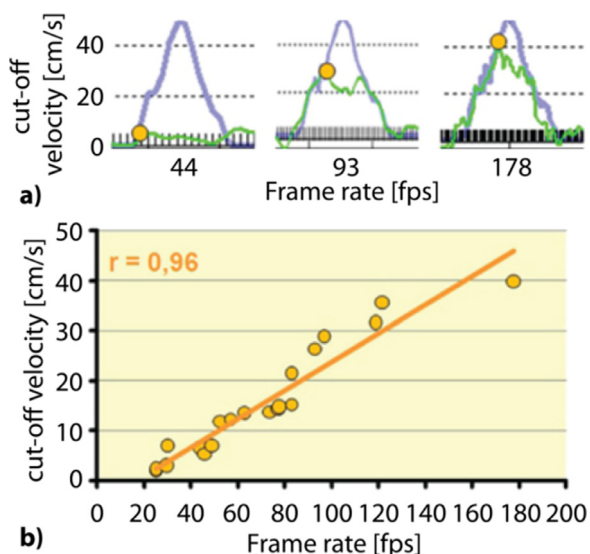


Fig. 3. Maximal velocities trackable by echo particle image velocimetry (echoPIV) for different frame rates. (a) Blue curve indicates transmittal jet velocity acquired with pulse-wave Doppler. EchoPIV-derived velocities (green curves) are more accurate for higher frame rates, as seen by better agreement between the blue and green curves from left to right. (b) Correlation between maximum trackable velocity (using echoPIV) and acquisition frame rate. Adapted with permission from Prinz et al. (2012).

HFR ECHOPIV

Frame rate requirements

EchoPIV poses certain conditions on the flow and frame rate for an accurate outcome. The technique relies on relatively small displacements of the scatterers between two consecutive frames and on a preserved speckle pattern (e.g., Adrian and Westerweel [2011, Ch. 8]). Thus, large displacements and/or high gradients in the flow will be more challenging for a system with limited frame rate, as the scatterer distribution can change significantly between two subsequent frames, and consequently, the speckle pattern will be significantly different.

The correlation between the patterns in the subsequent frames is also lost if particle displacement is too large between frames so that the algorithm cannot track the correct velocity magnitudes (Kheradvar et al. 2010; Gao et al. 2012; Prinz et al. 2012). Figure 3 illustrates this effect; higher velocities (“cutoff velocity” in Fig. 3a) can be tracked with higher frame rates. Velocities above this cutoff are tracked with severe underestimation. The underestimation can easily occur when attempting to quantify the transmittal inflow jet (having velocities of about 1 m/s) with frame rates of around 100 frames/s, which is the current state of the art in clinical applications. Moreover, various diseases (aortic and mitral regurgitations, stenotic lesions in the arterial system) lead to higher flow velocities, which are thus even more difficult to detect.

The beam-sweeping process of a conventional line-by-line scanning ultrasound system and the sweeping direction have been reported to introduce significant errors into flow velocity estimation using echoPIV (Zhou et al. 2013). This is caused by speckle elongation for lateral flow that travels with the beam scan direction and speckle shortening for lateral flow in the opposite direction. Thus, velocity is overestimated when the beam sweeps in the same direction as the flow direction, whereas underestimation occurs in the opposite case. A correction method for steady flow has been proposed (Zhou et al. 2013); however, this cannot be applied to a physiologic flow that is pulsatile and multidirectional.

Higher flow velocities can be detected by increasing the frame rate, up to about 5000 frames/s in cardiac and 8000 frames/s in vascular, which is the theoretical frame rate limit based on the round-trip time of the ultrasound echoes in echocardiography (depth limit of about 15 cm) or vascular echography (depth limit of about 10 cm). However, such high frame rates can only be attained with a single-shot single-image approach, as opposed to the conventional line-by-line scanning. Single-shot single-image systems require specialized detection schemes with a massive amount of data acquisition and processing.

HFR systems

Advances in micro-electronics have allowed for introduction of several experimental and commercial systems that capture all data from the ultrasound probe and process those data with massive parallel computing power either online or offline (Boni *et al.* 2018) to form one full image per shot. With such systems, the frame rates can reach values close to the theoretical limit at sufficient spatial resolution. These systems typically use unfocused wave transmission and parallel receiving to form one single image from the received echoes. The surge of interest in HFR contrast-enhanced ultrasound relies on the use of open platforms that support arbitrary sequencing of transmit and receive on each channel. Several custom platforms have been developed (Boni *et al.* 2018), as have several commercial systems (V1 and Vantage by Verasonics Inc., Kirkland, WA, USA; Prodigy and Prospect T1 by S-Sharp Corp., New Taipei City, Taiwan; SonixRP and SonixTOUCH with external SonixDAQ by Ultrasonix/BK Medical, Richmond, BC, Canada). Albeit more expensive than regular mass-produced clinical systems, the programmability and availability of these systems have accelerated the studies on and with HFR echography. A key technical challenge in the clinical roll-out of HFR ultrasound imaging is the sheer volume of sampled data being received from the transducer that needs temporary storage and further real-time processing of data captured in a few seconds. The real-time processing would respect the goal of producing continuous real-time vector flow imaging to improve workflow in the clinical routine.

Open ultrasound platforms suitable for HFR imaging can be grouped into two types. The software-based open platforms (Boni *et al.* 2018) implement fast image reconstruction through multipurpose computer processing units, that is, central processing unit (CPU) or graphics processing unit (GPU). When transmitting unfocused plane/diverging waves, the acceleration with a GPU enables continuous real-time beamforming (Boni *et al.* 2018). The hardware-based open platforms (Boni *et al.* 2018) use specialized hardware for data processing. For example, by exploiting the computing capability of onboard field programmable gate array and digital signal processor devices that are programmed by firmware, HFR ultrasound imaging with the vector flow overlay could be performed in real time without any acquisition interruption (Ricci *et al.* 2017; Boni *et al.* 2018).

Vascular HFR echoPIV

In the current workflow for vascular pathology, UCAs are used regularly by bolus injection, mostly post-interventional to check for leaks around the stent graft (endoleaks). It has been reported that the sensitivity and

specificity for detecting endoleaks with contrast-enhanced echography outperform those of CT angiography-based analysis (Lowe *et al.* 2017). Other applications include imaging of the *vasa vasorum* for assessing plaque vulnerability and diagnosis of intestinal ischemia. Also, peri-operative usage is starting to emerge (Mehta *et al.* 2017). As in cardiac applications, automated tracking of the contrast pattern is emerging. These include imaging of the carotid bifurcation in humans (Zhang *et al.* 2011) and the abdominal aorta in animals (Leow *et al.* 2015) and assessment of WSS *in vitro* (Leow and Tang 2018) and in human volunteers (Gurung *et al.* 2017). Another recent study reported the feasibility, in human volunteers, of acquiring full flow fields in the abdominal aorta (Fig. 4) (Engelhard *et al.* 2018). As Gurung *et al.* (2017) reported for the carotids, this study also found good agreement of echoPIV with phase contrast MRI measurements for the temporal center velocity profiles and the radial velocity profiles. Contrast agent-specific settings have been studied in the abdominal aorta as well (Voorneveld *et al.* 2018a).

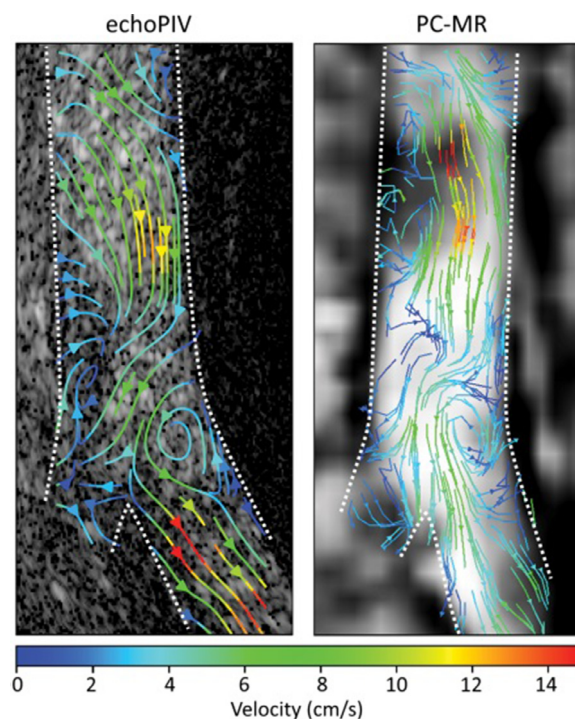


Fig. 4. Streamline representation of blood flow velocities during early diastole of the abdominal aorta of a volunteer. Left: High-frame-rate contrast-enhanced echography. Right: Phase contrast magnetic resonance imaging. Similar flow patterns can be observed, including a slow (counterclockwise) recirculation zone near the origin of the left common iliac artery. *Dashed lines* indicate estimated delineation of the vessel wall. echoPIV = echo particle image velocimetry; Reprinted with permission from Engelhard *et al.* (2018).

Note that the frame rate using line scanning could be increased by reducing the field of view (depth and width) as well as the line density (within the limits of the clinical ultrasound machine). By limiting the field of view, some studies have been able to accurately measure high flow velocities but noted that careful optimization was required to obtain accurate near-wall velocities for WSS calculation (Zhang et al. 2011; Poelma et al. 2012; Walker et al. 2014). However, reducing the field of view is not a viable option for cardiac and deep vessel imaging.

Left-ventricular HFR echoPIV

Toulemonde et al. (2018a) were the first to report that HFR contrast-enhanced echocardiography could produce images of superior quality to conventional line-scanning

contrast-enhanced echocardiography, in the left ventricle of a sheep. Toulemonde et al. (2018b) obtained similar results in human volunteers but also found that HFR echoPIV was feasible with the data. The accuracy of HFR echoPIV for LV applications has been studied *in vitro* using a dynamic LV phantom, where it was found that the high velocities expected in the transmitral jet (~ 1 m/s) could be measured accurately (Voorneveld et al. 2018b). Voorneveld et al. (2019) used HFR echoPIV in a patient, where the measured transmitral jet velocities corresponded to pulsed wave-Doppler measurements used as reference (Fig. 5).

Validation techniques

Validation of echoPIV is a critical step for its clinical translation and acceptance, although this is

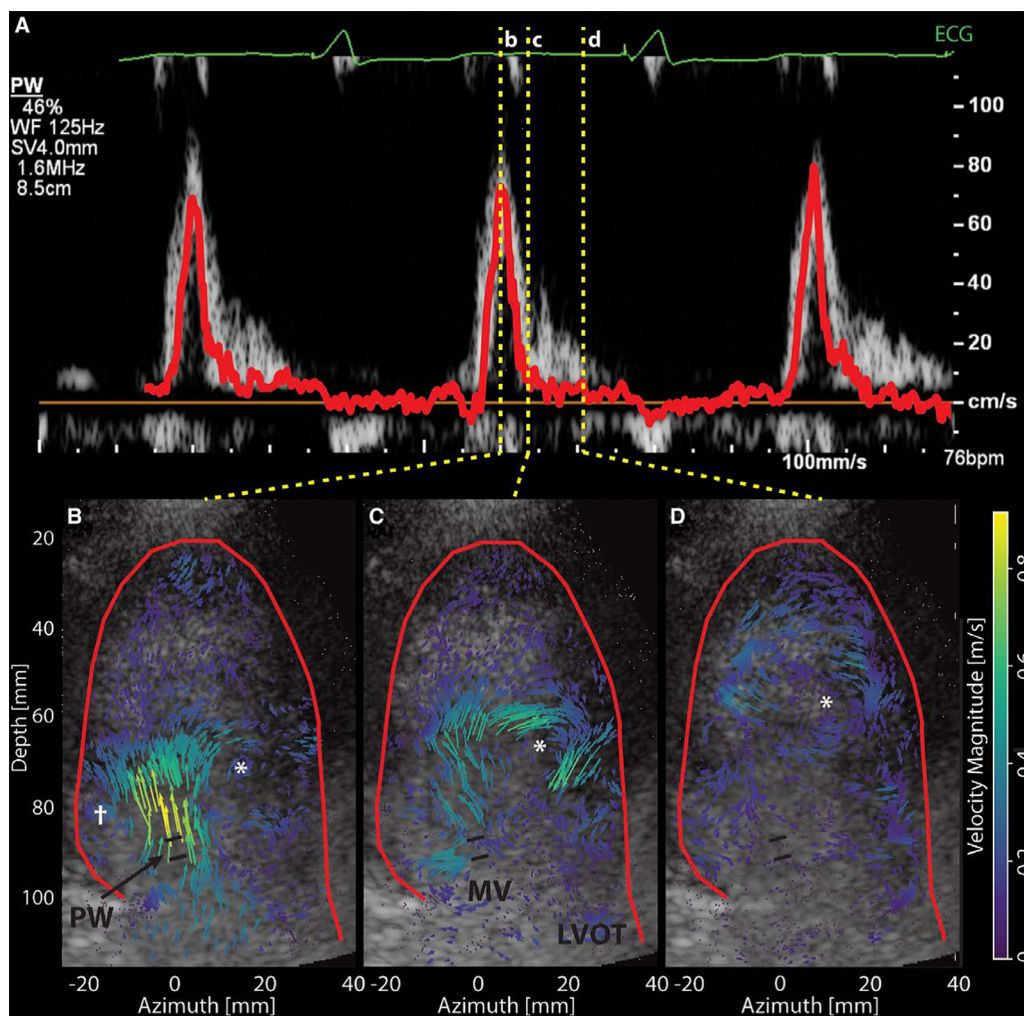


Fig. 5. High-frame-rate echoPIV in the left ventricle. (a) Mean echoPIV velocity (red) overlaid on pulsed-wave Doppler spectrogram obtained in the mitral valve region (see PW in b). (b–d) Velocity map visualization during diastolic filling (temporal locations marked in a), revealing the high-velocity transmitral jet entering the ventricle (b) and central clockwise vortex (*) that starts basally and migrates apically (c, d). MV = mitral valve, LVOT = left ventricular outflow tract. A female patient with dilated cardiomyopathy and dual-chamber pacemaker defibrillator (DDD-ICD); frame rate = 1225 Hz. Reprinted with permission from Voorneveld et al. (2019).

not a straightforward task given that reference velocimetry techniques might have their own limitations. The most convenient method for validation is simulation studies, as the true velocity distributions are known exactly and precise alignment of the measured and expected velocity values makes bias and variance estimation straightforward (Leow and Tang 2018). However, the transferability of findings to clinical conditions is relatively weak for simulation studies, which often do not model many of the complex physiological phenomena present in biological systems.

Alternatively, *in vitro* models have been used to perform validation studies, such as simple laminar (Poiseuille) flow phantoms (Kim *et al.* 2004; Voorneveld *et al.* 2016), or pulsatile (Womersley) flow phantoms (Leow *et al.* 2015), where analytical solutions of the flow profile can be calculated using a measured flow rate. More representative flow dynamics have been produced using anatomically realistic models, such as carotid bifurcation phantoms (Zhang *et al.* 2011; Leow and Tang 2018) and left ventricle phantoms (Kheradvar *et al.* 2010; Gao *et al.* 2012; Voorneveld *et al.* 2018b). However, the use of more realistic models comes at the cost of more complicated methods of acquiring the true velocity data (such as optical PIV and numerical modeling) and less certainty in the alignment and/or accuracy of the ground truth values. Obviously, clinical applicability is still not perfect where physiologic conditions, such as temperature, pressure, acoustic attenuation and aberrations, are not often taken into account.

In vivo validation of vector flow imaging is not trivial as a perfect ground truth reference is not available. PC-MRI is capable of measuring all three components of blood velocity over a large region of interest in either a 2-D slice or 3-D volume, but requires hundreds of heartbeats to produce a single acquisition, thus averaging out cycle-to-cycle variations that may be present in echoPIV recordings. In addition, PC-MRI has limited temporal resolution (<30 phases per heartbeat), which also makes comparison with HFR echoPIV difficult. Nevertheless, *in vivo* comparison has been performed between HFR echoPIV and PC-MRI in the abdominal aortas of healthy volunteers (Engelhard *et al.* 2018). The disadvantage of using PC-MRI in this case was that the echoPIV scans and MRI scans were performed on different days and so there is a chance that blood flow differed between acquisitions, confounding analysis. However, the results indicated good agreement on the major flow aspects between these two techniques (*cf.* Fig. 4). An alternative method is to use pulsed wave Doppler echography in key locations and compare the results with the echoPIV-derived values in those same locations (Voorneveld *et al.* 2019). This has the advantage that data are acquired

in close succession and, thus, under similar physiologic conditions, but it limits the scope of comparison to several points of interest only and generally to a single direction. Another alternative may be patient-specific computational modeling of the flow, if accurate boundary conditions can be acquired, but this technique requires validation first.

Contrast-specific pulse sequences

Contrast/speckle detection schemes may differ depending on how the ultrasound images were acquired. Studies of HFR echoPIV have been performed *in vivo* using both linear fundamental (B-mode) imaging (Zhang *et al.* 2011; Engelhard *et al.* 2018) and contrast-specific imaging (Leow *et al.* 2015; Toulemonde *et al.* 2018a; Voorneveld *et al.* 2018a) approaches. The speckle generated from the microbubbles can be readily distinguished from the tissue signal when contrast-specific imaging is used, whereas additional clutter filtering is needed to extract the contrast/blood signal from surrounding tissue in B-mode imaging. On the other hand, a higher temporal resolution can be achieved by B-mode imaging as the number of transmitted pulses per B-mode image is usually two to three times less than that in contrast-specific imaging; this is caused by the contrast-specific sequencing methods, which generally take two or three pulses to suppress linear tissue response while maintaining the non-linear contrast signal.

Microbubble concentration

Next to the imaging frame rate and details in image reconstruction, microbubble concentration is another parameter that could potentially affect the velocity estimation of HFR echoPIV. Too low a concentration could result in blind areas not covered by the microbubbles, while too high a concentration may cause multiple scattering and non-linear artifacts (Stride and Saffari 2005; Tang and Eckersley 2006) and acoustic shadowing. It is difficult to formulate straightforward guidelines as the concentration of microbubbles changes as a function of time, and the response of microbubbles changes with ambient pressure. For conventional line scanning (low frame rate) echoPIV, the optimal concentration for *in vitro* experiments was found to be in the range of 10^3 microbubbles/mL, whereas the concentration for *in vivo* experiments was in the range of 10^5 microbubbles/mL (Kim *et al.* 2004; Niu *et al.* 2011). However, for HFR echoPIV, there is no consensus on the optimal microbubble concentration to use, and there is limited information on the effect of microbubble concentration on the tracking results. Leow *et al.* (2015) used a 0.1-mL bolus injection of SonoVue (Bracco Imaging, Geneva, Switzerland) in a rabbit model for aortic imaging, which equates to

about 10^5 microbubbles/mL—assuming a 260-mL blood volume and a bolus of 100–500 million microbubbles/mL. However, Engelhard et al. (2018) used a 0.25-mL bolus injection of SonoVue in human volunteers for abdominal aortic imaging (roughly 10^4 microbubbles/mL, assuming a 4.7-L blood volume). Toulemonde et al. (2018b) used a continuous infusion of SonoVue at 1.2 mL/min ($\sim 10^5$ microbubbles/mL·min) in human volunteers for cardiac imaging.

Voorneveld et al. (2018a) tested four bolus volumes (0.25, 0.5, 0.75 and 1.5 mL) of SonoVue for abdominal aortic imaging in healthy human volunteers and used the average tracking correlation value as a measure for optimization. The effect of bolus volume on the correlation values was relatively minor, but it was noted that for fast flows during systole, lower correlations were observed for higher bolus volumes, whereas for slow flows during diastole, higher bolus volumes resulted in higher correlation values. It was noted that lower bolus volumes would result in zones without any microbubbles during diastole because of microbubble destruction during the slow flow periods, when less replenishment from upstream occurs than during systole.

The administration of UCA can be done either by bolus injection or by continuous intravenous infusion at low doses, where bolus injection is practically simpler to realize but the UCA concentration must be monitored to ensure that data are acquired at the desired concentration. Continuous infusion requires specialized contrast pumps (e.g., VueJect BR-Inf 100, Bracco Imaging), but has the advantage that optimal UCA concentration, when known, can be held constant over longer scan durations.

The aforementioned values might serve as a starting point for first choice of concentration when new applications of HFR echoPIV are explored; however, it is strongly recommended that a pilot study be executed first to establish the range of UCA concentration for good performance of echoPIV processing.

Acoustic pressure

For echoPIV analysis, acoustic pressure as parameterized in the mechanical index (MI) needs to be controlled to maintain microbubble concentration over time. Microbubble destruction can have a strong impact on echoPIV measurement as both the signal amplitude decreases and the speckle changes. In HFR imaging, the microbubbles are irradiated more often than in the conventional line scanning method. The combined effect calls for a relatively low MI. Because of regular tissue attenuation and the broader beams used in HFR echography, the acoustic pressure near the probe—typically the apex in an apical cardiac view—is much higher than deeper in the tissue. Thus, the microbubbles close to the probe can be more significantly disrupted at an acoustic MI >0.1 (Toulemonde et al. 2017). In

abdominal imaging, it has been reported that significant microbubble destruction can even occur with MIs >0.06 (Engelhard et al. 2018; Voorneveld et al. 2018a). These are relatively low MI values, at which level system noise is a dominant factor for loss of contrast, thus reducing image quality and sensitivity to the UCA signal (Voorneveld et al. 2018a). As this noise is highly uncorrelated it can be somewhat suppressed through singular value decomposition filtering (Voorneveld et al. 2018a).

Improving sensitivity and resolution

The sensitivity and resolution of HFR imaging can be increased by combining multiple plane waves or diverging waves transmitted at several angles. The approach that combines multiple low-resolution images to form a high-resolution image is known as *coherent compounding* and was first found by Montaldo et al. (2009) to improve image quality at the cost of lower frame rate. Thus, a trade-off between the number of compounding/averaging frames and achievable frame rate should be carefully considered. Similarly, for flow tracking using HFR echoPIV, the image quality is important as the correlation analysis is improved by the better SNR and resolution of the flow speckle after compounding. However, large motion can make coherent compounding less effective as such compounding techniques assume stationary targets and large displacements will generate decorrelation artifacts, degrading image quality (Nie et al. 2019; Stanziola et al. 2019). To avoid speckle decorrelation, particularly under fast and accelerating flow conditions, the incoherent ensemble correlation (also called *correlation compounding*) approach has been proposed. Instead of cross-correlating the compounded images, it performs cross-correlation between the uncompounded images per angle and compounds the cross-correlation maps to generate a sharp displacement peak. It has been reported (Figs. 6 and 7) to enhance the robustness of echoPIV tracking (Leow and Tang 2018; Toulemonde et al. 2018a; Voorneveld et al. 2018b). Comparison in a carotid flow phantom (Fig. 6) reveals that the incoherent ensemble correlation leads to higher tracked velocities in high-velocity flow regions than the coherent ensemble correlation. Likewise, Figure 7 illustrates that tracked peak mitral inflow velocity is higher with compounding in the correlation domain than in the spatial domain.

Another approach to deal with tissue and microbubble motion and their effect on coherent compounding is motion correction/compensation. Such algorithms correct for the incoherence in summation between steered transmissions induced by the motion of the scatterers. For HFR contrast-enhanced echocardiography using diverging waves, methods based on image registration (Stanziola et al. 2019) and cross-correlation (Nie et al. 2019) have been investigated to correct for motion between different steering angles. At each steering angle, the motion artifacts within the

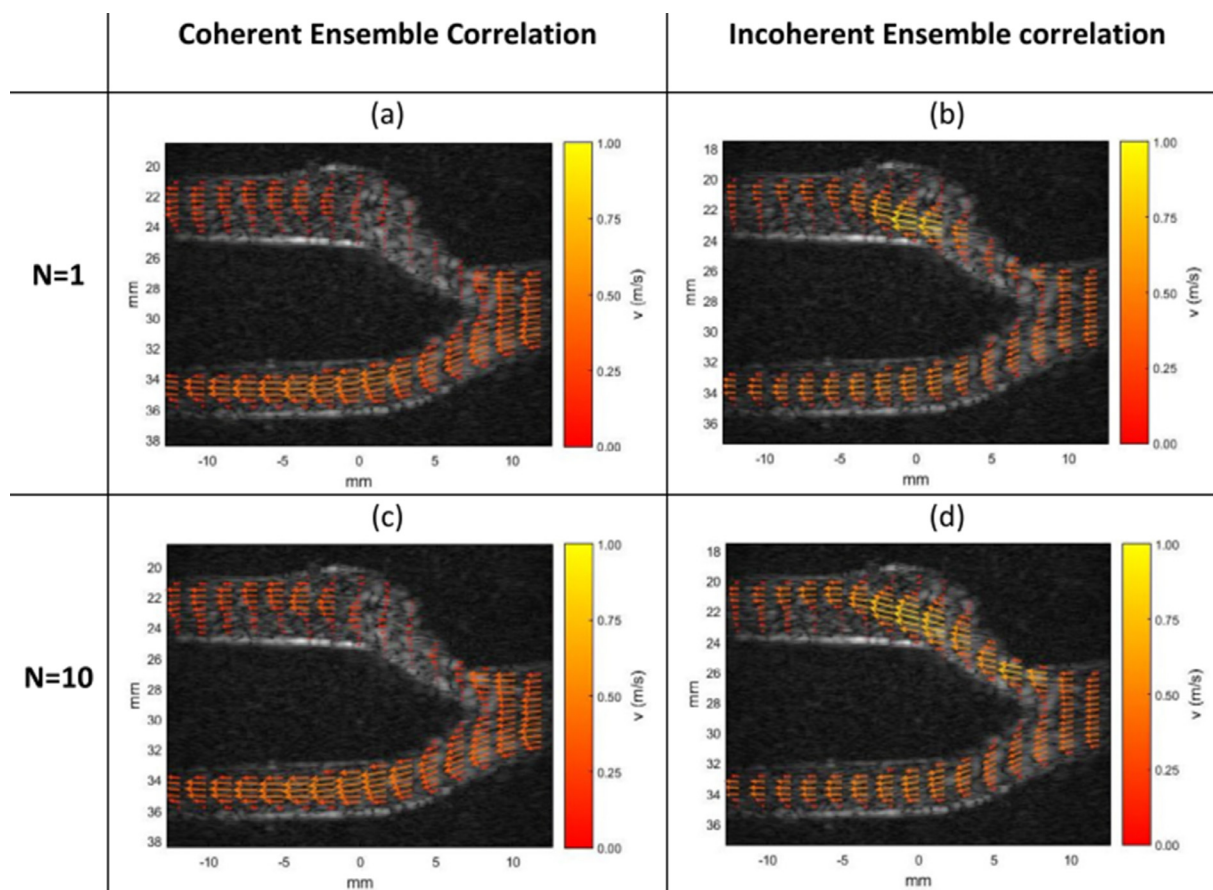


Fig. 6. Flow tracking in a phantom mimicking a healthy carotid. Comparison of the flow velocity mapping at peak systole reveals the robustness of the incoherent ensemble correlation approach to track highly accelerated flow when a similar number of high-resolution images (N) are used to estimate the flow velocity. Note that the coherent ensemble correlations are estimated from the final compounded images (N), but the incoherent ensemble correlations are computed on the multiple low-resolution images ($M \times N$) used to construct the same compounded images. Reprinted with permission from [Leow and Tang \(2018\)](#).

multipulse packet based on pulse inversion or amplitude modulation can be removed, as reported by [Nie et al. \(2019\)](#). The motion field calculated for motion compensation can be encoded and superimposed on its anatomic background. With the same pulse sequence, simultaneous HFR contrast-enhanced echocardiography and VFM at 250 Hz have been achieved ([Nie et al. 2019](#)).

CLINICAL RELEVANCE

The HFR techniques that have emerged provide the opportunity to study the relationship between cardiovascular disease progression and flow-derived parameters, such as vorticity, residence time and WSS. Other opportunities are more accurate methods for stenosis grading, based on transfer of energy to the recirculating flow distal to the stenosis. A first attempt to capture this in a flow parameter is the introduction of vector complexity or vector concentration (in short, the deviation of a vector from a straight line)

for more accurate stenosis grading ([Hansen et al. 2019](#); [Saris et al. 2019](#)). Furthermore, abdominal aneurysm rupture risk using blood flow-based prediction of thrombus formation in aneurysms could be a relevant application. The fact that the velocity fields obtained can be measured in a single cardiac cycle, compared with interleaved (or gated) MRI scans, also allows analysis with respect to variability of flow over several heartbeats.

With respect to the technical implementation in clinical equipment, the current echoPIV algorithms require much longer processing times compared with Doppler-based techniques which contain much smaller numbers of operations. Doppler techniques can be implemented in real-time on current systems, which facilitate real-time feedback on data quality and first interpretation of measurement results. In current implementations, echoPIV algorithms take at least minutes to process a low-frame-rate data set, which quickly grows to hours in case of a HFR data set of several cardiac cycles. Although some waiting time to

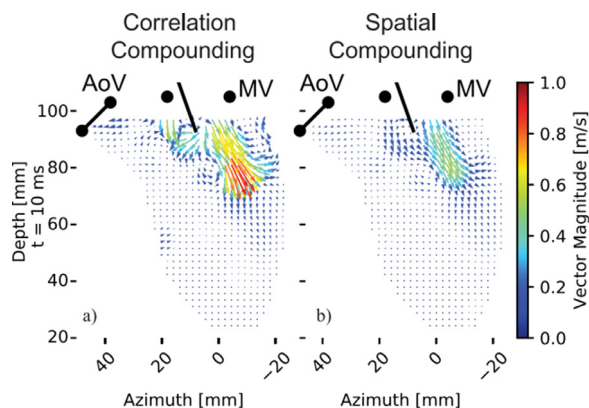


Fig. 7. Flow tracking in a phantom mimicking a healthy left ventricle, revealing the effect of compounding angular acquisitions in the correlation domain (a) and the spatial domain (b). When angles are averaged spatially after beamforming (coherent compounding), fast-moving scatterers decorrelate as in (b), degrading the signal for echoPIV analysis. AoV = aortic valve; MV = mitral valve. Reprinted with permission from Vorneveld et al. (2018b).

process data with the echoPIV techniques might be acceptable even in clinical routine, speeding up the processing by massively parallel computing and/or refinement of the algorithms themselves might improve clinical acceptance.

The relationship between pressure and volume in the left ventricle contains a wealth of information on cardiac health and is visualized with a pressure–volume loop. Pressure–volume loops are currently obtainable only in the clinic using invasive catheterization procedures. However, recent research has explored non-invasive calculation of PV loops using numerical models and MRI-measured LV volumes over time (Seemann et al. 2019). These methods can be further improved using 3-D flow data from 3-D echoPIV (or PC-MRI) to calculate local pressure gradients within the left ventricle.

Intracardiac echoPIV can improve our understanding of the cardiac physiology and mechanism of the pathophysiology in different cardiac diseases, including valvular leakage (Morisawa et al. 2018). Current imaging techniques such as Doppler echocardiography and MRI have limited ability to provide prognostic information. In the future, intracardiac blood flow analysis may improve the predictive ability of cardiac imaging in, for example, heart failure patients, and play a role in appropriate targeting of new therapies to those patients most at risk of complications. However, validation studies are necessary to further evaluate the advantages of intracardiac blood flow analysis over conventional echocardiographic parameters in the diagnosis, prognosis and treatment of cardiac disease. This also includes our assessment that the intraventricular flow patterns of healthy volunteers and patients should be re-evaluated

using HFR echoPIV. Healthy hearts have been examined with conventional line-scanning echoPIV (Cimino et al. 2012), but re-examination of healthy LV dynamics at the frame rates permitted by HFR echoPIV is required for future comparison in patients.

The need for ultrasound contrast agent injection limits the use of echoPIV as an early-stage screening tool for heart and arterial diseases because of the increased cost and expertise required for contrast agent administration. In patients or situations where the SNR is unproblematic, other vector flow imaging techniques, such as VFM, blood speckle tracking, vector Doppler and transverse oscillation, can work without the need for contrast administration (Jensen et al. 2016a, 2016b).

THE FUTURE: 3-D ECHOPIV?

The current main efforts are focused on 2-D flow analysis, which prohibits physical quantification of flow such as energy conservation, instead of full 3-D flow analysis. Several studies have worked on extending echoPIV to three dimensions. Poelma et al. (2011) obtained a 3-D region by sweeping a linear array along the elevational direction and combining the 2-D echoPIV results from each plane. However, out-of-plane velocity components would not have been measurable using this technique, so they effectively captured two components of the velocity field in three dimensions of space. Sengupta et al. (2012) used biplanar acquisitions so that echoPIV could be performed in orthogonal directions, but all three velocity components were only acquired at the intersection of the two planes. More recently, full 3-D flow field reconstruction with all three components has been found to be possible using divergence-free interpolation of multiple 2-D scan planes taken at angles over the 3-D region of interest; however, this technique requires precise knowledge of the transducer scan locations and orientations (Zhou et al. 2019a, 2019b).

Separately, Poelma et al. (2011) found that the out-of-plane displacement magnitude (not direction) could be estimated using the decorrelation of the speckle pattern with a known elevational beam profile. Zhou et al. (2018) used this idea to measure blood flow in the abdominal aorta of a rabbit but they noted that precise perpendicular alignment to the flow was required to avoid bias, and the direction once again was not measurable. In further extension of the method, Zhou et al. (2019c) described a tilt of the view angle with respect to the cross-section of the vessel so that the direction could also be determined using in-plane echoPIV.

Alternatively, Gao et al. (2013) simulated a multi-line acquisition using a matrix transducer to measure blood flow in a simulated left ventricle, finding that high

velocities were underestimated because of the low frame rate (113 Hz). In an *in vitro* LV phantom, Voorneveld *et al.* (2020) studied the accuracy of HFR 3-D echoPIV using a prototype matrix transesophageal transducer at 1000 volumes/s. It was found that high flow rates were accurately measured close to the probe; loss of lateral resolution at depth resulted in underestimation of the transmitral jet velocities.

The translation to truly volumetric (3-D) echoPIV would allow for assessment of interesting fluid dynamics parameters with minimal assumptions, such as kinetic energy and its dissipation, pressure gradients and blood washout rate. The development of vortices in the heart could be studied in three dimensions, removing planar flow assumptions present in current 2-D studies. These parameters are currently evaluated by PC-MRI but at limited temporal resolution (20–30 phases per cycle). Through use of 3-D echoPIV, this could be increased by one or two orders of magnitude, potentially revealing transient flow patterns and fast events that are not visible using PC-MRI (Chnafa *et al.* 2016). Yet, scaling HFR ultrasound platforms to 3-D imaging is even more challenging. The increased channel count poses additional burden on probe development, system cost, data acquisition, data transfer and data processing. Recent examples of volumetric flow tracking with fully populated matrix probes include 3-D super-resolution imaging (Heiles *et al.* 2019) and VFM (Correia *et al.* 2016). To reduce the channel count for HFR 3-D ultrasound imaging, the employment of sparse (Harput *et al.* 2018) and row–column arrays (Holbek *et al.* 2016) is being intensively investigated. In an alternative route, compressive 3-D ultrasound imaging by use of a single sensor was recently reported by Kruizinga *et al.* (2017). A plastic coding mask was placed in front of the ultrasound sensor, ensuring a unique compressed measurement for each voxel. This technique could provide an alternative to HFR 3-D contrast-enhanced ultrasound that uses 2-D matrix arrays.

CONCLUSIONS

This review has described the technical implementations and feasibility of high-frame-rate flow tracking with UCAs from first principles up to performance in patient studies. The high frame rates, compared with conventional frame rates, allow quantification of higher flow velocities using echoPIV, which is highly beneficial in tracking blood flow in ventricles and arteries. Very recent studies indicate a trend toward implementation of the techniques into 3-D imaging, such that all components of the flow can be captured, and thus, physical flow quantities can be extracted. However, we also identify that there is no clear view yet on what physical flow

quantities would characterize cardiac and vascular function best. A translation to clinical routine, therefore, would benefit from an increase in clinical pull. Yet, given the quickly rising availability of advanced systems capable of obtaining and processing the high frame rates needed for tracking physiologic flows, more clinical studies are expected in the near future to prove clinical relevance and thus motivate the clinical pull.

ETHICS STATEMENT

The inclusion criteria for the pre-clinical and clinical studies cited were respectively that approval from the Institutional Animal Care and Use Committee (IACUC) was obtained if animals were studied or that informed consent was obtained from each study participant and that each study was approved by an ethics committee or institutional review board. The majority of studies cited were published in journals for which these criteria were conditions of publication. For those studies for which this was not the case, a check was made that appropriate statements were included or that the authors have performed the study according to all common ethical considerations. There was a small number of studies for which ethical approval could not be confirmed because of their being published before the widespread requirement for inclusion of a statement of ethics board approval. The current authors, however, have no reason to doubt that these cited works were compliant with the 1964 Declaration of Helsinki.

REFERENCES

- Abe H, Caracciolo G, Kheradvar A, Pedrizzetti G, Khandheria BK, Narula J, Sengupta PP. Contrast echocardiography for assessing left ventricular vortex strength in heart failure: A prospective cohort study. *Eur Heart J Cardiovasc Imaging* 2013;14:1049–1060.
- Adrian RJ, Westerweel J. Particle image velocimetry. New York: Cambridge University Press; 2011.
- Agati L, Cimino S, Tonti G, Cicogna F, Petronilli V, De Luca L, Iacoponi C, Pedrizzetti G. Quantitative analysis of intraventricular blood flow dynamics by echocardiographic particle image velocimetry in patients with acute myocardial infarction at different stages of left ventricular dysfunction. *Eur Heart J Cardiovasc Imaging* 2014;15:1203–1212.
- Arvidsson PM, Kovács SJ, Töger J, Borgquist R, Heiberg E, Carlsson M, Arheden H. Vortex ring behavior provides the epigenetic blueprint for the human heart. *Sci Rep* 2016;6:22021.
- Assi KC, Gay E, Chnafa C, Mendez S, Nicoud F, Abascal JF, Lantelme P, Tournoux F, Garcia D. Intraventricular vector flow mapping—A Doppler-based regularized problem with automatic model selection. *Phys Med Biol* 2017;62:7131.
- Au JS, Yiu BY, Yu AC. Case studies in physiology: Visualization of blood recirculation in a femoral artery “trifurcation” using ultrasound vector flow imaging. *J Appl Physiol* (1985) 2019;127:1809–1813.
- Au JS, Yiu BYS, So H, Chee AJY, Greaves DK, Hughson RL, Yu ACH. Ultrasound vector projectile imaging for detection of altered carotid bifurcation hemodynamics during reductions in cardiac output. *Med Phys* 2020;47:431–440.
- Averkiou MA, Bruce MF, Powers JE, Sheeran PS, Burns PN. Imaging methods for ultrasound contrast agents. *Ultrasound Med Biol* 2020;46:498–517.

- Bechsgaard T, Hansen K, Brandt A, Moshavegh R, Forman J, Fogh P, Klittfod L, Bækgaard N, Lönn L, Jensen J, Nielsen M. Evaluation of peak reflux velocities with vector flow imaging and spectral Doppler ultrasound in varicose veins. *Ultrasound Int Open* 2018;4:E91–E98.
- Bercoff J, Montaldo G, Loupas T, Savary D, Mézière F, Fink M, Tanter M. Ultrafast compound doppler imaging: Providing full blood flow characterization. *IEEE Trans Ultrason Ferroelectr Freq Control* 2011;58:134–147.
- Boni E, Yu ACH, Freear S, Jensen JA, Tortoli P. Ultrasound open platforms for next-generation imaging technique development. *IEEE Trans Ultrason Ferroelectr Freq Control* 2018;65:1078–1092.
- Chnafa C, Mendez S, Nicoud F. Image-based simulations show important flow fluctuations in a normal left ventricle: What could be the implications?. *Ann Biomed Eng* 2016;44:3346–3358.
- Cimino S, Pedrizzetti G, Tonti G, Canali E, Petronilli V, De Luca L, Iacoboni C, Agati L. In vivo analysis of intraventricular fluid dynamics in healthy hearts. *Eur J Mech B Fluids* 2012;35:40–46.
- Correia M, Provost J, Tanter M, Pernot M. 4D ultrafast ultrasound flow imaging: In vivo quantification of arterial volumetric flow rate in a single heartbeat. *Phys Med Biol* 2016;61:L48–L61.
- Ekröll IK, Wigén M, Fadnes S, Avdal J. 2018 Quantitative vascular blood flow imaging: A comparison of vector velocity estimation schemes. *IEEE International Ultrasonics Symposium (IUS)*. Kobe, Japan1–4. doi: 10.1109/ULTSYM.2018.8579692.
- Engelhard S, Voorneveld J, Vos HJ, Westenberg JJM, Gijzen FJH, Taimr P, Versluis M, de Jong N, Bosch JG, Reijnen MMPJ, Groot Jebbink E. High-frame-rate contrast-enhanced US particle image velocimetry in the abdominal aorta: First human results. *Radiology* 2018;289:119–125.
- Eriksson J, Bolger AF, Ebberts T, Carlhäll C-J. Four-dimensional blood flow-specific markers of LV dysfunction in dilated cardiomyopathy. *Eur Heart J Cardiovasc Imaging* 2012;14:417–424.
- Fadnes S, Nyrnes SA, Torp H, Lovstakken L. Shunt flow evaluation in congenital heart disease based on two-dimensional speckle tracking. *Ultrasound Med Biol* 2014;40:2379–2391.
- Fadnes S, Bjærum S, Torp H, Lovstakken L. Clutter filtering influence on blood velocity estimation using speckle tracking. *IEEE Trans Ultrason Ferroelectr Freq Control* 2015;62:2079–2091.
- Fadnes S, Wigén MS, Nyrnes SA, Lovstakken L. In vivo intracardiac vector flow imaging using phased array transducers for pediatric cardiology. *IEEE Trans Ultrason Ferroelectr Freq Control* 2017;64:1318–1326.
- Gao H, Claus P, Amzulescu MS, Stankovic I, D’Hooge J, Voigt JU. How to optimize intracardiac blood flow tracking by echocardiographic particle image velocimetry? Exploring the influence of data acquisition using computer-generated data sets. *Eur Heart J Cardiovasc Imaging* 2012;13:490–499.
- Gao H, Heyde B, D’hooge J. 3D intra-cardiac flow estimation using speckle tracking: A feasibility study in synthetic ultrasound data. 2013 *IEEE International Ultrasonics Symposium (IUS)*. Prague, Czech Republic 68–71. doi: 10.1109/ULTSYM.2013.0018.
- Gao H, Bijnens N, Coisne D, Lugiez M, Rutten M, D’Hooge J. 2-D Left Ventricular Flow Estimation by Combining Speckle Tracking With Navier-Stokes-Based Regularization: An In Silico. In *Vitro and In Vivo Study*, *Ultrasound Med Biol* 2015;41:99–113.
- Garcia D, Del Alamo JC, Tanne D, Yotti R, Cortina C, Bertrand E, Antoranz JC, Perez-David E, Rieu R, Fernandez-Aviles F, Bermejo J. Two-dimensional intraventricular flow mapping by digital processing conventional color-Doppler echocardiography images. *IEEE Trans Med Imaging* 2010;29:1701–1713.
- Garcia D, Lantelme P, Saloux E. Introduction to speckle tracking in cardiac ultrasound imaging. In: Loizou CP, Pattichis CS, D’hooge J, (eds). *Handbook of speckle filtering and tracking in cardiovascular ultrasound imaging and video*. London: Institution of Engineering and Technology; 2018. p. 571–598.
- Goliasch G, Goscinska-Bis K, Caracciolo G, Nakabo A, Smolka G, Pedrizzetti G, Narula J, Sengupta PP. CRT improves LV filling dynamics: Insights from echocardiographic particle imaging velocimetry. *J Am Coll Cardiol Cardiovasc Imaging* 2013;6:704–713.
- Gurung A, Gates PE, Mazzaro L, Fulford J, Zhang F, Barker AJ, Hertzberg J, Aizawa K, Strain WD, Elyas S, Shore AC, Shandas R. Echo particle image velocimetry for estimation of carotid artery wall shear stress: Repeatability, reproducibility and comparison with phase-contrast magnetic resonance imaging. *Ultrasound Med Biol* 2017;43:1618–1627.
- Hansen KL, Pedersen MM, Møller-Sørensen H, Kjaergaard J, Nilsson JC, Lund JT, Jensen JA, Nielsen MB. Intraoperative cardiac ultrasound examination using vector flow imaging. *Ultrason Imaging* 2013;35:318–332.
- Hansen KL, Hansen PM, Ewertsen C, Lönn L, Jensen JA, Nielsen MB. Vector flow imaging compared with digital subtraction angiography for stenosis assessment in the superficial femoral artery—A study of vector concentration, velocity ratio and stenosis degree percentage. *Ultrasound Int Open* 2019;5:E53–E59.
- Hansen KL, Møller-Sørensen H, Kjaergaard J, Jensen JA, Nielsen MB. Vector flow imaging of the ascending aorta in patients with tricuspid and bicuspid aortic valve stenosis treated with biological and mechanical implants. *Ultrasound Med Biol* 2020;46:64–72.
- Harput S, Christensen-Jeffries K, Brown J, Zhu J, Zhang G, Leow CH, Toulemonde M, Ramalli A, Boni E, Tortoli P, Dunsby C, Tang MX. 3-D super-resolution ultrasound imaging using a 2-D sparse array with high volumetric imaging rate. 2018 *IEEE International Ultrasonics Symposium*. Kobe, Japan1–9. doi: 10.1109/ULTSYM.2018.8579662.
- Hathcock JJ. Flow effects on coagulation and thrombosis. *Arterioscler Thromb Vasc Biol* 2006;26:1729–1737.
- Heiles B, Correia M, Hingot V, Pernot M, Provost J, Tanter M, Couture O. Ultrafast 3D ultrasound localization microscopy using a 32 × 32 matrix array. *IEEE Trans Med Imaging* 2019;38:2005–2015.
- Holbek S, Christiansen TL, Stuart MB, Beers C, Thomsen EV, Jensen JA. 3-D vector flow estimation with row–column-addressed arrays. *IEEE Trans Ultrason Ferroelectr Freq Control* 2016;63:1799–1814.
- Holbek S, Hansen KL, Bouzari H, Ewertsen C, Stuart MB, Thomsen C, Nielsen MB, Jensen JA. Common carotid artery flow measured by 3-D ultrasonic vector flow imaging and validated with magnetic resonance imaging. *Ultrasound Med Biol* 2017;43:2213–2220.
- Holbek S, Hansen KL, Fogh N, Moshavegh R, Olesen JB, Nielsen MB, Jensen JA. Real-time 2-D phased array vector flow imaging. *IEEE Trans Ultrason Ferroelectr Freq Control* 2018;65:1205–1213.
- Hong GR, Pedrizzetti G, Tonti G, Li P, Wei Z, Kim JK, Baweja A, Liu S, Chung N, Houle H. Characterization and quantification of vortex flow in the human left ventricle by contrast echocardiography using vector particle image velocimetry. *J Am Coll Cardiol Cardiovasc Imaging* 2008;1:705–717.
- Ishii T, Nahas H, Yiu BYS, Chee AJY, Alfred CH. Contrast-enhanced urodynamic vector projectile imaging (CE-UroVPI) for urethral voiding visualization: Principles and phantom studies. *Urology* 2020;140:P171–P177.
- Jensen JA, Munk P. A new method for estimation of velocity vectors. *IEEE Trans Ultrason Ferroelectr Freq Control* 1998;45:837–851.
- Jensen JA, Nikolov SI, Yu ACH, Garcia D. Ultrasound vector flow imaging: Part I. Sequential systems. *IEEE Trans Ultrason Ferroelectr Freq Control* 2016a;63:1704–1721.
- Jensen JA, Nikolov SI, Yu ACH, Garcia D. Ultrasound vector flow imaging: Part II. Parallel systems. *IEEE Trans Ultrason Ferroelectr Freq Control* 2016b;63:1722–1732.
- Jensen J, Hoyos CAV, Traberg MS, Olesen JB, Tomov BG, Moshavegh R, Holbek S, Stuart MB, Ewertsen C, Hansen KL, Thomsen C, Nielsen MB, Jensen JA. Accuracy and precision of a plane wave vector flow imaging method in the healthy carotid artery. *Ultrasound Med Biol* 2018;44:1727–1741.
- Kheradvar A, Houle H, Pedrizzetti G, Tonti G, Belcik T, Ashraf M, Lindner JR, Gharib M, Sahn D. Echocardiographic particle image velocimetry: A novel technique for quantification of left ventricular blood vorticity pattern. *J Am Soc Echocardiogr* 2010;23:86–94.
- Kilner PJ, Yang GZ, Wilkes AJ, Mohiaddin RH, Firmin DN, Yacoub MH. Asymmetric redirection of flow through the heart. *Nature* 2000;404:759–761.
- Kim HB, Hertzberg JR, Shandas R. Development and validation of echo PIV. *Exp Fluids* 2004;36:455–462.
- Kripfgans OD, Rubin JM, Hall AL, Fowlkes JB. Vector Doppler imaging of a spinning disc ultrasound Doppler phantom. *Ultrasound Med Biol* 2006;32:1037–1046.

- Kruizinga P, van der Meulen P, Fedjajevs A, Mastik F, Springeling G, de Jong N, Bosch JG, Leus G. Compressive 3D ultrasound imaging using a single sensor. *Sci Adv* 2017;3:e1701423.
- Ku DN, Giddens DP, Zarins CK, Glagov S. Pulsatile flow and atherosclerosis in the human carotid bifurcation: Positive correlation between plaque location and low oscillating shear stress. *Arteriosclerosis* 1985;5:293–302.
- Kutty S, Li L, Danford DA, Houle H, Datta S, Mancina J, Xiao Y, Pedrizzetti G, Porter TR. Effects of right ventricular hemodynamic burden on intraventricular flow in tetralogy of Fallot: An echocardiographic contrast particle imaging velocimetry study. *J Am Soc Echocardiogr* 2014;27:1311–1318.
- Langille BL, O'Donnell F. Reductions in arterial diameter produced by chronic decreases in blood flow are endothelium-dependent. *Science* 1986;231:405–407.
- Lee SJ, Park JH, Kim JJ, Yeom E. Quantitative analysis of helical flow with accuracy using ultrasound speckle image velocimetry: In vitro and in vivo feasibility studies. *Ultrasound Med Biol* 2018;44:657–669.
- Leow CH, Bazigou E, Eckersley RJ, Yu ACH, Weinberg PD, Tang MX. Flow velocity mapping using contrast enhanced high-frame-rate plane wave ultrasound and image tracking: Methods and initial in vitro and in vivo evaluation. *Ultrasound Med Biol* 2015;41:2913–2925.
- Leow CH, Tang MX. Spatio-temporal flow and wall shear stress mapping based on incoherent ensemble-correlation of ultrafast contrast enhanced ultrasound images. *Ultrasound Med Biol* 2018;44:134–152.
- Liu L, Zheng H, Williams L, Zhang F, Wang R, Hertzberg J, Shandas R. Development of a custom-designed echo particle image velocimetry system for multi-component hemodynamic measurements: System characterization and initial experimental results. *Phys Med Biol* 2008;53:1397–1412.
- Lowe C, Abbas A, Rogers S, Smith L, Ghosh J, McCollum C. Three-dimensional contrast-enhanced ultrasound improves endoleak detection and classification after endovascular aneurysm repair. *J Vasc Surg* 2017;65:1453–1459.
- Malek AM, Alper SL, Izumo S. Hemodynamic shear stress and its role in atherosclerosis. *JAMA* 1999;282:2035–2042.
- Mehta KS, Lee JJ, Taha AA, Avgerinos E, Chaer RA. Vascular applications of contrast-enhanced ultrasound imaging. *J Vasc Surg* 2017;66:266–274.
- Mele D, Smarrazzo V, Pedrizzetti G, Capasso F, Pepe M, Severino S, Luisi GA, Maglione M, Ferrari R. Intracardiac flow analysis: Techniques and potential clinical applications. *J Am Soc Echocardiogr* 2019;32:319–332.
- Montaldo G, Tanter M, Bercoff J, Bence N, Fink M. Coherent plane-wave compounding for very high frame rate ultrasonography and transient elastography. *IEEE Trans Ultrason Ferroelectr Freq Control* 2009;56:489–506.
- Morisawa D, Falahatpisheh A, Avenatti E, Little SH, Kheradvar A. Intraventricular vortex interaction between transmitral flow and paravalvular leak. *Sci Rep* 2018;8:15657.
- Nie LZ, Cowell DMJ, Carpenter TM, McLaughlan JR, Çubukçu AA, Freear S. High-frame-rate contrast-enhanced echocardiography using diverging waves: 2-D motion estimation and compensation. *IEEE Trans Ultrason Ferroelectr Freq Control* 2019;66:359–371.
- Niu L, Qian M, Yan L, Yu W, Jiang B, Jin Q, Wang Y, Shandas R, Liu X, Zheng H. Real-time texture analysis for identifying optimum microbubble concentration in 2-D ultrasonic particle image velocimetry. *Ultrasound Med Biol* 2011;37:1280–1291.
- Nyrnes SA, Fadnes S, Wigen MS, Mertens L, Lovstakken L. Blood speckle-tracking based on high-frame rate ultrasound imaging in pediatric cardiology. *J Am Soc Echocardiogr* 2020;33:493–503.e5.
- Ohtsuki S, Tanaka M. The flow velocity distribution from the Doppler information on a plane in three-dimensional flow. *J Visual* 2006;9:69–82.
- Pedrizzetti G. On the computation of hemodynamic forces in the heart chambers. *J Biomech* 2019;95:109323.
- Pedrizzetti G, Domenichini F, Tonti G. On the left ventricular vortex reversal after mitral valve replacement. *Ann Biomed Eng* 2010;38:769–773.
- Pedrizzetti G, La Canna G, Alfieri O, Tonti G. The vortex—An early predictor of cardiovascular outcome?. *Nat Rev Cardiol* 2014;11:545.
- Pihl MJ, Marcher J, Jensen J. Phased-array vector velocity estimation using transverse oscillations. *IEEE Trans Ultrason Ferroelectr Freq Control* 2012;59:2662–2675.
- Piro V, Piro N, Piro O. Characterization of intraventricular blood flow using a microbubble-contrast tracking echo-PIV technique. *J Am Coll Cardiol* 2012;59:E1139.
- Poelma C. Ultrasound imaging velocimetry: A review. *Exp Fluids* 2017;58:3.
- Poelma C, Fraser KH. Enhancing the dynamic range of ultrasound imaging velocimetry using interleaved imaging. *Meas Sci Technol* 2013;24:115701.
- Poelma C, Mari JM, Foin N, Tang MX, Krams R, Caro CG, Weinberg PD, Westerweel J. 3D flow reconstruction using ultrasound PIV. *Exp Fluids* 2011;50:777–785.
- Poelma C, van der Mijle RME, Mari JM, Tang MX, Weinberg PD, Westerweel J. Ultrasound imaging velocimetry: Toward reliable wall shear stress measurements. *Eur J Mech B/Fluids* 2012;35:70–75.
- Prinz C, Faludi R, Walker A, Amzulescu M, Gao H, Uejima T, Fraser AG, Voigt JU. Can echocardiographic particle image velocimetry correctly detect motion patterns as they occur in blood inside heart chambers? A validation study using moving phantoms. *Cardiovasc Ultrasound* 2012;10:24.
- Provost J, Papadacci C, Arango JE, Imbault M, Fink M, Gennisson JL, Tanter M, Pernot M. 3D ultrafast ultrasound imaging in vivo. *Phys Med Biol* 2014;59:L1–L13.
- Quénot GM, Pakleza J, Kowalewski TA. Particle image velocimetry with optical flow. *Exp Fluids* 1998;25:177–189.
- Raffel M, Willert CE, Wereley ST, Kompenhans J. Particle image velocimetry: A practical guide. Heidelberg/New York: Springer; 2007.
- Ricci S, Ramalli A, Bassi L, Boni E, Tortoli P. Real-time blood velocity vector measurement over a 2-D region. *IEEE Trans Ultrason Ferroelectr Freq Control* 2017;65:201–209.
- Rodríguez Muñoz D, Markl M, Moya Mur JL, Barker A, Fernández-Golfín C, Lancellotti P, Zamorano Gómez JL. Intracardiac flow visualization: Current status and future directions. *Eur Heart J Cardiovasc Imaging* 2013;14:1029–1038.
- Ruhnau P, Kohlberger T, Schnorr C, Nobach H. Variational optical flow estimation for particle image velocimetry. *Exp Fluids* 2005;38:21–32.
- Saris AE, Hansen HH, Fekkes S, Menssen J, Nillesen MM, de Korte CL. In vivo blood velocity vector imaging using adaptive velocity compounding in the carotid artery bifurcation. *Ultrasound Med Biol* 2019;45:1691–1707.
- Scarano F. Iterative image deformation methods in PIV. *Meas Sci Technol* 2002;13:R1.
- Seemann F, Arvidsson P, Nordlund D, Kopic S, Carlsson M, Arheden H, Heiberg E. Noninvasive quantification of pressure-volume loops from brachial pressure and cardiovascular magnetic resonance. *Circ Cardiovasc Imaging* 2019;12:e008493.
- Sengupta PP, Khandheria BK, Korinek J, Jahangir A, Yoshifuku S, Milosevic I, Belohlavek M. Left ventricular isovolumic flow sequence during sinus and paced rhythms: New insights from use of high-resolution Doppler and ultrasonic digital particle imaging velocimetry. *J Am Coll Cardiol* 2007;49:899–908.
- Sengupta PP, Pedrizzetti G, Kilner PJ, Kheradvar A, Ebberts T, Tonti G, Fraser AG, Narula J. Emerging trends in CV flow visualization. *J Am Coll Cardiol Cardiovasc Imaging* 2012;5:305–316.
- Stanzola A, Toulemonde M, Li Y, Papadopoulou V, Corbett R, Duncan N, Eckersley RJ, Tang MX. Motion artifacts and correction in multipulse high-frame rate contrast-enhanced ultrasound. *IEEE Trans Ultrason Ferroelectr Freq Control* 2019;66:417–420.
- Stride E, Saffari N. Investigating the significance of multiple scattering in ultrasound contrast agent particle populations. *IEEE Trans Ultrason Ferroelectr Freq Control* 2005;52:2332–2345.
- Stugaard M, Koriyama H, Katsuki K, Masuda K, Asanuma T, Takeda Y, Sakata Y, Itatani K, Nakatani S. Energy loss in the left ventricle obtained by vector flow mapping as a new quantitative measure of

- severity of aortic regurgitation: A combined experimental and clinical study. *Eur Heart J Cardiovasc Imaging* 2015;16:723–730.
- Swillens A, Segers P, Torp H, Lovstakken L. Two-dimensional blood velocity estimation with ultrasound: Speckle tracking versus crossed-beam vector Doppler based on flow simulations in a carotid bifurcation model. *IEEE Trans Ultrason Ferroelectr Freq Control* 2010;57:327–339.
- Takahashi H, Hasegawa H, Kanai H. Echo speckle imaging of blood particles with high-frame-rate echocardiography. *Jap J Appl Phys* 2014;53(7S):07KF08.
- Tang MX, Eckersley RJ. Nonlinear propagation of ultrasound through microbubble contrast agents and implications for imaging. *IEEE Trans Ultrason Ferroelectr Freq Control* 2006;53:2406–2415.
- Tortoli P, Lenge M, Righi D, Ciuti G, Liebgott H, Ricci S. Comparison of carotid artery blood velocity measurements by vector and standard Doppler approaches. *Ultrasound Med Biol* 2015;41:1354–1362.
- Toulemonde M, Duncan WC, Leow C, Sboros V, Li Y, Eckersley RJ, Lin S, Tang M, Butler M. Cardiac flow mapping using high frame rate diverging wave contrast enhanced ultrasound and image tracking. 2017 IEEE International Ultrasonics Symposium. Washington DC1–4. doi: 10.1109/ULTSYM.2017.8091924.
- Toulemonde M, Li Y, Lin S, Cordonnier F, Butler M, Duncan WC, Eckersley RJ, Sboros V, Tang MX. High-frame-rate contrast echocardiography using diverging waves: initial in vitro and in vivo evaluation. *IEEE Trans Ultrason Ferroelectr Freq Control* 2018a;65:2212–2221.
- Toulemonde MEG, Corbett R, Papadopoulou V, Chahal N, Li Y, Leow CH, Cosgrove DO, Eckersley RJ, Duncan N, Senior R, Tang MX. High frame-rate contrast echocardiography: In-human demonstration. *J Am Coll Cardiol Cardiovasc Imaging* 2018b;11:923–924.
- Trahey GE, Allison JW, von Ramm OT. Angle independent ultrasonic detection of blood flow. *IEEE Trans Biomed Eng* 1987;BME-34:965–967.
- Uejima T, Koike A, Sawada H, Aizawa T, Ohtsuki S, Tanaka M, Furukawa T, Fraser AG. A new echocardiographic method for identifying vortex flow in the left ventricle: Numerical validation. *Ultrasound Med Biol* 2010;36:772–788.
- Voorneveld J, Kruizinga P, Vos HJ, Gijzen FJH, Jebbink EG, van der Steen AFW, de Jong N, Bosch JG. Native blood speckle vs ultrasound contrast agent for particle image velocimetry with ultrafast ultrasound—In vitro experiments. 2016 IEEE International Ultrasonics Symposium. Tours, France1–4. doi: 10.1109/ULTSYM.2016.7728614.
- Voorneveld J, Engelhard S, Vos HJ, Reijnen M, Gijzen F, Versluis M, Jebbink EG, de Jong N, Bosch JG. High-frame-rate contrast-enhanced ultrasound for velocimetry in the human abdominal aorta. *IEEE Trans Ultrason Ferroelectr Freq Control* 2018a;65:2245–2254.
- Voorneveld J, Muralidharan A, Hope T, Vos HJ, Kruizinga P, van der Steen AFW, Gijzen FJH, Kenjeres S, de Jong N, Bosch JG. High frame rate ultrasound particle image velocimetry for estimating high velocity flow patterns in the left ventricle. *IEEE Trans Ultrason Ferroelectr Freq Control* 2018b;65:2222–2232.
- Voorneveld J, Keijzer LBH, Strachinaru M, Bowen DJ, Goei JSL, Ten Cate F, van der Steen AFW, de Jong N, Vos HJ, van den Bosch AE, Bosch JG. High-frame-rate echo-particle image velocimetry can measure the high-velocity diastolic flow patterns. *Circ Cardiovasc Imaging* 2019;12 e008856.
- Voorneveld J, Saaid H, Schinkel C, Radeljic N, Lippe B, Gijzen FJH, van der Steen AFW, de Jong N, Claessens T, Vos HJ, Kenjeres S, Bosch JG. 4-D echo-particle image velocimetry in a left ventricular phantom. *Ultrasound Med Biol* 2020;46:805–817.
- Wagner RF, Smith SW, Sandrik JM, Lopez H. Statistics of speckle in ultrasound B-scans. *IEEE Trans Ultrason Ferroelectr Freq Control* 1983;30:156–163.
- Walker AM, Scott J, Rival DE, Johnston CR. In vitro post-stenotic flow quantification and validation using echo particle image velocimetry (Echo PIV). *Exp Fluids* 2014;55:1821.
- Westerdale J, Belohlavek M, McMahon EM, Jiamsripong P, Heys JJ, Milano M. Flow velocity vector fields by ultrasound particle imaging velocimetry in vitro comparison with optical flow velocimetry. *J Ultrasound Med* 2011;30:187–195.
- Whittingham TA. Contrast-specific imaging techniques: Technical perspective. In: Quaiia E, (ed). *Contrast media in ultrasonography*. Cham: Springer; 2005. p. 43–70.
- Wigen MS, Fadnes S, Rodriguez-Molares A, Bjåstad T, Eriksen M, Stensæth KH, Støylen A, Lovstakken L. 4-D intracardiac ultrasound vector flow imaging—Feasibility and comparison to phase-contrast MRI. *IEEE Trans Med Imaging* 2018;37:2619–2629.
- Yiu BYS, Lai SSM, Yu ACH. Vector projectile imaging: Time-resolved dynamic visualization of complex flow patterns. *Ultrasound Med Biol* 2014;40:2295–2309.
- Yiu BYS, Yu ACH. Least-squares multi-angle Doppler estimators for plane-wave vector flow imaging. *IEEE Trans Ultrason Ferroelectr Freq Control* 2016;63:1733–1744.
- Zarins CK, Giddens DP, Bharadvaj BK, Sottirai VS, Mabon RF, Glagov S. Carotid bifurcation atherosclerosis: Quantitative correlation of plaque localization with flow velocity profiles and wall shear-stress. *Circ Res* 1983;53:502–514.
- Zhang F, Lanning C, Mazzaro L, Barker AJ, Gates PE, Strain WD, Fulford J, Gosling OE, Shore AC, Bellenger NG, Rech B, Chen J, Chen J, Shandas R. In vitro and preliminary in vivo validation of echo particle image velocimetry in carotid vascular imaging. *Ultrasound Med Biol* 2011;37:450–464.
- Zheng H, Liu L, Williams L, Hertzberg JR, Lanning C, Shandas R. Real time multicomponent echo particle image velocimetry technique for opaque flow imaging. *Appl Phys Lett* 2006;88 261915.
- Zhou B, Fraser KH, Poelma C, Mari J-M, Eckersley RJ, Weinberg PD, Tang M-X. Ultrasound imaging velocimetry: Effect of beam sweeping on velocity estimation. *Ultrasound Med Biol* 2013;39:1672–1681.
- Zhou X, Leow CH, Rowland E, Riemer K, Rubin JM, Weinberg PD, Tang M-X. 3-D Velocity and volume flow measurement in vivo using speckle decorrelation and 2-D high-frame-rate contrast-enhanced ultrasound. *IEEE Trans Ultrason Ferroelectr Freq Control* 2018;65:2233–2244.
- Zhou X, Papadopoulou V, Leow CH, Vincent P, Tang M-X. 3-D flow reconstruction using divergence-free interpolation of multiple 2-D contrast-enhanced ultrasound particle imaging velocimetry measurements. *Ultrasound Med Biol* 2019a;45:795–810.
- Zhou X, Vincent P, Zhou X, Leow CH, Tang M-X. Optimization of 3-D divergence-free flow field reconstruction using 2-D ultrasound vector flow imaging. *Ultrasound Med Biol* 2019b;45:3042–3055.
- Zhou X, Zhou X, Leow CH, Tang MX. Measurement of flow volume in the presence of reverse flow with ultrasound speckle decorrelation. *Ultrasound Med Biol* 2019c;45:3056–3066.