



This is a repository copy of *Early variation of ultrasound halo sign with treatment and relation with clinical features in patients with giant cell arteritis.*

White Rose Research Online URL for this paper:  
<https://eprints.whiterose.ac.uk/160943/>

Version: Accepted Version

---

**Article:**

Ponte, C., Serafim, A.S., Monti, S. et al. (10 more authors) (2020) Early variation of ultrasound halo sign with treatment and relation with clinical features in patients with giant cell arteritis. *Rheumatology*, 59 (12). pp. 3717-3726. ISSN 1462-0324

<https://doi.org/10.1093/rheumatology/keaa196>

---

This is a pre-copyedited, author-produced version of an article accepted for publication in *Rheumatology* following peer review. The version of record Cristina Ponte, Ana Sofia Serafim, Sara Monti, Elisabete Fernandes, Ellen Lee, Surjeet Singh, Jennifer Piper, Andrew Hutchings, Eugene McNally, Andreas P Diamantopoulos, Bhaskar Dasgupta, Wolfgang A Schmidt, Raashid Ahmed Luqmani, Early variation of ultrasound halo sign with treatment and relation with clinical features in patients with giant cell arteritis, *Rheumatology*, keaa196, is available online at:  
<https://doi.org/10.1093/rheumatology/keaa196>

**Reuse**

Items deposited in White Rose Research Online are protected by copyright, with all rights reserved unless indicated otherwise. They may be downloaded and/or printed for private study, or other acts as permitted by national copyright laws. The publisher or other rights holders may allow further reproduction and re-use of the full text version. This is indicated by the licence information on the White Rose Research Online record for the item.

**Takedown**

If you consider content in White Rose Research Online to be in breach of UK law, please notify us by emailing [eprints@whiterose.ac.uk](mailto:eprints@whiterose.ac.uk) including the URL of the record and the reason for the withdrawal request.



[eprints@whiterose.ac.uk](mailto:eprints@whiterose.ac.uk)  
<https://eprints.whiterose.ac.uk/>

# Early variation of ultrasound halo sign with treatment and relation with clinical features in patients with giant cell arteritis

Ponte C<sup>1,2</sup>, Serafim AS<sup>3</sup>, Monti S<sup>4,5</sup>, Fernandes E<sup>6</sup>, Lee E<sup>7</sup>, Singh S<sup>8</sup>, Piper J<sup>8</sup>, Hutchings A<sup>9</sup>, McNally E<sup>10</sup>, Diamantopoulos AP<sup>11</sup>, Dasgupta B<sup>12</sup>, Schmidt WA<sup>13</sup>, Luqmani RA<sup>8</sup>

1. Rheumatology Department, Hospital de Santa Maria, Centro Hospitalar Universitário Lisboa Norte, Lisbon, Portugal
2. Rheumatology Research Unit, Instituto de Medicina Molecular, Faculdade de Medicina, Universidade de Lisboa, Lisbon, Portugal
3. Internal Medicine Department, Centro Hospitalar Barreiro-Montijo, Barreiro, Portugal
4. Department of Rheumatology, IRCCS Policlinico S. Matteo Fondazione, Pavia, Italy
5. PhD in Experimental Medicine, University of Pavia, Pavia, Italy
6. Biomathematics Laboratory, Faculdade de Medicina, Universidade de Lisboa, Lisbon, Portugal
7. Clinical Trials Research Unit, ScHARR, The University of Sheffield, Sheffield, UK
8. Nuffield Department of Orthopaedics Rheumatology and Musculoskeletal Sciences, University of Oxford, Oxford, UK
9. London School of Hygiene and Tropical Medicine, London, UK
10. Oxford Musculoskeletal Radiology, Oxford, UK
11. Department of Rheumatology, Martina Hansens Hospital, Bærum Oslo, Norway
12. Department of Rheumatology, Southend Hospital NHS Trust, Westcliff-on-Sea, UK
13. Immanuel Krankenhaus Berlin, Medical Centre for Rheumatology Berlin-Buch, Berlin, Germany

## Correspondence to:

Dr. Cristina Ponte

Department of Rheumatology, Hospital de Santa Maria, Centro Hospitalar Universitário Lisboa Norte; Rheumatology Research Unit, Instituto de Medicina Molecular, Faculdade de Medicina, Universidade de Lisboa

Av. Prof. Egas Moniz

649-035 Lisboa

Lisbon, Portugal

Email: cristinadbonte@gmail.com

## Key messages

- 1) Presence of halo sign is associated with ischaemic symptoms of giant cell arteritis
- 2) Physical examination findings are related to the presence of ipsilateral temporal artery halo
- 3) Temporal artery halo thickness consistently decreases with glucocorticoids in the first 7-days of treatment

**Keywords:** giant cell arteritis, ultrasound, halo sign, temporal arteries, axillary arteries, glucocorticoids, diagnosis, monitoring and prognosis.

## Abstract

**Objectives:** To compare the ultrasound characteristics with clinical features, final diagnosis and outcome; and to evaluate the halo size following glucocorticoid (GC) treatment in patients with newly diagnosed giant cell arteritis (GCA).

**Methods:** Patients with suspected GCA, recruited from an international cohort, had an ultrasound of temporal (TA) and axillary (AX) arteries performed within 7-days of commencing GCs. We compared differences in clinical features at disease presentation, after 2-weeks and after 6-months, according to the presence or absence of halo sign. We undertook a cross-sectional analysis of the differences in halo thickness using Pearson's correlation coefficient (r) and Analysis of Variance (ANOVA).

**Results:** A total of 345 patients with 6-months follow-up data were included; 226 (65.5%) had a diagnosis of GCA. Jaw claudication and visual symptoms were more frequent in patients with halo sign ( $p=0.018$  and  $p=0.003$ , respectively). Physical examination abnormalities were significantly associated with the presence of ipsilateral halo ( $p<0.05$ ). Stenosis or occlusion on ultrasound failed to contribute to the diagnosis of GCA. During 7 days of GC treatment, there was a consistent reduction in halo size in the TA (maximum halo size per patient:  $r=-0.30$ ,  $p=0.001$ ; and all halos  $r=-0.23$ ,  $p<0.001$ ), but not in the AX ( $p>0.05$ ). However, the presence of halo at baseline failed to predict future ischaemic events occurring during follow-up.

**Conclusions:** In newly diagnosed GCA, TA halo is associated with the presence of ischaemic features and its size decreases following GC treatment, supporting its early use as a marker of disease activity, in addition to its diagnostic role.

## Introduction

Giant cell arteritis (GCA) is the most common form of primary systemic vasculitis in patients aged > 50 years, affecting large and medium-sized arteries, in particular the aorta and its main branches [1,2]. Irreversible visual loss secondary to ischaemic optic neuropathy is one of the most serious complications of the disease [3]. Therefore, early diagnosis should be achieved and glucocorticoid (GC) treatment initiated as soon as possible to avoid ischaemic complications. However, GCA is a diagnostic challenge. The history, typical clinical findings and elevation of acute phase reactants are usually sufficient to lead to a suspicion of GCA but are not enough to give diagnostic certainty [4]. Temporal artery biopsy (TAB) has been considered the gold-standard for the diagnosis of GCA because of its high specificity; however, TAB has various limitations [5–8], particularly its low sensitivity for diagnosis (around 40% [9]).

During the last decade, high-resolution ultrasound has attracted considerable interest as a non-invasive diagnostic tool for patients with suspected GCA [10–14]. The presence of a non-compressible, hypoechoic, most commonly concentric arterial wall thickening, known as the 'halo sign', is highly specific for the diagnosis of GCA [15,16] and it has already been proposed as part of a diagnostic algorithm for this disease [4,17]. In addition, many studies have suggested cut-off values for the intima-media thickness (IMT) to define positive halo sign [18–23]. Schäfer et al. compared patients with controls in a prospective study assessing the IMT of arteries commonly involved in GCA: the cut-off values for the common superficial temporal arteries, the frontal and parietal branches, and the axillary arteries with the best performance characteristics to diagnose GCA were 0.42, 0.34, 0.29, and 1.0 mm, respectively [24]. In addition, the presence of bilateral halo sign has been reported to increase the specificity for GCA diagnosis by up to 100% [25]. Stenoses and occlusions, although less specific for GCA, may also be present in patients with GCA [26].

Ultrasound may also be useful to assess inflammatory activity in response to treatment [17,19,25,27,28]. De Miguel and colleagues have reported an association between halo disappearance and reduction of inflammatory markers. Moreover, a larger number of temporal artery branches affected by the disease before treatment initiation has been associated with increased values of CRP and ESR and slower resolution of the halo sign [19]. In addition, patients with large-vessel involvement seem to be less likely to have visual impairment [29,30]; however, abnormalities on temporal artery ultrasound do not appear to correlate with eye complications [30]. The halo sign of the temporal arteries has been reported to disappear after a mean of 2-10 weeks following initiation of GC treatment [15,18,19,25], but persists for much longer in the axillary arteries [31]. However, early halo sign variation with treatment has yet to be assessed.

The role of ultrasound compared to TAB in the diagnosis of GCA (TABUL) study [9] evaluated the diagnostic accuracy and the cost-effectiveness of ultrasound in a prospective multicentre cohort study that included 430 patients with suspected GCA. All patients underwent both ultrasound of the temporal and axillary arteries and TAB in the first 7-days of commencing high-doses of GCs (>20 mg of prednisolone or equivalent per day) and were assessed at three time points (baseline, 2-weeks, and 6-months) for clinical features of the disease, adverse events and diagnostic certainty.

The present study is a sub-analysis of the TABUL cohort with the specific aim of assessing the halo sign variation with GC treatment within a 7-day period for the temporal and axillary arteries, and to compare the halo sign characteristics (presence, size, anatomical distribution and number of sites affected) with ischaemic features of the disease, TAB results, outcome at 2-weeks and 6-months, and final diagnosis of GCA.

## **Methods**

### *Patients and data collection:*

A total of 430 patients were originally recruited at baseline into the TABUL study (ClinicalTrials.gov Identifier: NCT00974883) from 20 centres in 5 different countries (United Kingdom, Ireland, Norway, Germany and Portugal) from June 2010 to December 2013; 396 patients were assessed at 2-weeks; and 345 patients at 6-months. TAB and ultrasound were completed before the 2-weeks assessment. For diagnostic purposes, TAB results were provided to the clinician before the 2-week assessment, but ultrasound results only before the 6-months visit. Therefore, only patients with a complete 6-months assessment, in which the clinician decided on final diagnosis with full knowledge of the data, were used as the cohort for this study. The data from the TABUL study was collected in the PROSPECT database (Clinical Trials Unit, Sheffield University). Ethical approval was obtained for the study (REC No. 09/H0505/132) and patients signed informed consent prior to inclusion in the study.

### *Technical ultrasound specifications:*

In the TABUL study, a specific scanning protocol was used to ensure a systematic examination of 10 arterial territories of interest: bilateral common superficial temporal arteries (TA), parietal branches, proximal and distal segments of the frontal branches, and bilateral distal segment of the axillary (AX) arteries [32]. The sonographers were required to report the presence or absence of any ultrasound abnormality including halo sign, stenosis, occlusion, and atherosclerosis for each of the TA segments and AX arteries. If the presence of halo sign was reported, investigators were additionally asked to detail its maximum thickness. To support the findings, video and static images, in both longitudinal and transverse planes, were acquired and reviewed by a panel of ultrasound experts.

Ultrasound machines with linear probes were used to perform all scans. Sonographers were instructed to use the following settings: vascular pre-set; focus positioned 5 mm below skin surface for TA; grey scale frequency  $\geq 10$  MHz; colour Doppler with frequency  $\geq 6$  MHz; pulse repetition frequency at approximately 2–3 kHz; colour box with angle correction for longitudinal scans; and gain adjusted to fill only the lumen.

As part of the TABUL study, all scans were performed at one single time point around the onset of disease. All sonographers undertook a training program that consisted of an online review of 20 ultrasound images, and the correct scanning of a patient with active GCA plus scanning of 10 healthy controls, which was independently assessed by one of the TABUL experts [33].

### *Data analysis:*

Data were summarized by mean  $\pm$  standard deviation (SD) for continuous variables, and percentages and frequencies for categorical variables. Differences in clinical features between patients with the presence or absence of the halo sign at disease presentation, 2-weeks and 6-months of follow-up were compared using Student's t-test and Mann-Whitney non-parametric U test for continuous variables, and Chi-square test for categorical variables. Shapiro-Wilk test was used to assess normality of the continuous variables analysed. Logistic regression was used to determine the association between the presence of temporal artery halo and physical examination abnormalities of the ipsilateral side, and presence of ultrasound abnormalities and final diagnosis of GCA. A cross-sectional analysis of the halo size was performed to determine the relationship of the halo size with days of GC treatment using Pearson correlation coefficient ( $r$ ). In addition, analysis of variance (ANOVA) was applied to compare the halo size on different days. In all the analyses, the cut-off of  $p < 0.05$  was adopted for defining statistical significance and confidence intervals (CIs) were calculated at 95% level. Given the exploratory nature of the analyses, no adjustment was made for multiple testing. Statistical analysis was performed using Statistical Package for Social Science Software (SPSS), version 24.

## **Results**

### *1) Patient characteristics at disease presentation and presence of halo sign*

A total of 345 patients with complete 6-months data were evaluated; 243 (70.4%) females, mean age  $70.2 \pm 9.4$  years. After disclosure of pathology and ultrasonography features at 6-months, 226 (65.5%) patients were diagnosed with GCA by the treating physician; 158 (69.9%) females, mean age  $72.0 \pm 8.2$  years.

At disease presentation, the most frequently reported symptoms for patients with GCA were localised pain in the head (85.4%), constitutional symptoms (77.9%), generalised scalp tenderness (59.3%), and jaw claudication (52.2%) (**Supplementary Graphic 1**). At least one cranial feature (localized headache, scalp tenderness, jaw/tongue claudication, or visual symptoms) was present in 220 (97.3%) patients. Mean ESR was  $53.8 \pm 33.3$  mm/hr and mean CRP was  $55.8 \pm 59.8$  mg/L. In 214 cases, results of TAB were available: 47.2% compatible with vasculitis. In 121 (53.5%) patients, ultrasound of the temporal $\pm$ axillary arteries showed the presence of a halo sign.

**Table 1** shows the difference in disease characteristics for patients with a diagnosis of GCA and the presence or absence of the halo sign on ultrasound. Patients with halo were older ( $73.1 \pm 8.2$  vs.  $70.8 \pm 8.2$ ;  $p = 0.036$ ) with a lower percentage of females (66.1% vs. 74.3%;  $p = 0.018$ ); they had a higher percentage of positive TABs (60.3% vs. 31.6%); more jaw claudication (59.5% vs. 43.8%;  $p = 0.018$ ) and visual symptoms (47.9% vs. 28.6%;  $p = 0.003$ ) and higher levels of mean CRP ( $63.7 \pm 58.1$  vs.  $46.5 \pm 59.8$ ;  $p = 0.002$ ) at disease presentation.

**Table 1:** Comparison between patients with a diagnosis of GCA with halo vs. no halo

	Presence of halo on ultrasound (n= 121)	Absence of halo on ultrasound (n= 105)	p- value*
Demographics			
Age (years); mean (SD)	73.1±8.2	70.8±8.2	<b>0.036</b>
Female sex; n (%)	80 (66.1)	78 (74.3)	<b>0.018</b>
Diagnostic tests			
Positive TAB (214 results available); n (%)	70 (60.3)	31 (31.6)	<b>&lt;0.001</b>
ESR at baseline (mm/hr); mean (SD)	55.96±31.31	51.24±35.33	0.215
CRP at baseline (mg/L); mean (SD)	63.72±58.1	46.52±59.83	<b>0.002</b>
Disease symptoms at presentation, n (%)			
Constitutional symptoms (any)	97 (80.2)	79 (75.2%)	0.373
Fatigue	76 (62.8)	68 (64.8)	0.761
Anorexia	53 (43.8)	38 (36.2)	0.245
Fever or night sweats	52 (43.0)	32 (30.5)	0.052
PMR features (any)	38 (31.4)	46 (43.8)	0.054
Bilateral shoulder pain	34 (28.1)	37 (35.2)	0.249
Early morning stiffness	22 (18.2)	21 (20.0)	0.728
Bilateral hip stiffness	16 (13.2)	25 (23.8)	<b>0.039</b>
Localised pain in the head	99 (81.8)	94 (89.5)	0.102
Generalised scalp tenderness	68 (56.2)	66 (62.9)	0.310
Jaw claudication	72 (59.5)	46(43.8)	<b>0.018</b>
Tongue claudication	10 (8.3)	3 (2.9)	0.082
Visual symptoms (any)	58 (47.9)	30 (28.6)	<b>0.003</b>
Reduced or lost vision	49 (40.5)	24 (22.9)	<b>0.005</b>
Double vision	12 (9.9)	5 (4.8)	0.143
Amaurosis fugax	4 (3.3)	4 (3.8)	0.838
Stroke (assessed in 220 patients)	0 (0)	2 (2.0)	0.123

CRP: C-reactive protein; ESR: erythrocyte sedimentation rate; PMR: polymyalgia rheumatica; SD: standard deviation; TAB: temporal artery biopsy

\*Pearson's Chi-squared test, student's independent t-test or the Mann-Whitney U test

In bold the statistically significant values (p < 0.05)

An abnormal examination of the temporal artery (TA), including reduced or absent pulse and tenderness or thickness of the artery, was found in 154/225 (68%) of patients with GCA who had this assessment reported: 108 on right TA and 104 on the left TA. Regarding visual examination, which included assessment for presence of anterior ischaemic optic neuropathy (AION), posterior ischaemic optic neuropathy (PION), relative afferent pupillary defect and III/IV/VI nerve palsy, in 22/190 (11.6%) patients, pathological findings were reported: 10 in the right eye and 14 in the left eye (**Supplementary Graphic 1**).

One hundred and twelve of 121 (92.6%) patients had a halo sign reported in the TA (91/112 on the right and 86/112 on the left), and 33/121 (27.2%) patients in the AX

(23/33 on the right and 25/33 on the left). The presence of a right TA halo was associated with pathological findings on physical examination of the ipsilateral side; these patients were more likely to present with at least one abnormality on physical examination of the right TA (OR 2.2, 95% CI:1.3-3.7), particularly thickened artery and change in pulse character (OR 2.4, 95% CI:1.3-4.5, and OR 2.2, 95% CI:1.1-4.2; respectively). The same was true for the presence of left TA halo; these patients were more likely to have thickened TA on the left side (OR 2.2, 95% CI:1.2-4.1) and left sided visual disturbances (OR 4.6, 95% CI:1.4-15.4), in particular AION and relative afferent pupillary defect (OR 6.4, 95% CI:1.3-32.3, and OR 10.9, 95% CI:1.2-95.5; respectively) (**Table 2**).

**Table 2:** Association between the presence of halo and physical examination abnormalities of the ipsilateral side

	Ipsilateral TA abnormal examination, OR (95% CI)				Ipsilateral visual disturbances, OR (95% CI)		
	Any <sup>1</sup>	Thickened	Tender	Reduced or absent pulse	Any <sup>2</sup>	AION	Relative afferent pupillary defect
<b>Right TA halo</b>	2.2* (1.3-3.7)	2.4* (1.3-4.5)	1.2 (0.7-2.2)	2.2* (1.1-4.2)	3.8 (1.0-15.4)	4.7 (0.9-24.9)	6.2 (0.6-61.0)
<b>Left TA halo</b>	1.5 (0.9-2.6)	2.2* (1.2-4.1)	1.3 (0.7-2.3)	1.1 (0.6-2.1)	4.6* (1.4-15.4)	6.4* (1.3-32.3)	10.9* (1.2-95.5)

\*p<0.05; AION: anterior ischaemic optic neuropathy, CI: confidence interval; OR: odds ratio, TA: temporal artery

1 - Any TA abnormality on examination: tenderness or thickness of the artery or reduced or absent pulse

2 - Any visual disturbances on examination: anterior ischaemic optic neuropathy, posterior ischaemic optic neuropathy, relative afferent pupillary defect, or III/IV/VI nerve palsy

## 2) Association between ultrasound findings and final diagnosis of GCA

Halo sign was reported in 152/345 patients. Out of the 10 artery segments evaluated by ultrasound for presence of halo, there were 40 (26.3%) cases involving only 1 segment, 38 (25.0%) involving 2 segments, 16 (10.5%) involving 3 segments, 18 (11.8%) involving 4 segments, 5 (3.3%) involving 5 segments, 9 (5.9%) involving 6 segments, 9 (5.9%) involving 7 segments, 14 (9.2%) involving 8 segments, and 3 (2.0%) in which all 10 segments were involved. Amongst patients who had a halo sign reported, 144/152 (94.7%) had TA involvement, 40/152 (26.3%) axillary involvement, 79/152 (52.0%) had bilateral TA involvement, and 17/152 (11.2%) bilateral AX involvement. Mean halo thickness of the TA was 0.67±0.35 mm and of the AX 1.31±0.96 mm.

The presence of halo was found in 121/226 (53.5%) patients with a diagnosis of GCA and 31/119 (26.1%) of patients without GCA (p<0.001). However, when the cut-off values for intima-media thickness (IMT) of TA and AX, defined by Schafer et al., were applied, the number of patients with halo without a diagnosis of GCA reduced to 19/119 (16%); there was also a reduction in the number of patients with halo and GCA to 107/224 (47.8%) (**Supplementary Table 1**). In addition, with this adjustment based on the IMT cut-off measurements, the OR for GCA diagnosis increased from 3.3 (95% CI:2.0-5.3) to 4.6 (95% CI:2.7-8.1) (**Table 3**).



**Table 3:** Different ultrasound findings as potential risk factors for final diagnosis of GCA

	Diagnosis of GCA at 6 months		
	OR	95% CI	p-value
<b>Ultrasound findings</b>			
Presence of halo sign (TA or AX)	3.3	2.0-5.3	<b>&lt;0.001</b>
TA halo	3.0	1.9-4.9	<b>&lt;0.001</b>
AX halo	3.3	1.4-8.2	<b>0.009</b>
Presence of stenosis (TA or AX)	1.2	0.5-3.3	0.665
TA stenosis	1.0	0.4-2.4	0.940
AX stenosis	2.0	0.2-18.9	0.546
Presence of occlusion (TA or AX)	2.3	0.7-7.0	0.151
TA occlusion	2.2	0.7-6.7	0.180
Presence of arteriosclerosis (TA or AX)	1.2	0.5-2.6	0.583
TA arteriosclerosis	1.4	0.6-3.1	0.457
AX arteriosclerosis	0.7	0.2-3.1	0.666
<b>Halo general characteristics</b>			
Halo sign with adjusted IMT cut-offs (TA or AX) *	4.6	2.7-8.1	<b>&lt;0.001</b>
TA halo with adjusted IMT cut-offs *	4.7	2.6-8.4	<b>&lt;0.001</b>
AX halo with adjusted IMT cut-offs *	4.0	1.2-13.6	<b>0.028</b>
Bilateral halo (TA or AX)	4.2	2.2-8.1	<b>&lt;0.001</b>
Bilateral TA halo	3.8	1.9-7.3	<b>&lt;0.001</b>
Bilateral AX halo	4.2	2.2-8.1	0.061
TA halo without AX halo	2.4	1.4-3.9	<b>0.001</b>
TA halo with AX halo	3.1	1.2-8.3	<b>0.024</b>
<b>Number of arterial segments with the presence of halo</b>			
≥ 1 arterial segments	3.3	2.0-5.3	<b>&lt;0.001</b>
≥ 2 arterial segments	3.7	2.1-6.4	<b>&lt;0.001</b>
≥ 3 arterial segments	6.7	3.0-15.2	<b>&lt;0.001</b>
≥ 4 arterial segments	9.0	3.2-25.6	<b>&lt;0.001</b>
≥ 5 arterial segments	7.6	2.3-25.1	<b>&lt;0.001</b>
≥ 6 arterial segments	10.0	2.4-42.5	<b>0.002</b>
≥ 7 arterial segments	14.7	2.0-109.7	<b>0.009</b>
<b>Halo thickness</b>			
Maximum TA halo thickness	16.6	3.8-72.5	<b>&lt;0.001</b>
Mean TA halo thickness	14.5	4.6-45.8	<b>&lt;0.001</b>
Maximum AX halo thickness	3.7	0.3-42.8	0.297
Mean AX halo thickness	2.5	0.3-19.4	0.381

AX: axillary artery; CI: confidence interval; GCA: giant cell arteritis; IMT: intima-media thickness; OR: odds ratio, TA: temporal artery

\*Cut-offs for common superficial temporal arteries, frontal and parietal branches, and axillary arteries of 0.42, 0.34, 0.29, and 1.0mm, respectively [24]

In bold the statistically significant values (p<0.05)

The presence of halo was found in 121/226 (53.5%) patients with a diagnosis of GCA and 31/119 (26.1%) of patients without GCA (p<0.001). However, when the cut-off

values for intima-media thickness (IMT) of TA and AX, defined by Schafer et al., were applied, the number of patients with halo without a diagnosis of GCA reduced to 19/119 (16%); there was also a reduction in the number of patients with halo and GCA to 107/224 (47.8%) (**Supplementary Table 1**). In addition, with this adjustment based on the IMT cut-off measurements, the OR for GCA diagnosis increased from 3.3 (95% CI:2.0-5.3) to 4.6 (95% CI:2.7-8.1) (**Table 3**).

The maximum TA halo thickness and mean TA halo thickness were higher in patients who were given a final diagnosis of GCA vs. patients who were not considered to have GCA ( $0.81\pm 0.44$  vs.  $0.47\pm 0.33$  and  $0.70\pm 0.35$  vs.  $0.48\pm 0.31$ ;  $p<0.001$  and  $p<0.001$  respectively); however, this difference was not observed in the AX halo thickness (**Supplementary Table 1**). The OR for having a diagnosis of GCA increased with the number of segments involved (**Table 3**); all patients with  $\geq 8$  segments containing a halo had a diagnosis of GCA. Bilateral TA or AX halos were found less frequently in patients without a final diagnosis of GCA in comparison to patients diagnosed with GCA (12/119 [10.1%] vs. 72/226 [31.9%];  $p<0.001$ ), and the presence of AX halo in addition to TA halo increased the OR for diagnosing GCA from 2.4 (95% CI:1.4-3.9) to 3.1 (95% CI:1.2-8.3).

Besides the presence of halo, other ultrasound abnormalities were described (stenosis, occlusion, and arteriosclerosis). However, none of these ultrasound findings was found to be statistically significant as a risk factor for a final diagnosis of GCA (**Table 3; Supplementary Table 1**).

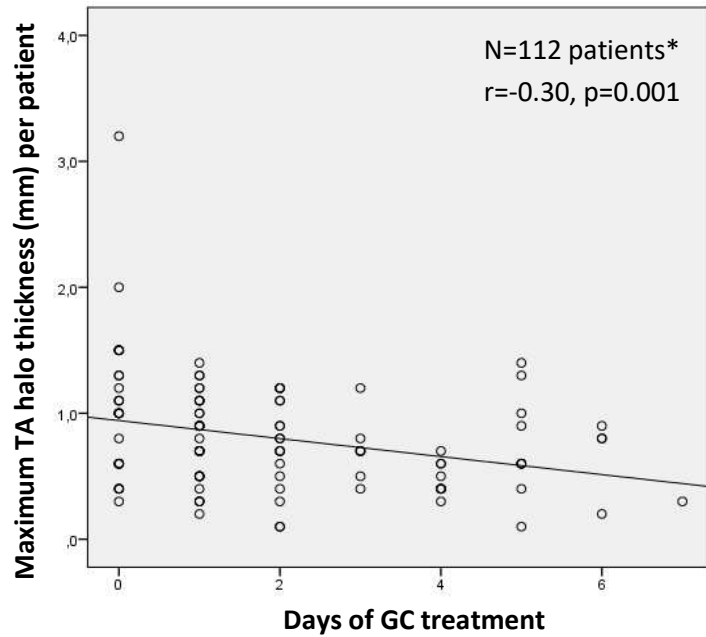
### *3) Effect of glucocorticoid therapy on early ultrasound halo findings*

To determine the association between halo size and the number of days of GC treatment, we performed a cross-sectional analysis of all patients with GCA who had a halo sign on ultrasound ( $n=121$ ). A total of 120/121 patients were started on  $\geq 40$  mg of prednisolone or equivalent per day; only one patient who underwent ultrasound on day 2 of treatment was started on an inferior dose of 30 mg of prednisolone. Most patients were scanned within the first 2-days of starting GC treatment (71.9%).

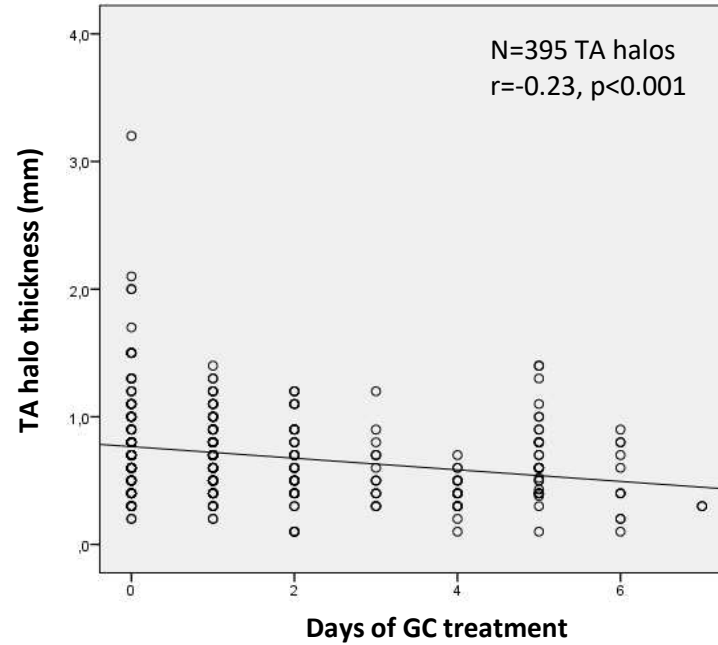
The linear regression model for the TA halos, using the maximum TA halo intima-media thickness (IMT) registered per patient with GCA ( $n=112$ ; **Graphic 1A**), or the IMT of all TA halos reported in patients with GCA ( $n=395$ ; **Graphic 1B**) showed a consistently smaller halo size over the 7-days of GC treatment ( $r=-0.30$ ,  $p=0.001$ , and  $r=-0.23$ ,  $p<0.001$ ; respectively). The multiple comparisons in ANOVA confirmed a statistically significant difference in halo size between baseline and  $\geq 4$  days of GC treatment ( $p=0.003$ ) for the maximum TA halo IMT per patient with GCA ( $n=112$ ; **Supplementary Graphic 2A**). When all TA halos of patients with GCA were considered, the multiple comparisons in ANOVA also showed a statistically significant difference in halo size between baseline and  $\geq 4$  days of GC treatment ( $p<0.001$ ) and additionally between day 1 and  $\geq 4$  days of GC treatment ( $p=0.041$ ) ( $n=395$ ; **Supplementary Graphic 2B**). The trend of finding a smaller halo over time was not possible to predict after 4 days of GC treatment.

**Graphic 1.** Scatter-plots with variation of TA halo thickness according to number of days on GC treatment

**A. Maximum TA halo thickness per patient with GCA**



**B. All TA halo thickness from patients with GCA**



\*Patients with GCA who had at least one measurement of IMT for TA halo reported

Day 0 represents the patients who haven't started GC or started GC on that same day; r: Pearson's regression coefficient

GCA: giant cell arteritis; GC: glucocorticoid; IMT: intima-media thickness, TA: temporal artery

Regarding the AX halos, when applying linear regression models using the maximum AX halo IMT registered per patient with GCA (n=33; **Supplementary Graphic 3A**), or the IMT of all AX halos reported in patients with GCA (n=48; **Supplementary Graphic 3B**) the correlation coefficients were very weak and not statistically significant (r=-0.064, p=0.721, and r=-0.044, p=0.764; respectively). These results were also confirmed by the ANOVA analyses in which no statistically significant change in halo size was found in both cases of AX involvement referred above (p=0.403 and p=0.067; respectively).

#### 4) Predictive value of halo for clinical outcome at 2-weeks and 6-month

The differences between presence vs. absence of halo on ultrasound and clinical features at 2-weeks and 6-months in patients with GCA were assessed (**Table 4**). At 2-weeks, patients with halo reported less new constitutional symptoms since disease presentation (2.5% vs. 9.5%; p=0.023) and had higher mean levels of ESR (14.8±12.3 vs. 11.4±11.7; p=0.001). No differences were found in the occurrence of new visual symptoms at 2-weeks and 6-months; however, patients with halo were reported to have more new and maintained visual symptoms (31.4% vs. 17.1%, p=0.013, and 34.7% vs. 16.2%, p=0.002).

**Table 4:** Comparison between the presence vs. absence of halo and clinical features at 2-weeks and 6-months

	Presence of halo on ultrasound (n= 121)	Absence of halo on ultrasound (n= 105)	p-value*
Disease symptoms at 2-weeks (new), n (%)			
Constitutional symptoms (any)	3 (2.5)	10 (9.5)	<b>0.023</b>
Fatigue	3 (2.5)	4 (3.8)	0.565
Anorexia	0 (0.0)	3 (2.9)	0.061
Fever or night sweats	0 (0.0)	4 (3.8)	0.030
PMR features (any)	0 (0.0)	2 (1.9)	0.127
Bilateral shoulder pain	0 (0.0)	1 (1.0)	0.282
Early morning stiffness	0 (0.0)	0 (0.0)	
Bilateral hip stiffness	0 (0.0)	1 (1.0)	0.282
Localised pain in the head	0 (0.0)	2 (1.9)	0.127
Generalised scalp tenderness	0 (0.0)	2 (1.9)	0.127
Jaw claudication	1 (0.8)	1 (1.0)	0.920
Tongue claudication	1 (0.8)	0 (0.0)	0.351
Visual symptoms (any)	1 (0.8)	4 (3.8)	0.128
Reduced or lost vision	0 (0.0)	2 (1.9)	0.127
Double vision	0 (0.0)	0 (0.0)	
Amaurosis fugax	1 (0.8)	2 (1.9)	0.480

Disease symptoms at 2-weeks (new and maintained), n (%)			
Constitutional symptoms (any)	43 (35.5)	46 (43.8)	0.201
Fatigue	37 (30.6)	38 (36.2)	0.372
Anorexia	10 (8.3)	15 (14.3)	0.150
Fever or night sweats	15 (12.4)	15 (14.3)	0.676
PMR features (any)	10 (8.3)	13 (12.4)	0.307
Bilateral shoulder pain	8 (6.6)	10 (9.5)	0.420
Early morning stiffness	6 (5.0)	1 (1.0)	0.083
Bilateral hip stiffness	4 (3.3)	3 (2.9)	0.846
Localised pain in the head	30 (24.8)	38 (36.2)	0.062
Generalised scalp tenderness	13 (10.7)	19 (18.1)	0.114
Jaw claudication	24 (19.8)	19 (18.1)	0.740
Tongue claudication	4 (3.3)	1 (1.0)	0.230
Visual symptoms (any)	38 (31.4)	18 (17.1)	<b>0.013</b>
Reduced or lost vision	36 (29.8)	17 (16.2)	<b>0.016</b>
Double vision	2 (1.7)	0 (0.0)	0.186
Amaurosis fugax	2 (1.7)	2 (1.9)	0.886
Follow up assessments at 2-weeks			
ESR (mm/hr); mean (SD)	14.8±12.3	11.4±11.7	<b>0.001</b>
CRP (mg/L); mean (SD)	5.4±15.9	3.7±8.1	0.846
Disease symptoms at 6-months (new), n (%)			
Constitutional symptoms	18 (14.9)	11 (10.5)	0.324
Fatigue	12 (9.9)	8 (7.6)	0.544
Anorexia	3 (2.5)	3 (2.9)	0.860
Fever or night sweats	5 (4.1)	5 (4.8)	0.818
PMR features	7 (5.8)	7 (6.7)	0.784
Bilateral shoulder pain	4 (3.3)	6 (5.7)	0.380
Early morning stiffness	3 (2.5)	4 (3.8)	0.565
Bilateral hip stiffness	4 (3.3)	4 (3.8)	0.838
Localised pain in the head	5 (4.1)	8 (7.6)	0.262
Generalised scalp tenderness	2 (1.7)	5 (4.8)	0.178
Jaw claudication	1 (0.8)	3 (2.9)	0.248
Tongue claudication	2 (1.7)	0 (0.0)	0.186
Visual symptoms	5 (4.1)	4 (3.8)	0.902
Reduced or lost vision	5 (4.1)	1 (1)	0.138
Double vision	1 (0.8)	3 (2.9)	0.248
Amaurosis fugax	0 (0.0)	2 (1.9)	0.127
Disease symptoms at 6-months (new and maintained), n (%)			
Constitutional symptoms (any)	44 (36.4)	42 (40.0)	0.574
Fatigue	36 (29.8)	39 (37.1)	0.239
Anorexia	7 (5.8)	11 (10.5)	0.194
Fever or night sweats	14 (11.6)	13 (12.4)	0.851
PMR features (any)	12 (9.9)	12 (11.4)	0.713
Bilateral shoulder pain	9 (7.4)	11 (10.5)	0.423
Early morning stiffness	6 (5.0)	4 (3.8)	0.675

Bilateral hip stiffness	5 (4.1)	6 (5.7)	0.581
Localised pain in the head	19 (15.7)	32 (30.5)	<b>0.008</b>
Generalised scalp tenderness	9 (7.4)	10 (9.5)	0.573
Jaw claudication	10 (8.3)	11 (10.5)	0.568
Tongue claudication	3 (2.5)	1 (1.0)	0.385
Visual symptoms (any)	42 (34.7)	17 (16.2)	<b>0.002</b>
Reduced or lost vision	40 (33.1)	15 (14.3)	<b>0.001</b>
Double vision	3 (2.5)	3 (2.9)	0.860
Amaurosis fugax	2 (1.7)	2 (1.9)	0.886
Follow up assessments at 6-months			
VDI; mean (SD)	0.57±0.965	0.47±0.735	0.706
ESR (mm/hr); mean (SD)	16.0±13.8	16.1±17.3	0.333
CRP (mg/L); mean (SD)	7.6±15.8	6.0±12.0	0.824

CRP: C-reactive protein; ESR: erythrocyte sedimentation rate; PMR: polymyalgia rheumatica; SD: standard deviation; TAB: temporal artery biopsy; VDI: Vasculitis Damage Index

\*Pearson's Chi-squared test, student's independent t-test or the Mann-Whitney U test  
In bold the statistically significant values (p<0.05)

## Discussion

The inclusion of ultrasound in the diagnostic assessment of GCA has been an increasing reality for many centres treating this disease, particularly in the last decade. In this present sub-analysis of the TABUL study [9], the halo sign, deemed as the most important ultrasound finding to diagnose GCA [16], was only found in 121/226 (53.5%) of patients who were given a final diagnosis of GCA by the treating physician after full disclosure of the TAB and ultrasound results. This low percentage could be explained by several reasons: 1) When the TABUL study was conducted (2010-2013) the majority of sonographers had little or no experience with vascular ultrasound [9,26] which might have influenced the quality of the ultrasound results, even after a strict training program had been undertaken (*see methods*); 2) The TABUL study allowed the use of probes with a B-mode frequency of 10 MHz, which is currently considered an insufficient resolution for TA assessment [17]; 3) The presence of vessel occlusion caused by vasculitis might have precluded the correct identification of halo sign by less experienced sonographers; 4) In the majority of studies, the presence of a halo sign on ultrasound has shown higher specificity than sensitivity to diagnose GCA [10–14]; therefore, in a disease that carries a high risk of ischaemic complications if left untreated, physicians are likely to be less prepared to exclude GCA based on a negative ultrasound, than to diagnose this disease based on a positive examination and suggestive clinical presentation; 5) At the time the TABUL study was conducted, only few centres regularly used this imaging technique and ultrasound was still not part of the EULAR recommendations [17,34] to diagnose GCA, thus many physicians

might have had little reliance on ultrasound results to exclude GCA; 6) Possible false clinical diagnosis of GCA, supported by the low positive TABs (31.6%) reported in patients with GCA and absence of halo on ultrasound.

We found that the presence of halo sign was associated with the most specific findings of GCA such as positive TAB ( $p < 0.001$ ), jaw claudication ( $p = 0.018$ ) and visual symptoms ( $p = 0.003$ ), but not with constitutional symptoms ( $p = 0.373$ ), PMR ( $p = 0.054$ ) or headache ( $p = 0.102$ ) which are more frequent in GCA but have little specificity for this diagnosis. In addition, physical examination findings were significantly associated with the presence of ipsilateral halo, contrasting with the previous work by Schmidt et al. in which ophthalmic complications were not significantly related to positive temporal artery ultrasound [30].

When looking specifically at the type of ultrasound findings and their relation to final diagnosis of GCA, only the presence of halo sign contributed to the diagnosis. The presence or absence of stenosis or occlusion were not discriminatory. In addition, bilateral halos, TA halo with AX halo, adjusted IMT cut-offs for TA and AX halos, and more arterial segments with halo increased the odds ratio for having the diagnosis of GCA. These findings suggest that a potential composite score including these halo abnormalities, instead of the current binary presence / absence of halo in any arterial segment assessed, might improve the probability of correctly diagnosing GCA in patients with clinical features suggestive of GCA [35,36]. Moreover, it confirms that additional ultrasound assessment of stenosis or occlusion is no longer necessary to support the diagnosis of GCA [37].

In the cross-sectional analysis of all patients with GCA who had a halo sign on ultrasound we observed a significantly smaller TA halo size during the 7-day period from commencing high doses of GCs. This was demonstrated by looking at the maximum TA halo size per patient ( $r = -0.30$ ,  $p = 0.001$ ) or by considering all TA halos reported ( $r = -0.23$ ,  $p < 0.001$ ). Although in both cases the negative correlation was weak, when performing an ANOVA analysis, we observed significantly smaller halos between baseline and  $\geq 4$  days of GC treatment. Therefore, these findings support the use of TA ultrasound as a potential surrogate marker for disease activity and response to GCs, even in the early stages of treatment ( $\leq 7$  days). In addition, our current data (albeit limited by its cross-sectional design) establishes the rationale for undertaking prospective monitoring studies using ultrasound as a biomarker. We anticipate this will be particularly useful in the future for patients treated with IL-6 inhibitors [34,38] because they will limit the usefulness of CRP and ESR to monitor activity. In addition, our data corroborates the need for rapid diagnostic assessment in GCA, because prior to or in the first few days of GC treatment, the TA halo size is larger and therefore is more visible upon ultrasound examination and less likely to be missed by the sonographers. This fact could explain the decrease in sensitivity with treatment observed by Hauenstein and colleagues [39], using ultrasound, that ranged from 88%

in the first day of GCs to 50% following >4 days of GCs. For patients with large-vessel (LV) involvement of the disease (LV-GCA), the cross-sectional analysis of the AX halos showed no correlation between halo size and number of days on GCs in the first 7 days of treatment, which could be explained by the fact that in larger arteries the halo sign takes much longer time to disappear [31,40] and therefore a week would not be enough to see a significant variation. However, only a small proportion of patients with GCA and halo sign had at least one axillary halo (27.2%). Prospective studies with longer duration and in individual patients are warranted to assess the long-term relation of halo sign thickness with features of GCA.

When looking at the potential predictive role of the presence of halo at baseline with the occurrence of new ischaemic events at 2-weeks and 6-months, no association was found. Nevertheless, when evaluating the presence of new or maintained symptoms, patients with halo sign at baseline had more visual symptoms at 2-weeks and 6-months, reflecting the irreversible nature of eye involvement in this disease. This predictive assessment is however limited by the lack of follow-up data after 6-months.

In summary, we conclude that in newly diagnosed GCA, if a halo sign is detected, its presence is associated with manifestations of ischaemic symptoms and abnormal findings at examination of the ipsilateral side. Furthermore, its size is affected by the duration of GC treatment. These findings encourage the early use of the halo sign as a biomarker of response to treatment and enhance its potential prognostic role for the presence of irreversible ischaemic features of the disease (e.g. vision loss).

**Acknowledgements:** Mike Bradburn from Sheffield University (CTU) contributed to this study by providing the data from the PROSPECT database. Investigators from all TABUL sites.

**Disclosure statement:** the authors have declared no conflicts of interest.

**Funding statement:** The TABUL study is supported by the National Institute for Health Research Health Technology Assessment (NIHR HTA Ref No. 08/64/01).

## References

1. Jennette JC, Falk RJ, Bacon PA, Basu N, Cid MC, Ferrario F, et al. 2012 Revised International Chapel Hill Consensus Conference Nomenclature of Vasculitides. *Arthritis & Rheumatism*. 2013 Jan;65(1):1–11.
2. Devauchelle-Pensec V, Jousse S, Destombe C, Saraux A. Epidemiology, imaging, and treatment of giant cell arteritis. *Joint Bone Spine*. 2008 May;75(3):267–72.
3. González-Gay MA, García-Porrúa C, Llorca J, Hajeer AH, Brañas F, Dababneh A, et al. Visual manifestations of giant cell arteritis. Trends and clinical spectrum in 161 patients.



- Medicine (Baltimore). 2000 Sep;79(5):283–92.
4. Laskou F, Coath F, Mackie SL, Banerjee S, Aung T, Dasgupta B. A probability score to aid the diagnosis of suspected giant cell arteritis. *Clinical and Experimental Rheumatology*. 2019;5.
  5. Siemssen SJ. On the occurrence of necrotising lesions in arteritis temporalis: review of the literature with a note on the potential risk of a biopsy. *British Journal of Plastic Surgery*. 1987 Jan;40(1):73–82.
  6. Bhatti MT, Goldstein MH. Facial nerve injury following superficial temporal artery biopsy. *Dermatol Surg*. 2001 Jan;27(1):15–7.
  7. Yoon MK, Horton JC, McCulley TJ. Facial nerve injury: a complication of superficial temporal artery biopsy. *Am J Ophthalmol*. 2011 Aug;152(2):251-255.e1.
  8. Murchison AP, Bilyk JR. Brow Ptosis after Temporal Artery Biopsy. *Ophthalmology*. 2012 Dec;119(12):2637–42.
  9. Luqmani R, Lee E, Singh S, Gillett M, Schmidt WA, Bradburn M, et al. The Role of Ultrasound Compared to Biopsy of Temporal Arteries in the Diagnosis and Treatment of Giant Cell Arteritis (TABUL): a diagnostic accuracy and cost-effectiveness study. *Health Technol Assess*. 2016 Nov;20(90):1–238.
  10. Karassa FB, Matsagas MI, Schmidt WA, Ioannidis JPA. Meta-Analysis: Test Performance of Ultrasonography for Giant-Cell Arteritis. *Ann Intern Med*. 2005 Mar 1;142(5):359.
  11. Ball EL, Walsh SR, Tang TY, Gohil R, Clarke JMF. Role of ultrasonography in the diagnosis of temporal arteritis. *Br J Surg*. 2010 Dec;97(12):1765–71.
  12. Arida A, Kyprianou M, Kanakis M, Sfikakis PP. The diagnostic value of ultrasonography-derived edema of the temporal artery wall in giant cell arteritis: a second meta-analysis. *BMC Musculoskelet Disord*. 2010 Dec;11(1):44.
  13. Duftner C, Dejaco C, Sepriano A, Falzon L, Schmidt WA, Ramiro S. Imaging in diagnosis, outcome prediction and monitoring of large vessel vasculitis: a systematic literature review and meta-analysis informing the EULAR recommendations. *RMD Open*. 2018 Feb;4(1):e000612.
  14. Rinagel M, Chatelus E, Jousse-Joulin S, Sibilia J, Gottenberg J-E, Chasset F, et al. Diagnostic performance of temporal artery ultrasound for the diagnosis of giant cell arteritis: a systematic review and meta-analysis of the literature. *Autoimmunity Reviews*. 2019 Jan;18(1):56–61.
  15. Schmidt WA, Kraft HE, Vorpahl K, Völker L, Gromnica-Ihle EJ. Color Duplex Ultrasonography in the Diagnosis of Temporal Arteritis. *N Engl J Med*. 1997 Nov 6;337(19):1336–42.
  16. Chrysidis S, Duftner C, Dejaco C, Schäfer VS, Ramiro S, Carrara G, et al. Definitions and reliability assessment of elementary ultrasound lesions in giant cell arteritis: a study from the OMERACT Large Vessel Vasculitis Ultrasound Working Group. *RMD Open*. 2018;4(1):e000598.
  17. Dejaco C, Ramiro S, Duftner C, Besson FL, Bley TA, Blockmans D, et al. EULAR recommendations for the use of imaging in large vessel vasculitis in clinical practice. *Ann Rheum Dis*. 2018;77(5):636–43.
  18. Karahaliou M, Vaiopoulos G, Papaspyrou S, Kanakis MA, Revenas K, Sfikakis PP. Colour duplex sonography of temporal arteries before decision for biopsy: a prospective study in 55 patients with suspected giant cell arteritis. *Arthritis Res Ther*. 2006;8(4):R116.
  19. De Miguel E, Roxo A, Castillo C, Peiteado D, Villalba A, Martín-Mola E. The utility and sensitivity of colour Doppler ultrasound in monitoring changes in giant cell arteritis. *Clin Exp Rheumatol*. 2012 Feb;30(1 Suppl 70):S34-38.
  20. Czihal M, Schröttle A, Baustel K, Lottspeich C, Dechant C, Treitl M, et al. B-mode sonography wall thickness assessment of the temporal and axillary arteries for the diagnosis of giant cell arteritis: a cohort study. *Clinical and Experimental Rheumatology*.

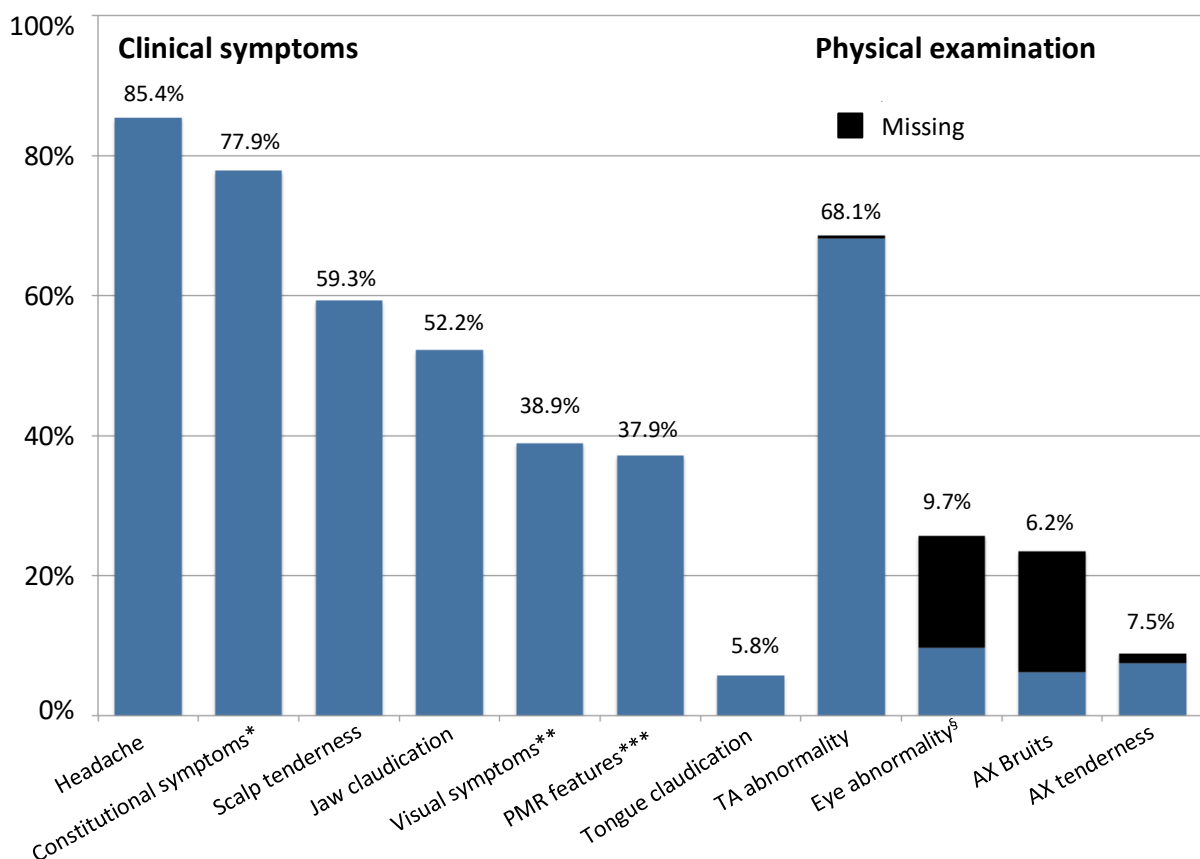
- 2017;6.
21. Salvarani C, Silingardi M, Ghirarduzzi A, Lo Scocco G, Macchioni P, Bajocchi G, et al. Is duplex ultrasonography useful for the diagnosis of giant-cell arteritis? *Ann Intern Med.* 2002 Aug 20;137(4):232–8.
  22. Förster, Tato, Weiss, Czihal, Rominger, Bartenstein, et al. Patterns of extracranial involvement in newly diagnosed giant cell arteritis assessed by physical examination, colour coded duplex sonography and FDG-PET. *Vasa.* 2011 May;40(3):219–27.
  23. Ghinoi A, Pipitone N, Nicolini A, Boiardi L, Silingardi M, Germano G, et al. Large-vessel involvement in recent-onset giant cell arteritis: a case-control colour-Doppler sonography study. *Rheumatology.* 2012 Apr 1;51(4):730–4.
  24. Schäfer VS, Juche A, Ramiro S, Krause A, Schmidt WA. Ultrasound cut-off values for intima-media thickness of temporal, facial and axillary arteries in giant cell arteritis. *Rheumatology.* 2017 Sep 1;56(9):1479–83.
  25. Habib HM, Essa AA, Hassan AA. Color duplex ultrasonography of temporal arteries: role in diagnosis and follow-up of suspected cases of temporal arteritis. *Clin Rheumatol.* 2012 Feb;31(2):231–7.
  26. Schmidt WA. Ultrasound in the diagnosis and management of giant cell arteritis. *Rheumatology.* 2018 Feb 1;57(suppl\_2):ii22–31.
  27. Pérez López J, Solans Laqué R, Bosch Gil JA, Molina Cateriano C, Huguet Redecilla P, Vilardell Tarrés M. Colour-duplex ultrasonography of the temporal and ophthalmic arteries in the diagnosis and follow-up of giant cell arteritis. *Clin Exp Rheumatol.* 2009 Feb;27(1 Suppl 52):S77-82.
  28. Monti S, Floris A, Ponte CB, Schmidt WA, Diamantopoulos AP, Pereira C, et al. The proposed role of ultrasound in the management of giant cell arteritis in routine clinical practice. *Rheumatology (Oxford).* 2018 01;57(1):112–9.
  29. Czihal M, Zanker S, Rademacher A, Tatò F, Kuhlencordt P, Schulze-Koops H, et al. Sonographic and clinical pattern of extracranial and cranial giant cell arteritis. *Scandinavian Journal of Rheumatology.* 2012 May;41(3):231–6.
  30. Schmidt WA, Krause A, Schicke B, Kuchenbecker J, Gromnica-Ihle E. Do temporal artery duplex ultrasound findings correlate with ophthalmic complications in giant cell arteritis? *Rheumatology.* 2009 Jan 30;48(4):383–5.
  31. Schmidt WA, Seifert A, Gromnica-Ihle E, Krause A, Natusch A. Ultrasound of proximal upper extremity arteries to increase the diagnostic yield in large-vessel giant cell arteritis. *Rheumatology.* 2008 Jan 1;47(1):96–101.
  32. Monti S, Floris A, Ponte C, Schmidt WA, Diamantopoulos AP, Pereira C, et al. The use of ultrasound to assess giant cell arteritis: review of the current evidence and practical guide for the rheumatologist. *Rheumatology (Oxford).* 2018 Feb 1;57(2):227–35.
  33. Piper J, Serafim AS, Ponte C, Singh S, Dasgupta B, Schmidt WA, et al. A Diagnostic Protocol for Giant Cell Arteritis (GCA) Using Ultrasound Assessment [Internet]. *ACR Meeting Abstracts.* 2014 [cited 2019 Dec 10]. Available from: <https://acrabstracts.org/abstract/a-diagnostic-protocol-for-giant-cell-arteritis-gca-using-ultrasound-assessment/>
  34. Hellmich B, Agueda A, Monti S, Buttgereit F, de Boysson H, Brouwer E, et al. 2018 Update of the EULAR recommendations for the management of large vessel vasculitis. *Ann Rheum Dis.* 2019 Jul 3;
  35. Monti S, Ponte C, Pereira C, Manzoni F, Klersy C, Rumi F, et al. The impact of disease extent and severity detected by quantitative ultrasound analysis in the diagnosis and outcome of giant cell arteritis. *Rheumatology.* 2019 Dec 17;kez554.
  36. van der Geest KSM, Borg F, Kayani A, Paap D, Gondo P, Schmidt W, et al. Novel ultrasonographic Halo Score for giant cell arteritis: assessment of diagnostic accuracy and association with ocular ischaemia. *Ann Rheum Dis.* 2020 Jan 3;
  37. Chrysidis S, Duftner C, Dejaco C, Schäfer VS, Ramiro S, Carrara G, et al. Definitions and

reliability assessment of elementary ultrasound lesions in giant cell arteritis: a study from the OMERACT Large Vessel Vasculitis Ultrasound Working Group. *RMD Open*. 2018;4(1):e000598.

38. Stone JH, Tuckwell K, Dimonaco S, Klearman M, Aringer M, Blockmans D, et al. Trial of Tocilizumab in Giant-Cell Arteritis. *N Engl J Med*. 2017 Jul 27;377(4):317–28.
39. Hauenstein C, Reinhard M, Geiger J, Markl M, Hetzel A, Treszl A, et al. Effects of early corticosteroid treatment on magnetic resonance imaging and ultrasonography findings in giant cell arteritis. *Rheumatology (Oxford)*. 2012 Nov;51(11):1999–2003.
40. Aschwanden M, Schegk E, Imfeld S, Staub D, Rottenburger C, Berger CT, et al. Vessel wall plasticity in large vessel giant cell arteritis: an ultrasound follow-up study. *Rheumatology*. 2019 May 1;58(5):792–7.

## Supplementary material

**Supplementary Figure S1.** Presenting symptoms and physical examination of patients with the diagnosis of giant cell arteritis



AX: axillary arteries; PMR: polymyalgia rheumatica; TA: temporal arteries

\* Constitutional symptoms - fatigue, anorexia, fever or night sweats

\*\* Visual symptoms - reduced or lost vision in either eye, double vision, or amaurosis fugax

\*\*\* PMR features - new onset of bilateral shoulder pain, early morning stiffness or hip stiffness or pain

<sup>§</sup> Eye abnormality - anterior ischaemic optic neuropathy, posterior ischaemic optic neuropathy, relative afferent pupillary defect and III/IV/VI nerve palsy

**Supplementary Table 1: Association between ultrasound findings and final diagnosis of GCA**

	Diagnosis of GCA (N=226)	No diagnosis of GCA (N=119)	p-value*
<b>Ultrasound findings - N/N of patients (%)</b>			
Presence of halo sign	121/226 (53.5)	31/119 (26.1)	<b>&lt;0.001</b>
TA halo	114/226 (50.4)	30/119 (25.2)	<b>&lt;0.001</b>
AX halo	34/226 (15.0)	6/119 (5.0)	<b>0.006</b>
Presence of stenosis	24/114 (21.1)	6/34 (17.6)	0.665
TA stenosis	24/111 (21.6)	8/36 (22.2)	0.940
AX stenosis	6/33 (18.2)	1/10 (10.0)	0.539
Presence of occlusion	26/120 (21.7)	4/37 (10.8)	0.142
TA occlusion	26/116 (22.4)	4/34 (11.8)	0.172
AX occlusion	0/32 (0)	1/10 (10)	0.070
Presence of arteriosclerosis	49/117 (41.9)	14/38 (36.8)	0.583
TA arteriosclerosis	43/109 (39.4)	11/34 (32.4)	0.456
AX arteriosclerosis	10/34 (29.4)	4/11 (36.4)	0.665
<b>Halo general characteristics - N/N of patients (%)</b>			
Halo sign with adjusted IMT cut-offs (TA or AX) **	107/224 (47.8)	19/119 (16.0)	<b>&lt;0.001</b>
TA halo with adjusted IMT cut-offs **	101/224 (45.0)	17/118 (14.4)	<b>&lt;0.001</b>
AX halo with adjusted IMT cut-offs **	21/225 (9.3)	3/119 (2.5)	<b>0.013</b>
Bilateral halo (TA or AX)	72/226 (31.9)	12/119 (10.1)	<b>&lt;0.001</b>
Bilateral TA halo	67/226 (29.6)	12/119 (10.1)	<b>&lt;0.001</b>
Bilateral AX halo	15/226 (5.8)	2/119 (1.7)	<b>0.043</b>
TA halo without AX halo	87/226 (38.5)	25/119 (21.0)	<b>0.001</b>
TA halo with AX halo	27/226 (11.9)	5/119 (4.2)	<b>0.018</b>
<b>Number of arterial segments with the presence of halo - N/N of patients (%)</b>			
≥ 1 arterial segments	121/226 (53.5)	31/119 (26.1)	<b>&lt;0.001</b>
≥ 2 arterial segments	93/226 (41.2)	19/119 (16.0)	<b>&lt;0.001</b>
≥ 3 arterial segments	67/226 (29.6)	7/119 (5.9)	<b>&lt;0.001</b>
≥ 4 arterial segments	54/226 (23.9)	4/119 (3.4)	<b>&lt;0.001</b>
≥ 5 arterial segments	37/226 (16.4)	3/119 (2.5)	<b>&lt;0.001</b>
≥ 6 arterial segments	33/226 (14.6)	2/119 (1.7)	<b>&lt;0.001</b>
≥ 7 arterial segments	25/226 (11.1)	1/119 (0.8)	<b>0.001</b>
≥ 8 arterial segments	17/226 (7.5)	0/119 (0)	<b>0.002</b>
10 arterial segments	3/226 (1.3)	0/119 (0)	0.207
<b>Halo thickness - mean (SD)</b>			
Maximum TA halo thickness (141 patients)	0.81±0.44	0.47±0.33	<b>&lt;0.001</b>
Mean TA halo thickness (452 TA halos)	0.70±0.35	0.48±0.31	<b>&lt;0.001</b>
Maximum AX halo thickness (39 patients)	1.39±1.02	1.05±0.37	0.290
Mean AX halo thickness (56 AX halos)	1.35±1.03	1.05±0.34	0.371

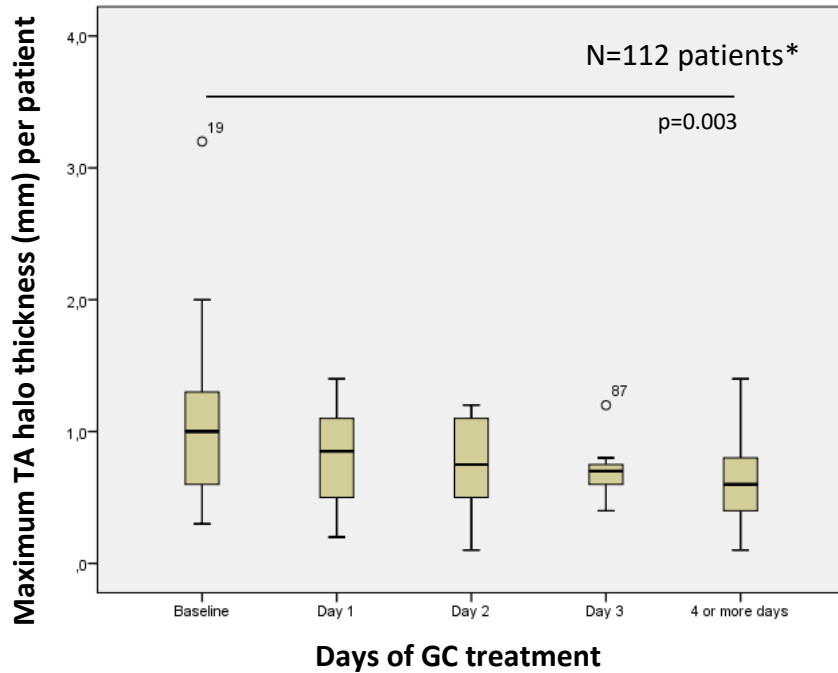
AX: axillary artery; GCA: giant cell arteritis; IMT: intima-media thickness; TA: temporal artery

\*Pearson's Chi-squared test, student's independent t-test or the Mann-Whitney U test; in bold the statistically significant values (p<0.05)

\*\*Cut-offs for common superficial temporal arteries, frontal and parietal branches, and axillary arteries of 0.42, 0.34, 0.29, and 1.0mm, respectively [24]

**Supplementary Figure S2. Boxplot-graphics with of TA halo thickness according to the number of days on GC treatment**

**A. Maximum TA halo thickness per patient with GCA**



ANOVA model:  $p=0.006$  between groups

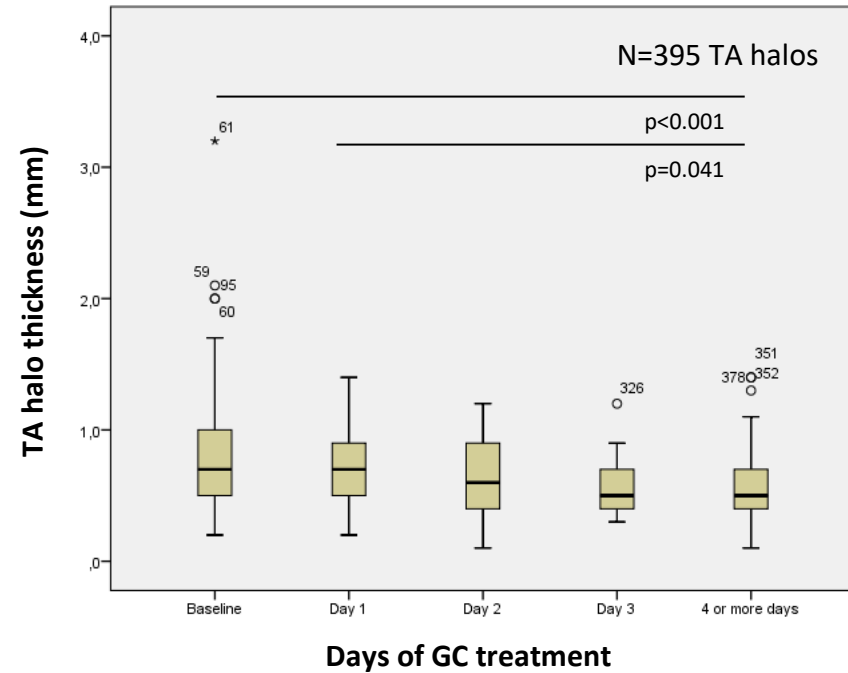
With the removal of outlier n19 no relevant change was seen in the performance characteristics of the model

\*Patients with GCA who had at least one measurement of IMT for TA halo reported.

Day 0 represents the patients who haven't started GC or started GC on that same day.

GCA: giant cell arteritis; GC: glucocorticoid; IMT: intima-media thickness, TA: temporal artery

**B. Halo thickness of all TA segments from patients with GCA**

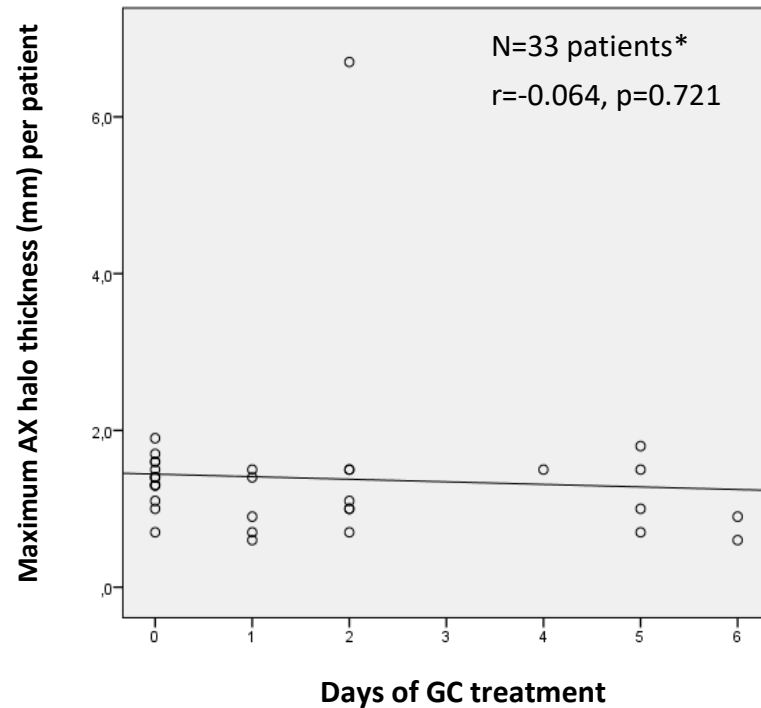


ANOVA model:  $p<0.001$  between groups

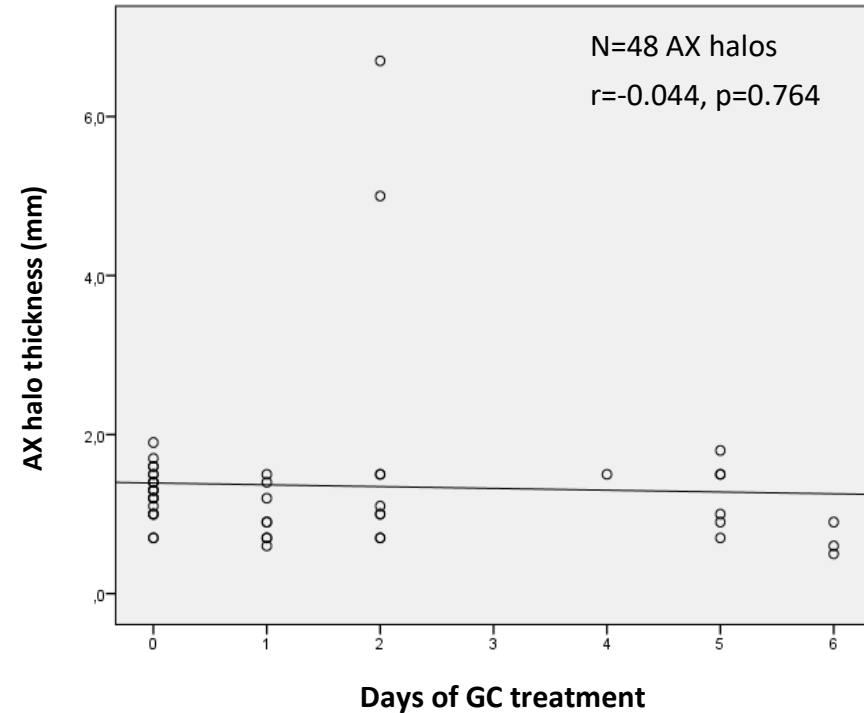
With the removal of outlier n61 no relevant change was seen in the performance characteristics of the model

**Supplementary Figure S3.** Scattered-plots with variation of AX halo thickness according to number of days on GC treatment

**A. Maximum AX halo thickness per patient with GCA**



**B. Halo thickness of all AX segments from patients with GCA**



With the removal of the outliers from day 3 no relevant changes were seen in the performance characteristics of the model

\* Patients with GCA who had at least one measurement of IMT for AX halo reported

Day 0 represents the patients who haven't started GC or started GC on that same day; r: Pearson's regression coefficient

AX: axillary artery; GCA: giant cell arteritis; GC: glucocorticoid; IMT: intima-media thickness