



Deposited via The University of Sheffield.

White Rose Research Online URL for this paper:

<https://eprints.whiterose.ac.uk/id/eprint/160849/>

Version: Accepted Version

Article:

Borysewicz-Sańczyk, H., Sawicka, B., Michalak, J. et al. (2020) Case report: A 10-year-old girl with primary hypoparathyroidism and systemic lupus erythematosus. *Journal of Pediatric Endocrinology and Metabolism*, 33 (9). pp. 1231-1235. ISSN: 0334-018X

<https://doi.org/10.1515/jpem-2020-0015>

© 2020 Walter de Gruyter GmbH, Berlin/Boston. This is an author-produced version of a paper subsequently published in *Journal of Pediatric Endocrinology and Metabolism*. Uploaded in accordance with the publisher's self-archiving policy.

Reuse

Items deposited in White Rose Research Online are protected by copyright, with all rights reserved unless indicated otherwise. They may be downloaded and/or printed for private study, or other acts as permitted by national copyright laws. The publisher or other rights holders may allow further reproduction and re-use of the full text version. This is indicated by the licence information on the White Rose Research Online record for the item.

Takedown

If you consider content in White Rose Research Online to be in breach of UK law, please notify us by emailing eprints@whiterose.ac.uk including the URL of the record and the reason for the withdrawal request.

1 **Case report: A 10-year-old girl with primary hypoparathyroidism and systemic lupus**
2 **erythematosus**

3

4 Hanna Borysewicz-Sańczyk¹, Beata Sawicka¹, Justyna Michalak¹, Jerzy Wójtowicz¹, Elżbieta
5 Dobreńko², Jerzy Konstantynowicz², E. Helen Kemp³, Rajesh V. Thakker⁴, Jeremy Allgrove⁵,
6 Fadil Hanna⁴, Artur Bossowski¹

7 ¹Department of Pediatrics, Endocrinology, Diabetology with a Cardiology Division, Medical
8 University of Białystok, Poland; ²Department of Pediatrics, Rheumatology, Immunology and
9 Metabolic Bone Diseases, Medical University of Białystok, Poland; ³Department of Oncology
10 and Metabolism, University of Sheffield, Sheffield, UK; ⁴Academic Endocrine Unit, Radcliffe
11 Department of Medicine, Oxford Centre for Diabetes, Endocrinology and Metabolism,
12 University of Oxford, Oxford, UK; ⁵Department of Pediatric Endocrinology, Great Ormond
13 Street Hospital for Children, London, UK.

14

15 Corresponding authors:

16 Hanna Borysewicz-Sańczyk,

17 Department of Paediatrics, Endocrinology, Diabetology with Cardiology Division,
18 Medical University of Białystok, ul. Waszyngtona 17, 15-274 Białystok, Poland.

19 E-mail: hannaborysewicz@poczta.fm; Tel: +48 85 74 50 732; Fax: +48 85 74 50 730; ORCID
20 ID: <https://orcid.org/0000-0003-4932-1983>

21 Professor Artur Bossowski, MD, PhD

22 Department of Paediatrics, Endocrinology, Diabetology with Cardiology Division,
23 Medical University of Białystok, ul. Waszyngtona 17, 15-274 Białystok, Poland.

24 E-mail: abossowski@hotmail.com; Tel: +48 85 74 50 735; Fax: +48 85 74 50 730; ORCID ID:
25 <https://orcid.org/0000-0002-6316-5342>

26 **Word count:** 1571 (text not including abstract, references or figure legends)

27 **Figures:** 1

28 **Tables:** 1

29 **Author statements**

30 **Author contributions:** All the authors have accepted responsibility for the entire content of
31 this submitted manuscript and approved its submission.

32 **Research funding:** None to declare.

33 **Employment or leadership:** None to declare.

34 **Honorarium:** None to declare.

35 **Competing interests:** No funding organisation played a role in the study design, the
36 collection, analysis, and interpretation of data, the writing of the report or in the decision to
37 submit the report for publication.

38 **Ethical statement:** Not applicable.

39 **Disclosure of potential conflicts of interest:** None to declare.

40 **Research involving human participants and/or animals:** Not applicable.

41 **Informed consent:** Informed consent was obtained from the parents of the patient for the
42 preparation of this manuscript.

43 **Abstract**

44 Hypoparathyroidism is a rare disease in children that occurs as a result of autoimmune
45 destruction of the parathyroid glands, a defect in parathyroid gland development or secondary
46 to physical parathyroid gland disturbance. Typical symptoms of hypoparathyroidism present as
47 hypocalcaemia and hyperphosphatemia due to decreased parathyroid hormone secretion and
48 may lead to nerve and muscles disturbances resulting in clinical manifestation of tetany,
49 arrhythmias and epilepsy. Currently, there is no conventional hormone replacement treatment
50 for hypoparathyroidism and therapeutic approaches include normalising mineral levels using
51 an oral calcium supplement and active forms of vitamin D. We present the case of a 10-year-
52 old girl with primary hypoparathyroidism who had no prior history of autoimmune disorders,
53 but who subsequently developed systemic lupus erythematosus.

54

55 **Keywords:** primary hypoparathyroidism, hypocalcaemia, hyperphosphatemia, parathyroid
56 hormone, systemic lupus erythematosus, autoimmune polyglandular syndrome.

57 **Background**

58 Hypoparathyroidism is a rare endocrine disease in children caused by parathyroid hormone
59 (PTH) deficiency or resistance to PTH [1]. Primary hypoparathyroidism may occur as a result
60 of either autoimmune destruction of the parathyroid glands, a congenital defect of parathyroid
61 gland development as in DiGeorge 22q11.2 deletion syndrome, mutations in the calcium-
62 sensing receptor gene, damage to the parathyroids during surgery, most commonly in the
63 course of thyroidectomy, or following radiation treatment of the neck [2-4]. The typical
64 manifestations of the disease present when all four parathyroid glands are affected and include
65 hypocalcaemia, hyperphosphatemia and low serum PTH concentrations. The serum mineral
66 abnormalities affect nerve and muscle functions leading to tetany, arrhythmias and seizures.
67 There is no conventional hormone replacement therapy and the management of
68 hypocalcaemia and hyperphosphatemia involves an oral calcium supplement and active forms
69 of vitamin D [3].

70 Here, we present the case of a 10-year-old girl with primary hypoparathyroidism who had no
71 prior history of autoimmune disorders, but who developed systemic lupus erythematosus
72 (SLE) a few months after her diagnosis of hypoparathyroidism. To date, there are only a few
73 reported cases of the coexistence of hypoparathyroidism and SLE [5].

74 **Case presentation**

75 A 10-year-old Polish female initially presented to the Department of Paediatric Neurology
76 and Rehabilitation with convulsions. Following a confirmation of hypocalcaemia she was
77 referred to the Department of Paediatrics, Endocrinology, Diabetology with Cardiology with
78 suspected hypoparathyroidism. The patient had no history of mucocutaneous candidiasis and
79 no history suggesting an endocrine or autoimmune disorder in her family. Her mental
80 development was normal. Her weight was 35 kg (6th percentile of 10-year-old females) and
81 her height was 141 cm (50th percentile of 10-year-old females). She was in early puberty at
82 stage 2 on the Tanner scale, based on breast development.

83 The patient was admitted to our department severely unwell with drowsiness and confusion.

84 The physical examination revealed a whole body rash that was attributed to an allergic
85 reaction to oxcarbazepine that was being used for the treatment of convulsions. She had no
86 features of ectodermal dystrophy or any signs of primary adrenal insufficiency.

87 Hypoparathyroidism was diagnosed based on very low PTH levels at <3 pg/mL (reference
88 range, 10-69 pg/mL), low total serum calcium levels at 0.80 mmol/L (reference range, 2.19-
89 2.69 mmol/L) (Figure 1) and high plasma phosphate levels at 11.8 mg/dL (reference range,
90 3.4-6.2 mg/dL) (Figure 1). Alkaline phosphatase levels and serum magnesium concentrations
91 were normal. Total serum vitamin D was low at 35 nmol/L (reference range, 50-150 nmol/L).
92 Urinary calcium levels were lower than normal at admission.

93 Hormone analysis showed normal thyroid function (thyroid-stimulating hormone at 1.76
94 IU/L, reference range, 0.28-4.3 IU/L; free T4 at 23 pmol/L, reference range, 14-22 pmol/L).

95 Adrenal function tests were within the normal range (cortisol at 347.3 nmol/L;
96 adrenocorticotrophic hormone at 2.8 pmol/L; adequate peak cortisol level of 749.5 nmol/L
97 after 250 µg of tetracosactin by intravenous injection). Markers for specific for autoimmune
98 diseases including antibodies against interferon (IFN)- ω , 21-hydroxylase, 17- α -hydroxylase,

99 the calcium-sensing receptor, the acetylcholine receptor, and tissue transglutaminase were not
100 detected (Table 1). Autoantibodies associated with autoimmune thyroid disease and type 1
101 diabetes were also undetectable (Table 1). In blood morphology analysis, there were
102 periodical findings indicating anaemia, leucopaenia and hypoalbuminaemia in biochemical
103 tests.

104 Ultrasonography revealed a slightly enlarged spleen without any features of nephrocalcinosis
105 and no parathyroid pathology. Echocardiography (ECG) did not reveal any heart defect.
106 However, effusion in the pericardium was observed coinciding with the fever and elevated
107 inflammatory markers. Long QTc (over 0.5 seconds) was recorded in the ECG. A bone
108 densitometry scan showed normal values for bone mass density of the spine L2-L4 (Z-score
109 +0.5) and for total body less head (Z-score +0.1). There was no ectopic calcification observed
110 in magnetic resonance imaging (MRI) of the head. A positron emission tomography-magnetic
111 resonance imaging (PET-MRI) scan of the whole body did not reveal any other pathologies.
112 Electroencephalography was abnormal with pathological changes localised in temporal areas
113 on both sides during activity and generalised paroxysmal patterns during sleep. However,
114 there were no more epileptic seizures during clinical observation.

115 The patient was started on intravenous calcium gluconate at 5.5 g elemental calcium/day
116 along with oral calcium carbonate (0.8 g elemental calcium/day), vitamin D (2000 IU/day)
117 and the synthetic precursor of the active form of vitamin D3, alfacalcidol (2 µg/day).
118 Hyperphosphatemia was initially treated with a diet low in phosphates. She was also treated
119 with valproic acid for epilepsy, metoprolol for long QTc, and hydrocortisone for the first nine
120 days to reduce her allergy symptoms. The patient's condition improved and her total serum
121 calcium levels increased, although they remained below the normal range (Figure 1).

122 After fourteen days of hospitalisation, the patient developed a fever with pneumonia and
123 pericardial effusion together with increased inflammatory markers in laboratory tests. C-

124 reactive protein increased significantly from 30.2 to 1497 nmol/L (reference range, 0-47
125 nmol/L). She was treated with antibiotics, although the blood cultures returned negative
126 results. There was no evidence of either viral infections including HIV, B19 parvovirus,
127 influenza or of zoonoses or tuberculosis. Furthermore, neoplastic disease was excluded
128 following a bone marrow biopsy. During the course of a chest infection, her total serum
129 calcium levels dropped to below 2 mmol/L. After three weeks of hospitalisation and with a
130 high plasma phosphate level of 9.20 mg/dL, she was given sevelamer (initial dose 2.4 g/day),
131 a phosphate-binding medication, to reduce hyperphosphatemia (Figure 1). Finally, the patient
132 was discharged on regular oral calcium carbonate (3.6 g elemental calcium/day), sevelamer
133 (4.8 g/day) and alphacalcidol (1 µg/day).

134 Taken together, the clinical symptoms, laboratory test results and the criteria of the American
135 College of Rheumatology for SLE, in particular, epilepsy, leucopaenia, pericardial effusion
136 and anti-nuclear antibodies, the patient was diagnosed with SLE. She was treated
137 subsequently with chloroquine phosphate and oral prednisone (5 mg/day). This treatment
138 unexpectedly improved the patient's calcium and phosphate levels (Figure 1) and allowed a
139 reduction in the doses of calcium, sevelamer and vitamin D. During monthly follow up visits,
140 the patient's serum calcium and phosphate levels continued to normalise (Figure 1), albeit
141 with episodes of hypercalcaemia.

142 At four months follow-up, the patient was re-evaluated for anti-IFN- ω and anti-21-hydroxylase
143 antibodies. She was found positive for IFN- ω antibodies (antibody index 21.4, reference range
144 <5.0) (Table 1). To further investigate the cause of the hypoparathyroidism, we evaluated
145 genetic mutations that are typically connected with the disease. Mutational analysis of genes
146 encoding the calcium-sensing receptor (*CASR*), guanine nucleotide-binding protein subunit
147 alpha-11 (*GNA11*), PTH (*PTH*), glial cells missing transcription factor 2 (*GCM2*),
148 autoimmune regulator (*AIRE*) and GATA binding protein 3 (*GATA3*) were all negative. In

149 addition, whole exome sequence variants in established disease genes and candidate variants
150 in genes not yet associated with disease were negative. However, it revealed a heterozygous
151 microdeletion in chromosome 15q11.2, inherited from the father and not reported previously
152 to be in association with hypoparathyroidism.

153 **Discussion**

154 The combination of hypoparathyroidism and SLE is extremely rare therefore the underlying
155 causes and significance of these diseases occurring in conjunction is intriguing.

156 Hypoparathyroidism can be caused by several factors including autoimmunity affecting the
157 parathyroid glands, damage to parathyroid glands and genetic mutations such as DiGeorge
158 syndrome or calcium-sensing receptor-activating mutations [6, 7]. In this case, secondary
159 hypoparathyroidism could immediately be discounted as the patient had had no surgery or
160 trauma to the neck or parathyroid glands. The patient did not display symptoms associated
161 with DiGeorge syndrome nor with calcium-sensing receptor-activating mutations. This was
162 supported by mutational analysis, which did not reveal mutations in the *CASR* gene. In view
163 of the above and the association with SLE, it was expected that hypoparathyroidism in this
164 patient had an underlying autoimmune origin.

165 An autoimmune aetiology of the hypoparathyroidism in our patient was considered after her
166 hypocalcaemia improved with glucocorticoid treatment. Autoimmune hypoparathyroidism is
167 a major component of autoimmune polyglandular syndrome type 1 (APS1) along with chronic
168 mucocutaneous candidiasis and primary adrenal insufficiency (Addison's disease) [8-12].

169 APS1 commonly manifests in childhood and our patient presents with one of the major
170 components. However, she does not fully adhere to an APS1 diagnosis as she does not display
171 other symptoms currently. In addition, *AIRE* gene analysis in our patient did not identify
172 typical known genetic mutations that cause APS1. However, there may be *AIRE* gene
173 mutations not detected by our analysis and further in-depth mutational analysis is planned.

174 IFN- ω antibodies are highly specific for APS1 [13,14]. Interestingly, our patient initially
175 tested negative for IFN- ω antibodies, but proved positive on re-testing several months after
176 her initial hypoparathyroidism diagnosis. This might suggest that she is progressing towards
177 APS1 and may in time develop another major APS1 autoimmunity. Therefore, monitoring for

178 chronic mucocutaneous candidiasis and Addison's disease would seem appropriate in the
179 future. Considering an alternative APS diagnosis, there have been occasional reports of
180 hypoparathyroidism occurring in other APS types [10, 11]. The patient does not conform to
181 an APS2 (Addison's disease, thyroid disease and/or type 1 diabetes) or APS3 (thyroid disease
182 plus one other non-Addison's disease autoimmunity) diagnosis. Thus APS4 (two or more
183 autoimmune diseases not in APS types 1, 2 or 3) was considered. Our patient currently has
184 two autoimmune diseases thus fulfils the criteria for APS4, however, as she matures, she may
185 develop additional autoimmune endocrinopathies and her diagnosis might alter accordingly.

186 In summary, our case report describes the presentation and diagnosis of a 10-year-old girl
187 with hypoparathyroidism who subsequently developed SLE. We suggest that an autoimmune
188 mechanism, potentially associated with an underlying genetic predisposition, is responsible
189 for the disease combination seen in our patient.

190 **Acknowledgements**

191 We are grateful to Jadwiga Furmaniak, Sarah Black, Shu Chen and Bernard Rees Smith

192 (FIRS Laboratories, RSR Ltd., Cardiff, UK) for performing autoantibody tests.

193 **References**

- 194 [1] Liu MJ, Li JW, Shi XY, Hu LY, Zou LP. Epileptic seizure, as the first symptom of
195 hypoparathyroidism in children, does not require antiepileptic drugs. *Childs Nerv Syst* 2017;
196 33:297-305.
- 197 [2] Yoo DY, Kim HJ, Cho KH, Kwon EB, Yoo EG. Delayed diagnosis of 22q11 deletion
198 syndrome due to late onset hypocalcemia in an 11-year-old girl with imperforated anus. *Ann*
199 *Pediatr Endocrinol Metab* 2017;22:133-8.
- 200 [3] Mishra PE, Schwartz BL, Sarafoglou K, Hook K, Kim Y, Petryk A. Short-Term PTH(1-
201 34) therapy in children to correct severe hypocalcemia and hyperphosphatemia due to
202 hypoparathyroidism: Two case studies. *Case Rep Endocrinol* 2016;
203 <http://dx.doi.org/10.1155/2016/6838626>.
- 204 [4] Nordenström E, Bergenfelz A, Almquist M. Permanent hypoparathyroidism after total
205 thyroidectomy in children: Results from a national registry. *World J Surg* 2018;42:2858-63.
- 206 [5] Sahebari M, Afkhamizadeh M, Hashemzadeh K, Pezeshki Rad M. Development of
207 systemic lupus erythematosus in a patient with hypoparathyroidism: A case report and review
208 of the literature. *Int J Rheum Dis* 2010;13:175-9.
- 209 [6] Fukumoto S, Namba N, Ozono K, Yamauchi M, Sugimoto T, Michigami T, et al. Causes
210 and differential diagnosis of hypocalcemia - recommendation proposed by expert panel
211 supported by ministry of health, labour and welfare. *Japan Endocr J* 2008;55:787-94.
- 212 [7] Nillawar AN, Mitul Chhatriwala. A case of idiopathic hypoparathyroidism with systemic
213 lupus erythematosus. *WIMJOURNAL* 2016;3:58-66.
- 214 [8] Krysiak R, Kobielski-Gembala I, Okopień B. Atypical clinical presentation of
215 autoimmune polyglandular syndrome type 4. *Przegl Lek* 2011;68:339-41.

- 216 [9] Krysiak R, Okopień B, Bóldys A. Autoimmune polyglandular syndromes. *Przegl Lek*
217 2008;65:393-400.
- 218 [10] Melcescu E, Kemp EH, Majithia V, Vijayakumar V, Uwaifo GI, Koch CA. Graves'
219 disease, hypoparathyroidism, systemic lupus erythematosus, alopecia and angioedema:
220 autoimmune polyglandular syndrome variant or coincidence? *Int J Immunopathol Pharmacol*
221 2013;26:217-22.
- 222 [11] Kemp EH, Kahaly GJ, Porter JA, Frommer L, Weetman AP. Autoantibodies against the
223 calcium-sensing receptor and cytokines in autoimmune polyglandular syndromes types 2, 3
224 and 4. *Clin Endocrinol* 2018;88:139–45.
- 225 [12] Seifi-Alan M, Shamsi R, Setoodeh A, Sayarifard F, Aghasi P, Kompani F, et al.
226 Autoimmune polyendocrinopathy-candidiasis-ectodermal dystrophy: Report of three cases
227 from Iran. *J Pediatr Endocrinol Metab* 2016;29:979-83.
- 228 [13] Meloni A, Furcas M, Cetani F, Marcocci C, Falorni A, Perniola R, et al. Autoantibodies
229 against type I interferons as an additional diagnostic criterion for autoimmune polyendocrine
230 syndrome type I. *J Clin Endocrinol Metab* 2008;93:4389-97.
- 231 [14] Ferre EMN, Rose SR, Rosenzweig SD, Burbelo PD, Romito KR, Niemela JE, et al.
232 Redefined clinical features and diagnostic criteria in autoimmune polyendocrinopathy-
233 candidiasis-ectodermal dystrophy. *J Clin Invest Insight* 2016;1:1-18.

234 **Figure legend**

235

236 **Figure 1.** The patient's total serum calcium and plasma phosphate concentrations over time.

237 Shading indicates the reference ranges (total serum calcium, 2.19-2.69 mmol/L; plasma

238 phosphate, 3.4-6.2 mg/dL). The patient's blood calcium levels were initially low

239 (hypocalcaemia) and plasma phosphate levels were initially high (hyperphosphatemia), but

240 both normalised following treatment with calcium and prednisone. The start-points of

241 treatment with sevelamer (4.8 g/day) and prednisone (5 mg/day) are indicated.

242 **Table 1.** Autoantibody screening of the patient

243

Antibody target	Positive/negative	Result	Reference range
Diabetes screening (Zinc transporter 8; glutamic acid decarboxylase; islet antigen IA2)	Negative	6.7 (index)	≤30 (index)
Interferon-ω (07.03.2018)	Negative	<5 (index)	<5 (index)
Interferon-ω (27.06.2018)	Positive	21.4 (index)	<5 (index)
21-hydroxylase	Negative	<0.4 u/mL	≤0.4 u/mL
Calcium-sensing receptor	Negative	0.52 (index)	1.37 (index)
Acetylcholine receptor	Negative	<0.45 nmol/L	<0.45 nmol/L
17-α-hydroxylase	Negative	<1 U/mL	<1 U/mL
Tissue transglutaminase	Negative	0.4 U/mL	<4 U/mL
Thyroid peroxidase	Negative	5.9 IU/mL	<34 IU/mL
Thyroglobulin	Negative	13.6 IU/mL	<115 IU/mL
Thyroid-stimulating hormone receptor	Negative	0.35 IU/L	<1.75 IU/L

244

245 **Learning points**

246 1. Hypoparathyroidism in children might be caused by an autoimmune process, damage to the
247 parathyroid glands or a genetic disorder.

248 2. The typical manifestations of the disease are hypocalcaemia and hyperphosphataemia that
249 affect nerve and muscle functions leading to tetany, arrhythmias and seizures.

250 3. Autoimmune hypoparathyroidism is often associated with other autoimmune diseases to
251 constitute autoimmune polyglandular syndromes, typically APS1.

252 4. The management of hypocalcaemia and hyperphosphatemia following decreased PTH
253 concentrations involves supplementation with calcium and active forms of vitamin D.

254

255 **What is new?**

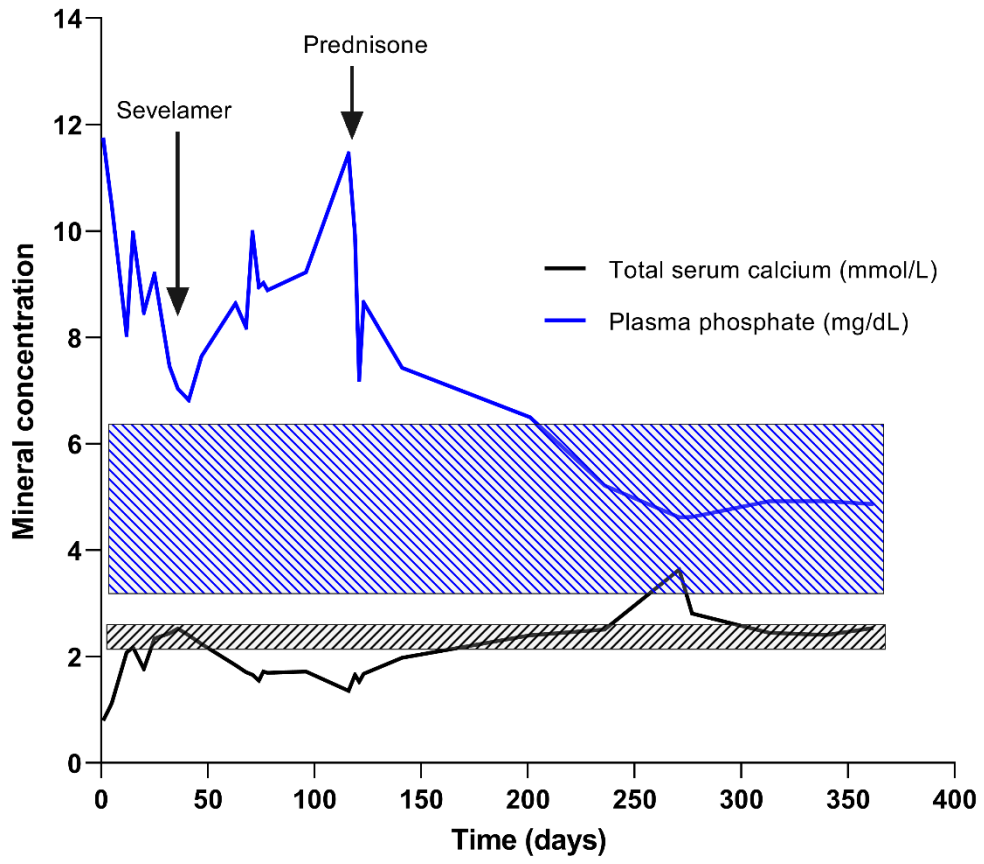
256 - The coexistence of hypoparathyroidism and SLE is extremely rare in children and is not
257 typical for APS1.

258 - The normalisation of calcium and phosphate blood concentrations after glucocorticoid
259 treatment for SLE, reversed the symptoms of hypoparathyroidism indicating a possible
260 autoimmune basis for the disease.

261

262 **Figure 1**

263



264