



This is a repository copy of *Cognitive deficit and white matter changes in persons with celiac disease: a population-based study*.

White Rose Research Online URL for this paper:
<https://eprints.whiterose.ac.uk/157779/>

Version: Supplemental Material

Article:

Croall, I.D., Sanders, D.S., Hadjivassiliou, M. orcid.org/0000-0003-2542-8954 et al. (1 more author) (2020) Cognitive deficit and white matter changes in persons with celiac disease: a population-based study. *Gastroenterology*, 158 (8). pp. 2112-2122. ISSN 0016-5085

<https://doi.org/10.1053/j.gastro.2020.02.028>

Article available under the terms of the CC-BY-NC-ND licence
(<https://creativecommons.org/licenses/by-nc-nd/4.0/>).

Reuse

This article is distributed under the terms of the Creative Commons Attribution-NonCommercial-NoDerivs (CC BY-NC-ND) licence. This licence only allows you to download this work and share it with others as long as you credit the authors, but you can't change the article in any way or use it commercially. More information and the full terms of the licence here: <https://creativecommons.org/licenses/>

Takedown

If you consider content in White Rose Research Online to be in breach of UK law, please notify us by emailing eprints@whiterose.ac.uk including the URL of the record and the reason for the withdrawal request.



eprints@whiterose.ac.uk
<https://eprints.whiterose.ac.uk/>

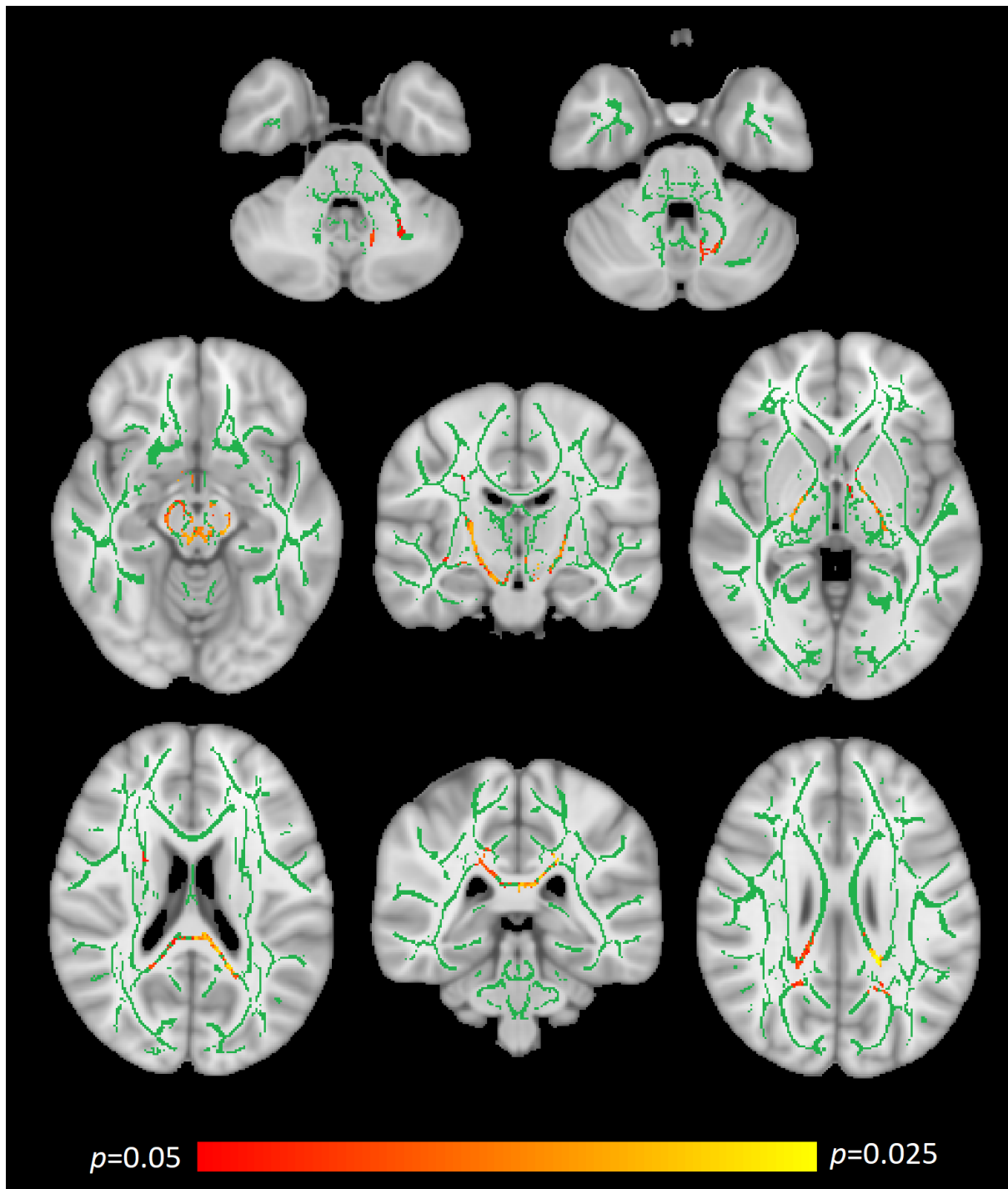


Figure 2. TBSS outputs showing areas of significant Axial Diffusivity (AD) increase in the Coeliac group (red / yellow locations; green indicates no significant change). TOP ROW- cerebellar white matter; MIDDLE ROW- ascending white matter including the red nucleus (left), brainstem (middle) and extending into the thalamus (right); BOTTOM ROW- forceps major (left and middle) and superior longitudinal fasciculus (right).