



Deposited via The University of Leeds.

White Rose Research Online URL for this paper:

<https://eprints.whiterose.ac.uk/id/eprint/150850/>

Version: Accepted Version

---

**Article:**

Muralidhar, S, Fila, A, Nsengimana, J et al. (2019) Vitamin D-VDR signaling inhibits Wnt/beta-catenin-mediated melanoma progression and promotes anti-tumor immunity. *Cancer Research*, 79 (23). pp. 5986-5998. ISSN: 0008-5472

<https://doi.org/10.1158/0008-5472.CAN-18-3927>

---

© 2019, American Association for Cancer Research. This is an author produced version of a journal article published in *Cancer Research*. Uploaded in accordance with the publisher's self-archiving policy.

**Reuse**

Items deposited in White Rose Research Online are protected by copyright, with all rights reserved unless indicated otherwise. They may be downloaded and/or printed for private study, or other acts as permitted by national copyright laws. The publisher or other rights holders may allow further reproduction and re-use of the full text version. This is indicated by the licence information on the White Rose Research Online record for the item.

**Takedown**

If you consider content in White Rose Research Online to be in breach of UK law, please notify us by emailing [eprints@whiterose.ac.uk](mailto:eprints@whiterose.ac.uk) including the URL of the record and the reason for the withdrawal request.

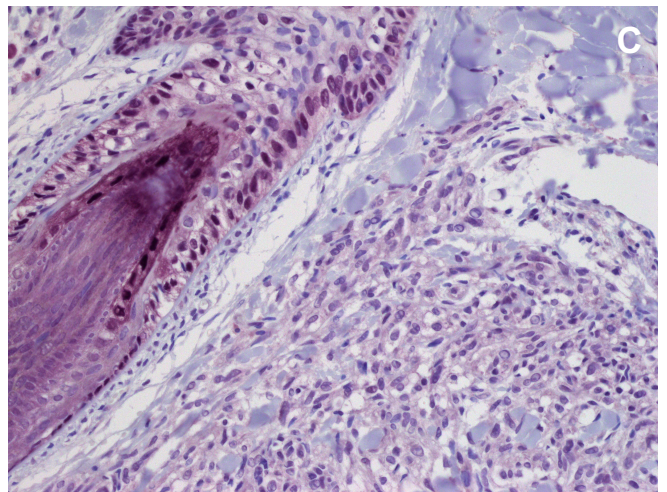
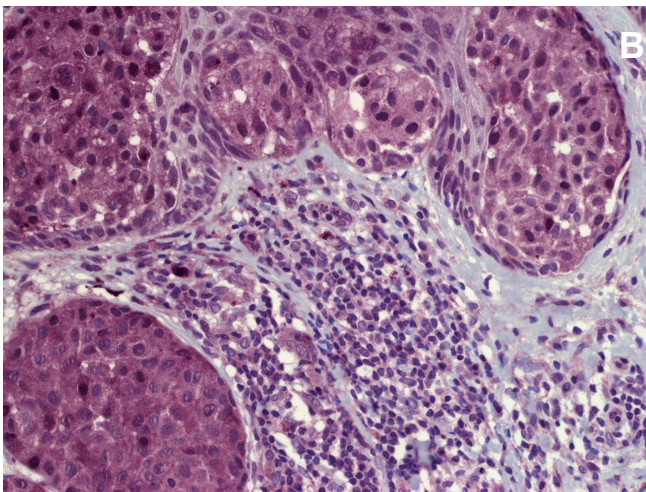
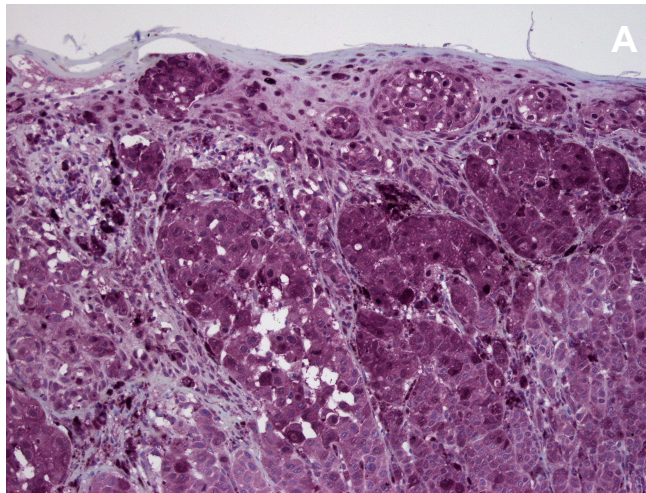
## Supplementary Figure 1

Immunohistochemistry of tumor sections from the LMC for VDR expression.

A) Representative image of strong VDR expression in primary melanoma demonstrating cytoplasmic and occasional nuclear-localised immuno-staining (purple chromagen, 10x magnification). In association with the tumor, strong VDR staining is apparent in the epidermis, most commonly seen in the nuclei of keratinocytes which was used as an intra slide positive control (see Image C). Tumor associated stroma demonstrates much weaker VDR expression.

B) Representative image of strong VDR expression in a primary tumor, both cytoplasmic and nuclear in localisation, and in contrast weak cytoplasmic to absent VDR expression in the surrounding stroma (20x magnification). Lymphocytes demonstrate weak cytoplasmic to absent VDR expression whilst a small proportion display nuclear immuno-labeling.

C) Representative image of weak VDR expression in primary melanoma, in association with weak to absent stromal expression of VDR (20x magnification). In contrast, strong nuclear VDR staining is apparent in the root sheath keratinocytes of the hair follicle.



## Supplementary Figure 2

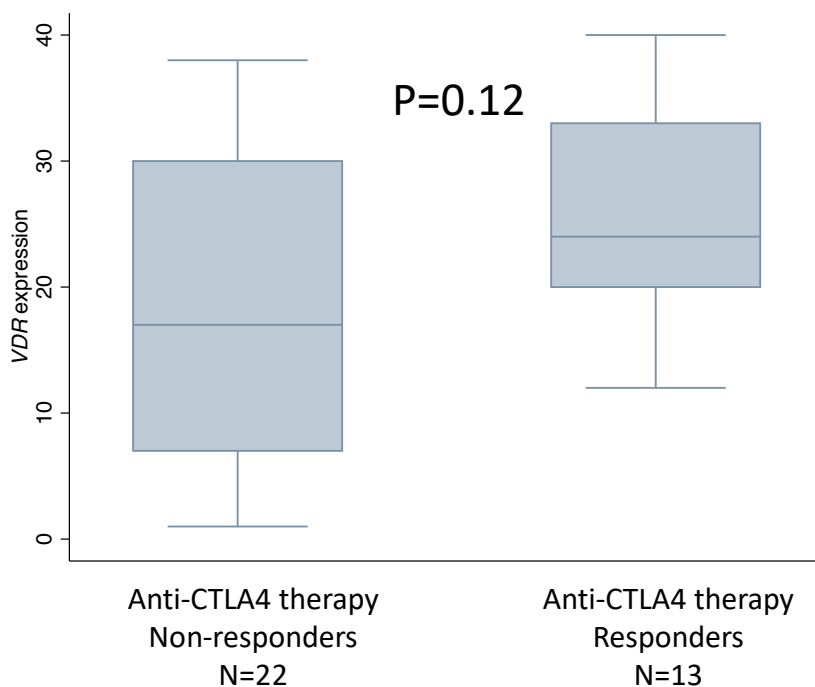
Comparison of VDR expression between primary melanomas of patients who responded and did not respond to immunotherapy.

A) Comparison of VDR expression between responders and non-responders to anti-CTLA4, using data published by Van Allen et al

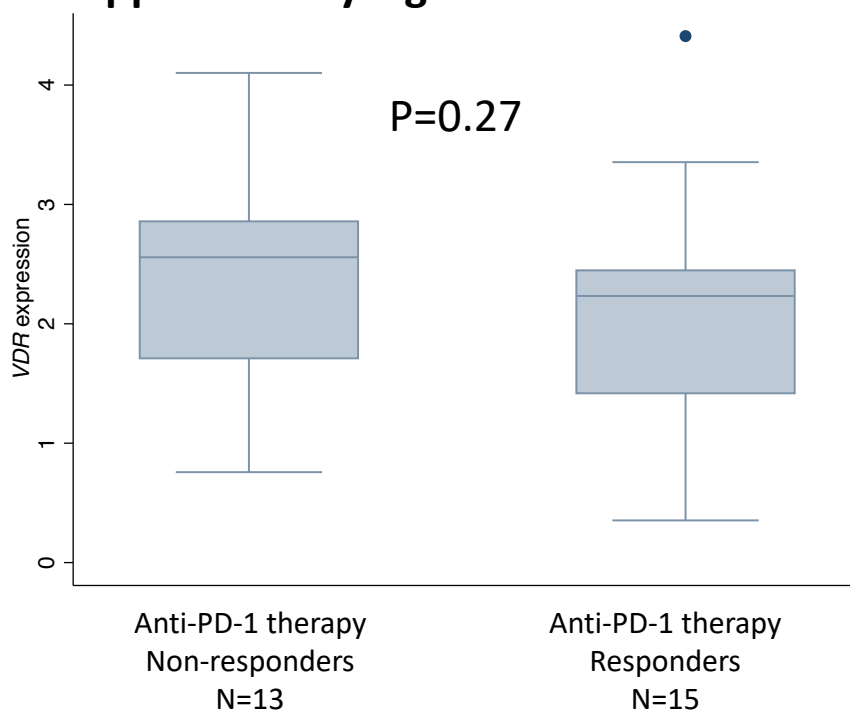
B) Comparison of VDR expression between responders and non-responders to anti-PD-1, using data published by Hugo et al

P values from Kruskal-Wallis test

### Supplementary Figure 2A



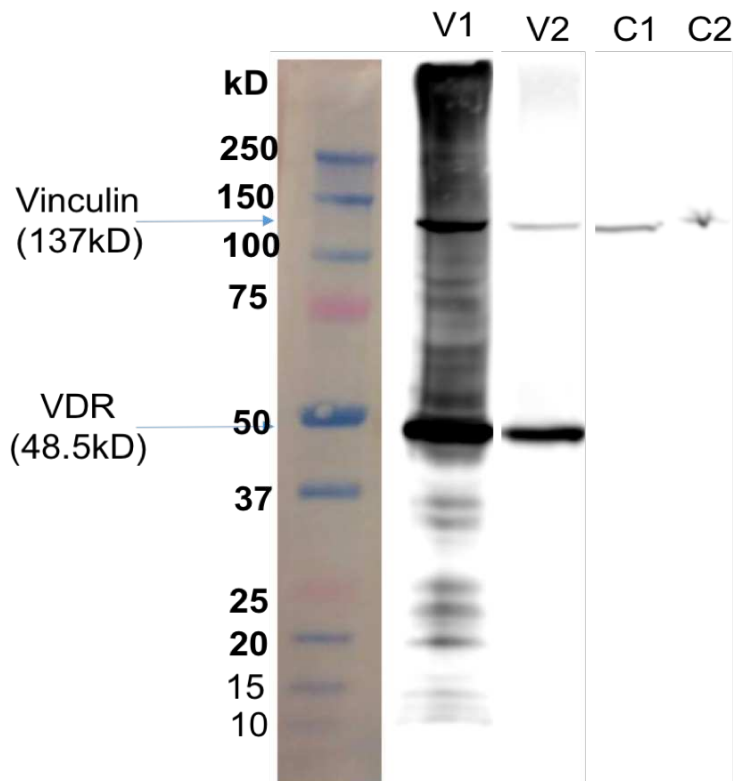
### Supplementary Figure 2B



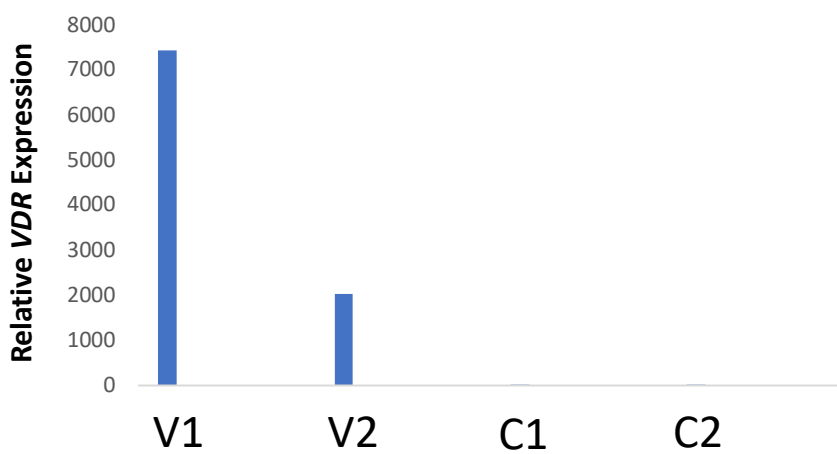
### Supplementary Figure 3

A) Western blot for murine VDR (48.5Kda) expression in the two VDR-transfected clones (V1 and V2) compared to control clones C1 and C2. Vinculin (137kDa) is used as housekeeping control  
B) qRT-PCR comparing expression of murine VDR in the two VDR-transfected clones (V1 and V2) compared to control clones C1 and C2 (Fold changes reported relative to clone C1).  
house gene used: *GAPDH*

### Supplementary Figure 3A



### Supplementary Figure 3B



## Supplementary Figure 4

Comparison of number of CD3 positive tumour infiltrating lymphocytes in pulmonary sections from mice injected with VDR-B16-BL6 (V1 and V2) and control: B16-BL6 cells (C1 and C2).  
P value from Mann-Whitney U-test.

