

MRI for Detecting Root Avulsions in Traumatic Adult Brachial Plexus Injuries: A Systematic Review and Meta-Analysis of Diagnostic Accuracy

Ryckie G. Wade, MBBS, MSc, MClinEd, MRCS, FHEA • Yemisi Takwoingi, DVM, MSc, PhD • Justin C. R. Wormald, MBBS, MRes, MRCS • John P. Ridgway, BSc, MSc, PhD • Steven Tanner, BSc, MSc, PhD • James J. Rankine, MBChB, MRCP, MRad, FRCR, MD • Grainne Bourke, MB, BCh, BAO, FRCSI, FRCS(Plast)

From the Department of Plastic and Reconstructive Surgery, Academic Plastic Surgery Office (R.G.W., G.B.), Department of Medical Physics and Engineering (J.P.R., S.T.), and Department of Musculoskeletal Radiology (J.J.R.), Leeds Teaching Hospitals Trust, Leeds General Infirmary, Leeds LS1 3EX, England; Faculty of Medicine and Health Sciences, University of Leeds, Leeds, England (R.G.W., G.B.); Institute of Applied Health Research, University of Birmingham, Birmingham, England (Y.T.); Nuffield Department of Orthopaedics, Rheumatology and Musculoskeletal Sciences, University of Oxford, Oxford, England (J.C.R.W.); Department of Plastic and Reconstructive Surgery, Stoke Mandeville Hospital, Buckinghamshire Healthcare NHS Trust, Aylesbury, England (J.C.R.W.); and National Institute for Health Research Leeds Biomedical Research Centre, Leeds, England (J.P.R., S.T., J.J.R.). Received January 30, 2019; revision requested April 15; final revision received May 24; accepted June 17. **Address correspondence to** R.G.W. (e-mail: ryckiewade@gmail.com).

R.G.W. is supported by the National Institute for Health Research (NIHR) through a doctoral research fellowship award (DRF-2018-11-ST1-159) in Leeds. Y.T. is supported by the NIHR through a postdoctoral fellowship award (PDF-2017-10-059) and the NIHR Birmingham Biomedical Research Centre. The views expressed in this publication are those of the author(s) and not necessarily those of the National Health Service, the NIHR, or the Department of Health and Social Care.

Conflicts of interest are listed at the end of this article.

Radiology 2019; 293:125–133 • <https://doi.org/10.1148/radiol.2019190218> • Content codes: **NR MR ER**

Background: Traumatic brachial plexus injuries affect 1% of patients involved in major trauma. MRI is the best test for traumatic brachial plexus injuries, although its ability to differentiate root avulsions (which require urgent reconstructive surgery) from other types of nerve injury remains unknown.

Purpose: To evaluate the accuracy of MRI for diagnosing root avulsions in adults with traumatic brachial plexus injuries.

Materials and Methods: For this systematic review, MEDLINE and Embase were searched from inception to August 20, 2018. Studies of adults with traumatic nonpenetrating unilateral brachial plexus injuries were included. The target condition was root avulsion. The index test was preoperative MRI, and the reference standard was surgical exploration. A bivariate meta-analysis was used to estimate summary sensitivities and specificities of MRI for avulsion.

Results: Eleven studies of 275 adults (mean age, 27 years; 229 men) performed between 1992 and 2016 were included. Most participants had been injured in motorcycle collisions (84%). All studies were at risk of bias, and there were high applicability concerns for the index test (ie, MRI) in four studies given the lack of diagnostic criteria, inadequate descriptions of pulse sequences, and multiplicity of reporting radiologists. Overall, 72% of patients with brachial plexus injuries had at least one root avulsion (interquartile range [IQR]: 53%–86%); meta-analysis of patient-level data was not performed because of sparse and heterogeneous data. With the nerve root as the unit of analysis, 583 of 918 roots were avulsed (median, 55%; IQR: 38%–71%); the mean sensitivity of MRI for root avulsion was 93% (95% confidence interval [CI]: 77%, 98%) with a mean specificity of 72% (95% CI: 42%, 90%).

Conclusion: On the basis of limited data, MRI offers modest diagnostic accuracy for traumatic brachial plexus root avulsion(s), and early surgical exploration should remain as the preferred method of diagnosis.

Published under a CC BY 4.0 license.

Online supplemental material is available for this article.

Traumatic brachial plexus injuries affect 1% of patients involved in major trauma (1). Brachial plexus injuries may cause permanent disability (2–6), pain (6–8), psychologic morbidity (9,10), and reduced quality of life (2,4,11). Early reconstructive nerve surgery is associated with better functional recovery in the upper limb (2,3,11,12), which improves quality of life (4).

Nerve reconstruction for patients with root avulsion(s) is a clinical priority for several reasons. After root avulsion, the cell bodies of motor neurons in the spinal cord recede (4,5,12,13), so the limb never reanimates spontaneously. Because reimplantation of avulsed roots yields no meaningful recovery (14–16), nerve transfers are performed,

which significantly improves function (11,17–20). Nerve transfers are relatively minor and cost-effective procedures (21,22) with low morbidity (20,23–25). Furthermore, 95% of patients with traumatic brachial plexus injuries have neuropathic pain (6), and the evolving evidence suggests that early reconstructive nerve surgery reduces cortical reorganization and thus neuropathic or phantom limb pain (26–28). Therefore, correctly identifying patients with root avulsions is of paramount importance.

MRI is the best noninvasive test for brachial plexus injuries (29). MRI is superior to nerve and muscle electrophysiology studies (30), US (31–34), and intraoperative somatosensory-evoked potentials (35). Currently, MRI

Abbreviations

CI = confidence interval, IQR = interquartile range, QUADAS = Quality Assessment of Diagnostic Accuracy Studies, SROC = summary receiver operating characteristic

Summary

This systematic review and diagnostic test accuracy meta-analysis shows that the overall accuracy of MRI for traumatic brachial plexus root avulsion is modest.

Key Results

- A systematic review and diagnostic test accuracy meta-analysis showed that 72% of patients with traumatic brachial plexus injuries had at least one root avulsion (interquartile range: 53%–86%).
- On average, MRI had a mean sensitivity of 93% and specificity of 72% for root avulsion, with surgical exploration as the reference standard.
- On the basis of these limited data, MRI has modest accuracy for diagnosing root avulsions following traumatic brachial plexus injury, and early surgical exploration should remain as the method of diagnosis.

is unable to help reliably differentiate root avulsion (and other nerve injuries proximal to the intervertebral exit foramen) from injuries outside the foramen. The delay from injury to surgical reconstruction is the leading cause of poor functional recovery (36–38). To identify patients with root avulsion who need urgent reconstructive nerve surgery, most surgeons use preoperative MRI, although the accuracy of this test remains a topic of debate. Therefore, the prevailing clinical practice involves either protracted observation (for months) or surgical exploration of the brachial plexus.

Numerous studies have examined aspects of MRI for traumatic brachial plexus injuries, and this review aims to evaluate its diagnostic accuracy for the identification of root avulsion(s) in adults with traumatic brachial plexus injuries.

Materials and Methods

This systematic review and meta-analysis was performed in accordance with our protocol (39) and was written in accordance with the Preferred Reporting Items for Systematic Reviews and Meta-Analyses—Diagnostic Test Accuracy, or PRISMA-DTA, Statement (40).

Participants and Studies

We included studies of adults with symptomatic brachial plexus injuries sustained from nonpenetrating trauma that reported the findings of preoperative MRI and surgical exploration of the roots of the brachial plexus. We excluded case reports and studies concerning bilateral injuries (41,42).

Target Condition

The primary target condition was avulsion of the root(s) of the brachial plexus. The secondary target condition was a pseudomeningocele, which is purported to be a surrogate marker of root avulsion. Our review was concerned with the ability of MRI to help distinguish between normal roots (no avulsions) and any frequency of root avulsion.

Index Test

The role of MRI is to depict root avulsion (Fig E1 [online]). This examination is typically performed within weeks of the injury and before surgery. The interpretation of MRI for root avulsion is binary, with an implicit threshold. Similarly, images are examined for the presence of a pseudomeningocele (sometimes erroneously termed meningocele), which is also a binary outcome with an implicit threshold. The target conditions can be observed at any spinal level, from C4 to T2, depending on the pattern of plexus fixation. Several systematic differences were expected, including the following: MRI unit brand and model, field strength, pulse sequences, software for postprocessing, and display hardware and viewing environment; these differences were investigated if possible.

Prior Tests

Patients typically undergo extensive clinical assessment and imaging. Some patients might undergo electrodiagnostic studies (nerve conduction and electromyography). All examination and medical test findings would typically be made available to the radiologist interpreting the MRI study.

Reference Standard

The reference standard was surgical exploration of the supraclavicular brachial plexus. This may be supplemented by hemilaminectomy, sensory evoked potentials, and bipolar motor nerve stimulation, and we consider these as part of the reference standard of “surgical exploration.”

Search Strategy

MEDLINE and Embase were searched from inception to August 20, 2018, with no restrictions (Appendix E1 [online]). Citations were independently deduplicated by two authors (R.G.W. and J.C.R.W., both academic plastic and reconstructive surgery registrars with 8 and 6 years of experience, respectively) and were independently screened.

Study Selection

Two authors (R.G.W. and J.C.R.W.) independently screened all citations. The full texts of potentially eligible articles were obtained and were independently assessed by the same two authors (39). Disagreements were resolved by discussion. Eligible articles were imported to Review Manager, version 5 (RevMan; the Nordic Cochrane Centre, the Cochrane Collaboration, Denmark) and were categorized as included or excluded.

Data Extraction

Two authors (R.G.W. and J.C.R.W.) independently extracted data concerning patient demographics (age and sex); mechanism of injury; time frames between injury, imaging, and surgery; imaging protocols; surgical steps; and test statistics to construct 2×2 tables of the number of true-positive findings, false-positive findings, false-negative findings, and true-negative findings. The authors of two studies (43,44) provided missing data.

Methodologic Quality Assessment

The risk of bias and the applicability of included studies was assessed by two authors (R.G.W. and J.C.R.W.) using a tailored version of the Quality Assessment of Diagnostic Accuracy Studies (QUADAS)-2 (Appendix E2 [online]) (39,45), and there were no disagreements.

Statistical Analysis

We used RevMan to generate forest plots and summary receiver operating characteristic (SROC) plots. Estimates of sensitivity and specificity were provided on forest plots. In Stata, version 15 (Stata, College Station, Tex), a bivariate meta-analytical model was used to obtain summary sensitivities and specificities, with the nerve as the unit of analysis (46–48). A meta-analysis of patient-level data was not performed because of sparse and heterogeneous data. To determine the effect of a covariate on the sensitivity and specificity of MRI, we planned a bivariate meta-regression, but this was not possible because of limited data. We did not assess publication bias because the determinants are not well understood for diagnostic accuracy reviews (48), and the Deeks test has low power in the presence of substantial heterogeneity (49). The significance level was set at 5%. Analyses were performed by R.G.W. and Y.T. (a biostatistician with 12 years of experience).

Results

Study Selection

A total of 1688 unique articles were identified (Fig 1). Eighty-six full texts were retrieved, of which 66 were excluded for the following reasons: narrative review ($n = 24$), no reference standard ($n = 17$), case report ($n = 7$), opinion piece ($n = 4$), no pre-operative MRI ($n = 3$), a systematic review ($n = 1$), a survey of brachial plexus imaging ($n = 1$), or irrelevant ($n = 9$). Nine articles were later excluded (50–58) because of missing outcome data (50,53–56,58), inability to disaggregate results (52,57), and a report of root avulsion within a series of patients with other nerve injuries that was treated as a case report (51). Ultimately, 11 articles (11 studies) (43,44,59–67) were included.

Study Characteristics

Study characteristics are presented in Table 1 and Table E1 (online). Studies originated from the United Kingdom (44,66), Sweden (59), China (63,67), Japan (61,62,65), Belgium (43), Italy (64), and Thailand (60). All studies were small, with a median sample size of 23 (interquartile range [IQR]: 9–31; range, 7–86), and had been performed between 1992 and 2016. One study (63) was reported as retrospective study, while the remainder did not describe the study design.

Overall, 275 adults with traumatic brachial plexus injuries were considered, of whom 229 (83%) were men. The mean age of the participants was 27 years (43,59,60,62–67), and 84% (145 of 173) had been injured during a motorcycle collision (60,62–66).

The unit of analysis and therefore the prevalence of root avulsion varied between studies (Table 1). Five studies

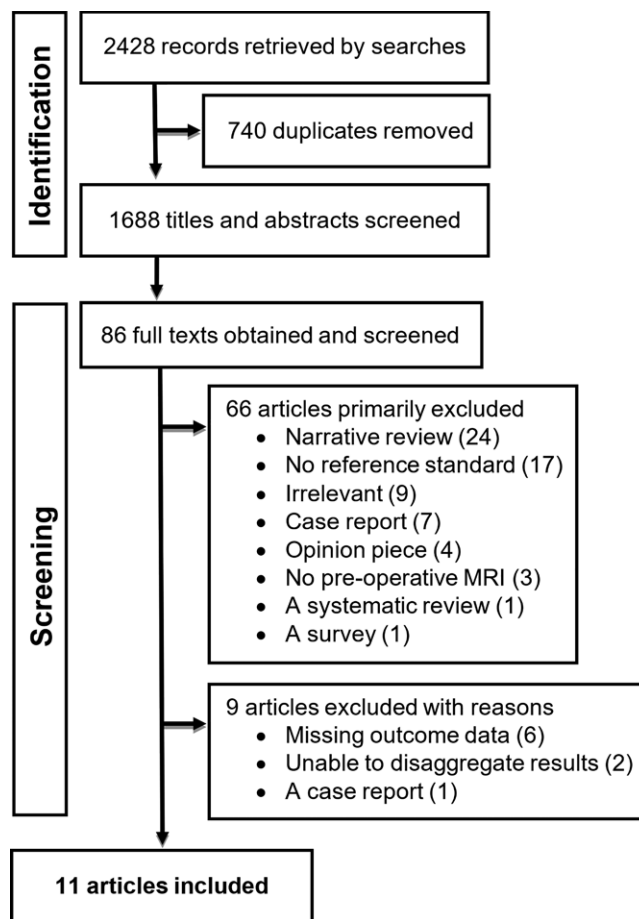


Figure 1: Study flow diagram.

(59,60,63,65,66) reported the accuracy of MRI for patients and nerves; two studies (43,44) reported results only at the patient level; three studies (62,64,67) reported the accuracy with the nerve as the exclusive unit of analysis; and the unit of analysis was unclear in one study (61), so it did not contribute to summary estimates. With the patient as the unit of analysis (43,44,59,60,63,65,66), 104 of 144 patients (median, 72%; IQR: 53%–86%) had at least one root avulsion. With the nerve as the unit of analysis (59,60,62–67), 583 of 918 roots were avulsed (median, 55%; IQR: 38%–71%).

The time from injury to MRI was reported in six studies (44,59,60,63,65,66) and varied considerably, with a median delay of 36 days (IQR: 26–66 days; range, 0–840 days). The time from injury to exploratory surgery was reported in four studies (59,60,66,67) and also varied, with a median delay of 67 days (IQR: 52–74 days; range, 6–399 days).

Risk of Bias and Applicability Concerns

The results of the risk of bias and applicability assessment are summarized in Figure 2. Six studies (43,60,61,63–65) were at unclear risk of selection bias because the sampling strategy was unclear or because patients were inappropriately excluded. The study by Hayashi et al (62) was at high risk of selection bias because of the retrospective exclusion of (an unknown number of) patients whose MRI images were suboptimal. The study by Yang et al (67) was also at high risk of selection bias because they

Table 1: Characteristics of Included Studies

Lead Author, Publication Year, and Study	Recruitment Time Frame	Location	Study Type	Participants Undergoing MRI and Surgical Exploration of the Roots of the Brachial Plexus					Overall Frequency of Root Avulsions	Description of Surgical Exploration of Brachial Plexus
				No. of Patients	Mean Patient Age (y)	Male: Female Ratio	Patients With at Least One Root Avulsion			
Abul-Kasim 2010 (59)	2000 to 2008	Sweden	Consecutive series; retrospective research	7	29	7:0	5 (71)	15 (44)	Clavicle splitting supra- and infraclavicular exploration by the same surgeon	
Chanlalit 2005 (60)	1997 to 2000	Thailand	Consecutive series; retrospective research	35	25.7	35:0	35 (100)	46 (66)	Supraclavicular exploration by the senior author	
Doi 2002 (61)	1995 to 1997	Japan	Not described	35	25.5	Not described	Not described	Not described	Supraclavicular exploration with intraoperative spinal root sensory evoked potentials, compared with a preoperatively placed epidural electrode	
Dubuisson 2002 (43)	1992 to 1995	Belgium	Not described	7	27	Approximately 4:1	3 (43)	Not described	Supraclavicular and infraclavicular exploration by the same surgeon, with or without a posterior approach if needed	
Gasparotti 1997 (64)	1993 to 1994	Italy	Consecutive series; temporality unknown	13	26	18:2	Not described	25 (40)	Supraclavicular exploration of selected roots by two experience neurosurgeons with intraoperative recording of sensory evoked potentials	
Hayashi 1998 (62)	1995 to 1996	Japan	Not described	25	22.8	25:2	Not described	40 (32)	Supraclavicular exploration of extravertebral roots with intraoperative recording of sensory evoked potentials	
Hems 1999 (44)	1997 to 1999	United Kingdom	Consecutive series; temporality unknown	23	30	23:0	11 (48)	Not described	Supraclavicular exploration; no further details	
Nakamura 1997 (65)	1993 to 1996	Japan	Consecutive series; temporality unknown	10	22	9:1	10 (100)	17 (34)	Exploration with intraoperative recording of sensory evoked potentials	
Qin 2016 (63)	2007 to 2012	China	Not described	33	33.5	10:1	23 (70)	96 (93)	Exploration with intraoperative recording of sensory evoked potentials	
Wade 2018 (66)	2008 to 2016	United Kingdom	Consecutive series; retrospective research	47	29	47:0	17 (36)	56 (39)	Supraclavicular exploration and assessment under loupe and operating microscope magnification by the senior author, alongside an intraoperative nerve stimulation.	
Yang 2014 (67)	2006 to 2010	China	Consecutive series; retrospective research	86	29	77:9	Not described	288 (88)	Exploration of the supraclavicular plexus with intraoperative sensory evoked potentials interpreted in relation to the index test	

Note.—Data in parentheses are percentages.

	Risk of Bias				Applicability Concerns		
	Patient Selection	Index Test	Reference Standard	Flow and Timing	Patient Selection	Index Test	Reference Standard
Abul-Kasim 2010	+	?	?	+	+	?	?
Chanlalit 2005	?	?	?	+	?	?	?
Doi 2002	?	+	?	?	?	+	?
Dubuisson 2002	?	-	?	?	?	-	?
Gasparotti 1997	?	+	?	?	?	?	?
Hayashi 1998	-	-	?	?	+	-	?
Hems 1999	+	?	?	+	+	?	?
Nakamura 1997	?	-	?	+	+	-	?
Qin 2016	?	-	?	+	+	-	?
Wade 2018	+	+	?	+	+	+	?
Yang 2014	-	?	?	+	?	?	?

- High	? Unclear	+ Low
---	---	--

Figure 2: Graph shows risk of bias and applicability concerns. For more information on how the judgments were made, see Appendix E2 (online).

inappropriately excluded individuals with concomitant injuries. Eight studies (43,44,59,60,62,63,65,67) were at risk for bias concerning the MRI examination; four studies (43,62,63,65) at high risk because no definition or threshold was described, and four studies (44,59,60,67) were at unclear risk because potential features of root avulsion were described but no criteria were provided. All 11 studies were at unclear risk of bias regarding the reference standard because the surgeons performing the exploration had knowledge of the MRI findings; additionally, partial verification bias was present in five studies (61–64,67). There was an unclear risk of bias in the flow and timing of four studies (43,61,62,64) owing to a lack of information about the time between injury and MRI or surgery.

Five articles (43,60,61,64,67) were of unclear concern regarding the applicability of patient selection because of nonconsecutive recruitment. There were applicability concerns for MRI in nine studies (43,44,59,60,62–65,67); four studies (43,62,63,65) were of high concern because no MRI criteria or thresholds were described, and five studies (44,59,60,64,67) were of unclear concern because multiple radiologists reported the images (59–64,67), the methods were not described (43,44,65), the description of the MRI protocol was different from the parameters shown in figures (60), or the pulse sequences were not adequately described (43,44,59,63–65,67). All 11 studies had

unclear applicability concerns regarding the reference standard because surgeons had knowledge of the MRI findings.

Synthesis of Results

Figure 3 shows the forest plots of the sensitivity and specificity of MRI for root avulsion, according to the unit of analysis. There was no apparent influence of field strength on diagnostic accuracy when the patient was the unit of analysis (Fig 3). When the nerve was the unit of analysis, 3.0-T MRI systems appeared to improve the sensitivity and reduce the specificity (Fig 3). Of note, all studies of MRI performed at 3.0 T reported the diagnostic accuracy with the nerve as the unit of analysis, while studies at lower field strengths (0.5 and 1.5 T) used patients.

With the nerve as the unit of analysis, the mean sensitivity of MRI for root avulsion was 93% (95% confidence interval [CI]: 77%, 98%), with a mean specificity of 72% (95% CI: 42%, 90%), as shown in Figure 4. The accuracy of MRI with the patient as the unit of analysis is summarized in a forest plot (Fig 3) and an SROC plot (Fig E2 [online]) and varied considerably; a meta-analysis was not possible owing to sparse and heterogenous data. The clinical consequences of using MRI to diagnose root avulsion are summarized in Table 2 using the median prevalence. There were insufficient data to allow us to estimate the effect of a covariate (eg, field strength) on the accuracy of MRI.

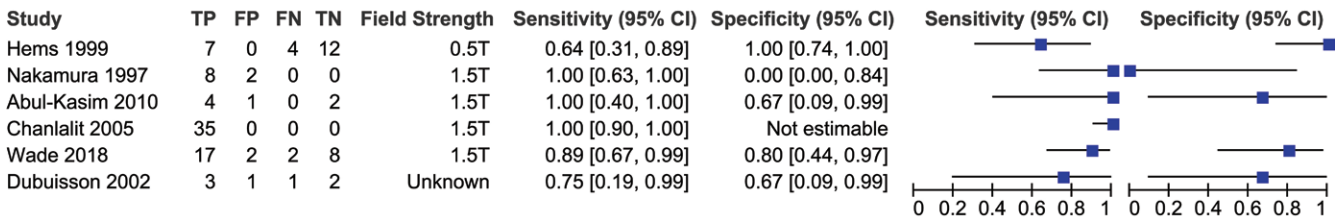
Forest plots of the sensitivity and specificity of pseudomeningoceles as a surrogate marker of root avulsion are shown in Figure 5. No meta-analysis was performed owing to the substantial heterogeneity and sparsity of data.

Discussion

MRI for traumatic brachial plexus root avulsion has a mean sensitivity of 93% (95% confidence interval [CI]: 77%, 98%) and a mean specificity of 72% (95% CI: 42%, 90%). This means that MRI fails to depict seven in 100 avulsed nerves and incorrectly classifies 28 in 100 nerves as avulsed when they are in continuity. Our data suggest that pseudomeningoceles are an unreliable marker of root avulsion. Moreover, the performance of MRI and the clinical consequences vary depending on the prevalence (Table 2).

MRI appears to have modest diagnostic accuracy for root avulsions in adults with traumatic brachial plexus injuries, which is unlikely to be acceptable to patients or surgeons given that a false-negative finding may cause irreversible morbidity. Moreover, it is probable that the diagnostic accuracy of MRI is worse than suggested because there were several methodologic concerns (68). Eight (73%) of 11 studies were at risk for selection bias (60–65,67), meaning that the samples may not be representative. For example, one study excluded patients whose images were suboptimal (62), which would upwardly bias the accuracy (69). Furthermore, there were issues in the reporting of MRI in all studies that hamper critical appraisal and translation to practice. We decided to ascribe an unclear risk of bias when surgeons knew the MRI findings because the effect of reviewer bias is inconsistent (69). Additionally, the lack of detail regarding pulse sequences limits both the reliability and external validity. Overall, the quality of the included studies in our review was

Root Avulsion: Unit of Analysis = Patients



Root Avulsion: Unit of Analysis = Nerves

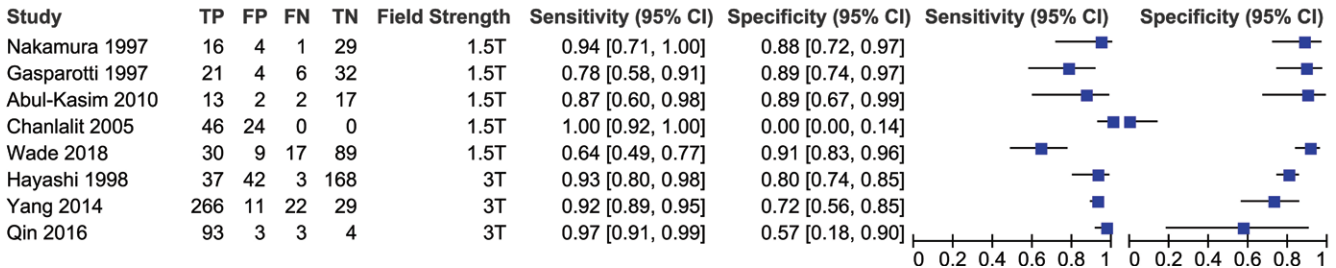


Figure 3: Forest plots of the sensitivity and specificity of MRI for root avulsion with patients as the unit of analysis (top) and nerves as the unit of analysis (bottom). CI = confidence interval, FN = false-negative, FP = false-positive, TN = true-negative, TP = true-positive.

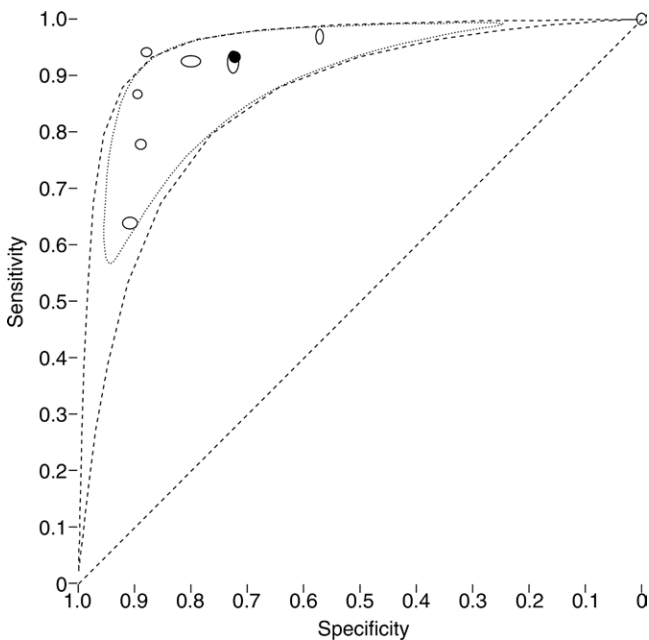


Figure 4: Summary receiver operating characteristic plot of MRI for root avulsion, with the nerve as the unit of analysis. Markers = studies and are scaled by sample size to indicate the precision of the estimates of sensitivity and specificity from each study. The dotted and dashed regions around the solid (summary) point = 95% confidence and 95% prediction regions.

poor because 71% of all QUADAS domains were assessed as high or unclear risk, which is 15% worse than diagnostic test accuracy reviews in other fields (70).

Our review suggests that root avulsions are found in approximately three in four patients, but given the variability of the estimates and quality of the original data, this is unlikely to be reliable. There are several clinical and artifactual factors that might reduce the apparent prevalence of root avulsions

and therefore the accuracy of MRI (71). Patients with a brachial plexus injury are typically victims of polytrauma who undergo several tests that may identify a problem obscuring or superseding the brachial plexus injury. Patients with polytrauma are typically treated by clinicians who do not specialize in nerve injury, so the intrinsic threshold for identifying the condition and referring the patient might be lower. Moreover, most surgeons do not perform hemilaminectomy when exploring the supraclavicular brachial plexus, so the status of the root proximal to the exit foramen is unknown, which might lead to further underestimation of the prevalence. Overall, several factors suggest that the true prevalence of root avulsion could be higher than observed, which may have important clinical ramifications.

Currently there is no evidence nor consensus to suggest whether a more sensitive or specific test is preferable. A more sensitive test would enable clinicians to rule out root avulsions (potentially avoiding unnecessary exploratory surgery), although the fiscal and functional costs of false-negative findings are substantial—notably, lifelong disability (2–6), pain (6–8), mental illness (9,10), and impaired quality of life (2,4,11). A more specific test might rule in root avulsion, enabling clinicians to avoid exploration and proceed directly to nerve transfer while eliminating prolonged surveillance (36–38). Furthermore, avoidance of unnecessary surgery would reduce morbidity for patients and costs for health services. We accept that a proportion of patients who are not found to have root avulsion may have other nerve injuries that warrant reconstruction; however, the diagnosis of root avulsion is of paramount importance. Therefore, improving the specificity of MRI for root avulsion appears to be most desirable.

In upper extremity nerve surgery, there is no consensus on the unit of analysis (patient, limb, or nerve). This is a common issue in surgical research but is profoundly important in upper extremity research (72,73). In this situation, if the patient is

Table 2: Summary of Findings Regarding the Diagnostic Accuracy of MRI for Detecting Root Avulsions in Adults with Traumatic Brachial Plexus Injuries

Parameter	Finding
Patient population	Adults with symptomatic traumatic brachial plexus injuries.
Prior testing	Highly variable. Patients may have undergone any of the following: recording of the history and mechanism of injury, focused US in trauma, repeated clinical examinations, plain radiography, CT with or without myelography with lumbar puncture, electrodiagnostic examination (nerve conduction or electromyography).
Settings	Inpatients in major trauma centers specializing in brachial plexus injuries.
Index test	Preoperative MRI of the brachial plexus.
Reference standard	Surgical exploration and visual inspection of the supraclavicular roots of the brachial plexus with the patient in general anesthesia.
Target condition	Root avulsion(s) of the brachial plexus.
Included studies	A total of 11 cross-sectional studies in 275 adults with traumatic brachial plexus injuries that reported the findings of preoperative MRI and surgical exploration of the roots of the brachial plexus.
Risk of bias and applicability concerns	There was potential for bias in patient selection. The diagnostic criteria for root avulsion were poorly reported. The applicability concerns regarding the reference standard were unclear in all studies.
Data synthesis	The unit of analysis differed between studies. Six studies reported both per-patient and per-nerve analyses. A total of six studies reported per-patient analysis, while eight studies reported per-nerve analysis. Meta-analysis was not performed at the patient level because of sparse and heterogeneous data.
Limitations	The study samples may not represent the population. There was poor reporting of diagnostic thresholds. Investigation of heterogeneity was not possible because of limited data. Owing to limited and heterogeneous data, it is difficult to determine the extent to which the review findings can be applied to clinical practice.

Note.—In the eight studies that reported per-nerve analysis, there were a total of 583 avulsions of 918 nerves. Overall, the mean sensitivity was 93% (95% confidence interval [CI]: 77%, 98%), and the mean specificity was 72% (95% CI: 42%, 90%). In terms of consequences per 100 nerves, the prevalence (median and interquartile range estimated from the included studies) was 38 per 100 (number of missed avulsions, three [95% CI: one, nine]; number of nerves explored unnecessarily, 45 [95% CI: 26, 56]), 55 per 100 (number of missed avulsions, four [95% CI: one, 13]; number of nerves explored unnecessarily, 32 [95% CI: 19, 41]), and 71 per 100 (number of missed avulsions, five [95% CI: one, 16]; number of nerves explored unnecessarily, 21 [95% CI: 12, 26]).

Pseudomeningocele: Unit of Analysis = Patients

Study	TP	FP	FN	TN	Field Strength	Sensitivity (95% CI)	Specificity (95% CI)	Sensitivity (95% CI)	Specificity (95% CI)
Hems 1999	7	0	4	12	0.5T	0.64 [0.31, 0.89]	1.00 [0.74, 1.00]		
Wade 2018	12	3	7	7	1.5T	0.63 [0.38, 0.84]	0.70 [0.35, 0.93]		
Qin 2016	15	8	8	2	3T	0.65 [0.43, 0.84]	0.20 [0.03, 0.56]		

Pseudomeningocele: Unit of Analysis = Nerves

Study	TP	FP	FN	TN	Field Strength	Sensitivity (95% CI)	Specificity (95% CI)	Sensitivity (95% CI)	Specificity (95% CI)
Wade 2018	22	12	34	77	1.5T	0.39 [0.26, 0.53]	0.87 [0.78, 0.93]		

Figure 5: Forest plots of the sensitivity and specificity of MRI for pseudomeningoceles with patients as the unit of analysis (top) and nerves as the unit of analysis (bottom). CI = confidence interval, FN = false-negative, FP = false-positive, TN = true-negative, TP = true-positive.

the unit of analysis, then MRI would classify patients as either negative (avulsion free) or positive (having between one and five avulsions), which fails to discriminate between distinct patterns of roots injury and wrongly apportion one to five avulsions the same result, introducing composite bias (74). Conversely, if the root is the unit of analysis, then composite bias is avoided, and five clinically meaningful and distinct assessments are provided. Therefore, we advocate using the nerve as the unit of analysis.

There is one systematic review related to this topic that compares the performance of MRI to CT myelography for the diagnosis of root avulsions (75). The authors concluded that MRI is “an excellent test for assessing traumatic brachial plexus injuries”; however, this statement is not substantiated because all three studies were judged to be at risk for methodologic bias and

no meta-analysis was performed. Their review had no protocol and was not reported in accordance with recommended guidelines. Furthermore, CT myelography carries a demonstrable risk of cancer induction. Therefore, we disagree with the authors’ findings and suggest that their conclusion is too optimistic (76) and that the hazards of CT myelography outweigh the potential benefits as compared with MRI.

Our review had limitations. While 20 potentially relevant articles were identified, data extraction was impossible for nine articles (50–58). Retrospective studies of medical tests tend to report inflated estimates of diagnostic accuracy (68); our review included four retrospective studies (59,60,66,67) and seven articles that incompletely described the time frames between injury, imaging, and surgery. Similarly, studies recruiting nonconsecutive (nonrandom) samples are prone to selection

bias and inflated estimates of accuracy (68); our review included four such articles (43,61–63). We expected the accuracy of MRI to improve over time, in line with technologic and methodologic advances, although this is not appreciable (Fig 3). This discord is likely multifactorial, and certainly high-quality prospective research is needed.

In conclusion, on the basis of limited and heterogeneous data, MRI offers modest diagnostic accuracy for traumatic brachial plexus root avulsion(s), and early surgical exploration should remain as the preferred method of diagnosis.

Author contributions: Guarantors of integrity of entire study, R.G.W., G.B.; study concepts/study design or data acquisition or data analysis/interpretation, all authors; manuscript drafting or manuscript revision for important intellectual content, all authors; approval of final version of submitted manuscript, all authors; agrees to ensure any questions related to the work are appropriately resolved, all authors; literature research, R.G.W., J.C.R.W., S.T., G.B.; clinical studies, R.G.W., J.C.R.W.; experimental studies, R.G.W.; statistical analysis, R.G.W., Y.T.; and manuscript editing, all authors

Disclosures of Conflicts of Interest: R.G.W. disclosed no relevant relationships. Y.T. disclosed no relevant relationships. J.C.R.W. disclosed no relevant relationships. J.P.R. Activities related to the present article: disclosed no relevant relationships. Activities not related to the present article: receives royalties from Springer as the coauthor of the book *Cardiovascular MR Manual*, 1st and 2nd editions. Other relationships: disclosed no relevant relationships. S.T. disclosed no relevant relationships. J.J.R. disclosed no relevant relationships. G.B. disclosed no relevant relationships.

References

- Midha R. Epidemiology of brachial plexus injuries in a multitrauma population. *Neurosurgery* 1997;40(6):1182–1188; discussion 1188–1189.
- Franzblau LE, Shauver MJ, Chung KC. Patient satisfaction and self-reported outcomes after complete brachial plexus avulsion injury. *J Hand Surg Am* 2014;39(5):948–55.e4.
- Kretschmer T, Ihle S, Antoniadis G, et al. Patient satisfaction and disability after brachial plexus surgery. *Neurosurgery* 2009;65(4 Suppl):A189–A196.
- Dolan RT, Butler JS, Murphy SM, Hynes D, Cronin KJ. Health-related quality of life and functional outcomes following nerve transfers for traumatic upper brachial plexus injuries. *J Hand Surg Eur Vol* 2012;37(7):642–651.
- Maldonado AA, Kircher MF, Spinner RJ, Bishop AT, Shin AY. Free functioning gracilis muscle transfer versus intercostal nerve transfer to musculocutaneous nerve for restoration of elbow flexion after traumatic adult brachial pan-plexus injury. *Plast Reconstr Surg* 2016;138(3):483e–488e.
- Teixeira MJ, da Paz MG da S, Bina MT, et al. Neuropathic pain after brachial plexus avulsion—central and peripheral mechanisms. *BMC Neurol* 2015;15(1):73.
- Lee K. Long term effect of thalamic deep brain stimulation for pain due to brachial plexus injury. *J Pain* 2012;13(4 Suppl):S68.
- Brill S, Aryeh IG. Neuromodulation in the management of pain from brachial plexus injury. *Pain Physician* 2008;11(1):81–85.
- Franzblau L, Chung KC. Psychosocial outcomes and coping after complete avulsion traumatic brachial plexus injury. *Disabil Rehabil* 2015;37(2):135–143.
- Wilson TJ, Chang KWC, Yang LJS. Depression and anxiety in traumatic brachial plexus injury patients are associated with reduced motor outcome after surgical intervention for restoration of elbow flexion. *Neurosurgery* 2016;78(6):844–850.
- Mancuso CA, Lee SK, Dy CJ, Landers ZA, Model Z, Wolfe SW. Expectations and limitations due to brachial plexus injury: a qualitative study. *Hand (N Y)* 2015;10(4):741–749.
- Liu Y, Lao J, Gao K, Gu Y, Zhao X. Functional outcome of nerve transfers for traumatic global brachial plexus avulsion. *Injury* 2013;44(5):655–660.
- Karalija A, Novikova LN, Orådd G, Wiberg M, Novikov LN. Differentiation of pre- and postganglionic nerve injury using mri of the spinal cord. *PLoS One* 2016;11(12):e0168807.
- Eggers R, Tannemaat MR, De Winter F, Malessy MJA, Verhaagen J. Clinical and neurobiological advances in promoting regeneration of the ventral root avulsion lesion. *Eur J Neurosci* 2016;43(3):318–335.
- Fournier HD, Mercier P, Menei P. Repair of avulsed ventral nerve roots by direct ventral intraspinal implantation after brachial plexus injury. *Hand Clin* 2005;21(1):109–118.
- Kachramanoglou C, De Vita E, Thomas DL, et al. Metabolic changes in the spinal cord after brachial plexus root re-implantation. *Neurorehabil Neural Repair* 2013;27(2):118–124.
- Oberhoffer J, Antoniadis G, König R, Heinen C, Kretschmer T, Wirtz C. 10-year experience with nerve transfers for restoration of elbow function in patients with traumatic brachial plexus injuries [abstr]. *J Neurosurg* 2013;122:A554.
- Songcharoen P. Brachial plexus injury in Thailand: a report of 520 cases. *Microsurgery* 1995;16(1):35–39.
- Quick TJ, Singh AK, Fox M, Sinisi M, MacQuillan A. A quantitative assessment of the functional recovery of flexion of the elbow after nerve transfer in patients with a brachial plexus injury. *Bone Joint J* 2016;98-B(11):1517–1520.
- Yang LJS, Chang KWC, Chung KC. A systematic review of nerve transfer and nerve repair for the treatment of adult upper brachial plexus injury. *Neurosurgery* 2012;71(2):417–429; discussion 429.
- Wali AR, Santiago-Dieppa DR, Brown JM, Mandeville R. Nerve transfer versus muscle transfer to restore elbow flexion after pan-brachial plexus injury: a cost-effectiveness analysis. *Neurosurg Focus* 2017;43(1):E4.
- Wali AR, Park CC, Brown JM, Mandeville R. Analyzing cost-effectiveness of ulnar and median nerve transfers to regain forearm flexion. *Neurosurg Focus* 2017;42(3):E11.
- de Mendonça Cardoso M, Gepp R, Correa JFG. Outcome following phrenic nerve transfer to musculocutaneous nerve in patients with traumatic brachial palsy: a qualitative systematic review. *Acta Neurochir (Wien)* 2016;158(9):1793–1800.
- Yang G, Chang KWC, Chung KC. A systematic review of outcomes of contralateral C7 transfer for the treatment of traumatic brachial plexus injury: part 2. donor-site morbidity. *Plast Reconstr Surg* 2015;136(4):480e–489e.
- Hems T. Nerve transfers for traumatic brachial plexus injury: advantages and problems. *J Hand Microsurg* 2011;3(1):6–10.
- Makin TR, Scholz J, Filippini N, Henderson Slater D, Tracey I, Johansen-Berg H. Phantom pain is associated with preserved structure and function in the former hand area. *Nat Commun* 2013;4(1):1570.
- Pelled G, Chuang KH, Dodd SJ, Koretsky AP. Functional MRI detection of bilateral cortical reorganization in the rodent brain following peripheral nerve deafferentation. *Neuroimage* 2007;37(1):262–273.
- Pawela CP, Biswal BB, Hudetz AG, et al. Interhemispheric neuroplasticity following limb deafferentation detected by resting-state functional connectivity magnetic resonance imaging (fMRI) and functional magnetic resonance imaging (fMRI). *Neuroimage* 2010;49(3):2467–2478.
- Vargas MI, Viallon M, Nguyen D, Beaulieu JY, Delavelle J, Becker M. New approaches in imaging of the brachial plexus. *Eur J Radiol* 2010;74(2):403–410.
- Nardin RA, Patel MR, Gudas TF, Rutkove SB, Raynor EM. Electromyography and magnetic resonance imaging in the evaluation of radiculopathy. *Muscle Nerve* 1999;22(2):151–155.
- Zhu YS, Mu NN, Zheng MJ, et al. High-resolution ultrasonography for the diagnosis of brachial plexus root lesions. *Ultrasound Med Biol* 2014;40(7):1420–1426.
- Mallouhi A, Meirer R, Bodner G. Ultrasonographic features of brachial plexus traumatic rupture. Case illustration. *J Neurosurg* 2003;99(2):432.
- Lapegue F, Faruch-Bilfeld M, Demondion X, et al. Ultrasonography of the brachial plexus, normal appearance and practical applications. *Diagn Interv Imaging* 2014;95(3):259–275.
- Chin B, Ramji M, Farrokhvar F, Bain JR. Efficient imaging: examining the value of ultrasound in the diagnosis of traumatic adult brachial plexus injuries, a systematic review. *Neurosurgery* 2018;83(3):323–332.
- Sureka J, Cherian RA, Alexander M, Thomas BP. MRI of brachial plexopathies. *Clin Radiol* 2009;64(2):208–218.
- Jivan S, Novikova LN, Wiberg M, Novikov LN. The effects of delayed nerve repair on neuronal survival and axonal regeneration after seventh cervical spinal nerve axotomy in adult rats. *Exp Brain Res* 2006;170(2):245–254.
- Jivan S, Kumar N, Wiberg M, Kay S. The influence of pre-surgical delay on functional outcome after reconstruction of brachial plexus injuries. *J Plast Reconstr Aesthet Surg* 2009;62(4):472–479.
- Martin E, Senders JT, DiRisio AC, Smith TR, Broekman MLD. Timing of surgery in traumatic brachial plexus injury: a systematic review. *J Neurosurg* 2018 May 1:1–13 [Epub ahead of print].
- Wade RG, Takwoingi Y, Wormald JCR, et al. Magnetic resonance imaging for detecting root avulsions in traumatic adult brachial plexus injuries: protocol for a systematic review of diagnostic accuracy. *Syst Rev* 2018;7(1):76.
- McInnes MDF, Moher D, Thombs BD, et al. Preferred Reporting Items for a Systematic Review and Meta-analysis of Diagnostic Test Accuracy Studies: The PRISMA-DTA Statement. *JAMA* 2018;319(4):388–396.
- Sambasivan A, Pandit S. Bilateral brachial plexus injury after a hanging suicide attempt: a case report. *PM R* 2013;5(9S):S187.

42. Anwar F, McLaughlin D, Panesar BS. Bilateral brachial plexus injury. *J Coll Physicians Surg Pak* 2012;22(3):176–178.
43. Dubuisson AS, Kline DG. Brachial plexus injury: a survey of 100 consecutive cases from a single service. *Neurosurgery* 2002;51(3):673–682; discussion 682–683.
44. Hems TEJ, Birch R, Carlstedt T. The role of magnetic resonance imaging in the management of traction injuries to the adult brachial plexus. *J Hand Surg [Br]* 1999;24(5):550–555.
45. Whiting P, Rutjes AWS, Reitsma JB, Bossuyt PMM, Kleijnen J. The development of QUADAS: a tool for the quality assessment of studies of diagnostic accuracy included in systematic reviews. *BMC Med Res Methodol* 2003;3(1):25.
46. Chu H, Cole SR. Bivariate meta-analysis of sensitivity and specificity with sparse data: a generalized linear mixed model approach. *J Clin Epidemiol* 2006;59(12):1331–1332; author reply 1332–1333.
47. Reitsma JB, Glas AS, Rutjes AWS, Scholten RJPM, Bossuyt PM, Zwinderman AH. Bivariate analysis of sensitivity and specificity produces informative summary measures in diagnostic reviews. *J Clin Epidemiol* 2005;58(10):982–990.
48. Macaskill P, Gatsonis C, Deeks JJ, Harbord RM, Takwoingi Y. Chapter 10: Analysing and presenting results. In: Deeks JJ, Bossuyt PM, Gatsonis C, eds. *Cochrane Handbook for Systematic Reviews of Diagnostic Test Accuracy Version 1.0*. The Cochrane Collaboration; 2010. <https://methods.cochrane.org/sdt/handbook-dta-reviews>. Accessed March 1, 2018.
49. Deeks JJ, Macaskill P, Irwig L. The performance of tests of publication bias and other sample size effects in systematic reviews of diagnostic test accuracy was assessed. *J Clin Epidemiol* 2005;58(9):882–893.
50. Upadhyaya V, Upadhyaya DN, Kumar A, Gujral RB. MR neurography in traumatic brachial plexopathy. *Eur J Radiol* 2015;84(5):927–932.
51. Ning D, Sun M, Sun B, et al. Magnetic resonance imaging with three-dimensional fast imaging employing steady-state acquisition with phase-cycled and short T1 inversion recovery pulse sequence for evaluating brachial plexus injury. *Neural Regen Res* 2011;6(14):1097–1102.
52. Penkert G, Carvalho GA, Nikkhah G, Tatagiba M, Matthies C, Samii M. Diagnosis and surgery of brachial plexus injuries. *J Reconstr Microsurg* 1999;15(1):3–8.
53. Gerevini S, Mandelli C, Cadioli M, Scotti G. Diagnostic value and surgical implications of the magnetic resonance imaging in the management of adult patients with brachial plexus pathologies. *Surg Radiol Anat* 2008;30(2):91–101.
54. Carvalho GA, Nikkhah G, Matthies C, Penkert G, Samii M. Diagnosis of root avulsions in traumatic brachial plexus injuries: value of computerized tomography myelography and magnetic resonance imaging. *J Neurosurg* 1997;86(1):69–76.
55. Schmidt T, Kretschmer T, Heinen C, et al. Clinical application of diffusion tensor tractography (DTT) of traumatic brachial plexus injuries: oral presentations, 2011 AANS Meeting, Denver, Colorado, April 9–13, 2011. *J Neurosurg* 2011;115(2):A402–A452.
56. Disawal A, Taori K, Rathod J. Role of newer MR imaging techniques in traumatic brachial plexopathies - Our experience [abstr]. *The Royal Australian and New Zealand College of Radiologists Annual Scientific Meeting* 2012. DOI: 10.1594/ranzcraocr2012/R-0195.
57. Caporrino FA, Moreira L, Moraes VY, Belloti JC, Gomes dos Santos JB, Faloppa F. Brachial plexus injuries: diagnosis performance and reliability of everyday tools. *Hand Surg* 2014;19(1):7–11.
58. Veronesi BA, Rodrigues MB, Sambuy MTC, Macedo RS, Cho ÁB, Rezende MR. Use of magnetic resonance imaging to diagnose brachial plexus injuries. *Acta Ortop Bras* 2018;26(2):131–134.
59. Abul-Kasim K, Backman C, Björkman A, Dahlin LB. Advanced radiological work-up as an adjunct to decision in early reconstructive surgery in brachial plexus injuries. *J Brachial Plex Peripher Nerve Inj* 2010;5:14.
60. Chanlalit C, Vipulakorn K, Jirattananapochai K, Mairiang E, Chowcheun P. Value of clinical findings, electrodiagnosis and magnetic resonance imaging in the diagnosis of root lesions in traumatic brachial plexus injuries. *J Med Assoc Thai* 2005;88(1):66–70.
61. Doi K, Otsuka K, Okamoto Y, Fujii H, Hattori Y, Baliarsing AS. Cervical nerve root avulsion in brachial plexus injuries: magnetic resonance imaging classification and comparison with myelography and computerized tomography myelography. *J Neurosurg* 2002;96(3,Suppl):277–284.
62. Hayashi N, Yamamoto S, Okubo T, et al. Avulsion injury of cervical nerve roots: enhanced intradural nerve roots at MR imaging. *Radiology* 1998;206(3):817–822.
63. Qin BG, Yang JT, Yang Y, et al. Diagnostic value and surgical implications of the 3D DW-SSFP MRI on the management of patients with brachial plexus injuries. *Sci Rep* 2016;6(1):35999.
64. Gasparotti R, Ferraresi S, Pinelli L, et al. Three-dimensional MR myelography of traumatic injuries of the brachial plexus. *AJNR Am J Neuroradiol* 1997;18(9):1733–1742.
65. Nakamura T, Yabe Y, Horiuchi Y, Takayama S. Magnetic resonance myelography in brachial plexus injury. *J Bone Joint Surg Br* 1997;79(5):764–769.
66. Wade RG, Itte V, Rankine JJ, Ridgway JP, Bourke G. The diagnostic accuracy of 1.5T magnetic resonance imaging for detecting root avulsions in traumatic adult brachial plexus injuries. *J Hand Surg Eur Vol* 2018;43(3):250–258.
67. Yang J, Qin B, Fu G, et al. Modified pathological classification of brachial plexus root injury and its MR imaging characteristics. *J Reconstr Microsurg* 2014;30(3):171–178.
68. Rutjes AWS, Reitsma JB, Di Nisio M, Smidt N, van Rijn JC, Bossuyt PM. Evidence of bias and variation in diagnostic accuracy studies. *CMAJ* 2006;174(4):469–476.
69. Whiting PF, Rutjes AWS, Westwood ME, Mallett S; QUADAS-2 Steering Group. A systematic review classifies sources of bias and variation in diagnostic test accuracy studies. *J Clin Epidemiol* 2013;66(10):1093–1104.
70. Di Girolamo N, Winter A, Meursinge Reynders R. High and unclear risk of bias assessments are predominant in diagnostic accuracy studies included in Cochrane reviews. *J Clin Epidemiol* 2018;101:73–78.
71. Leeftang MMG, Rutjes AWS, Reitsma JB, Hooft L, Bossuyt PMM. Variation of a test's sensitivity and specificity with disease prevalence. *CMAJ* 2013;185(11):E537–E544.
72. Wade RG, Bland JM, Wormald JCR, Figus A. The importance of the unit of analysis: commentary on Beugels et al. (2016). Complications in unilateral versus bilateral deep inferior epigastric artery perforator flap breast reconstructions: a multicentre study. *J Plast Reconstr Aesthet Surg* 2016;69(9):1299–1300.
73. Sauerland S, Lefering R, Bayer-Sandow T, Brüser P, Neugebauer EAM. Fingers, hands or patients? the concept of independent observations. *J Hand Surg [Br]* 2003;28(2):102–105.
74. Naaktgeboren CA, Bertens LCM, van Smeden M, de Groot JAH, Moons KGM, Reitsma JB. Value of composite reference standards in diagnostic research. *BMJ* 2013;347(oct25 2):f5605.
75. Fuzari HKB, Dornelas de Andrade A, Vilar CF, et al. Diagnostic accuracy of magnetic resonance imaging in post-traumatic brachial plexus injuries: a systematic review. *Clin Neurol Neurosurg* 2018;164:5–10.
76. Ochodo EA, de Haan MC, Reitsma JB, Hooft L, Bossuyt PM, Leeftang MM. Overinterpretation and misreporting of diagnostic accuracy studies: evidence of “spin”. *Radiology* 2013;267(2):581–588.