

This is a repository copy of *A month in a horse's life:healing process of a fractured third metatarsal bone from medieval Viljandi, Estonia.*

White Rose Research Online URL for this paper:

<https://eprints.whiterose.ac.uk/140163/>

Version: Accepted Version

---

**Article:**

Rannamae, Eve, Andrianov, Vladimir, Järv, Eha et al. (3 more authors) (2019) A month in a horse's life:healing process of a fractured third metatarsal bone from medieval Viljandi, Estonia. *International Journal of Paleopathology*. pp. 286-292. ISSN 1879-9817

<https://doi.org/10.1016/j.ijpp.2018.07.003>

---

**Reuse**

This article is distributed under the terms of the Creative Commons Attribution-NonCommercial-NoDerivs (CC BY-NC-ND) licence. This licence only allows you to download this work and share it with others as long as you credit the authors, but you can't change the article in any way or use it commercially. More information and the full terms of the licence here: <https://creativecommons.org/licenses/>

**Takedown**

If you consider content in White Rose Research Online to be in breach of UK law, please notify us by emailing [eprints@whiterose.ac.uk](mailto:eprints@whiterose.ac.uk) including the URL of the record and the reason for the withdrawal request.

# A month in a horse's life: healing process of a fractured third metatarsal bone from medieval Viljandi, Estonia

---

*Eve Rannamäe<sup>a,b,\*</sup>, Vladimir Andrianov<sup>c</sup>, Eha Järv<sup>d</sup>, Aleksandr Semjonov<sup>c</sup>, Arvi Haak<sup>a,e</sup>, Juhan Kreem<sup>f,g</sup>*

<sup>a</sup>*Department of Archaeology, Institute of History and Archaeology, University of Tartu, Jakobi 2, 51005 Tartu, Estonia, eve.rannamae@ut.ee*

<sup>b</sup>*BioArCh, Department of Archaeology, University of York, Environment Building, Wentworth Way, YO10 5DD York, United Kingdom*

<sup>c</sup>*Chair of Clinical Veterinary Medicine, Estonian University of Life Sciences, Kreutzwaldi 62, 51014 Tartu, Estonia, vladimir.andrianov@emu.ee, aleksandr.semjonov@emu.ee*

<sup>d</sup>*Chair of Veterinary Bio- and Population Medicine, Estonian University of Life Sciences, Kreutzwaldi 62, 51014 Tartu, Estonia, eha.jarv@emu.ee*

<sup>e</sup>*Tartu City Museum, Narva Road 23, 51009 Tartu, Estonia, arvi.haak@katarina.ee*

<sup>f</sup>*Tallinn City Archives, Tolli 6, 10133 Tallinn, Estonia, juhan.kreem@tallinnlv.ee*

<sup>g</sup>*School of Humanities, Institute of History, Archaeology and Art History, Tallinn University, Narva Road 25, 10120 Tallinn, Estonia*

*\*corresponding author*

## Abstract

The remains of a horse's hind foot – a third metatarsal bone and three phalanges – were found in a presumed waste pit of a prosperous medieval household in Viljandi, Estonia, dated from the second half of the 13<sup>th</sup> to the beginning of the 15<sup>th</sup> century. The metatarsal bone had been broken during the horse's lifetime and showed evidence of partial healing. Using archaeological, zooarchaeological, morphological, microscopic, densitometric and radiographic analyses, we investigated the bones and the healing process in order to understand animal treatment in a medieval urban context. Our results show that the fracture was a complete comminuted fracture that appears to have been closed and stable, caused most probably by a trauma from a strong impact. Based on callus formation and the worn edges of the separated diaphysis, the horse had survived for at least a month and used the injured foot to some extent. We suggest that the horse was treated by splinting the foot and keeping the animal in a standing position during the healing process. Eventually the horse died because of a wound infection, or was killed. The relatively long period of careful treatment indicates the animal's economic or emotional value.

**Keywords:** *Equus caballus*; horse metatarsus; bone fracture; Middle Ages

## 1. Introduction

The horse has played an important role in the economic, cultural and political spheres of past societies. Different attitudes towards horses have been identified in the archaeological record, including their consumption for meat, use in the military actions, and value as a social marker, to name only a few. During the Medieval Period in Estonia, which lasted from the crusades of the 13<sup>th</sup> century to the collapse of the medieval principalities in the middle of the 16<sup>th</sup> century, the

horse was undoubtedly a valued and important animal, although is only scarcely represented in the faunal remains. While eating horse meat was to some extent practised in the prehistoric times, the conversion to Christianity brought an end to this habit (Hillgarth 1986, 174), which may explain the scarcity of horse remains in faunal assemblages. Written sources on horses in medieval Livonia are not very numerous. Some urban accounts refer to the purchase of horses, and visitation reports of the Teutonic Order occasionally mention the number of stabled horses in castles. Also, correspondence makes reference to the delivery of horses between neighbouring countries, and horses appear as precious gifts or strategic items under embargo (although no comprehensive overview has yet been published, Leimus 2017 provides a good introduction on trade and prices). In some cases, horses of different types (like destrier, riding horse, ambler) and geographic origin (Frisian, Spanish, Walachian) can be distinguished in medieval documents, but the material is much poorer in comparison to the records of the Teutonic Order in neighbouring Prussia (Ekdahl 1998). Therefore, in order to understand medieval horse-breeding and exploitation, even minor bits of evidence can be incredibly significant.


The current case comes from the town of Viljandi (Ger. Fellin), situated in the area of historical Livonia, present-day south Estonia (Figure 1A). A horse cannon bone, *i.e.* the third metapodial bone along with three phalanges, was found from a courtyard of a medieval household in a pit dated from the second half of the 13<sup>th</sup> to the beginning of the 15<sup>th</sup> century. While the phalanges display no morphological changes, the cannon bone clearly reveals a complete *ante mortem* fracture with evidence of healing. The fracture itself is not extraordinary, because bone fractures in general, including those on horse specimens, occur rather often in faunal assemblages. Regarding horse cannon bones, however, no cases of fractured specimens are known from Estonia and only few are known from the rest of Europe (*e.g.* Antikas 2008, 25–26; Boessneck *et al.* 1968, 40–41; Daugnora & Thomas 2002, 72; von den Driesch 1989, 651; Teichert 1988, 298–299; for an overview see also Udrescu & Van Neer 2005). Modern cases of complete fractures of third metapodial bones are also not very common, and the prognosis for recovery is usually very poor, especially for adult individuals (Bischofberger *et al.* 2009, 465; Orsini & Divers 2014, Table 21-5; Reidla 2004, 125–127; see also McClure *et al.* 1998).

The medieval horse find from Viljandi offers a unique possibility to examine one aspect of horse treatment in medieval Livonia. This paper adopts a traditional approach to the analysis of the palaeopathological specimen, consisting in the description, diagnosis and interpretation of the lesions, by the use of archaeological, zooarchaeological and veterinary methods (see O'Connor 2003, 188). We explore the traumatic injury and provide suggestions for how the accident might have occurred, what symptoms the fractured bone showed, how the injury was treated, what might have been the final cause of death, and what it all tells us about the horse's value. Although we approach only one individual, our results indicate human therapeutic intervention, and provide insights on the treatment of animals and the role of horses in the medieval society.

## 2. Archaeological context and material

The excavation site where the investigated horse specimens were found is located in the centre of Viljandi, just north of the market square (Figure 1B). The site included remains of several buildings and a courtyard area. Analysis of ceramic material led to the conclusion that this territory was one of the first occupied in the town, where the earliest deposits can be dated to the period *c.* 1250–1300 (Haak & Russow 2013, 65, 69ff). Both the housing remains and the

fragments of wicker fences in the yard area suggest that the investigated area was divided during the Medieval Period into several plots.



**Figure 1.** Archaeological site and finds. **A)** Location of the town of Viljandi, Estonia. **B)** Excavation area in Viljandi, marked with a red cross. **C)** Stoneware from North Germany (VM 10942: 324). **D)** Copper alloy tripod pot (VM 10536: 163). **E)** Probable handle plate made of antler (VM 10942: 285). **F)** Fragments of the hot plate of hypocaust oven (VM 11457: 148, 67). **G)** Faunal remains from the yard deposits (VM 10942; osteological collections held in the Department of Archaeology, University of Tartu, Estonia). Abbreviations: VM = Viljandi Museum; NISP = Number of Identified Specimens. Photos: A. Haak, H. Helves (Museum of Viljandi); figure compiled by E. Rannamäe.

The four horse bones were found together in a rather shallow and slightly oblong pit in the yard area. Only part of the pit, with dimensions of c. 2.4 × 1.5 m remained within the investigated area (Kodar 1993–1995). The pit was located in the same plot as an assumed animal shed, the floor of which was covered with a stratum of dung remains. There was a row of poles (probably those of a fence; thus marking a property boundary) on the southeastern side of the pit. The excavator interpreted the pit as a waste pit (A. Kodar, personal information). The deposit inside the pit included Siegburg proto-stoneware, mid-Rhenish near-stoneware and local pottery (VM 10942: 24–39), which allow dating the deposit to a time span from the mid-13<sup>th</sup> to the beginning of the 15<sup>th</sup> century, although the imported wares would be more elaborately associated with the mid- and third quarter of the 13<sup>th</sup> century. In addition, three textile fragments, the largest with dimensions 317 × 75 mm, originated from this pit (VM 11483: 1–3).

Several other waste deposition features were present in the yard in the vicinity of the discussed pit; faunal remains from this area were abundant, with the characteristics of usual kitchen and food waste (Figure 1G). Most of the bone and tooth material consisted of livestock remains (cattle, sheep, goat, pig), with a few additions from cat, hare, some birds and fish. No other horse remains besides the four foot bones were found.

Several indicators show that the site was a wealthy premise in medieval Viljandi. The main arguments are the architectural remains, *i.e.* the existence of stone houses with hypocaust heating systems (Figure 1F; Kodar 1993–1995; cf. Tvauri 2009), the composition of finds, particularly the abundance of imported wares compared to the rest of the town (Figure 1C; Haak & Russow 2013, 77, Fig. 7), and the presence of metal cooking vessels and richly-decorated items (Figure 1D–E). The proximity of the market square gave the area an even more prestigious location.

### 3. Methods

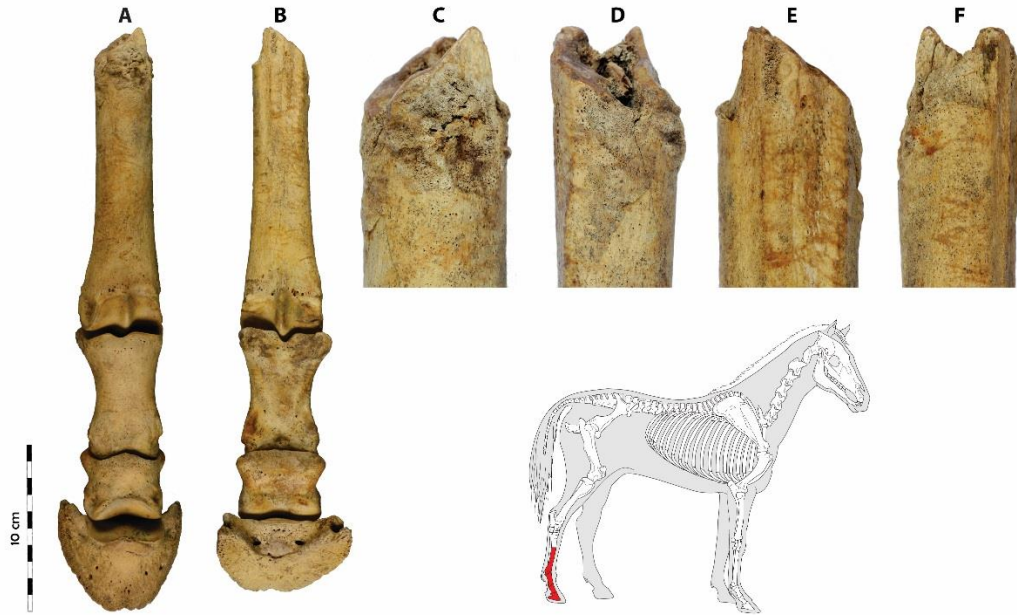
To describe the horse bones, we conducted a thorough morphological observation and age assessment based on the anatomical and proportional features of the specimens, and used linear measurements to estimate the size and weight of the individual. Wither height was calculated based on the greatest length of the third metatarsal bone following two widely used methods by Kiesewalter (1888) and Vitt (1952). Because of the fragmentation of the archaeological specimen, its greatest length was estimated based on the proportional comparison to the modern reference of an Estonian native horse in the collections of the Estonian University of Life Sciences. In weight estimation we relied on suggestions by Saastamoinen (2011, 57), where the horse's weight is estimated based on the pectoral girth and wither height. However, pectoral girth could not be included for the archaeological and modern specimens presented in this study, and any weight suggestions should be therefore considered putative.

To study the healing process and condition of the bone tissue, we used radiological (SEDECAL APR-VET, SN:1579) and densitometric (Dual-Energy X-Ray Absorptiometry Lunar DPX-IQ) applications with an aid of a stereomicroscopic inspection (Stereo Microscope Zeiss Stemi 200-CS; camera Zeiss MRc5), and evaluated the formation of new bone tissue and the wear of fractured surfaces.

We compared the estimations about the individual and the healing process with ancient and modern studies on horse third metapodial bone fractures to discuss the reason and complications of the trauma. Finally, archaeological and historical context was used to find the possible argument behind the witnessed effort of treatment.

### 4. Results and discussion

**Size and shape.** Visual comparison and the co-occurrence of all four bones in a single shallow pit indicate that they all belonged to a single individual. Based on the elongated hoof, round cross-section of the cannon bone, and wider medial articular surfaces of the phalanges, the remains were determined to be from a right hind leg (Figure 2A–B). Based on an overall size, bone structure and presence of fused epiphyses, the individual appears to be an adult of at least 15 months of age (Chaix & Méniel 2001).



**Figure 2.** Four horse bone specimens of the right hind leg (marked red on the skeleton) in the medieval assemblage from Viljandi from **A)** dorsal and **B)** plantar view; and a close up of the fracture from **C)** dorsal, **D)** lateral, **E)** plantar and **F)** medial view. Photos and figure: E. Rannamäe, A. Haak; skeleton template by ©ArchéoZoo.org.

To assess the height of the horse, we compared the specimen to a similar size skeletal hind leg of a modern-day Estonian native horse. Withers height of the native horse (Figure 3) can vary between 129–151 cm (Niilo 1936, 8; Teinberg *et al.* 1995, 68), and weight can be between 266–505 kg (Niilo 1936, 8–10; Saastamoinen 2011, 57). Our calculations showed the medieval horse to have been approximately 128–136 cm high in withers and to have weighed around 360–390 kg (Table 1). This coincides with other osteological data from medieval Estonia, where the height of horses has been estimated to be 112–144 cm (Maldre 1998; Rannamäe & Lõugas in press).



**Figure 3.** Estonian native horse. Withers height 145 cm, pectoral girth 173 cm (ARIB), estimated weight around 420 kg (after Saastamoinen 2011, 57). Photo: E. Rannamäe.

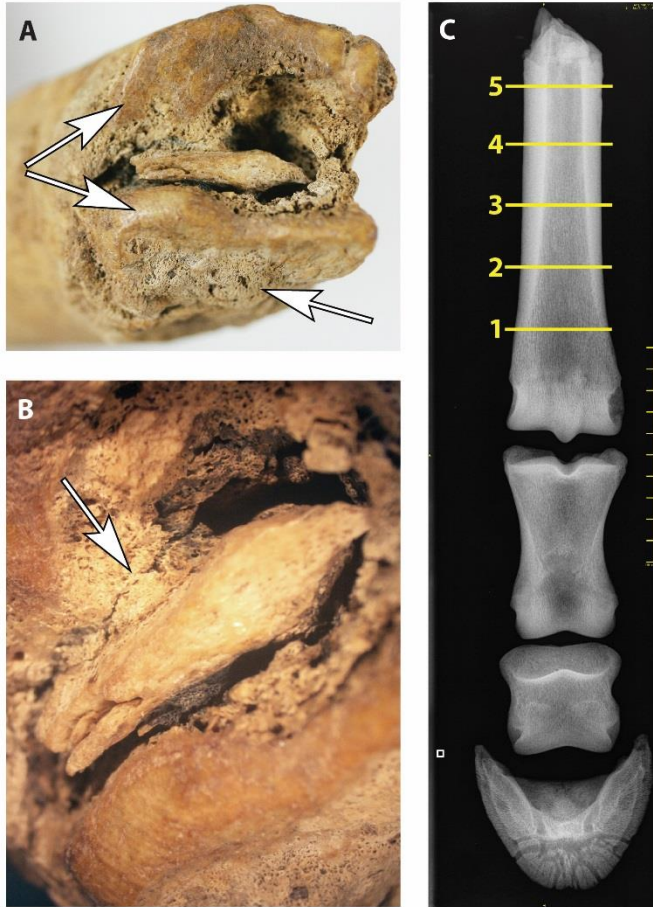
**Table 1.** Estimated withers height and weight of the medieval and modern reference individual. Calculations are based on the greatest length (GL) of the metatarsal bone.

	Metatarsal GL (mm)	Withers height (cm)		Weight (kg)
		Kiesewalter 1888	Vitt 1952	Saastamoinen 2011
Medieval individual	248 (estimated)	132	128–136	c. 360–390
Modern individual	265	141	136–144	c. 390–410

**Injury type.** The third metatarsal is broken along the proximal part of the diaphysis, and the proximal part of the bone element is missing. The proximal extremity of the specimen, *i.e.* the edges of the broken diaphysis display significant *ante mortem* modifications, especially on the bone's dorsal side (Figure 2C). The bone surfaces close to the fracture show callus formation and bone remodelling, which means that the fracture had clearly begun to repair (Figure 2C–F). The surface of the fracture is significantly polished (Figure 4A), possibly for two reasons: either by the rubbing of the fracture extremities against the opposite (missing) part of the bone, or due to bone remodelling, *i.e.* demineralisation and reconstruction of the fractured surface. No pathological modifications were observed on the associated phalanges.

The bone had suffered a complete comminuted fracture, as seen from the entire affected surface of the broken diaphysis and the fusion of the 1 cm<sup>2</sup> bone splinter to the diaphysis with trabecular bone tissue (Figure 4A–B). The worn edges, the extent of both periosteal and endosteal lysis process with the formation of callus on the surfaces of the bone, and the fusion of the splinter suggest the animal survived for at least one month after the incident (see also Fossum 2002, Fig. 33–11; Märtson 2006, 42–44). This allows us to suggest the bone fracture had been closed and stable, because no infection seems to have occurred during the healing period. If the fracture had been open and infected, the animal would have developed sepsis – frequent in the distal parts of the limbs due to their proximity to the ground, and difficult to deal with in the absence of antimicrobial drugs (see also Lugo & Gaughan 2006). To our knowledge, there is no reference to the survival time for a horse with an open bone fracture, or from the occurrence of sepsis. However, in our opinion, the horse surviving for a month would not have been a very probable scenario.

Radiographic analysis confirms the macroscopic observations and shows the formation of callus on the external side of the bone and around the bone fragment in the cavity. Otherwise the bone appears to be healthy with normal thickness throughout the bone (Figure 4C), as also confirmed by the densitometric measurements (Table 2). The bone mineral density was shown to be similar between the third metatarsal bones of the medieval and modern individual. Measurements indicate that the medieval individual did not have any predispositions to fractures (*e.g.* osteoporosis or some inherent metabolic disorder) and could be considered a healthy animal.



**Figure 4.** **A)** Ossification of the fracture. A newly formed callus is visible on the plantar surface of the bone (marked with lower arrow) and in the cavity, while edges of the separated diaphysis appear polished (marked with upper arrows). Photo: E. Rannamäe. **B)** The bone splinter attached to the bone cavity with newly formed bone tissue (100 × microscopic magnification). Some time during the post-mortem process the splinter has mechanically broken loose, indicated by a crack on the plantar side of the splinter (marked with arrow). Photo: E. Järv. **C)** Radiogram of the four specimens from dorsal view, and the locations (1–5) of densitometric measurements (see Table 2). Photo: A. Semjonov.

**Table 2.** Bone mineral density (BMD) of the third metatarsal bone of the medieval and modern reference individual. For the locations where measures 1–5 were taken, see Figure 4C.

BMD (g/cm <sup>3</sup> )	Medieval individual	Modern individual
Measurement 1	1.634	1.622
Measurement 2	1.536	1.399
Measurement 3	1.362	1.127
Measurement 4	0.995	0.874
Measurement 5	0.540	0.507



**Causes.** Baker & Brothwell (1980, 82) have categorised traumatic injuries as of (a) damage from human agencies, (b) modification by surgery, (c) injury from intra- or inter-group conflict, prey/predator relationship or mating trauma, (d) accidental wounds like those from falling and joint stress, and (e) collapse of bone due to some disease. The current case appears to be either due to intra-/inter-group conflicts or to accidental causes. Similar cases from modern-day veterinary suggest the most probable reasons for this type of fracture are high-energy injuries, like kicking (by another individual) or slipping on hard ground (*i.e.* falling); horses with a broken leg have been found in the stable (because of struggling out from a stuck position) or in the pasture (Bischofberger *et al.* 2009). The analysed individual was a healthy adult with strong bones, therefore the impact must have been heavy.

**Injury appearance and symptoms.** As discussed above, the evidence suggests that the fracture had been closed and the skin had not been torn – otherwise there would have been an infection, which would have killed the horse in a short period of time. Closed fractures of the third metapodial bone are rare – they are usually open at the time of referral, because the covering soft tissue is minimal (Bischofberger *et al.* 2009, 466). For this same reason, the swelling was probably not very extensive, but it surely caused immediate pain, lameness and prevented the animal from putting pressure on the leg (Reidla 2004, 126).

**Treatment.** Because of the importance of horses in the medieval society, veterinary knowledge must have been an essential and integral part of horse husbandry in the Middle Ages. Some of this knowledge was codified into writing, as testified by a German textbook of horse treatment, written in 1408 and dedicated to the Grand Master of the Teutonic Order (Ekdahl 1998, 135). The majority of knowledge was however most likely transferred orally, through practice. From written documents of medieval Tallinn (Ger. Reval) we know that blacksmiths treated horses (Johansen & von zur Mühlen 1973, 248), but there were other specialised caretakers as well. The accountbook of Tallinn mentions a certain Marcus the horse-physician in 1495 and 1504 (*perdearst*, KB no. 2291, 2649); in 1499, the horses were treated by a certain Albert the stableboy (*marstallesknecht*, KB no. 2456). It is difficult to say how specialised the horse care in a relatively small town of Viljandi would have been, or how treatment would have actually been applied. Together with veterinary knowledge, although without any supportive evidence, we could presume the practise of using salves, magical incantations or prayers to ease the clinical symptoms.

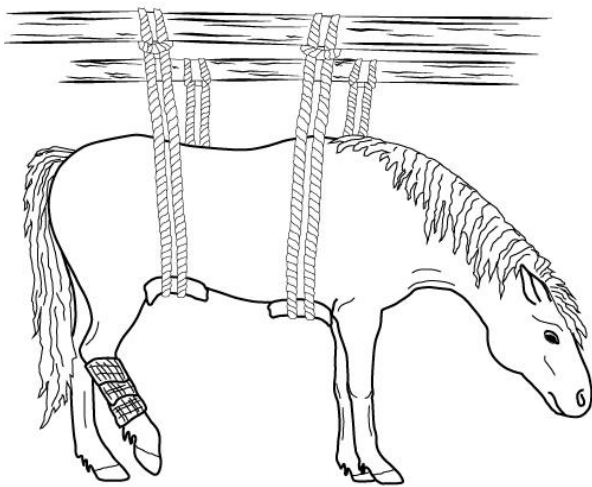
Horses are not as flexible animals as dogs or cats. To get off the ground from a lying position, a horse must lean on its hind legs, putting its whole body weight on them (Figure 5). This kind of pressure would most probably have torn the skin near the fracture, leading to an infection and death in a few days. However, as stated above, the bone fracture seems to have been closed and stable with no apparent infection, allowing the horse to survive for around a month. It has been suggested that a horse can stand on its four legs for two weeks or even more without signs of heavy fatigue (Reidla 1995, 328), but in the current case the horse had only three legs to use. Thus, spontaneous healing on a pasture or in a stall is unlikely, as moving around or standing for a whole month without wanting to lie down could hardly have been possible.



**Figure 5.** Estonian native horse getting up from prone position. Note that just before standing up, the whole body weight lies on hind legs. Photos: E. Rannamäe.

We suggest, therefore, that this animal received an immediate treatment – immobilising the leg, avoiding further damage to bone and soft tissue. The third metapodial bone is relatively easy to immobilise because of the very little soft tissue surrounding it (see Bischofberger *et al.* 2009; Udrescu & Van Neer 2005, 30–31). The horse could have been treated with a simple cloth wound around the leg or with a more elaborate splint; both appear possible on the basis of osteological data. Today’s veterinary knowledge includes the fixation of the nearest joints in the case of a bone fracture, but there is no ground for extending this practise to the current case, especially considering the fracture was closed and the caretakers were possibly not fully aware of the extent of the injury. It could be suggested that the cloth fragments found in that same pit had in some way been used in treatment of the horse, but beyond their co-occurrence in the waste pit there is no evidence to support this assumption.

It is worthwhile to note that a simple splint would not have been sufficient to enable healing for one month without the animal laying down and risking re-injury. Therefore, a use of some sling is likely (Figure 6). This method of treatment has been used since at least the 19<sup>th</sup> century (von den Driesch & Peters 2003, Abb. 8-3), but to our knowledge, there is no such evidence from medieval Livonia. Being in a sling does not allow the animal to make any active movements, but it does not keep it from passive movements or from putting some pressure on the leg (the probable cause for the fused bone splinter). These passive movements are suggested by the heavily polished extremities of the diaphysis and by small sections of the callus that have been worn down (Figure 4A).



**Figure 6.** Horse in a sling. Figure composed by E. Rannamäe and E. Järv (modified after von den Driesch & Peters 2003, Abb. 8-3; Reidla 1995, Fig. 113).

Similar cases in archaeological assemblages have led researchers to the conclusion that nursing a lame horse with little hope for full recovery or keeping it after an incomplete recovery shows that the animal was valued (Antikas 2008; Baker & Brothwell 1980, 89; Janeczek *et al.* 2010; Teichert 1988, 298–299; see also Udrescu & Van Neer 2005). Although emotional importance must not be excluded, in our case it might have been more of an economical one. Local horses were valued in Livonia during the Middle Ages as draught and riding animals. In Prussia (and thus probably also in Livonia) local breeds were used for light cavalry (Ekdahl, 1998, 122–124). There was also exchange between the horse pools of the Teutonic Order in Prussia and Livonia: some of the horses in Prussia in the first half of the 15<sup>th</sup> century are identified as Livonians (*Lyfflender*, GÄ, 589; MÄ, 154–155). Livonian horses could have served even as precious gifts: in 1431, for example, a *Vogt* from Maasi (Ger. Soneburg) presented a stallion from Saaremaa (Ger. Ösel) to the Grand Master of the Teutonic Order in Prussia (LECUB, no. 419; see also Mänd 2016; 2017). Although local horses were cheaper than other varieties in the market, they were part of so-called “strategic merchandise” alongside with more expensive horses (Leimus 2017, 13–14). Because it may have belonged to a wealthy household, the analysed horse might have had this kind of value as well. If the external appearance of the wound was not dire, the caretakers of the horse might have hoped for a full recovery: horses are hardy animals and even a partially recovered horse could eventually be harnessed for work or kept for breeding. In case of a pregnant or suckling mare, waiting to give birth or to nurse the foal would have been especially justified. However, here complications from injury would have been even more serious, owing to the bigger weight and tender belly of the pregnant animal, and because of the production of colostrum while extra calcium was needed for the formation of new bone tissue.

**Cause of death.** All changes that occurred to the bone after the injury show an inflammation, but it appears to have been aseptic. As soon as the skin was torn, a wound infection would have occurred. Since the diaphysis of the third metapodial bone contains a thick, dense cortex with poor blood supply, it is very vulnerable to infection (Bischofberger *et al.* 2009). Septic process usually takes from few days to several months, depending on the nature of the injury (*e.g.* celiac injury is more dangerous than limb injury), animal species (*e.g.* pigs are rather resistant while horses are the weakest) and treatment (availability of antibacterial medicine). For a horse, splinting the newly occurred open wound would not have been sufficient to prevent sepsis, which might have occurred within only a few days. Another complication could have been laminitis – a painful inflammatory condition in the hoof of the contralateral limb caused by an overload failure – the critical weight here has been reported to be above 320 kg (Bischofberger *et al.* 2009). Therefore, for our individual that was likely more than 360 kg, laminitis could have been a serious risk factor. In either way, complications must have brought death quickly, leaving no modifications in the bone tissue (either in visual or radiological terms). Alternatively, the animal might have been wilfully put down before any complications could develop, perhaps after the caretakers realised the animal would not fully recover.

**Deposition.** Non-food remains, as those of a horse, could easily become incorporated within regular domestic waste (Thomas 2005, 102). For example, in Northern America in the 19<sup>th</sup> century, horse carcasses were utilised very quickly for leather, hair, muscles (pet food), fat (soap) and fertiliser (McShane & Tarr 2006, 370). If horses were utilised similarly in this Livonian town during the Middle Ages, the accidental occurrence of one of the limbs in a different place would not be surprising. Potential explanations include displacement during construction work,

movement by scavengers, human curiosity, or intentional deposition of the “ill part” of the carcass in the waste.

## 5. Conclusions

A rare case of a horse third metatarsal bone fracture from Viljandi reveals important new insights into the process of medieval horse treatment and care. Morphological features and the healing process of the foot showed an adult horse of local type to have been treated for at least a month after the accident. Although only conjecture, the primary method of treatment might have been a splint and a sling. The efforts made by the caretakers affirm the high value of this particular animal and reveal that veterinary care was an important part of horse husbandry in medieval Livonia.

## Acknowledgements

We thank Agnes Osa (MTÜ Uniküla Tall) for the permission to photograph the Estonian native horses, and William Taylor for providing comments on the manuscript. The anatomical collections of the Zoomedicum at the Institute of Veterinary Science of the Estonian University of Life Sciences were used. The study was supported by European Research Council grant OVinE H2020-MSCA-IF-2016 749226, Institutional Research Fundings IUT18-8 and IUT20-7, and Estonian Research Council grant no PRG29.

The funders had no role in study design, data collection and analysis, decision to publish, or preparation of the manuscript.

## Competing interests

The authors have declared that no competing interests exist.

## References

- Antikas T.G. (2008) They didn't shoot horses: fracture management in a horse of the 5<sup>th</sup> century BCE from Sindos, Central Macedonia, Greece. *Veterinarija ir Zootechnika*, T 42(64), 24–27.
- ArchéoZoo.org, URL: [https://www.archeozoo.org/archeozootheque/index/category/136-squelettes\\_en\\_connexion\\_langen\\_skeletons\\_in\\_connection\\_lang\\_langes\\_esqueletos\\_en\\_conexion\\_lang](https://www.archeozoo.org/archeozootheque/index/category/136-squelettes_en_connexion_langen_skeletons_in_connection_lang_langes_esqueletos_en_conexion_lang) (last accessed December 6<sup>th</sup> 2017).
- ARIB = Agricultural Registers and Information Board. Equine Database, horse Tubli UELN 233401000814507, URL: <https://ariel.pria.ee/hobu/> (last accessed December 6<sup>th</sup> 2017).
- Baker J. & Brothwell D. (1980) *Animal Diseases in Archaeology*. London, New York, Toronto, Sydney, San Fransisco, Academic Press.

- Bischofberger A.S., Fürst A., Auer J. & Lischer C. (2009) Surgical management of complete diaphyseal third metacarpal and metatarsal bone fractures: clinical outcome in 10 mature horses and 11 foals. *Equine Veterinary Journal* 41(5), 465–473.
- Boessneck J., von den Driesch A. & Gejval N.G. (1968) *Die Knochenfunde von Säugetiere und von Menschen. The Archaeology of Skedemosse III (The Royal Swedish Academy of Letters, History and Antiquity)*. Stockholm, Almqvist & Wiksell.
- Chaix L. & Méniel P. (2001) *Archéozoologie. Les animaux et l'archéologie*. Paris, Errance.
- Daugnora L. & Thomas R. (2002) Horse burials from Middle Lithuania: a palaeopathological investigation. In: J. Davies, M. Fabiš, I. Mainland, M. Richards & R. Thomas (eds.) *Diet and health in Past Animal Populations: Current Research and Future Directions*. Oxford, Oxbow, 68–74.
- von den Driesch A. (1989) La paléopathologie animale: analyse d'ossements animaux pathologiques pré- et protohistoriques. *Revue de Médecine Vétérinaire* 140, 645–652.
- von den Driesch A. & Peters J. (2003) *Geschichte der Tiermedizin – 5000 Jahre Tierheilkunde, 2. Auflage*. Stuttgart, New York, Schattauer.
- Ekdahl S. (1998) Horses and Crossbows: Two important warfare advantages of the Teutonic Order in Prussia. In: H. Nicholson (ed.) *The Military Orders. Vol. 2. Welfare and Warfare*. Aldershot, Ashgate, 119–151.
- Fossum T. (2002) *Small animal surgery*, 2<sup>nd</sup> ed. St Louis, Mosby.
- GÄ = *Das grosse Ämterbuch des Deutschen Ordens*, ed. by W. Zieseimer (1921), Danzig, Kafemann.
- Haak A. & Russow E. (2013) On the development of the town of Viljandi in the light of earliest archaeological find complexes. *Estonian Journal of Archaeology* 17(1), 57–86.
- Hillgarth J.N. (ed.) (1986) *Christianity and Paganism, 350–750: The Conversion of Western Europe*. Philadelphia, University of Pennsylvania Press.
- Janeczek M., Chroszcz A., Miklikova Z. & Fabis M. (2010) The pathological changes in the hind limb of a horse from the Roman Period. *Veterinarni Medicina* 55(7), 331–335.
- Johansen P. & von zur Mühlen H. (1973) *Deutsch und Undeutsch im mittelalterlichen und frühneuzeitlichen Reval*. Köln, Böhlau.
- KB = *Kämmereibuch der Stadt Reval 1463–1507*, ed. by R. Vogelsang (1983), Köln, Wien, Böhlau.
- Kiesewalter L. (1888) *Skelettmessungen am Pferde als Beiträge zur theoretische Grundlage der Beurteilungslehre des Pferdes*. Inaugural-Dissertation einer hohen philosophischen Facultät der Universität Leipzig.
- Kodar A. (1993–1995) *Viljandi muuseumi hoovi kaevamiste materjalid: välitööde märkmed, joonised*. Unpublished fieldwork notes, Museum of Viljandi and in author's possession.
- LECUB = *Liv-, Est- und Curländisches Urkundenbuch. Bd. 8*, ed. by H. Hildebrand (1884), Riga, Moskau, Deubner.
- Leimus I. (2017) Eesti hobune – strateegiline kaup keskajal. *Tuna* 2/2017, 10–19.

- Lugo J. & Gaughan E.M. (2006) Septic Arthritis, Tenosynovitis, and Infections of Hoof Structures. *Veterinary Clinics: Equine Practice* 22, 363–388.
- Maldre L. (1998) Hobune Eestis muinas- ja keskajal. In: *Loodus, inimene ja tehnoloogia: interdistsiplinaarseid uurimusi arheoloogias = Nature, man and technology: interdisciplinary studies in archaeology*, Muinasaja Teadus 5. Tallinn, Eesti TA Ajaloo Instituut, 203–220.
- McClure S.R., Watkins J.P., Glickman N.W., Hawkins J.F. & Glickman L.T. (1998) Complete fractures of the third metacarpal or metatarsal bone in horses: 25 cases (1980–1996). *Journal of the American Veterinary Medical Association* 213, 847–850.
- McShane C. & Tarr J.A. (2006) The Horse as Technology – the City Animal as Cyborg. In: S.L. Olsen, S. Grant, A.M. Choyke & L. Bartosiewicz (eds.) *Horses and Humans: The Evolution of Human-Equine Relationships*, BAR International Series 1560. Oxford, Archaeopress, 365–375.
- MÄ = *Das Marienburger Ämterbuch*, ed. by W. Ziesemer (1916), Danzig.
- Mänd A. (2016) Horses, stags and beavers: animals as presents in Late-Medieval Livonia. *Acta Historica Tallinnensia* 22, 3–17.
- Mänd A. (2017) Animals as Presents in Late-Medieval Livonia. In: A.M. Choyke & G. Jaritz (eds.) *Animaltown: Beasts in Medieval Urban Space*, BAR International Series 2858. Oxford, BAR Publishing, 59–65.
- Märtson A. (2006) *Lower limb lengthening: experimental studies of bone regeneration and long-term clinical results. Dissertationes Medicinae Universitatis Tartuensis 122*. Tartu, Tartu University Press.
- Niilo A. (1936) Meie väikseim hobune. *Agronomia* 16(1), 8–13.
- O'Connor T. (2003) *The Analysis of Urban Animal Bone Assemblages: A Handbook for Archaeologists*, The Archaeology of York, Principles and Methods 19/2. York, York Archaeological Trust for Excavation and Research.
- Orsini J.A. & Divers T.J. (eds.) (2014) *Equine Emergencies: Treatment and Procedures*, 4<sup>th</sup> ed. St. Louis, Elsevier Saunders.
- Rannamäe E. & Lõugas L. (in press) Animal exploitation in Karksi and Viljandi (Estonia) in the Late Iron Age and medieval period. In: A.G. Pluskowski (ed.) *The Ecology of Crusading, Colonisation and Religious Conversion in the Medieval Eastern Baltic: Terra Sacra II*. Turnhout, Brepols.
- Reidla K. (1995) *Põllumajandusloomade traumatism*. Tartu, Eesti Loomaarstide Ühingu Kirjastus.
- Reidla K. (2004) *Veterinaar-erikirurgia III*. Tartu, Eesti Põllumajandusülikool.
- Saastamoinen M. (2011) Kui palju hobune kaalub? In: A. Ruus (ed.) *Eesti hobune*. Tallinn, Eesti Hobuse Kaitse Ühing, 52–57.
- Teichert M. (1988) Gebissanomalien und Pathologisch-Anatomische Veränderungen an Tierknochen aus der Germanischen Siedlung bei Mühlberg, Kreis Gotha. *Archiv für Experimentelle Veterinarmedizin* 42, 294–301.
- Teinberg R., Kalamees K. & Kallaste A. (1995) Native cattle and horse breeds in Estonia. *Animal Genetic Resources Information* 16, 65–70.

Thomas R. (2005) Perceptions Versus Reality: Changing Attitudes towards Pets in Medieval and Post-Medieval England. In: A. Pluskowski (ed.) *Just Skin and Bones? New Perspectives on Human-Animal Relations in the Historical Past*, BAR International Series 1410. Oxford, Archaeopress, 95–105.

Tvauri A. (2009) Late medieval hypocausts with heat storage in Estonia. *Baltic Journal of Art History* 1, 49–78.

Udrescu M. & Van Neer W. (2005) Looking for human therapeutic intervention in the healing of fractures of domestic animals. In: J. Davies, M. Fabiš, I. Mainland, M. Richards & R. Thomas (eds.) *Diet and health in past animal populations. Current research and future directions. Proceedings of the 9<sup>th</sup> Conference of the International Council of Archaeozoology*, Durham, August 2002. Oxford, Oxbow Books, 24–33.

Vitt 1952 = Витт В.О. (1952) Лошади Пазырыкских курганов. *Советская археология* 16, 163–205.