



This is a repository copy of *The diagnostic accuracy of cross-sectional imaging for detecting acute scaphoid fractures in children: a systematic review*.

White Rose Research Online URL for this paper:
<http://eprints.whiterose.ac.uk/127642/>

Version: Supplemental Material

Article:

Offiah, A.C. orcid.org/0000-0001-8991-5036 and Burke, D. (2018) The diagnostic accuracy of cross-sectional imaging for detecting acute scaphoid fractures in children: a systematic review. *British Journal of Radiology*, 91 (1086). ISSN 0007-1285

<https://doi.org/10.1259/bjr.20170883>

© 2018 The Authors. This is an author produced version of a paper subsequently published in *British Journal of Radiology*. Uploaded in accordance with the publisher's self-archiving policy.

Reuse

Items deposited in White Rose Research Online are protected by copyright, with all rights reserved unless indicated otherwise. They may be downloaded and/or printed for private study, or other acts as permitted by national copyright laws. The publisher or other rights holders may allow further reproduction and re-use of the full text version. This is indicated by the licence information on the White Rose Research Online record for the item.

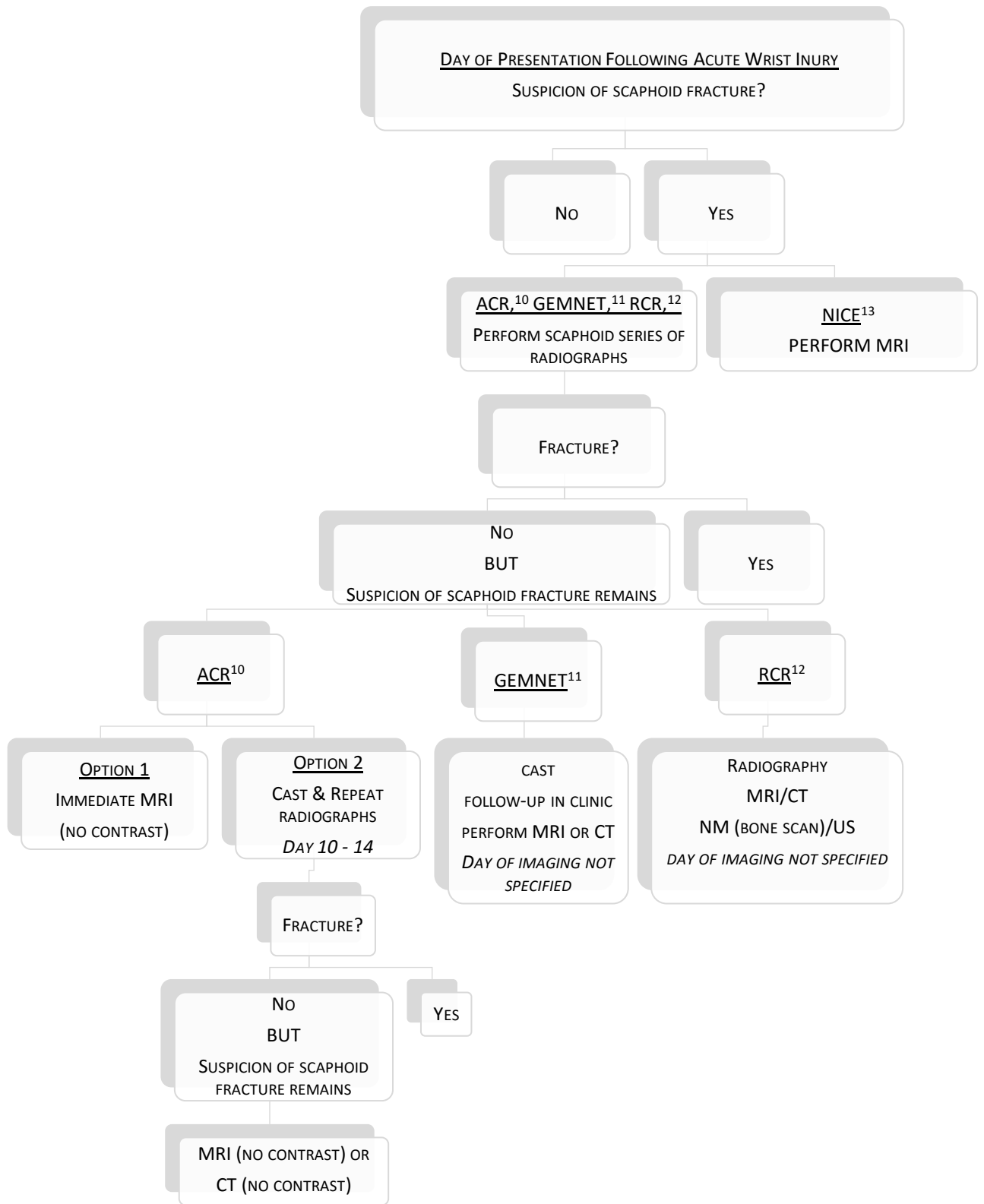
Takedown

If you consider content in White Rose Research Online to be in breach of UK law, please notify us by emailing eprints@whiterose.ac.uk including the URL of the record and the reason for the withdrawal request.



eprints@whiterose.ac.uk
<https://eprints.whiterose.ac.uk/>

Figure 2: Summary of existing guidelines for imaging of suspected scaphoid fracture*



* No existing guidelines specifically for children