



This is a repository copy of *Anti-Melanoma immunity and local regression of cutaneous metastases in melanoma patients treated with monobenzone and imiquimod; a phase 2 a trial.*

White Rose Research Online URL for this paper:  
<http://eprints.whiterose.ac.uk/127102/>

Version: Published Version

---

**Article:**

Teulings, H.E., Tjin, E.P.M., Willemsen, K.J. et al. (14 more authors) (2018) Anti-Melanoma immunity and local regression of cutaneous metastases in melanoma patients treated with monobenzone and imiquimod; a phase 2 a trial. *Oncolmmunology*, 7 (4). e1419113. ISSN 2162-4011

<https://doi.org/10.1080/2162402X.2017.1419113>

---

**Reuse**

This article is distributed under the terms of the Creative Commons Attribution-NonCommercial (CC BY-NC) licence. This licence allows you to remix, tweak, and build upon this work non-commercially, and any new works must also acknowledge the authors and be non-commercial. You don't have to license any derivative works on the same terms. More information and the full terms of the licence here:  
<https://creativecommons.org/licenses/>

**Takedown**

If you consider content in White Rose Research Online to be in breach of UK law, please notify us by emailing [eprints@whiterose.ac.uk](mailto:eprints@whiterose.ac.uk) including the URL of the record and the reason for the withdrawal request.



[eprints@whiterose.ac.uk](mailto:eprints@whiterose.ac.uk)  
<https://eprints.whiterose.ac.uk/>

## Anti-Melanoma immunity and local regression of cutaneous metastases in melanoma patients treated with monobenzone and imiquimod; a phase 2 a trial

Hansje-Eva Teulings, Esther P. M. Tjin, Karina J. Willemsen, Stephanie van der Kleij, Sylvia ter Meulen, E. Helen Kemp, Gabrielle Krebbers, Carel J. M. van Noesel, Cornelis L. M. C. Franken, Jan W. Drijfhout, Cornelis J. M. Melief, Ludmila Nieuweboer-Krobotova, Omgo E. Nieweg, Jos A. van der Hage, J. P. Wietze van der Veen, Germaine N. Relyveld & Rosalie M. Luiten

To cite this article: Hansje-Eva Teulings, Esther P. M. Tjin, Karina J. Willemsen, Stephanie van der Kleij, Sylvia ter Meulen, E. Helen Kemp, Gabrielle Krebbers, Carel J. M. van Noesel, Cornelis L. M. C. Franken, Jan W. Drijfhout, Cornelis J. M. Melief, Ludmila Nieuweboer-Krobotova, Omgo E. Nieweg, Jos A. van der Hage, J. P. Wietze van der Veen, Germaine N. Relyveld & Rosalie M. Luiten (2018): Anti-Melanoma immunity and local regression of cutaneous metastases in melanoma patients treated with monobenzone and imiquimod; a phase 2 a trial, *Oncoimmunology*, DOI: [10.1080/2162402X.2017.1419113](https://doi.org/10.1080/2162402X.2017.1419113)

To link to this article: <https://doi.org/10.1080/2162402X.2017.1419113>



© 2017 The Author(s). Published with license by Taylor & Francis Group, LLC© Hansje-Eva Teulings, Esther P. M. Tjin, Karina J. Willemsen, Stephanie van der Kleij, Sylvia ter Meulen, E. Helen Kemp, Gabrielle Krebbers, Carel J. M. van Noesel, Cornelis L. M. C. Franken, Jan W. Drijfhout, Cornelis J. M. Melief, Ludmila Nieuweboer-Krobotova, Omgo E. Nieweg, Jos A. van der Hage, J. P. Wietze van der Veen, Germaine N. Relyveld, and Rosalie M. Luiten




View supplementary material 



Published online: 15 Jan 2018.



Submit your article to this journal 



Article views: 328



View related articles [↗](#)


---



View Crossmark data [↗](#)

---

## Anti-Melanoma immunity and local regression of cutaneous metastases in melanoma patients treated with monobenzene and imiquimod; a phase 2 a trial

Hansje-Eva Teulings<sup>a,b</sup>, Esther P. M. Tjin<sup>a</sup>, Karina J. Willemsen<sup>a</sup>, Stephanie van der Kleij<sup>b</sup>, Sylvia ter Meulen<sup>c</sup>, E. Helen Kemp<sup>d</sup>, Gabrielle Krebbers<sup>a</sup>, Carel J. M. van Noesel<sup>e</sup>, Cornelis L. M. C. Franken<sup>f</sup>, Jan W. Drijfhout<sup>f</sup>, Cornelis J. M. Melief<sup>g</sup>, Ludmila Nieuweboer-Krobotova<sup>a,b</sup>, Omgo E. Nieweg<sup>c</sup>, Jos A. van der Hage<sup>c</sup>, J. P. Wietze van der Veen<sup>a,b</sup>, Germaine N. Relyveld <sup>b</sup>, and Rosalie M. Luiten<sup>a</sup>

<sup>a</sup>Dept. of Dermatology, Academic Medical Center, University of Amsterdam, Amsterdam, The Netherlands; <sup>b</sup>Depts. of Dermatology, Antoni van Leeuwenhoek Netherlands Cancer Institute, Amsterdam, The Netherlands; <sup>c</sup>Surgical Oncology, Antoni van Leeuwenhoek Netherlands Cancer Institute, Amsterdam, The Netherlands; <sup>d</sup>Dept. of Oncology and Metabolism, University of Sheffield, Sheffield, UK; <sup>e</sup>Dept. of Pathology, Academic Medical Center, University of Amsterdam, Amsterdam, The Netherlands; <sup>f</sup>Dept. of Immunohematology and Blood Transfusion, Leiden University Medical Center, Leiden, The Netherlands; <sup>g</sup>ISA Pharmaceuticals, Leiden, The Netherlands

### ABSTRACT

Vitiligo development in melanoma patients during immunotherapy is a favorable prognostic sign and indicates breakage of tolerance against melanocytic/melanoma antigens. We investigated a novel immunotherapeutic approach of the skin-depigmenting compound monobenzene synergizing with imiquimod in inducing antimelanoma immunity and melanoma regression. Stage III-IV melanoma patients with non-resectable cutaneous melanoma metastases were treated with monobenzene and imiquimod (MI) therapy applied locally to cutaneous metastases and adjacent skin during 12 weeks, or longer. Twenty-one of 25 enrolled patients were evaluable for clinical assessment at 12 weeks. MI therapy was well-tolerated. Partial regression of cutaneous metastases was observed in 8 patients and stable disease in 1 patient, reaching the statistical endpoint of treatment efficacy. Continued treatment induced clinical response in 11 patients, including complete responses in three patients. Seven patients developed vitiligo-like depigmentation on areas of skin that were not treated with MI therapy, indicating a systemic effect of MI therapy. Melanoma-specific antibody responses were induced in 7 of 17 patients tested and melanoma-specific CD8<sup>+</sup>T-cell responses in 11 of 15 patients tested. These systemic immune responses were significantly increased during therapy as compared to baseline in responding patients. This study shows that MI therapy induces local and systemic anti-melanoma immunity and local regression of cutaneous metastases in 38% of patients, or 52% during prolonged therapy. This study provides proof-of-concept of MI therapy, a low-cost, broadly applicable and well-tolerated treatment for cutaneous melanoma metastases, attractive for further clinical investigation.

### ARTICLE HISTORY

Received 21 July 2017  
Revised 11 December 2017  
Accepted 12 December 2017

### KEYWORDS


Melanoma; immunotherapy;  
vitiligo; cutaneous  
metastases

### Introduction

Melanoma patients undergoing immunotherapy can develop autoimmunity against melanocytes resulting in vitiligo-like depigmentation.<sup>1</sup> Our systematic review and meta-analysis of clinical immunotherapy studies over the past 18 years showed that vitiligo development in advanced melanoma patients during immunotherapy is associated with prolonged progression-free and overall survival (disease progression Hazard Ratio (HR) 0.51,  $p < 0.005$ ; risk of death HR 0.25,  $p < 0.003$ ).<sup>2</sup> This type of depigmentation in melanoma patients indicates breakage of tolerance against melanocytic antigens, leading to clinically active anti-melanocyte/melanoma immunity, consisting of melanoma-reactive T-cells and antibody responses.<sup>3,4</sup>

We developed a new type of immunotherapy for melanoma using the vitiligo-inducing agent monobenzene combined with imiquimod and/or CpG oligodeoxynucleotide. Our preclinical results showed synergy of these compounds in specifically inducing antimelanoma immunity and tumor growth inhibition.<sup>5</sup> Monobenzene (monobenzyl ether of hydroquinone) is a potent skin-bleaching agent that can induce vitiligo.<sup>6,7</sup> It has been used in the past to achieve complete depigmentation in patients with vitiligo universalis.<sup>6</sup> Importantly, monobenzene-induced depigmentation also occurs at distant, non-exposed skin sites in human beings, indicating the occurrence of systemic reactivity against melanocytes. The mechanism of action of monobenzene therapy consists of the selective interaction of

**CONTACT** Rosalie M. Luiten  [r.m.luiten@amc.uva.nl](mailto:r.m.luiten@amc.uva.nl)  Dept. of Dermatology Academic Medical Center, P.O Box 22660 1100 DD Amsterdam, The Netherlands.

 Supplemental data for this article can be accessed on the [publisher's website](#).

© 2017 Hansje-Eva Teulings, Esther P. M. Tjin, Karina J. Willemsen, Stephanie van der Kleij, Sylvia ter Meulen, E. Helen Kemp, Gabrielle Krebbers, Carel J. M. van Noesel, Cornelis L. M. C. Franken, Jan W. Drijfhout, Cornelis J. M. Melief, Ludmila Nieuweboer-Krobotova, Omgo E. Nieweg, Jos A. van der Hage, J. P. Wietze van der Veen, Germaine N. Relyveld, and Rosalie M. Luiten. Published with license by Taylor & Francis Group, LLC

This is an Open Access article distributed under the terms of the Creative Commons Attribution-NonCommercial License (<http://creativecommons.org/licenses/by-nc/4.0/>), which permits unrestricted non-commercial use, distribution, and reproduction in any medium, provided the original work is properly cited.

monobenzone with tyrosinase, the rate-limiting enzyme in melanin synthesis, in both melanocytes and melanoma cells.<sup>8,9</sup> This interaction leads to the inactivation of the tyrosinase enzyme and the formation of the reactive quinone product that is toxic to the melanocyte, and binds to melanosomal proteins, which increases the immunogenicity of these proteins. Together with the production of reactive oxygen species and the release of exosomes by monobenzone-exposed pigmented cells, this leads to the induction of systemic melanocyte/melanoma antigen-specific immunity.<sup>8,9</sup> Monobenzone acts synergistically in combination with the Toll-like receptor (TLR) agonists imiquimod (Aldara®) and CpG, to activate dendritic cells and induces effective immunity against established murine melanoma.<sup>5</sup>

Here, we present the first clinical study of monobenzone/imiquimod (MI) therapy in melanoma patients, exploring its immunizing capacity and local clinical effect against cutaneous melanoma metastases. Cutaneous metastases, including local relapse, satellite metastases or in-transit metastases, occur in approximately 5% of melanoma patients and they imply a negative prognostic outcome comparable to lymph node metastases.<sup>10</sup> Stage III melanoma patients with extensive cutaneous metastases not eligible for surgery have limited treatment options, as treatment of all cutaneous lesions in an affected skin area, especially microscopic lesions, remains difficult. Several local strategies such as carbon dioxide laser ablation, radiotherapy/hyperthermia, electrochemotherapy, topical immune modifiers, diphencyprone and intralesional therapy with cytokines have been applied but clinical results vary.<sup>11-17</sup> Isolated limb perfusion (ILP) or infusion (ILI) can be effective but also has significant toxicity. Injections with oncolytic viruses producing GM-CSF (T-Vec) show promising results, indicating that local immune stimulating therapy can translate into durable clinical responses in these patients.<sup>18</sup> However, this is an intensive treatment of biweekly intralesional injections, which can be painful for the patient and requires a post-injection observation of several hours in the hospital and extensive safety precautions limiting its use in non-specialized medical centers.

MI therapy may represent an attractive option for topical treatment of cutaneous melanoma metastases, including large numbers of small lesions that are not surgically resectable, considering its targeted antimelanoma immunizing mechanism of action preventing relapse in preclinical studies and with a low toxicity profile.

The objectives of this clinical trial were to assess clinical efficacy of MI therapy on cutaneous metastases in stage III-IV melanoma patients and its capacity to induce local and systemic antimelanoma immunity in patients.

## Results

### Patient characteristics

Twenty-five patients were accrued for the study in order to reach the required number of 21 evaluable patients according to the study design. All patients were monitored for systemic disease progression during the study as standard of care. Four patients were not evaluable for local efficacy of MI therapy: one patient decided to stop treatment for personal reasons; three patients were diagnosed with distant metastases during the

study and were referred back to their treating physician. Twenty-one patients did not experience systemic disease progression and were evaluable at the primary endpoint. Clinical and demographic characteristics of these 21 patients are shown in [Table 1](#). All patients, except for patient MI-02, had undergone prior lymph node dissection. [Table 1](#) shows the sites of metastases at study entry. Patients with cutaneous metastases not eligible for surgery were included, which presented as multiple small cutaneous lesions located on the extremities. Seventeen patients of the 21 evaluable patients received at least 12 weeks of MI therapy. Four patients of 21 patients stopped after 6 weeks due to local progression and were evaluated as PD at the primary endpoint. Thirteen patients continued MI therapy after 12 weeks. The median duration of therapy was 16 weeks.

### Toxicity

Adverse events causally related to MI therapy are listed in [Table 2](#). MI therapy was well tolerated. Almost all adverse events were grade 1 or 2 and resolved within 2–3 days, most were skin related (erythema, rash, pruritus, ulceration, crusta, edema, burning sensation) and few were systemic (transient fatigue, headache, nausea and flu-like symptoms). One patient developed erysipelas requiring hospitalization (grade 3) and 1 patient (MI-02) developed a contact hypersensitivity reaction to monobenzone within the first 6 weeks which required discontinuation of monobenzone in both patients. Hypersensitivity symptoms were relieved with topical steroids. Patient MI-25 interrupted MI treatment for 10 days due to an itchy skin rash but restarted thereafter and continued MI therapy for 12 weeks. No serious adverse events occurred and no patient left the study for safety reasons.

### Clinical responses

Local response of cutaneous metastases and response duration were evaluated in 21 patients ([Table 1](#)). These 21 patients did not develop systemic disease progression during MI therapy until the primary endpoint at 12 weeks. The study protocol was designed to include patients with inoperable cutaneous metastases, which mostly present as multiple small cutaneous lesions within a certain body area. MI therapy was therefore evaluated as a treatment option for these lesions. All treated lesions were smaller than 1 cm in diameter (non-target lesions), and tumor responses were assessed by the number of lesions relative to baseline, as described in the Patients and Methods section. In case of doubt, when clinically only hyperpigmentation was seen in a lesion that had regressed in size but did not completely disappear, the lesion was biopsied for histological analysis. The response rate was 38%, with 8 of 21 patients achieving PR after 12 weeks of treatment. In addition, one patient had stable disease (SD) after 12 weeks. This study thereby reached the statistical endpoint of local treatment efficacy to warrant further studies of MI therapy. Prolonged MI therapy improved the therapeutic effect, as shown by further decrease in number of lesions in 11 patients (response rate 52%). This response rate included 2 patients (MI-16 and MI-24) who did not show a local clinical response at 12 weeks and continued MI therapy because of lack of alternative treatment options, and responded

**Table 1.** Patient characteristics at study entry and clinical response to MI therapy.

Patient	Age (years)	M/F	Clinical stage <sup>a</sup>	TNM stage <sup>a</sup>	primary tumor			Site of metastasis <sup>d</sup>	Prior treatment <sup>e</sup>	serum S-100B		vitiligo t = 12	lesions (n)		Response at t = 12	MI therapy (weeks)	Best Response during MI therapy
					Site	Histology <sup>b</sup>	Bresl. <sup>c</sup>			t = 0	t = 12		t = 0 <sup>f</sup>	t = 12			
MI-07	60	F	IIIc	T2aN2cM0	leg	NA	1.4	skin	excision	0.04	0.05	—	13	10	PR	35	PR
MI-09	56	F	IIIc	T3bN2cM0	foot	SSM	4.0	skin	surgery/imiquimod	0.07	0.08	—	11	6	PR	32	CR
MI-10	73	F	IIIc	T1–4N3M0*	foot	NA	NA	skin	excision	0.06	0.05	—	7	4	PR	15	PR
MI-11	80	F	IIIc	T3bN2cM0	leg	NA	3.5	skin/sub-Q	excision, ILP	0.07	0.06	+	77	70	PR	16	PR
MI-14	75	M	IIIc	T1aN2cM0	leg	SSM	0.95	skin	excision	0.06	0.1	—	18	20	PD	12	PD
MI-15	71	F	IIIc	T2aN3M0	scapula	NA	1.4	skin	excision	0.07	0.07	—	165	170	PD	16	PD
MI-16	81	F	IIIc	T4bN2cM0	foot	NA	10	skin	excision	0.14	0.11	—	56	65	PD	28	PR
MI-17	71	F	IIIc	T4bN3M0	leg	acral	7.0	skin	excision, ILP, laser	0.07	0.08	+	20	42	PD	12	PD
MI-18	70	M	IIIc	T1bN2cM0	leg	SSM	0.6	skin	excision, laser	0.05	0.06	—	11	6	PR	16	PR
MI-19	66	F	IIIc	T2aN3M0	leg	NA	2.0	skin	excision	0.05	0.06	+	122	278	PD	12	PD
MI-20	53	M	IIIc	T2bN3M0	leg	SSM	2.0	skin	excision	0.04	0.08	—	33	14	PR	20	PR
MI-21	34	F	IIIc	T3aN3M0	leg	NA	2.6	skin	excision	0.05	na	—	8	>10	PD*	6	PD
MI-22	42	F	IIIc	T3 a,1bN3M0~	foot	SSM	3.8, 0.8	skin	excision, RT	0.08	na	—	13	>22	PD*	6	PD
MI-23	73	M	IIIc	T4bN3M0	foot	ALM	11	skin	excision, laser	0.06	0.1	+	14	36	PD	16	PD
MI-24	69	F	IIIc	T3bN2cM0	leg	SSM	2.2	skin	excision	0.07	0.08	—	69	161	PD	36	CR
MI-25	56	M	IIIc	T2aN3M0	back	SSM	1.04	skin	excision	0.05	0.04	—	6	1	PR	12	PR
MI-02	39	M	IV	T2aN3M1 a	back	NA	1.2	skin, LN	excision	0.06	0.05	—	45	>45	PD <sup>#</sup>	6	PD
MI-03	56	M	IV	T2aN2cM1 a	abdomen	NA	1.03	skin	excision	0.07	0.11	+	63	>85	PD <sup>#</sup>	6	PD
MI-04	47	M	IV	T1bN3M1 a	back	SSM	0.9	skin/sub-Q	excision, DTIC (6x)	0.08	0.07	+	4	4	SD	72	CR
MI-08	64	M	IV	T1–4N2cM1 a*	face	NA	NA	skin	excision, RT, laser	0.08	0.09	+	91	70	PR	36	PR
MI-13	77	M	IV	T4bN3M1 a	thorax	NA	5.0	skin	hyperthermia	0.06	0.14	—	94	93 <sup>^</sup>	PD	16	PD

<sup>a</sup>according to the American Joint Commission on Cancer staging (Ref. 10).

<sup>b</sup>SSM superficial spreading melanoma; ALM acral lentiginous melanoma; NM nodular melanoma; NA not available.

<sup>c</sup>Breslow thickness (mm).

<sup>d</sup>Site of metastasis at study entry. SubQ, subcutaneous tissue; LN, lymph node.

<sup>e</sup>ILP, isolated limb perfusion; RT, radiotherapy; laser, C02 laser ablation.

<sup>f</sup>Corrected for biopsies taken.

<sup>†</sup>T staging not evaluable.

<sup>~</sup>patient had two primary melanomas (T3 a and T1b).

<sup>#</sup>progressive local disease at t = 6.

<sup>^</sup>development of target lesions.

**Table 2.** Adverse events by Common Toxicity Criteria.

	grade I/II	grade III/IV
skin and subcutaneous tissue disorder		
maculopapular rash	8	0
pruritus	4	0
skin ulceration	5	0
skin infection	6	1
dry skin	1	0
depigmentation	7	0
skin other		
erythema	14	0
crusta	7	0
contact hypersensitivity	1	0
edema	4	0
burning sensation	2	0
general adverse events		
myalgia	2	0
fatigue	9	0
flue like symptoms	3	0
headache	7	0
nausea	6	0
malaise	1	0

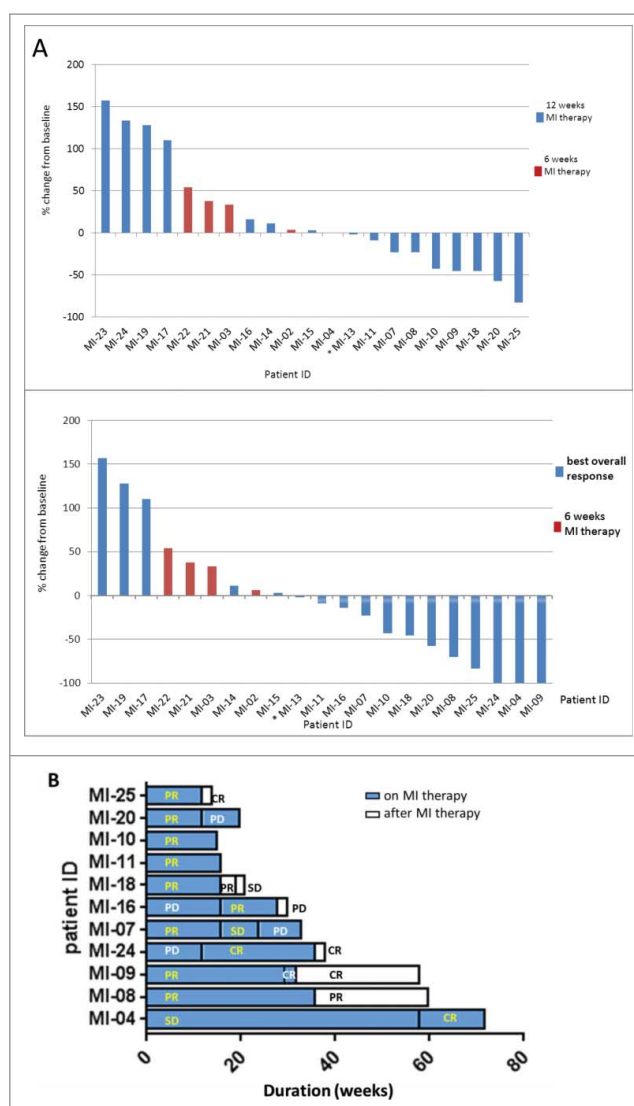
to prolonged MI therapy. The relative change in number of lesions in the 21 evaluable patients at  $t = 12$  and the best response during MI therapy (BR) are presented in **Figure 1A**.

The median clinical response duration in the 11 responding patients upon prolonged MI therapy was 6 months (**Figure 1B**). The median local progression-free survival during MI therapy and follow up without other therapy of all patients was 13 weeks. One stage IV patient (MI-04), having stable disease at  $t = 12$  weeks, continued MI therapy during 72 weeks and achieved CR by MI therapy only. After this study, he subsequently developed lymph node metastases in the right groin in December 2012, and received ipilimumab followed by pembrolizumab therapy. In March 2014 this lesion was excised and he experiences tumor-free survival. Patient MI-09 continued MI therapy for 32 weeks and achieved a CR. Patient MI-24 (PD) did not show any regression of cutaneous lesions until week 14 of MI therapy, but achieved a CR at 36 weeks of continued treatment. Likewise, patient MI-16 (PD) showed PR from 16 weeks of MI therapy onwards which continued up to 28 weeks. Patient MI-08 experienced regression of multiple cutaneous metastases in the head, neck and continued therapy up to 36 weeks (**Figure 2A**). Seven of the treated patients developed vitiligo-like depigmentation on areas of skin that were not treated with MI therapy (**Figure 2B**), indicating a systemic effect of MI therapy.<sup>3,4</sup>

Patient 25 had only 1 lesion left after 12 weeks of MI therapy. After this study, he continued with 5 times per week imiquimod (Aldara) treatment only. Since then he had 2 new in transit metastases in the treated area, which were excised, and is free of tumor since March 2016.

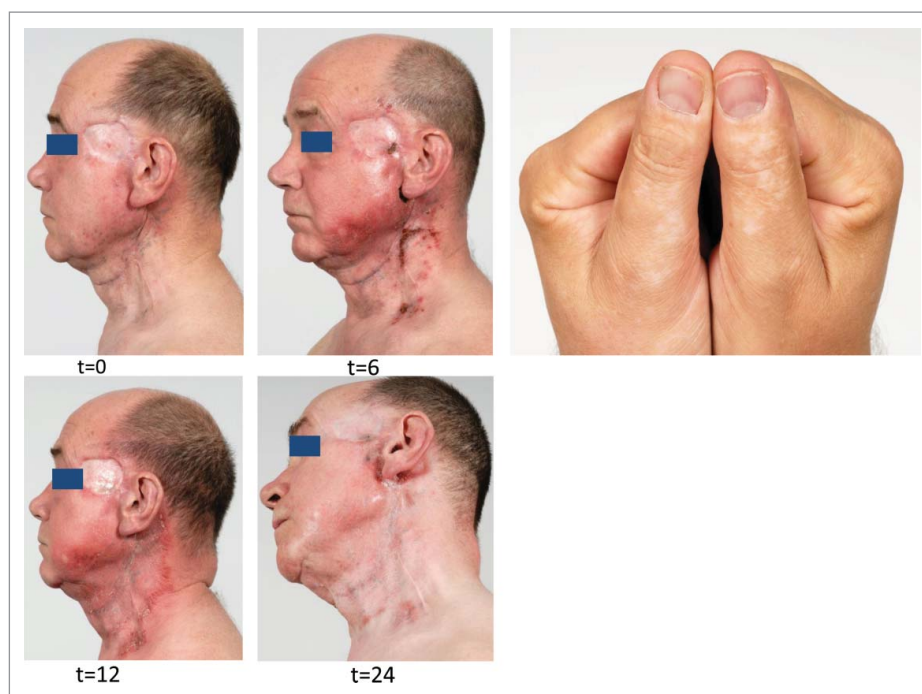
### Induction of antimelanoma immune responses

MI therapy induced specific antibody responses against MART-1, gp100 and tyrosinase in 7 of 17 patients who completed at least 12 weeks of MI therapy (**Figure 3**). None of the 4 nonresponding patients receiving only 6 weeks of MI therapy developed an antibody response. Antibody responses were found in 6 out of 11 patients with a clinical response to therapy



**Figure 1.** Local clinical responses of treated cutaneous metastases. A, Relative change (%) in number of cutaneous metastases at the primary endpoint after 12 weeks (*upper panel*) and the best response during MI therapy (*lower panel*) relative to baseline. The clinical response at 12 weeks was calculated by the formula:  $(L12-L0)/L0 \times 100\%$ , in which L0 is the number of lesions at baseline ( $t = 0$ ) and L12 the number of lesions at  $t = 12$ . The best response during MI therapy was calculated by the formula:  $(Lx-L0)/L0 \times 100\%$ , in which Lx is the least number of lesions during MI therapy, excluding  $t = 6$  weeks. Red bars represent nonresponding patients who stopped after 6 weeks. \*patient MI-13 developed target lesions (PD). B, Clinical response duration during prolonged MI therapy (*blue bars*) and after MI therapy cessation without additional therapy (*white bars*).

at 12 weeks or during prolonged MI therapy (**Figure 3A**). Only 1 patient (MI-15) out of 6 nonresponding patients, who completed 12 weeks of MI therapy, developed a melanoma-reactive antibody response (**Figure 3B**). A time-related increase of melanoma-specific antibody levels was observed in most patients and lasted for 10 weeks to one year. Antibody index levels of all patients analyzed were increased at 12 weeks as compared to baseline (baseline median 1.01, interquartile range (IQR) 0.93–1.04 vs median at 12 weeks 1.20, IQR 0.95–1.38,  $p < 0.024$ ). This significant increase was found in responders (baseline median 1.01, IQR 0.92–1.03 vs median at 12 weeks 1.31, IQR 0.97–1.67,  $p < 0.002$ ), and was not significant in nonresponding, nonresponding patients (baseline median 1.01, IQR 0.95–1.05 vs median at 12 weeks 1.07, IQR 0.92–1.03,  $p > 0.57$ ).



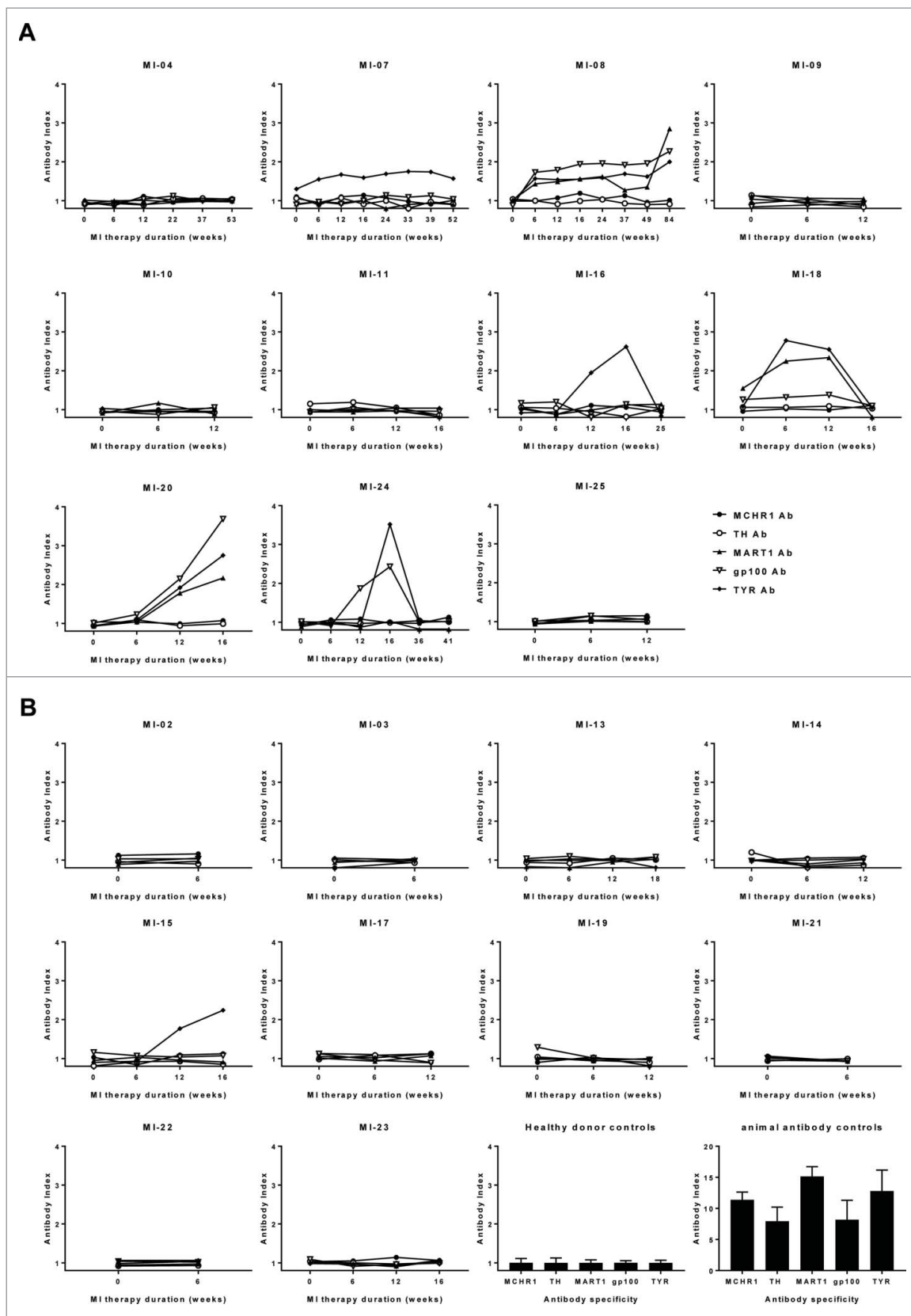
**Figure 2.** Tumor regression and depigmentation. *Left panels:* Regression of multiple cutaneous metastases in the head and neck of patient MI-08 during MI therapy. Photographs are taken at baseline and at 6, 12 and 24 weeks of MI therapy. *Right panel:* Depigmentation on a non-treated area following MI therapy to cutaneous metastases on upper body in patient MI-04.

The induction of systemic T-cell responses was analyzed by HLA-peptide tetramer analysis of T-cells recognizing melanoma antigens MART-1, gp100 or tyrosinase presented by HLA-A1, -A2 or -A3. Both peripheral blood mononuclear cells (PBMC) and cultured peripheral blood lymphocytes (PBL) taken at baseline, 12 weeks and at later time points during prolonged therapy were analyzed. Examples of the flow cytometric analyses are shown in Figure S1. Fifteen patients who completed at least 12 weeks of MI therapy and were typed HLA-A1, -A2 and/or -A3 were analyzed (Figure 4 and S2). Concerning the other 6 patients: patients MI-07 and MI-15 did not have an HLA type including HLA-A1, -A2 or -A3 and Fig 4 could therefore not be analyzed by the panel of HLA-peptide tetramers; 4 patients who received only 6 weeks of therapy were not included in the T cell analyses. Since the kinetics of T-cell response induction or amplification varied among patients, we compared the maximal T-cell response level reached during MI therapy (at 12 weeks and later time points) with baseline per patient for each tetramer (Figure 4 and S2). This maximal T-cell response level was reached between 12 and 24 weeks of MI therapy. Part of the T-cell reactivity was already present at baseline, which is known to occur in melanoma, and these responses either increased or stabilized during MI therapy in the majority of cases. PBMC analyses showed increased melanoma-reactive T-cell responses upon MI therapy (at percentages higher than 0.1% of CD8+ T cells), as compared to baseline, against various melanoma antigens in 5 responding patients and 3 nonresponding patients (Figure 4). In PBL expanded from PBMC in a culture without specific antigenic stimulus, increased T-cell reactivity was found in 8 responding patients and 3 nonresponding patients upon MI therapy (Figure S2). The PBL data also includes patients MI-14 and MI-24, of whom PBMC were not evaluable. Although systemic

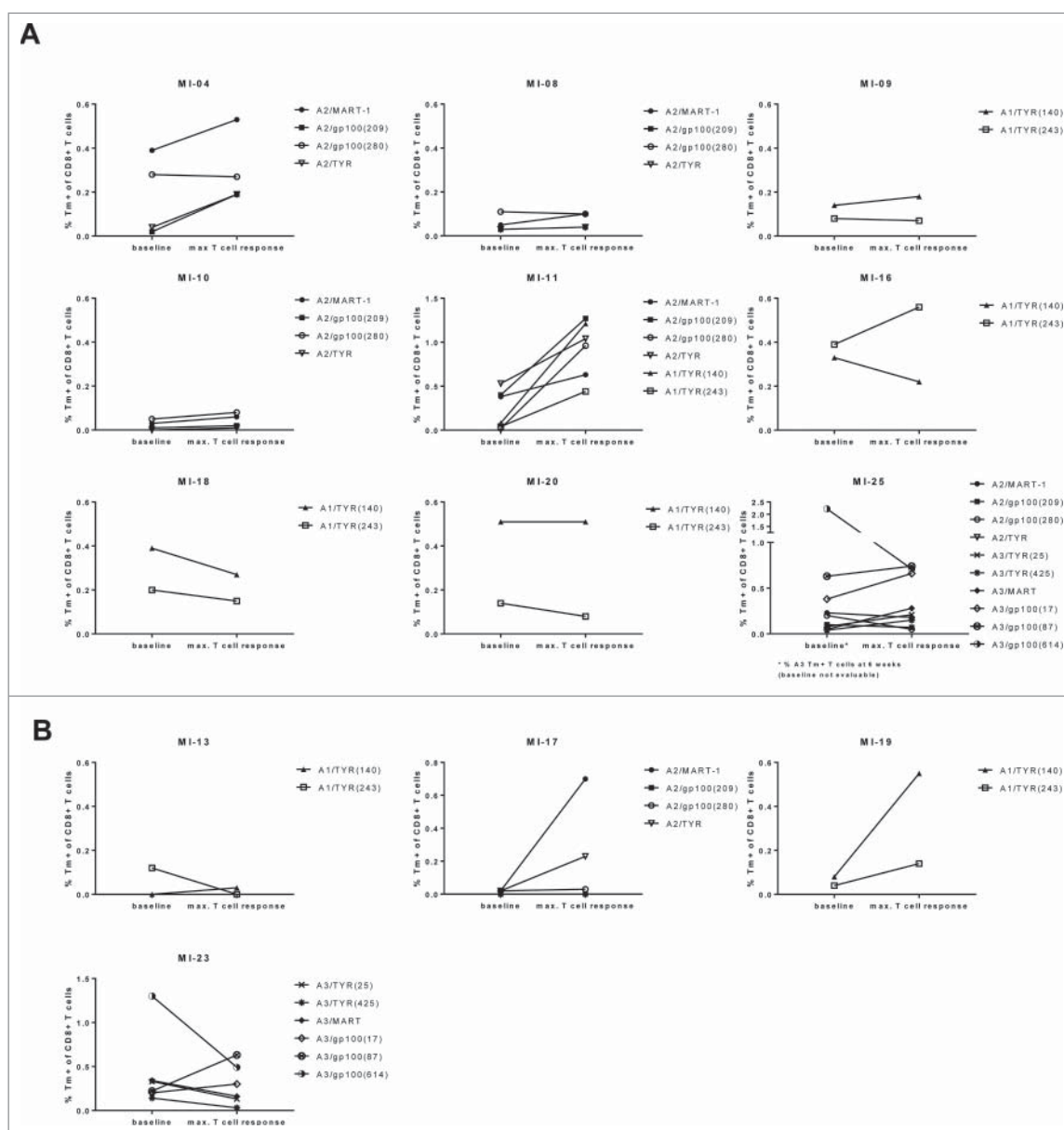
T-cell responses were found at low levels, pooled analysis of the percentages of melanoma-specific T-cells in the PBMC showed a significant increase upon MI therapy as compared to baseline (median 0.10, interquartile range (IQR) 0.03–0.31 vs median 0.17, IQR 0.06–0.47,  $p < 0.032$ ). These T-cell response levels were significantly increased in responding patients (median 0.10, IQR 0.03–0.34 vs 0.18, IQR 0.07–0.51,  $p < 0.016$ ), but not in nonresponding patients (median 0.10, IQR 0.02–0.24 vs 0.13, IQR 0.03–0.34,  $p > 0.98$ ).

Immunohistochemical analysis of biopsies taken from the tumor lesions and adjacent skin at baseline and at  $t = 12$  weeks showed an increase in CD3+ T-cell infiltration in the tumor in 2 of 4 responding patients (PR), and in 1 of 6 nonresponding patients (PD), and in adjacent skin in 2 of 7 responding patients and 2 of 10 nonresponding patients. We analyzed T-cells cultured from these tumor biopsies (TIL) or skin biopsies (SIL) of 15 patients (10 responders, 5 PD, all typed HLA-A1, A2 and/or A3) for the presence of antimelanoma CD8+ T-cell responses (Figure 5 and 6). Successful T-cell outgrowth in culture from tumor biopsies taken at baseline was observed in only 6 out of 15 patients (i.e. 4 out of 10 responding patients and 2 out of 5 nonresponding patients), suggesting low levels of T-cell infiltration into the tumor or their low proliferative capacity. T-cell outgrowth from biopsies during MI therapy succeeded in 11 of 15 patients (i.e. 8 out of 10 responding patients and 3 out of 5 nonresponding patients), suggesting an increased T cell infiltration or proliferative capacity upon MI therapy. Melanoma-reactive T-cells against one or more antigens were found upon MI therapy in TIL of 6 out of 8 responding patients with successful TIL growth upon MI therapy (Figure 5A) and in TIL of 3 out of 5 nonresponding patients (Figure 5B). The small size of the lesions treated in this study did not allow taking multiple biopsies from a single tumor





**Figure 3.** Induction of melanoma-specific antibody responses. Graphs show the antibody responses reactive with MART-1, gp100, tyrosinase, tyrosine hydroxylase or melanocortin receptor MCHR1 antigens during MI therapy in 11 responding patients (A) and 10 non-responding patients (B). Patients MI-02, MI-03, MI-21 and MI-22 only received 6 weeks of MI therapy. Antibody indices are normalized to a panel of 20 healthy controls. Antigen-specific animal antibodies were tested as positive controls.



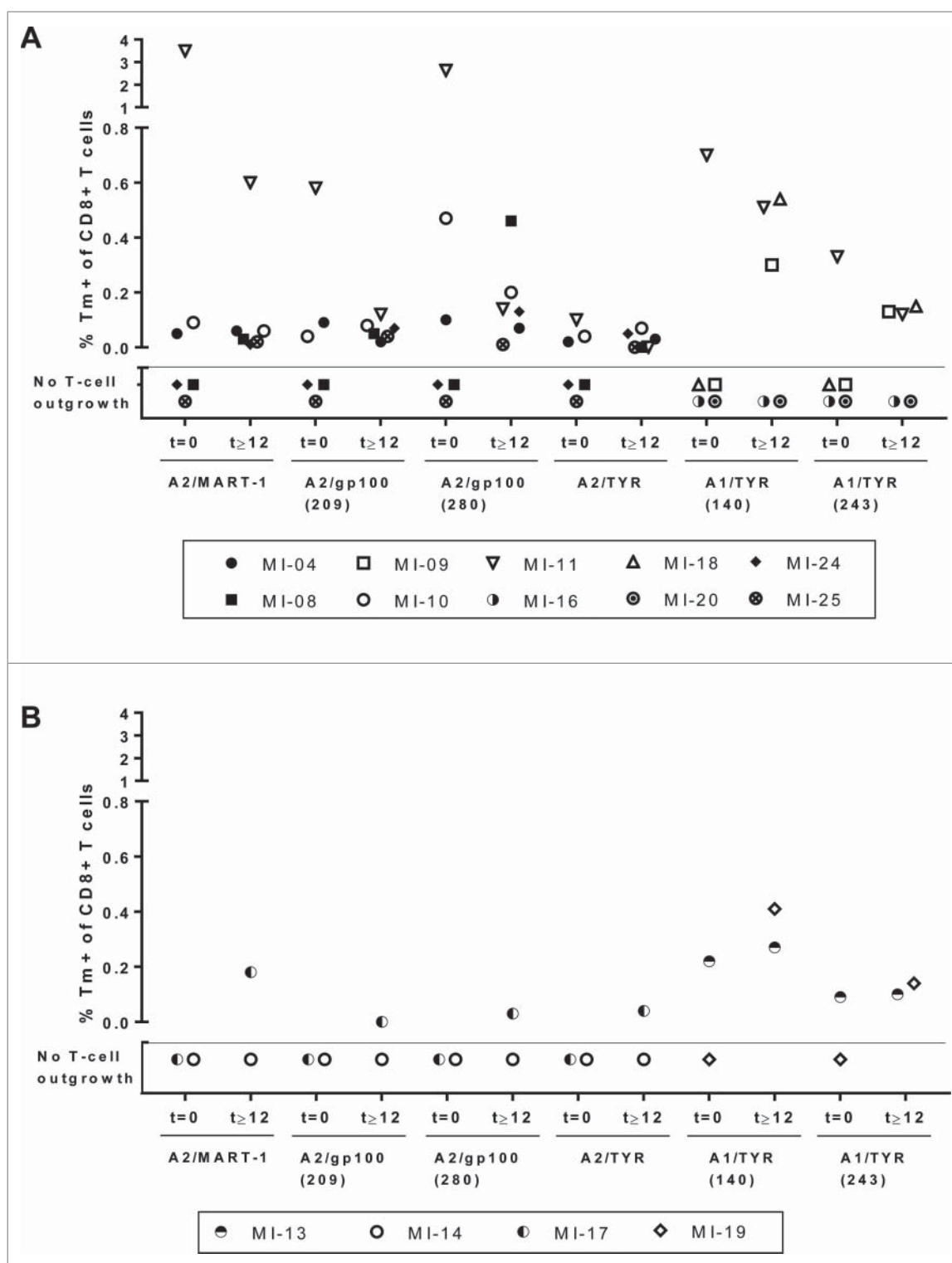
**Figure 4.** Melanoma-specific CD8<sup>+</sup> T-cell responses in PBMC upon MI therapy. Percentages of CD8<sup>+</sup> T-cells that recognize melanoma antigens MART-1, gp100 and tyrosinase presented by HLA-A1, -A2 or -A3 molecules. Graphs show the percentage of HLA-peptide-positive (Tm<sup>+</sup>) T-cells at baseline and the maximal level reached during MI therapy (max. T cell response) in the PBMC of responding patients (A) and nonresponding patients (B). PBMC analyses of patients MI-14 and MI-24 were not evaluable. Legends indicate the HLA-peptide tetramers analyzed: A2/MART-1, HLA-A2-binding epitope of MART-1; A3/MART-1, HLA-A3-binding epitope of MART-1; A2/gp100(209), HLA-A2-binding epitope 209 of gp100; A2/gp100(280), HLA-A2-binding epitope 280 of gp100; A3/gp100(17), HLA-A3-binding epitope 17 of gp100; A3/gp100(87), HLA-A3-binding epitope 87 of gp100; A3/gp100(614), HLA-A3-binding epitope 614 of gp100; A1/TYR(140), HLA-A1-binding epitope 140 of tyrosinase; A1/TYR(243), HLA-A1-binding epitope 243 of tyrosinase; A2/TYR, HLA-A2-binding epitope 243 of tyrosinase; A3/TYR(25), HLA-A3-binding epitope 25 of tyrosinase; A3/TYR(425), HLA-A3-binding epitope 425 of tyrosinase.

lesion over time, and thus biopsies at 12 weeks were taken from different lesions than at baseline, precluding analyses of changes in specific T-cell levels in the tumor during MI therapy.

In contrast to tumor lesions, longitudinal analysis of local T-cell response induction during MI therapy was more feasible in biopsies of MI therapy-treated adjacent skin taken at 6, 12 and 16 weeks and every 12 weeks thereafter during prolonged MI therapy. An increase in melanoma-reactive T-cells during MI therapy was found in skin-infiltrating lymphocytes (SIL) from biopsies taken at baseline or 6 weeks as compared to skin biopsies taken after 12 to 24 weeks, in 5 out of 6 responding patients

analyzed (Figure 6A) and in 2 out of 3 nonresponding patients analyzed (Figure 6B). Pooled analyses of the percentages of melanoma-specific T-cells in MI-therapy-treated skin of 9 patients analyzed showed small but significant increases in melanoma-specific T-cell levels at baseline or 6 weeks (median 0.13, IQR 0.04–0.31) as compared to 12 weeks or later time points (median 0.23, IQR 0.06–0.47,  $p < 0.031$ ).

Taken together, these results show that MI therapy effectively induced melanoma-specific antibody responses and T-cell reactivity and regression of treated cutaneous metastases in 8 of 21 patients after 12 weeks (38%) and in 11 of 21 patients (52%) upon prolonged treatment.

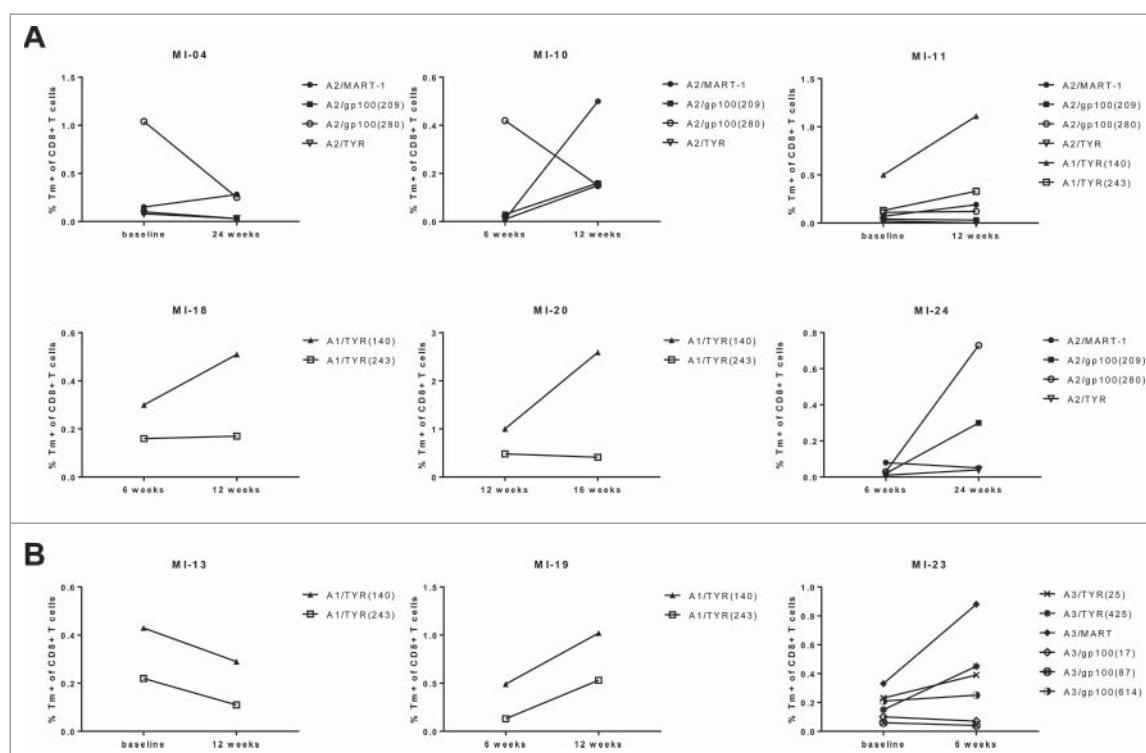


**Figure 5.** Melanoma-specific CD8+ T-cell responses in tumor-infiltrating lymphocytes (TIL) upon MI therapy. Percentages of CD8+ T-cells that recognize melanoma antigens MART-1, gp100 and tyrosinase presented by HLA-A1, -A2 or -A3 molecules. Graphs show the percentage of HLA-peptide-positive (Tm+) T-cells at baseline and during MI therapy in tumor-infiltrating lymphocytes (TIL) of responding patients (A) and nonresponding patients (B). X-axis indicates the HLA-peptide tetramers analyzed (see Figure 4) at baseline (t = 0) or upon ≥12 weeks of MI therapy. HLA-A3 tetramer analysis of patient MI-23 is not shown, since no T-cells grew out of biopsies during MI therapy and only baseline TILs were analyzed. Lower part indicates patients of whom no T-cells grew out of the tumor biopsy. Legends indicate the patients analyzed.

## Discussion

In the present study, we demonstrate that topical treatment with monobenzone and imiquimod can induce antimelanoma immunity and local regression of inoperable cutaneous metastases in stage III-IV melanoma patients. Eight (38%) out of 21

evaluable patients showed partial regression (8 patients) and one patient had stabilization of treated cutaneous lesions at the primary endpoint. Continued treatment strengthened the clinical response, achieving complete and partial responses in 11 of 21 patients (52%). This study outcome thereby meets the



**Figure 6.** Melanoma-specific CD8+ T-cell responses in skin-infiltrating lymphocytes upon MI therapy. Percentages of CD8+ T-cells that recognize melanoma antigens MART-1, gp100 and tyrosinase presented by HLA-A1, -A2 or -A3 molecules. Graphs show the percentage of HLA-peptide-positive (Tm+) T-cells at baseline and during MI therapy in skin-infiltrating lymphocytes (SIL) of responding patients (A) and nonresponding patients (B). Legends indicate the HLA-peptide tetramers analyzed (see Figure 4).

predetermined criteria of the study design to declare MI therapy effective and worthy of further investigation.

The best clinical responses during MI therapy indicate that the maximal induction of the antitumor response by MI therapy requires more than 12 weeks. This is clearly illustrated by the observations that 3 patients (MI-04, MI-09, MI-24) achieved a CR upon prolonged treatment and that the clinical response in two patients (MI-16 and MI-24) started later than 12 weeks, achieving PR and CR, respectively. Delayed clinical benefit is known from various immunotherapy regimens and has led to the development of immune related response criteria that take into account an initial increase in disease extent and allow for a longer interval before a response is established.<sup>19,20</sup> Clinical responses to MI therapy resulted in a median response duration of 6 months. Overall survival was not determined in this study that aimed at the local effect evaluation of MI therapy and response duration, but will be included in future subsequent investigations.

MI therapy was applied as a local therapy for cutaneous metastases, but also proved able to induce or enhance systemic immunity against melanoma antigens. The systemic immune activity was also demonstrated clinically by the development of vitiligo during therapy at distant skin sites. We have previously shown that patients with melanoma-associated vitiligo have both antibody and T-cell immunity against melanoma antigens.<sup>3,4</sup> We also observed clinical responses in patients who did not develop vitiligo within 12 weeks. Although we cannot exclude that some of these patients may have developed vitiligo at a later time point than 16 weeks, this suggests that the antitumor immune response also spreads to antigens that are not

shared by melanocytes. Tumor (neo)antigens arising from patient-specific mutations have been shown in patients that respond well to immunotherapy.<sup>21</sup> Further research will address whether MI therapy can induce responses against neoantigens. Vice versa, the occurrence of vitiligo and T-cell responses against melanocyte differentiation antigens (that shared between melanoma cells and melanocytes) in nonresponding patients may indicate loss of expression of these antigens in the tumor, resulting in immune escape of tumor cells. In these cases, the clinical benefit will depend on the spreading of the immune response to antigens that are expressed by escaping tumor cells.

Local targeting of melanoma cells and immune stimulation by MI therapy can induce priming of systemic immune responses, but additional immune adjuvants may be necessary to strengthen this systemic immunity. Our preclinical data has shown that the addition of CpG greatly enhances systemic anti-melanoma immunity induced by MI therapy.<sup>5</sup> The results of MI therapy described here provide a rationale for a trial to combine MI therapy with additional immune stimulation either by CpG or systemic therapy to enhance systemic antitumor activity.

Interestingly, antibody responses against melanocyte/melanoma antigens were found in responding patients, which were absent in almost all nonresponding patients. Not much is known about melanoma-specific antibodies and their relation to clinical outcome from literature.<sup>22-24</sup> The majority of immunomonitoring in immunotherapy studies focus on T-cell responses, in particular specific CD8+ T-cell responses using tetramer technology or activation assays. We demonstrated

that patients with melanoma-associated vitiligo have antibodies against gp100, tyrosinase and MART-1 in their serum while MART-1 antibodies were undetectable in vitiligo patients,<sup>4</sup> indicating their potential role in the melanoma-associated vitiligo. Antibody responses to these antigens were also found in a stage IV melanoma patient with an exceptional disease course of regression of brain metastases, vitiligo development and long-term disease-free survival upon radiotherapy.<sup>3</sup> These findings and the observation that MI therapy treated patients also developed MART-1 antibody responses further confirm the mechanism of action of MI therapy to induce melanoma-associated depigmentation and clinical benefit to melanoma patients.

By its specific interaction with tyrosinase, either by quinone-modification increasing their immunogenicity, or by epitope spreading of the T-cell response, monobenzone can induce immunity against a range of melanocyte/melanoma antigens presented in patient-specific HLA types.<sup>5,25</sup> MI therapy-induced immunity included CD8+ T-cell responses, having direct cytotoxic antimelanoma activity, and antibody responses that potentially amplify antimelanoma immunity by either antibody-dependent cellular cytotoxicity (ADCC) or by binding melanoma antigens released from dying cells and increasing their uptake and presentation by dendritic cells.<sup>26</sup> The effect of monobenzone is amplified by the addition of imiquimod, a topical immune response modifier and TLR7 ligand which stimulates the production of cytokines, namely interferon- $\alpha$ , IL-1, IL-6, IL-8 and TNF $\alpha$  and is known for its anti-viral and anti-tumor activity.<sup>27,28</sup> The locoregional immune activating activity of imiquimod was demonstrated in a placebo-controlled study of patients with high-risk primary melanoma, showing increased CD8+ T cell infiltration in the skin and sentinel lymph node, but not in the peripheral blood.<sup>29</sup> This indicates the low efficacy of imiquimod monotherapy to induce systemic melanoma-specific immunity. Several case reports and case series report the use of imiquimod as local monotherapy to treat cutaneous melanoma metastases that were not eligible for surgical excision.<sup>30</sup> Although these reports describe promising results, the therapeutic effect of imiquimod monotherapy on cutaneous melanoma metastases has never been evaluated in a clinical trial. In melanoma therapy, imiquimod has mostly been used as an adjuvant in combination with other treatments to enhance the induction of antitumor immunity, such as intralesional IL-2 injection with or without retinoid, intralesional BCG injection, protein or peptide vaccination, gentian violet, 5-FU, pulsed-dye laser, carbon dioxide laser, cryosurgery or isolated limb perfusion (ILP).<sup>31-42</sup> Imiquimod has recently also been applied to stimulate response to ipilimumab.<sup>43</sup>

In conclusion, this clinical study shows the induction of antimelanoma immunity and tumor regression of cutaneous melanoma metastases by MI therapy. MI therapy is applied by patients at home and has only transient skin toxicity, whereas T-Vec is a costly and intensive treatment of biweekly intralesional injections requiring specialized security measures for viral medication and time consuming post-injection observations of the patient in the clinic. MI therapy induced a clinical response in 7 patients within 12 weeks and in an additional 2 patients during prolonged therapy, which appears to be faster than the time to response to T-Vec in injected lesions of 4.1

months.<sup>18</sup> Moreover, multiple small lesions may be difficult to treat by intralesional injection. MI therapy may represent an attractive option for patients that do not receive T-Vec, e.g. in peripheral centers or when a cream based therapy is preferred. In addition, this study provides a rationale for further clinical investigation of MI therapy in combination with systemic therapy.

## Patients and methods

### Patients

This phase 2 a study was approved by the Institutional Review Board of the Antoni van Leeuwenhoek/ Netherlands Cancer Institute and by the Central Committee on Research Involving Human Subjects in the Netherlands (CCMO). (CCMO protocol number NL33849.031.10. The Netherlands trial register identifier: NTR 4848). All patients provided written informed consent. The study was performed between March 2011 and September 2014. All patients were staged prior to inclusion and during the trial according to standard hospital staging procedures. (Cross sectional staging was performed every three months). Eligibility criteria were histologically confirmed non-ocular melanoma patients with stage IIIC-IV disease, according to the American Joint Committee on Cancer staging classification, with multiple cutaneous metastases not eligible for surgery or other conventional therapies,<sup>10</sup> age  $\geq 18$  years, performance status 0-1 (WHO) and a wash-out period for prior systemic treatment of at least one month. Exclusion criteria included primary amelanotic melanoma, symptomatic brain metastases, concomitant treatment with immunosuppressive agents and active infections requiring antibiotics.

### Study design and sample size calculation

This study was designed to establish a proof-of-concept of local MI therapy efficacy. A positive effect in patients is defined as a local clinical response (CR, PR, SD) at the primary endpoint according to criteria described below in evaluable patients. For the sample size calculation the A'Hern single stage phase II design was applied, which is based on the exact binomial distribution and more accurate to estimate sample size in small trials than methods using the normal approximation.<sup>44</sup> It was specified in advance that the largest response probability which would imply that the treatment was clearly ineffective was  $p_0 = 0.20$ , and the smallest response probability that would clearly warrant further investigation was  $p_A = 0.45$ . The null hypothesis  $H_0: p \leq p_0 = 0.20$  is tested against the alternative  $H_A: p \geq p_A = 0.45$ . At the planning of the trial it was determined, using A'Hern's design,<sup>44</sup> that setting an  $\alpha$  of 0.05 and a power of 80%, the study should include 21 evaluable patients with 8 being the minimum number of responses required for a conclusion of sufficient treatment efficacy to justify further studies.

### Treatment

Patients applied imiquimod cream (2 sachets of 250 mg, 5% imiquimod, Aldara<sup>®</sup> Meda, Amstelveen, the Netherlands) 3 times a week on all cutaneous metastases present on an

predetermined body area including 1–2 cm unaffected skin surrounding the lesions. Monobenzone 20% (4-benzyloxyphenol, monobenzyl ether of hydroquinone, CAS number 103–16–2, Acros Organics, Geel, Belgium) Lanette cream FNA (Formulary Dutch Pharmacists) was applied seven times a week to the same skin area thereafter ( $\pm 1.5$  g). Monobenzone 20% cream was prepared magisterially for each individual patient upon inclusion in the study by the pharmacy of the Slotervaart Hospital, Amsterdam, the Netherlands (registration numbers 101018 A and 101019 C).

### Study endpoints and assessments

The primary endpoint was local clinical efficacy of MI therapy on cutaneous metastases in evaluable patients after 12 weeks of treatment. All patients were staged by their referring physician before entering the study. Evaluable patients were defined as patients who completed 12 weeks of MI therapy. Patients who experienced substantial increase in number or size of treated cutaneous lesions after 6 weeks, and who stopped MI therapy upon consultation of their physician, were evaluated as progressive disease (PD) at the primary study endpoint of this study. Control of systemic disease was performed by regular check-ups following our in-house guidelines according to disease stage. In case of suspicion of inoperable distant metastases after 6 weeks, and confirmation by imaging, the patient was referred to a medical oncologist for systemic therapy. In this case local clinical efficacy of MI therapy could not be monitored further and these patients were considered not evaluable for this study. The protocol provided for continued therapy in case of an ongoing clinical response, stable disease or lack of better treatment options in case of progressive disease, according to the treating physician's choice and patient consent. Best clinical response during MI therapy was evaluated regardless of MI therapy treatment duration.

The local clinical response was assessed at baseline, 6, 12 and 16 weeks and from then on every 4 weeks in case of prolonged treatment by physical examination and detailed photography of cutaneous lesions, and assessed according to the RECIST 1.1 criteria<sup>45</sup>: the sum of diameters of max. 5 target lesions relative to baseline in patients with target lesions (>1 cm diameter at baseline), defining 100% decrease as complete response (CR), >30% decrease as partial response (PR), < 30% decrease or <20% increase as stable disease (SD) and >20% increase as progressive disease (PD). Patients with non-target lesions (<1 cm diameter at baseline) were assessed by the number of lesions relative to baseline, defining total disappearance of all lesions as CR as, any decrease in number as PR, equal number to baseline as SD, and any increase in number as PD. The assessment of SD and PR on non-target lesions is a refinement of the non-CR/non-PD response defined by the RECIST criteria.<sup>45</sup> The baseline assessment was corrected for 2 lesions that were biopsied at baseline and after 6 weeks.

Patients were monitored for adverse events after the first week and further on a biweekly basis using the NCI Common Terminology Criteria for Adverse Events (CTCAE) version 4.0 including skin and subcutaneous tissue disorders, plus analysis of hematology, blood chemistry and S-100B serum values and treatment compliance.

The secondary endpoint was the induction of local and systemic antimelanoma immunity by MI therapy. A 6-mm biopsy of a cutaneous lesion, a 4-mm biopsy of adjacent, treated skin and 50 ml peripheral blood were taken at baseline and every 6 weeks for immunomonitoring purposes.

### Melanoma-specific antibody analysis

Antibodies in serum samples were detected using radioligand-binding assays (RBA), as described previously.<sup>46</sup> This technique is at least as sensitive as ELISA and more sensitive than Western blotting.<sup>47</sup> Briefly, plasmids pcDNA3-TH, pcDNA3-TYR, pcDNA3-PMEL17, pcDNA3-MCHR1 and pcDNA3-Melan-A (MART-1) were used according to the manufacturer in an in vitro TnTT7-coupled Reticulocyte Lysate System (Promega, Southampton, UK) with [<sup>35</sup>S]-methionine to produce radiolabeled full-length proteins TH, tyrosinase, gp100, MCHR1 and MART-1, respectively.<sup>46</sup> Radiolabeled antigens were then used in RBAs with patient and healthy control (n = 20) sera at a 1:100 dilution, as described previously.<sup>46</sup> An antigen-specific animal antibody was included in each RBA as a positive control. In each RBA, an antibody index for each serum was calculated as the counts per minute immunoprecipitated by tested serum divided by the mean counts per minute immunoprecipitated by 20 healthy control sera. In each experiment, the upper limit of normal was calculated as mean antibody index of controls plus 3 times the standard deviation (SD) and used as a threshold value for positivity. Increases in antibody indexes during therapy were analyzed statistically using the nonparametric Wilcoxon signed rank test of paired data (IBM SPSS Statistics version 22).

### Isolation and culture of peripheral blood mononuclear cells (PBMC), tumor-infiltrating lymphocytes (TIL) and skin-infiltrating lymphocytes (SIL)

We acknowledge the concept of the minimal information about T-cell assays (MIATA) reporting framework for human T-cell assays.<sup>48</sup> Peripheral blood was collected in Vacutainer blood collection tubes containing heparin (Greiner Bio-One, Alphen aan de Rijn, the Netherlands). PBMC were isolated by Ficoll gradient centrifugation (Lymphoprep, Fresenius Kabi, Zeist, the Netherlands), as described previously.<sup>49</sup> Tumor-infiltrating lymphocytes (TIL) and skin-infiltrating lymphocytes (SIL) were obtained, as described previously.<sup>50</sup> Biopsies of 6 mm or 4 mm diameter were taken from melanoma lesions or adjacent skin, respectively, transported to the AMC on ice in sterile tubes containing Phosphate Buffered Saline (Fresenius Kabi) and processed within 6 hours. Biopsies were cultured in a humidified atmosphere at 37 °C and 5% CO<sub>2</sub> in 24-wells plates with 1 ml/well Iscoves modified Dulbecco's Medium (IMDM), supplemented with 10% heat-inactivated human serum type AB (Lonza, Basel, Switzerland), 40 U/ml IL-2 (Proleukin, Novartis Pharma, Arnhem, The Netherlands), 5 ng/ml IL-15 (PeproTech EC, London, UK), 15  $\mu$ g/ml gentamycin (Duchefa, Haarlem, the Netherlands), 2 mM L-glutamine, 50 U/ml penicillin and 50  $\mu$ g/ml streptomycin (Gibco Life Technologies, Thermo Fisher Scientific, Landsmeer, The Netherlands). In addition, 1.25  $\mu$ l/ml anti-CD3/CD28 monoclonal antibody-

coated T-cell expander beads (Dynabeads, Life Technologies, Thermo Fisher Scientific, Landsmeer, the Netherlands) were added at day 0 to promote T-cell outgrowth and expansion. PBMC were cultured similarly during approximately 3 weeks to obtain cultured peripheral blood lymphocytes (PBL), keeping equal culture conditions and time periods for PBL, TIL and SIL of each patient until analysis.

### HLA typing

HLA typing of patients was performed on PBL, cultured from peripheral blood without cryopreservation, by flow cytometry using fluorescein isothiocyanate (FITC)-conjugated mouse anti-human HLA-A2-specific monoclonal antibody (mAb) (BD Biosciences, Breda, the Netherlands) and biotinylated HLA-A1/A36-specific antibody (BIH0331), biotinylated HLA-A2-specific antibody (BIH0648) or biotinylated HLA-A3-specific antibody (BIH0269, all from One Lambda Inc., Canoga Park, CA), followed by allophycocyanin (APC) conjugated streptavidin (Biolegend, ITK Diagnostics, Uithoorn, The Netherlands) to detect biotinylated antibody binding. Cells were acquired on a FACS Canto II (Beckton Dickinson, Breda, the Netherlands), and analyzed by FlowJo Software (Treestar, Ashland, OR).

### Detection of melanocyte-specific T-cells in peripheral blood lymphocytes and melanoma tissues

The protocol of the Laboratory of Experimental Dermatology at the AMC for HLA-peptide tetramer analysis of human T-cell responses was harmonized in 2013 with the maximum overall proficiency score by participating in the Immudex MHC Multi-mer Proficiency panel initiated by the Association of Cancer Immunotherapy Europe (CIMT)<sup>51</sup> and the Cancer Immunotherapy Consortium (CIC). HLA-A1-, HLA-A2- and HLA-A3/peptide tetramers containing peptides of the melanocyte differentiation antigens tyrosinase, gp100, MART-1 were used to detect antigen specificity of T-cells isolated from treated areas of the tumor (TIL), and adjacent skin (SIL), or peripheral blood (PBMC and cultured PBL), as previously described.<sup>50</sup> Briefly, R-phycoerythrin (PE)- or APC-conjugated HLA-A1, HLA-A2- and HLA-A3/peptide complex tetramers were synthesized for the antigens **HLA-A1:** tyrosinase<sub>145–156</sub>, tyrosinase<sub>243–251</sub>; **HLA-A2:** tyrosinase<sub>369–377</sub>, gp100<sub>280–288</sub>, gp100<sub>209–217</sub>, MART-1<sub>26–35</sub> (modified position 27 (A>L)) and **HLA-A3:** gp100<sub>17–25</sub>, gp100<sub>87–95</sub>, gp100<sub>614–622</sub>, tyrosinase<sub>25–33</sub>, tyrosinase<sub>425–434</sub> and MART-1<sub>42–50</sub> HLA/peptide. T-cells cultured from peripheral blood or biopsies were used for analyses without cryopreservation. HLA-peptide tetramer analyses of cultured T cells were performed at least 14 days after the CD3/28 antibody stimulation. PBMC were cryopreserved in culture medium containing 50% Fetal Calf Serum (FCS) and 10% DMSO in vapor-phase liquid nitrogen storage for approximately 3 weeks until analysis. Viability of thawed PBMC for analysis was 50–80%. Approximately  $0.5 \times 10^6$  cells were used per staining. T-cells were incubated with HLA-A1, -A2, or -A3/peptide tetramers in PBS, 1% Bovine Serum Albumin (BSA), and 0.5% sodium azide (this standard FACS buffer was previously tested for optimal assay performance) for 20 minutes at room temperature.

Subsequently, cells were counterstained with FITC-conjugated mouse anti-human CD8 mAb and APC-conjugated mouse anti-humans CD3 mAb (both from Biolegend, ITK Diagnostics, Uithoorn, the Netherlands). Antibody and tetramer binding to T-cells was analyzed by flow cytometry (FACS Canto II, Beckton Dickinson). The combination of fluorochromes for multicolor flow cytometry was chosen based on optimal performance on the FACS Canto II in previous tests.<sup>50</sup> Data were analyzed using Flow Jo software (Treestar, Ashland, OR), by life gating of the lymphocyte population on FSC-A/SSC scatter plots, exclusion of cell doublets on FSC-H/SSC scatter plots, compensation of fluorescent signal overflow and gating of CD3+ cells. The percentages of CD3+CD8+ Tm+ cells of total CD8+ T-cells were calculated from CD8 versus tetramer-binding dot plots of CD3+ gated populations. At least 300,000 cells were acquired in total for each sample. The range of tetramer-binding CD8+ T-cells found varied between 0.01 and 4.78%, of which percentages above 0.1% of total CD8+ T-cells were considered as a positive percentage. This threshold was predefined, based on earlier analyses.<sup>50</sup> The induction of an immune response was defined per tetramer as a positive percentage of tetramer-binding T-cells with an increase of at least 0.1% above the percentage of tetramer-binding CD8+ T-cells at baseline. The number of antigen-specific T-cell responses was analyzed per patient. Changes in percentage of antigen-specific T-cell responses per tissue (PBMC, PBL, TIL, SIL) from baseline to the primary endpoint (12 weeks) or maximal T-cell response during MI therapy were analyzed statistically in all patients or in subgroups of responding or nonresponding patients, using the nonparametric Wilcoxon signed rank test of paired data (IBM SPSS Statistics version 22).

### Conflict of interest

R. Luiten, J.W. Drijfhout and C. Melief are inventors on patents filed by the AMC, LUMC or ISA Pharmaceuticals, Leiden, the Netherlands. C. Melief is employed as CSO and owns stock at ISA Pharmaceuticals. C. Melief has been consulted as expert by the companies Immatics GmbH, Germany and Merck. H.E. Teulings has received a honorarium from BMS for an educational presentation. All other authors have no potential conflict of interest to declare.

### Acknowledgments

We thank H. van Tinteren, V. van der Noort, L. Pronk, L. Wever, A. Hiemstra and S. Cooke for the datamanagement, M. Lomecky and A. Jagt for the medical photography and M.W.J.M. Wouters, J.B.A.G. Haanen, C. Blank and A.J.M. van den Eertwegh for patient referral.

### Funding

H.E. Teulings was supported by a grant UVA2009–4378 from the Dutch Cancer Society. Trial data management was supported by grant UVA2011–5143 from the Dutch Cancer Society. The trial costs and E.P.M. Tjin were supported by a Pre-seed loan from the AMC (grant SKE Pre-seed 2010).

### ORCID

Germaine N. Relyveld  <http://orcid.org/0000-0002-8397-2037>

## References

- Quaglino P, Marenco F, Osella-Abate S, Cappello N, Ortoncelli M, Salomone B, Fierro MT, Savoia P, Bernengo MG. Vitiligo is an independent favourable prognostic factor in stage III and IV metastatic melanoma patients: results from a single-institution hospital-based observational cohort study. *Ann Oncol.* 2010;21:409–14. doi:10.1093/annonc/mdp325
- Teulings HE, Limpens J, Jansen SN, Zwinderman AH, Reitsma JB, Spuls PI, Luiten RM. Vitiligo-like depigmentation in stage III-IV melanoma patients receiving immunotherapy and its association with survival: a systematic review and meta-analysis. *J Clin Oncol.* 2015;33(7):773–81. doi:10.1200/JCO.2014.57.4756
- Teulings HE, Tjin EP, Willemsen KJ, Krebbers G, van Noesel CJ, Kemp EH, Nieuweboer-Krobotova L, van der Veen JP, Luiten RM. Radiation-induced melanoma-associated leucoderma, systemic anti-melanoma immunity and disease-free survival in a patient with advanced-stage melanoma: a case report and immunological analysis. *Br J Dermatol.* 2013;168:733–8. doi:10.1111/bjd.12136
- Teulings HE, Willemsen KJ, Glykofridis I, Krebbers G, Komen L, Kroon MW, Kemp EH, Wolkerstorfer A, van der Veen JP, Luiten RM. The antibody response against MART-1 differs in patients with melanoma-associated leucoderma and vitiligo. *Pigment Cell Melanoma Res.* 2014;27:1086–96. doi:10.1111/pcmr.12294
- van den Boorn JG, Konijnenberg D, Tjin EP, Picavet DI, Meeuwenoord NJ, Filippov DV, van der Veen JP, Bos JD, Melief CJ, Luiten RM. Effective melanoma immunotherapy in mice by the skin-depigmenting agent monobenzone and the adjuvants imiquimod and CpG. *PLoS One.* 2010;5:e10626. doi:10.1371/journal.pone.0010626
- Mosher DB, Parrish JA, Fitzpatrick TB. Monobenzyloether of hydroquinone. A retrospective study of treatment of 18 vitiligo patients and a review of the literature. *Br J Dermatol.* 1977;97:669–79. doi:10.1111/j.1365-2133.1977.tb14275.x
- Bleehen SS, Pathak MA, Hori Y, Fitzpatrick TB. Depigmentation of skin with 4-isopropylcatechol, mercaptoamines, and other compounds. *J Invest Dermatol.* 1968;50:103–17. doi:10.1038/jid.1968.13
- van den Boorn JG, Melief CJ, Luiten RM. Monobenzone-induced depigmentation: From enzymatic blockade to autoimmunity. *Pigment Cell Melanoma Res.* 2011;24:673–9. doi:10.1111/j.1755-148X.2011.00878.x
- van den Boorn JG, Picavet DI, Van Swieten PF, van Veen HA, Konijnenberg D, van Veelen PA, van Capel T, Jong EC, Reits EA, Drijfhout JW. Skin-depigmenting agent monobenzone induces potent t-cell autoimmunity toward pigmented cells by tyrosinase haptenation and melanosome autophagy. *J Invest Dermatol.* 2011;131:1240–51. doi:10.1038/jid.2011.16
- Balch CM, Gershenwald JE, Soong SJ, Thompson JF, Atkins MB, Byrd DR, Buzaid AC, Cochran AJ, Coit DG, Ding S. Final version of 2009 AJCC melanoma staging and classification. *J Clin Oncol.* 2009;27:6199–206. doi:10.1200/JCO.2009.23.4799
- Abbott AM, Zager JS. Locoregional therapies in melanoma. *Surg Clin North Am.* 2014;94:1003–15, viii. doi:10.1016/j.suc.2014.07.004
- Campana LG, Valpione S, Mocellin S, Sundararajan R, Granziera E, Sartore L, Chiarion-Sileni V, Rossi CR. Electrochemotherapy for disseminated superficial metastases from malignant melanoma. *Br J Surg.* 2012;99:821–30. doi:10.1002/bjs.8749
- Damian DL, Saw RP, Thompson JF. Topical immunotherapy with diphenylprone for in transit and cutaneously metastatic melanoma. *J Surg Oncol.* 2014;109:308–13. doi:10.1002/jso.23506
- Hersey P, Gallagher S. Intralesional immunotherapy for melanoma. *J Surg Oncol.* 2014;109:320–6. doi:10.1002/jso.23494
- John HE, Mahaffey PJ. Laser ablation and cryotherapy of melanoma metastases. *J Surg Oncol.* 2014;109:296–300. doi:10.1002/jso.23488
- Testori A, Rutkowski P, Marsden J, Bastholt L, Chiarion-Sileni V, Hauschild A, Eggermont AM. Surgery and radiotherapy in the treatment of cutaneous melanoma. *Ann Oncol.* 2009;20 Suppl 6:vi22–9. doi:10.1093/annonc/mdp257
- Olofsson R, Mattsson J, Lindner P. Long-term follow-up of 163 consecutive patients treated with isolated limb perfusion for in-transit metastases of malignant melanoma. *Int J Hyperthermia.* 2013;29:551–7. doi:10.3109/02656736.2013.802374
- Andtbacka RH, Kaufman HL, Collichio F, Amatruda T, Senzer N, Chesney J, Delman KA, Spitler LE, Puzanov I, Agarwala SS. Talimogene Laherparepvec Improves Durable Response Rate in Patients With Advanced Melanoma. *J Clin Oncol.* 2015;33:2780–8. doi:10.1200/JCO.2014.58.3377
- Hoos A. Evolution of end points for cancer immunotherapy trials. *Ann Oncol.* 2012;23 Suppl 8:viii47–52. doi:10.1093/annonc/mds263
- Wolchok JD, Hoos A, O'Day S, Weber JS, Hamid O, Lebbe C, Maio M, Binder M, Bohnsack O, Nichol G. Guidelines for the evaluation of immune therapy activity in solid tumors: immune-related response criteria. *Clin Cancer Res.* 2009;15:7412–20. doi:10.1158/1078-0432.CCR-09-1624
- van Rooij N, van Buuren MM, Philips D, Velds A, Toebes M, Heemskerck B, van Dijk LJ, Behjati S, Hilkmann H, El Atmioui D. Tumor exome analysis reveals neoantigen-specific T-cell reactivity in an ipilimumab-responsive melanoma. *J Clin Oncol.* 2013;31:e439–e42. doi:10.1200/JCO.2012.47.7521
- Dordic M, Matic IZ, Filipovic-Ljeskovic I, Dzodic R, Sasic M, Eric-Nikolic A, Vuletić A, Kolundžija B, Damjanović A, Grozdanić N. Immunity to melanin and to tyrosinase in melanoma patients, and in people with vitiligo. *BMC complementary and alternative medicine.* 2012;12:109. doi:10.1186/1472-6882-12-109
- Fishman P, Merimski O, Baharav E, Shoenfeld Y. Autoantibodies to tyrosinase: The bridge between melanoma and vitiligo. *Cancer.* 1997;79:1461–4. doi:10.1002/(SICI)1097-0142(19970415)79:8%3c1461::AID-CNCR3%3e3.0.CO;2-E
- Merimsky O, Shoenfeld Y, Baharav E, Zigelman R, Fishman P. Reactivity to tyrosinase: expression in cancer (melanoma) and autoimmunity (vitiligo). *Human antibodies and hybridomas.* 1996;7:151–6.
- van den Boorn JG, Picavet DI, van Swieten PF, van Veen HA, Konijnenberg D, van Veelen PA, van Capel T, Jong EC, Reits EA, Drijfhout JW. Skin-depigmenting agent monobenzone induces potent T-cell autoimmunity toward pigmented cells by tyrosinase haptenation and melanosome autophagy. *J Invest Dermatol.* 2011;131:1240–51. doi:10.1038/jid.2011.16
- van Montfoort N, Mangsbo SM, Camps MG, van Maren WW, Verhaart IE, Waisman A, Drijfhout JW, Melief CJ, Verbeek JS, Ossendorp F. Circulating specific antibodies enhance systemic cross-priming by delivery of complexed antigen to dendritic cells in vivo. *Eur J Immunol.* 2012;42:598–606. doi:10.1002/eji.201141613
- Wolf IH, Kodama K, Cerroni L, Kerl H. Nature of inflammatory infiltrate in superficial cutaneous malignancies during topical imiquimod treatment. *The American Journal of dermatopathology.* 2007;29:237–41. doi:10.1097/01.dad.0000211531.33670.94
- Tyring SK, Arany I, Stanley MA, Tomai MA, Miller RL, Smith MH, et al. A randomized, controlled, molecular study of condylomata acuminata clearance during treatment with imiquimod. *The Journal of infectious diseases.* 1998;178:551–5. doi:10.1086/517472
- Narayan R, Nguyen H, Bentow JJ, Moy L, Lee DK, Greger S, Haskell J, Vanchinathan V, Chang PL, Tsui S. Immunomodulation by imiquimod in patients with high-risk primary melanoma. *J Invest Dermatol.* 2012;132:163–9. doi:10.1038/jid.2011.247
- Sisti A, Sisti G, Oranges CM. Topical treatment of melanoma skin metastases with imiquimod: A review. *Dermatol Online J.* 2014 Dec 12;21(2). pii: 13030/qt8rj4k7r6
- Zeitouni NC, Dawson K, Cheney RT. Treatment of cutaneous metastatic melanoma with imiquimod 5% cream and the pulsed-dye laser. *Br J Dermatol.* 2005;152:376–7. doi:10.1111/j.1365-2133.2005.06307.x
- Adams S, O'Neill DW, Nonaka D, Hardin E, Chiriboga L, Siu K, et al. Immunization of malignant melanoma patients with full-length NY-ESO-1 protein using TLR7 agonist imiquimod as vaccine adjuvant. *J Immunol.* 2008;181:776–84. doi:10.4049/jimmunol.181.1.776
- Green DS, Bodman-Smith MD, Dalgleish AG, Fischer MD. Phase I/II study of topical imiquimod and intralesional interleukin-2 in the treatment of accessible metastases in malignant melanoma. *Br J Dermatol.* 2007;156:337–45. doi:10.1111/j.1365-2133.2006.07664.x



34. Shackleton M, Davis ID, Hopkins W, Jackson H, Dimopoulos N, Tai T, et al. The impact of imiquimod, a Toll-like receptor-7 ligand (TLR7 L), on the immunogenicity of melanoma peptide vaccination with adjuvant Flt3 ligand. *Cancer Immunol Immunother.* 2004;4:9.
35. Elfatoiki FZ, Longvert C, Clerici T, Bourgault-Villada I, Roudier-Pujol C, Vasseur E, Saiag P. [In-transit metastasis in melanoma: Efficacy of topical imiquimod combined with carbon dioxide laser or with electrocautery]. *Ann Dermatol Venereol.* 2014;141:106–10. doi:10.1016/j.annder.2013.10.058
36. Kidner TB, Morton DL, Lee DJ, Hoban M, Foshag LJ, Turner RR, Faries MB. Combined intralesional Bacille Calmette-Guerin (BCG) and topical imiquimod for in-transit melanoma. *J Immunother* 2012;35:716–20. doi:10.1097/CJI.0b013e31827457bd
37. Shi VY, Tran K, Patel F, Leventhal J, Konia T, Fung MA, Wilken R, Garcia MS, Fitzmaurice SD, Joo J. 100% Complete response rate in patients with cutaneous metastatic melanoma treated with intralesional interleukin (IL)-2, imiquimod, and topical retinoid combination therapy: Results of a case series. *J Am Acad Dermatol.* 2015;73:645–54. doi:10.1016/j.jaad.2015.06.060
38. Utikal J, Zimpfer A, Thoenke A, Figl R, Hildenbrand R, Kettelhack C, Goerdt S, Schadendorf D, Ugurel S. Complete remission of multiple satellite and in-transit melanoma metastases after sequential treatment with isolated limb perfusion and topical imiquimod. *Br J Dermatol.* 2006;155:488–91. doi:10.1111/j.1365-2133.2006.07333.x
39. Florin V, Desmedt E, Vercambre-Darras S, Mortier L. Topical treatment of cutaneous metastases of malignant melanoma using combined imiquimod and 5-fluorouracil. *Invest New Drugs.* 2012;30:1641–5. doi:10.1007/s10637-011-9717-2
40. Arbiser JL, Bips M, Seidler A, Bonner MY, Kovach C. Combination therapy of imiquimod and gentian violet for cutaneous melanoma metastases. *J Am Acad Dermatol.* 2012;67:e81–3. doi:10.1016/j.jaad.2011.10.028
41. Rivas-Tolosa N, Ortiz-Brugues A, Toledo-Pastrana T, Baradad M, Traves V, Soriano V, Sanmartín V, Requena C, Martí R, Nagore E. Local cryosurgery and imiquimod: A successful combination for the treatment of locoregional cutaneous metastasis of melanoma: A case series. *J Dermatol.* 2016;43:553–6. doi:10.1111/1346-8138.13197
42. Mauldin IS, Wages NA, Stowman AM, Wang E, Olson WC, Deacon DH, Smith KT, Galeassi N, Teague JE, Smolkin ME. Topical treatment of melanoma metastases with imiquimod, plus administration of a cancer vaccine, promotes immune signatures in the metastases. *Cancer Immunol Immunother.* 2016;65:1201–12. doi:10.1007/s00262-016-1880-z
43. Joseph RW, Cappel M, Tzou K, Bagaria S, Gilstrap C, Swaika A, Jambusaria-Pahlajani A. Treatment of in-transit and metastatic melanoma in two patients treated with ipilimumab and topical imiquimod. *Melanoma Res.* 2016;26:409–12. doi:10.1097/CMR.0000000000000247
44. A'Hern RP. Sample size tables for exact single-stage phase II designs. *Stat Med.* 2001;20:859–66. doi:10.1002/sim.721
45. Eisenhauer EA, Therasse P, Bogaerts J, Schwartz LH, Sargent D, Ford R, Dancey J, Arbuck S, Gwyther S, Mooney M. New response evaluation criteria in solid tumours: revised RECIST guideline (version 1.1). *Eur J Cancer.* 2009;45:228–47. doi:10.1016/j.ejca.2008.10.026
46. Kemp EH, Waterman EA, Hawes BE, O'Neill K, Gottumukkala RV, Gawkrödger DJ, et al. The melanin-concentrating hormone receptor 1, a novel target of autoantibody responses in vitiligo. *J Clin Invest.* 2002;109:923–30. doi:10.1172/JCI0214643
47. Levy-Marchal C, Bridel MP, Sodoyez-Goffaux F, Koch M, Tichet J, Zernichow P, et al. Superiority of radiobinding assay over ELISA for detection of IAAs in newly diagnosed type I diabetic children. *Diabetes care.* 1991;14:61–3. doi:10.2337/diacare.14.1.61
48. Britten CM, Janetzki S, Butterfield LH, Ferrari G, Gouttefangeas C, Huber C, et al. T cell assays and MIATA: The essential minimum for maximum impact. *Immunity.* 2012;37:1–2. doi:10.1016/j.immuni.2012.07.010
49. van den Boorn JG, Konijnenberg D, Dellemijn TA, van der Veen JP, Bos JD, Melief CJ, Vyth-Dreese FA, Luiten RM. Autoimmune destruction of skin melanocytes by perilesional T cells from vitiligo patients. *J Invest Dermatol.* 2009;129:2220–32. doi:10.1038/jid.2009.32
50. Tjin EP, Konijnenberg D, Krebbers G, Mallo H, Drijfhout JW, Franken KL, van der Horst CM, Bos JD, Nieweg OE, Kroon BB. T-cell immune function in tumor, skin, and peripheral blood of advanced stage melanoma patients: implications for immunotherapy. *Clinical Cancer Research: An Official Journal of the American Association for Cancer Research.* 2011;17:5736–47. doi:10.1158/1078-0432.CCR-11-0230
51. Britten CM, Gouttefangeas C, Welters MJ, Pawelec G, Koch S, Ottensmeier C, Mander A, Walter S, Paschen A, Müller-Berghaus J. The CIMT-monitoring panel: A two-step approach to harmonize the enumeration of antigen-specific CD8+ T lymphocytes by structural and functional assays. *Cancer Immunol Immunother.* 2008;57:289–302. doi:10.1007/s00262-007-0378-0