

This is a repository copy of *What is the Most Effective Treatment for Frozen Shoulder?*.

White Rose Research Online URL for this paper:

<https://eprints.whiterose.ac.uk/106942/>

Version: Published Version

---

**Article:**

Rangan, Amar, Hanchard, Nigel and McDaid, Catriona Maria orcid.org/0000-0002-3751-7260 (2016) What is the Most Effective Treatment for Frozen Shoulder? *BMJ Open*. i4162. pp. 1-7. ISSN 2044-6055

<https://doi.org/10.1136/bmj.i4162>

---

**Reuse**

This article is distributed under the terms of the Creative Commons Attribution (CC BY) licence. This licence allows you to distribute, remix, tweak, and build upon the work, even commercially, as long as you credit the authors for the original work. More information and the full terms of the licence here:

<https://creativecommons.org/licenses/>

**Takedown**

If you consider content in White Rose Research Online to be in breach of UK law, please notify us by emailing [eprints@whiterose.ac.uk](mailto:eprints@whiterose.ac.uk) including the URL of the record and the reason for the withdrawal request.

## PRACTICE



## UNCERTAINTIES

# What is the most effective treatment for frozen shoulder?

Amar Rangan *professor of orthopaedic surgery*<sup>1 2 3</sup>, Nigel Hanchard *reader in orthopaedics*<sup>4</sup>, Catriona McDaid *senior research fellow*<sup>3</sup>

<sup>1</sup>The James Cook University Hospital, Middlesbrough TS4 3BW, UK; <sup>2</sup>Nuffield Department of Orthopaedics, Rheumatology and Musculoskeletal Sciences, University of Oxford, Oxford OX3 7HE, UK; <sup>3</sup>York Trials Unit, Department of Health Sciences, University of York, York YO10 5DD, UK; <sup>4</sup>School of Health and Social Care, Teesside University, Middlesbrough TS1 3BX, UK

Frozen shoulder is a painful condition that most commonly affects people in their 50s,<sup>1 2</sup> and may limit daily activities and disturb sleep.<sup>3</sup> Its annual prevalence has been estimated as 1.4 per 1000 patients in a UK study of two general practices (total population 17 000).<sup>4</sup>

The diagnosis is clinical (see box 1). Restriction or pain, or both, on shoulder elevation and external rotation have been consistently described in the literature,<sup>6-12</sup> yet there are insufficient data to evaluate diagnostic accuracy of signs and symptoms.<sup>6</sup> Restriction and pain are evident on passive as well as active testing, which differentiates it from rotator cuff disease (where passive movements are classically of full range).<sup>6</sup> Another differentiator is crepitus in the shoulder, which is more indicative of arthritis.<sup>12</sup> Three phases (pain, stiffness, and resolution) are described, but they often overlap. Patients may have “pain-predominant” or “stiffness-predominant” frozen shoulder.<sup>13</sup>

Although frozen shoulder is considered self limiting, long term longitudinal follow-up data are scarce. The largest longitudinal series to date (223 patients) showed that 41% of patients had persistent symptoms at a mean follow up of 4.4 years, but this was based in secondary care, where more severe and less tractable cases are likely to be seen.<sup>14</sup> The same study found recurrence rare, but the other shoulder was affected in 6-17% of patients within five years.<sup>14</sup> Reported associations include diabetes, cardiovascular disease, trauma, stroke, neurosurgery, and thyroid disease.<sup>5</sup>

Less invasive treatments are generally tried first, but earlier use of more invasive interventions, particularly surgical capsular

release, is increasing (box 2).<sup>18</sup> There is uncertainty as to when these should be offered, and their clinical and cost effectiveness.

## What is the evidence of uncertainty?

There are large gaps in evidence for effectiveness of treatments for frozen shoulder. The systematic review we analysed (see box 3) included 28 randomised controlled trials, one quasi-experimental study, and two case series.<sup>15</sup> There were insufficient studies with a similar intervention and comparator to quantify effectiveness. Most studies are at a high risk of bias; do not report adequate methods for randomisation, allocation concealment, and outcome assessment; and seem to be inadequately powered. Few studies report a consistent method for collection of data on harms.<sup>15</sup>

Overall, physiotherapy and intra-articular steroid injections have been shown to have some benefit. Although there is no convincing evidence to support other measures, we emphasise the absence of good evidence rather than evidence that these management options are ineffective (see table 1 [↴](#)).

A systematic review of six randomised controlled trials comparing intra-articular corticosteroid injection with placebo and with manual therapy and exercise shows short term benefit with improvement in pain, function, and range of movement (up to 6-7 weeks) compared with placebo<sup>15</sup> and possibly compared with manual therapy and exercise.<sup>19</sup> This evidence suggests that a single corticosteroid injection for people with frozen shoulder of up to a year in duration may hasten improvements in pain and function by some weeks. There is moderate evidence for hydrodilatation—distension of the

Correspondence to: A Rangan amar.rangan@york.ac.uk

This is one of a series of occasional articles that highlight areas of practice where management lacks convincing supporting evidence. The series adviser is David Tovey, editor in chief, the *Cochrane Library*. This paper is based on a research priority identified and commissioned by the National Institute for Health Research's Health Technology Assessment programme on an important clinical uncertainty. To suggest a topic for this series, please email us at [uncertainties@bmj.com](mailto:uncertainties@bmj.com).

**What you need to know**

- Consider the diagnosis in patients with pain and limitation of passive external rotation of the shoulder
- There is insufficient evidence to reliably recommend a treatment approach. Moderate evidence supports corticosteroid injection or hydrodilatation; and physiotherapy in reduction of pain and stiffness
- Consider specialist referral if the patient does not respond to conservative treatment or if the diagnosis is in doubt

**Box 1: Diagnostic criteria for frozen shoulder<sup>5-11</sup>**

The diagnosis is clinical:

- Pain arising insidiously in deltoid region with increasing shoulder stiffness
- Pain at the end of external rotation, and restriction of this movement on both active and passive testing
- No obvious crepitus on movement

X rays are not routinely required, but if obtained, should show a normal glenohumeral joint

**Box 2: Treatment options for frozen shoulder**

- Oral analgesia and watchful waiting<sup>15</sup>
- Physiotherapy, typically combinations of advice and education, exercises, manual therapy, thermotherapy, and electrotherapy. Care packages may also include acupuncture or corticosteroid injections<sup>16</sup>
- Acupuncture<sup>15</sup>
- Oral corticosteroid<sup>17</sup>
- Intra-articular corticosteroid injections<sup>15</sup>
- Hydrodilatation (injection of up to 40 mL of sterile saline solution, usually with corticosteroid, to distend the shoulder capsule)<sup>15</sup>
- Manipulation of the shoulder joint under general anaesthesia<sup>15</sup>
- Capsular release (surgical procedure, typically arthroscopic, to release contracted tissue)<sup>15</sup>

**Box 3: Search strategy and study selection**

We have referenced the most up to date systematic review, published in 2012, for individual treatment comparisons.<sup>15</sup> We searched Medline for randomised controlled trials undertaken since then (up to May 2015) using the search strategy from the 2012 review combined with a validated filter for randomised controlled trials. We screened the results for new trials of manipulation under anaesthesia, capsular distension, and capsular release only, as physiotherapy interventions had been studied in Cochrane reviews published in 2014.

shoulder capsule with normal saline and corticosteroid—instead of a corticosteroid injection.<sup>15</sup> Exercise and mobilisation may augment the effect of steroid injection for some outcomes, but there is insufficient evidence to reach a conclusion.

Designing trials and quantifying the efficacy of physiotherapy is fraught with difficulty. It is a complex intervention encompassing a range of physical techniques, advice, education, painkillers, thermal or electrotherapy, and steroid injection that may have varying efficacy and may be delivered in varying intensities.<sup>8,9</sup>

Our updated Medline searches identified:

- A randomised trial of 64 patients comparing fluoroscopy guided anterior distension with ultrasonography guided posterolateral capsular distension<sup>21</sup>
- A randomised trial of 48 patients comparing ultrasonography guided and fluoroscopy guided capsular distension<sup>22</sup>
- A four-armed study with 53 participants investigating intensive mobilisation techniques combined with capsular distension.<sup>23</sup>

All the studies had a high risk of bias and seem to be inadequately powered.

**Is ongoing research likely to provide relevant evidence?**

We searched <http://clinicaltrials.gov> and the WHO International Clinical Trials Registry Platform and identified six ongoing

randomised trials (table 2⇓). These trials are likely to provide evidence on four commonly used current interventions—that is, intra-articular injection with physiotherapy, hydrodilatation, manipulation under anaesthesia, and capsular release.

**What should we do in light of the uncertainty?**

Communicate to patients that frozen shoulder is a benign and usually self limiting condition. Simple advice on activity modification and pain control may suffice (see box 4). Listen to the patient, and be prepared to adapt treatment, for example by referring on if their symptoms are not resolved or if the diagnosis is in doubt.

Consider referral for physiotherapy. Based on a survey of 289 UK physiotherapists,<sup>16</sup> physiotherapy care for frozen shoulder includes advice and education, which patients consider crucial.<sup>30</sup> In the pain-predominant stage, it is also likely to include an intra-articular steroid injection, a technique practised by many physiotherapists, and for which there is moderate evidence of effectiveness.

Current trends in practice involve escalation to more invasive treatments including manipulation under anaesthesia or arthroscopic capsular release, but there is insufficient evidence to recommend these. Although not clearly established, frozen shoulder may be associated with diabetes, and diabetic patients may be more resistant to treatment.<sup>22</sup>

**Box 4: What patients need to know***What should you expect?*

- At first, pain is the main problem. It can spread down the arm and is often worse in bed, especially if lying on the affected side, disturbing sleep.
- The pain slowly eases, but stiffness increases, becoming the main problem, before gradually resolving.
- The whole process may last from a few months to two to three years, but the pain does not last for the whole time.

*How can you help yourself?*

- When in pain, the emphasis is on pain relief and gentle use of your arm to ease spasm and maintain movement.
- Using your arm will not do any harm, but avoid aggravating your pain by doing too much. Take pain medication as advised. You may find hot packs helpful.
- In bed, support the arm with pillows as a reminder not to roll onto it.
- As time passes you will feel less need for pain relief.

*What are the common treatments?*

- Treatments other than pain medication are not always needed; but steroid injections are often used to reduce inflammation and pain in the shoulder, and physiotherapy may help to diminish pain and restore movement.
- A minority of people are referred to hospital with frozen shoulder, where additional options include release of the tight tissues by an injection or by keyhole surgery.
- It remains unclear which options are most effective. You should discuss treatment options with your clinician, based on your needs and preferences.

To address these uncertainties, it would be appropriate to encourage suitable patients to participate in trials designed to answer questions on which treatments are most effective (box 5).

We thank Helen Collin and Stanley West, our patient contributors to this article; and Lorna Goodchild, physiotherapist, for organising this aspect.

Contributors: The idea for this article was formulated by AR in discussion with M Chew (associate editor, BMJ). AR, NH, and CM contributed to different sections of the article in preparation of the first draft. All authors approved the final version, and AR is the guarantor.

Competing interests: We have read and understood the BMJ policy on declaration of interests and declare the following interests: AR has received travelling expenses to attend meetings, consultancy fees, and educational grants from DePuy; and licence fees from JRI towards a pending UK and European patent on a shoulder prosthesis. AR is chief investigator, and NH and CM are co-investigators, for UKFROST. NH and CM do not have any other competing interests to declare.

Patient consent obtained.

- van der Windt DA, Koes BW, de Jong BA, Bouter LM. Shoulder disorders in general practice: incidence, patient characteristics, and management. *Ann Rheum Dis* 1995;54:959-64. doi:10.1136/ard.54.12.959 pmid:8546527.
- Walker-Bone K, Palmer KT, Reading I, Coggon D, Cooper C. Prevalence and impact of musculoskeletal disorders of the upper limb in the general population. *Arthritis Rheum* 2004;51:642-51. doi:10.1002/art.20535 pmid:15334439.
- Dawson J, Shepperd S, Carr A. An overview of factors relevant to undertaking research and reviews on the effectiveness of treatment for frozen shoulder. *Shoulder Elbow* 2010;2:232-7doi:10.1111/j.1758-5740.2010.00067.x.
- Ostör AJ, Richards CA, Prevost AT, Speed CA, Hazleman BL. Diagnosis and relation to general health of shoulder disorders presenting to primary care. *Rheumatology (Oxford)* 2005;44:800-5. doi:10.1093/rheumatology/keh598 pmid:15769790.
- Boyle-Walker KL, Gabard DL, Bietsch E, Masek-VanArsdale DM, Robinson BL. A profile of patients with adhesive capsulitis. *J Hand Ther* 1997;10:222-8. doi:10.1016/S0894-1130(97)80025-7 pmid:9268913.
- Walmsley S, Osmotherly PG, Rivett DA. Movement and pain patterns in early stage primary/idiopathic adhesive capsulitis: a factor analysis. *Physiotherapy* 2014;100:336-43. doi:10.1016/j.physio.2014.02.001 pmid:24680792.
- Codman E. *Rupture of the supraspinatus tendon and other lesions in or about the subacromial bursa*. Boston, 1934.
- Rundquist PJ, Anderson DD, Guanche CA, Ludewig PM. Shoulder kinematics in subjects with frozen shoulder. *Arch Phys Med Rehabil* 2003;84:1473-9. doi:10.1016/S0003-9993(03)00359-9 pmid:14586914.
- Rundquist PJ, Ludewig PM. Patterns of motion loss in subjects with idiopathic loss of shoulder range of motion. *Clin Biomech (Bristol, Avon)* 2004;19:810-8. doi:10.1016/j.clinbiomech.2004.05.006 pmid:15342153.
- Wolf EM, Cox WK. The external rotation test in the diagnosis of adhesive capsulitis. *Orthopedics* 2010;33. doi:10.3928/01477447-20100329-11. pmid:20506951.
- Noboa E, López-Graña G, Barco R, Antuña S. Distension test in passive external rotation: Validation of a new clinical test for the early diagnosis of shoulder adhesive capsulitis.

- Rev Esp Cir Ortop Traumatol* 2015;59:354-9. doi:10.1016/j.recote.2015.07.001 pmid:25544715.
- Wolf EM, Cox WK. The external rotation test in the diagnosis of adhesive capsulitis. *Orthopedics* 2010;33. doi:10.3928/01477447-20100329-11. pmid:20506951.
- Hanchard NC, Goodchild L, Thompson J, O'Brien T, Davison D, Richardson C. Evidence-based clinical guidelines for the diagnosis, assessment and physiotherapy management of contracted (frozen) shoulder: quick reference summary. *Physiotherapy* 2012;98:117-20. doi:10.1016/j.physio.2012.01.001 pmid:22507361.
- Hand C, Cliphsham K, Rees JL, Carr AJ. Long-term outcome of frozen shoulder. *J Shoulder Elbow Surg* 2008;17:231-6. doi:10.1016/j.jse.2007.05.009 pmid:17993282.
- Maund E, Craig D, Suekarran S, et al. Management of frozen shoulder: a systematic review and cost-effectiveness analysis. *Health Technol Assess* 2012;16:1-264. doi:10.3310/hta16110. pmid:22405512.
- Hanchard NC, Goodchild L, Thompson J, O'Brien T, Davison D, Richardson C. A questionnaire survey of UK physiotherapists on the diagnosis and management of contracted (frozen) shoulder. *Physiotherapy* 2011;97:115-25. doi:10.1016/j.physio.2010.08.012 pmid:21497245.
- Buchbinder R, Green S, Youd JM, Johnston RV. Oral steroids for adhesive capsulitis. *Cochrane Database Syst Rev* 2006;4:CD006189. pmid:17054278.
- Uppal HS, Evans JP, Smith C. Frozen shoulder: A systematic review of therapeutic options. *World J Orthop* 2015;6:263-8. doi:10.5312/wjo.v6.i2.263 pmid:25793166.
- Page MJ, Green S, Kramer S, et al. Manual therapy and exercise for adhesive capsulitis (frozen shoulder). *Cochrane Database Syst Rev* 2014;8:CD011275. pmid:25157702.
- Page MJ, Green S, Kramer S, Johnston RV, McBain B, Buchbinder R. Electrotherapy modalities for adhesive capsulitis (frozen shoulder). *Cochrane Database Syst Rev* 2014;10:CD011324. pmid:25271097.
- Bae JH, Park YS, Chang HJ, et al. Randomized controlled trial for efficacy of capsular distension for adhesive capsulitis: fluoroscopy-guided anterior versus ultrasonography-guided posterolateral approach. *Ann Rehabil Med* 2014;38:360-8. doi:10.5535/arm.2014.38.3.360. pmid:25024960.
- Park KD, Nam HS, Kim TK, Kang SH, Lim MH, Park Y. Comparison of Sono-guided Capsular Distension with Fluoroscopically Guided Capsular Distension in Adhesive Capsulitis of Shoulder. *Ann Rehabil Med* 2012;36:88-97. doi:10.5535/arm.2012.36.1.88. pmid:22506240.
- Park SW, Lee HS, Kim JH. The effectiveness of intensive mobilization techniques combined with capsular distension for adhesive capsulitis of the shoulder. *J Phys Ther Sci* 2014;26:1767-70. doi:10.1589/jpts.26.1767. pmid:25435696.
- Multi-centre randomised controlled trial with economic evaluation and nested qualitative study comparing early structured physiotherapy versus manipulation under anaesthesia versus arthroscopic capsular release for patients referred to secondary care with a primary frozen shoulder (adhesive capsulitis). <http://www.isrctn.com/ISRCTN48804508>.
- Scientifically merged acupuncture and robot-assisted technology (SMART) for rehabilitation of frozen shoulder syndrome: First year project verification of acupuncture and evaluation by magnetic resonance imaging examination. <https://clinicaltrials.gov/ct2/show/NCT02076308>.
- A prospective randomized 3-arm trial comparing intra-articular corticosteroid injection versus arthrographic distension versus arthrographic distension plus intra-articular corticosteroid injection in the treatment of adhesive capsulitis. <https://clinicaltrials.gov/ct2/show/NCT01983527>.
- Treatment of adhesive capsulitis: a randomized placebo-controlled trial comparing arthrographic joint distension with steroid and local anaesthetic versus arthrographic joint distension with local anaesthetic alone. <https://clinicaltrials.gov/ct2/show/NCT02001740>.
- Manipulation under anaesthesia versus arthroscopic capsular release in the treatment of adhesive capsulitis. <https://clinicaltrials.gov/ct2/show/NCT01961219>.
- Adhesive capsulitis: prospective analysis of efficacy and financial impact for use of physical therapy in treatment. <https://clinicaltrials.gov/ct2/show/NCT02283996>.
- Jones S, Hanchard N, Hamilton S, Rangan A. A qualitative study of patients' perceptions and priorities when living with primary frozen shoulder. *BMJ Open* 2013;3:e003452. doi:10.1136/bmjopen-2013-003452. pmid:24078753.

Published by the BMJ Publishing Group Limited. For permission to use (where not already granted under a licence) please go to <http://group.bmj.com/group/rights-licensing/permissions>

**Box 5: Recommendations for future research**

Adequately powered randomised controlled trials with:

- Population—Patients with a clinical diagnosis of frozen shoulder
  - Studies should specifically address either the pain-predominant phase or the stiffness-predominant phase of frozen shoulder
  - The pain predominant phase is the priority, because most patients find this the most trying phase
- Interventions and comparisons:
  - Conservative strategies comparing individual and group physiotherapy, home exercises, electrotherapies, and steroid injection in different combinations
  - Invasive strategies including distension, manipulation under anaesthesia, and arthroscopic capsular release
- Outcomes—Resolution of pain, improvement of function and quality of life in the short and long term. Patient experience

**How patients were involved in the creation of this article**

We asked two patients with frozen shoulder to comment on the manuscript and incorporated their suggestions. They firmly endorsed individualised strategies over rigid pathways in management of symptoms. A patient contributor also recommended further research on effectiveness of a structured multidisciplinary approach with early involvement of general practitioner, orthopaedic surgeon or rheumatologist, physiotherapist, and pain management specialist.

## Tables

**Table 1 | Summary of evidence for different treatments of frozen shoulder**

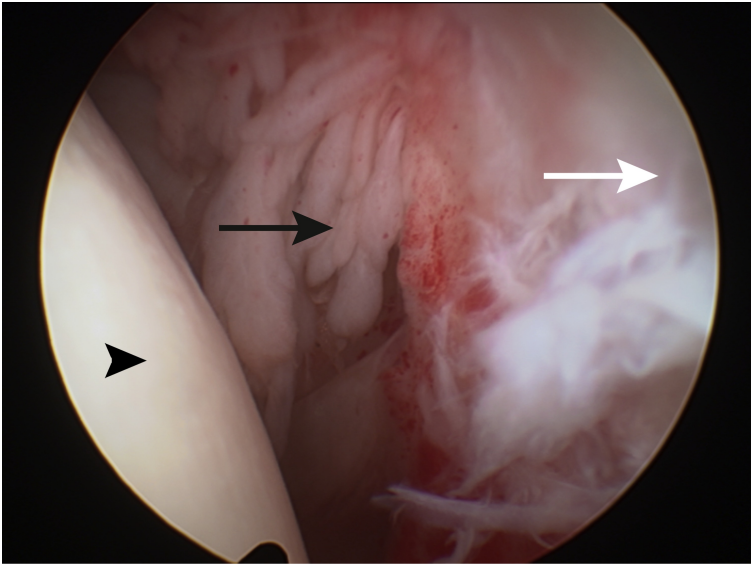
Intervention	Type of evidence	Summary of evidence	Evidence of harms
Watchful waiting, with or without oral analgesia	Systematic review <sup>15</sup> : 1 non-randomised controlled study (n=77)	Insufficient evidence	Insufficient evidence
Physiotherapy (manual therapy and exercises, thermotherapy, and electrotherapy)	Systematic review of manual therapy and exercise <sup>19</sup> : 30 RCTs, 2 quasi-RCTs (n=1836)	Insufficient to compare types of manual therapy or exercise with each other or treatment*	No serious harms but insufficient evidence
	Systematic review of electrotherapy (electrical, sound, light, or thermal energy) <sup>20</sup> : 19 RCTs (n=1249)	Moderate evidence* that 8 weeks' low level laser therapy added to exercise benefits pain, function, and range of movement for mixed-stage frozen shoulder populations	No serious harms but insufficient evidence
Acupuncture	Systematic review <sup>15</sup> : 3 RCTs (n=509)	Insufficient evidence	Insufficient evidence
Oral corticosteroid	Systematic review <sup>17</sup> : 5 RCTs (n=179)	Insufficient evidence to draw firm conclusions, especially compared with other treatments	Minor and short lived in the trials, though the known potential risks need to be considered
Intra-articular corticosteroid injection	Systematic reviews <sup>15-19</sup> : 6 RCTs (n=457)	Moderate evidence* of benefit on pain, function, and disability compared with placebo for mixed-stage frozen shoulder populations, and of enhancement of effects by combination with manual therapy and exercise	None reported, but insufficient evidence to draw conclusions
Hydrodilatation with steroid injection (arthrographic distension)	Systematic review <sup>15</sup> : 3 RCTs (n=144)	Moderate evidence of benefit on one of two function and disability outcomes compared with placebo for mixed-stage frozen shoulder populations. Insufficient evidence to draw firm conclusions compared with other treatments	Minor, including procedure related pain
Manipulation of the shoulder joint under general anaesthesia	Systematic review <sup>15</sup> : 4 RCTs (n=257)	No evidence of benefit though insufficient evidence to draw firm conclusions.	None reported, but insufficient evidence to draw conclusions
Capsular release	Systematic review <sup>15</sup> : 2 case series (n=249)	Insufficient evidence to draw firm conclusions	No serious harms, but insufficient evidence to draw conclusions

RCT=randomised controlled trial. \*GRADE system applied in this review.

Table 2| Ongoing trials of different treatments of frozen shoulder

Name of trial	Population (target sample size)	Intervention and comparison	Primary outcome
UK Frozen Shoulder Trial (UK FroST), <sup>24</sup> UK	Adults ≥18 years old with primary frozen shoulder, including diabetics (n=500)	1. Early structured physiotherapy (12 weeks) 2. Manipulation under anaesthesia without arthroscopic capsular release 3. Manipulation under anaesthesia with arthroscopic capsular release	Oxford Shoulder Score (OSS) at 12 months after randomisation
Acupuncture for treatment of Frozen shoulder Syndrome (SMART), <sup>25</sup> Taiwan	Adults 20-65 years old with frozen shoulder, (n=60)	1. Electroacupuncture and physical therapy 2. Sham electroacupuncture and surgery	Disabilities of the Arm Shoulder and Hand (DASH); Shoulder Pain and Disability Index (SPADI); passive and active range of motion; and musculoskeletal ultrasound at one year
Corticosteroids and/or Arthrographic Distension in the Treatment of Adhesive Capsulitis (CADAC), <sup>26</sup> Belgium	Adults ≥18 years old with pain and stiffness in predominantly one shoulder for ≥4 weeks and restriction in passive range of movement >30° in ≥2 planes of movement, (n=132)	1. Arthrographic distension plus intra-articular corticosteroid 2. Arthrographic distension 3. Intra-articular corticosteroid	SPADI at 4 weeks
Treatment of Adhesive Capsulitis Arthrographic Joint Distension with Local Anaesthetic Alone, <sup>27</sup> Canada	Adults 19-70 years old with frozen shoulder of ≥3 months' duration, (n=108)	1. Arthrographic distension with triamcinalone plus lidocaine 2. Arthrographic distension Lidocaine	SPADI at one year
Manipulation under Anaesthesia versus Capsular Release in the Treatment of Adhesive Capsulitis, <sup>28</sup> USA	Adults ≥18 years old in the frozen or thawing phase of frozen shoulder who have tried and failed three months of non-operative treatment or who demand a quicker return to function and will not try non-operative therapy, (n=50)	1. Manipulation under anaesthesia 2. Arthroscopic capsular release	DASH 12 months post-operation
Adhesive Capsulitis: Prospective Analysis of Efficacy and Financial Impact for Use of Physical Therapy in Treatment, <sup>29</sup> USA	Adults ≥18 years old with frozen shoulder as defined by American Academy of Orthopaedic Surgeons, (n=260)	1. Physiotherapy plus steroid injection 2. Watchful waiting with steroid injection	American Shoulder and Elbow Surgeons Standardized Questionnaire one year after enrolment

## Figure



Arthroscopic view of frozen shoulder, showing the humeral head (black arrowhead), glenoid (white arrow), and rotator interval with inflamed and proliferative tissue (black arrow) and site for injection