



UNIVERSITY OF LEEDS

This is a repository copy of *Superiority of Deformable Image Co-registration in the Integration of Diagnostic Positron Emission Tomography-Computed Tomography to the Radiotherapy Treatment Planning Pathway for Oesophageal Carcinoma*.

White Rose Research Online URL for this paper:  
<http://eprints.whiterose.ac.uk/102179/>

Version: Accepted Version

---

**Article:**

Ward, G, Ramasamy, S, Sykes, JR et al. (11 more authors) (2016) Superiority of Deformable Image Co-registration in the Integration of Diagnostic Positron Emission Tomography-Computed Tomography to the Radiotherapy Treatment Planning Pathway for Oesophageal Carcinoma. *Clinical Oncology*, 28 (10). pp. 655-662. ISSN 0936-6555

<https://doi.org/10.1016/j.clon.2016.05.009>

---

(c) 2016, The Royal College of Radiologists. Published by Elsevier Ltd. This manuscript version is made available under the CC-BY-NC-ND 4.0 license  
<http://creativecommons.org/licenses/by-nc-nd/4.0/>

**Reuse**

Items deposited in White Rose Research Online are protected by copyright, with all rights reserved unless indicated otherwise. They may be downloaded and/or printed for private study, or other acts as permitted by national copyright laws. The publisher or other rights holders may allow further reproduction and re-use of the full text version. This is indicated by the licence information on the White Rose Research Online record for the item.

**Takedown**

If you consider content in White Rose Research Online to be in breach of UK law, please notify us by emailing [eprints@whiterose.ac.uk](mailto:eprints@whiterose.ac.uk) including the URL of the record and the reason for the withdrawal request.



[eprints@whiterose.ac.uk](mailto:eprints@whiterose.ac.uk)  
<https://eprints.whiterose.ac.uk/>

## Introduction

Currently in the UK, oesophageal cancer has a high mortality rate with an estimated 5-year survival rate of 15% [1]. Many patients with locally advanced oesophageal cancer are treated with chemo-radiation. A large percentage of these patients will experience local recurrence within the first two years post-treatment [2,3]. Some studies suggest that persistent disease may be a result of inaccurate GTV delineation [4]. Consequently, accurate detection and delineation of the extent of disease is important. Improving this definition of the gross tumour volume (GTV) remains a challenge in oesophageal cancer [5,6].

The role of fluoride-18 fluorodeoxyglucose (FDG) positron emission tomography - computed tomography (PET-CT) imaging has been explored in recent years, with applications including tumour staging, target delineation and assessment of tumour response to treatment [7,8]. PET-CT can assist in identifying the metabolically active tumour but there remains uncertainty in how this information should be used [9-12]. Some studies suggest PET-CT may enable more accurate tumour delineation, compared to CT alone [6, 9, 13]. There are many difficulties in integrating PET-CT to the treatment planning process; primarily because the staging PET-CT is typically acquired prior to a decision to proceed with non-surgical treatment. Consequently these scans are not acquired in a radiotherapy treatment position. An additional PET-CT scan in the treatment position could be acquired but is resource intensive, onerous for patients and results in an increased radiation dose. Alternatively, the diagnostic PET-CT could be incorporated into the planning pathway using image co-registration, but the accuracy of this co-registration process is essential. Rigid co-registration in a region of interest may be suboptimal due to positional differences between the PET-CT and planning CT (pCT). Deformable image registration (DIR) provides an alternative option which has been used in other tumour sites [14]. It has many applications in radiotherapy treatment planning including calculating accumulative dose over a radiotherapy treatment course and auto-segmentation for target/organ at risk delineation/to account for contour changes in adaptive radiotherapy [15-22].

Analysis of the pattern of local recurrence is critical in evaluating the quality of the radiotherapy treatment. DIR has been used for this purpose in head and neck cancer [23-25]. It represents a promising method to evaluate local recurrence and to determine whether these recurrences are within the original treatment planning volume. DIR can be used to examine the pattern of recurrence relative to the metabolically active PET-CT volume, to determine whether this represents a potential target for dose escalation strategies.

Assessment of the accuracy of image co-registration is essential to allow the incorporation of diagnostic PET-CT in to the radiotherapy planning process and to validate accurate recurrence analysis. This study aims to quantify the accuracy of co-registration of diagnostic PET-CT and relapse imaging to the pCT, using both DIR and rigid registration, and to correlate the site of local recurrence with pre-treatment PET avidity.

## METHODS AND MATERIALS

## Patients

This retrospective study was performed using datasets from consecutive patients treated under the care of a single Radiation Oncologist between February 2009 and August 2010. Eligible patients fulfilled all of the following criteria: i) squamous cell or adenocarcinoma of the oesophagus, ii) treated with concurrent chemo-radiotherapy with curative intent, iii) baseline FDG-PET-CT, iv) availability of all diagnostic imaging, planning CT and, where relevant, relapse imaging. 16 patients were identified, of whom 2 were excluded as all datasets could not be obtained. 6 of the 14 patients included subsequently experienced a local relapse. A summary of the patient characteristics is included in table 1.

**Table 1**

Patient Characteristics

<b>Patient Details (n=14)</b>	
<b>Sex (n)</b>	
Male	7
Female	7
<b>Age (years)</b>	
Average	67
Range	50-83
<b>Histology (n)</b>	
Adenocarcinoma	4
Squamous Cell Carcinoma	10
<b>Clinical Staging (n)</b>	
T2N0M0	4
T2N1M0	1
T3N0M0	3
T3N1M0	5
T4N1M0	1
<b>Location (n)</b>	
Upper	2
Lower	6
Mid	6

Diagnostic PET-CT scans which were acquired an average of 1.4 months prior to the planning CT scan (range of 0.1 - 4.5 months). Relapse CT scans were acquired an average of 11 months after the planning CT (range of 4 - 16.5 months).

## Imaging

As part of routine clinical staging, all patients underwent an FDG PET-CT scan (Discovery ST, GE Medical Systems, Milwaukee, Wisconsin). Patients were scanned on a curved couch-top with arms raised. Images were acquired from skull base to upper thigh, 60 minutes after a 400MBq dose of intravenous fluorine-18 FDG. The CT component of the PET-CT was

performed according to a standardized protocol with the following settings: 140 kV; 80 mAs; tube rotation time 0.5 s per rotation; pitch 6; section thickness 3.75 mm (to match the PET section thickness). Patients maintained normal shallow respiration during the CT acquisition. No iodinated contrast material was administered. No immobilisation equipment was used.

A CT scan for treatment planning was acquired with a 24 or 40 slice, wide-bore scanner equipped with a flat couch-top (Somatom Sensation, Siemens Medical Systems, Erlangen, Germany). Patients were scanned in the supine position immobilised on a wing-board with their arms above their heads. One patient was scanned with their arms down and immobilised in a 5-point thermoplastic mask. Intravenous contrast was administered and 5mm slices were acquired from lung apices to iliac crests.

Recurrence imaging was acquired according to standard diagnostic CT protocols. Patients were scanned on a standard curved couch-top and no immobilisation equipment was used.

### Radiotherapy Treatment Planning

All patients were treated according to the NCRI UK SCOPE1 trial protocol [25] and received a conformal radiotherapy treatment of 50Gy in 25 treatment fractions to the planning target volume (PTV<sub>TP</sub>). The PTV<sub>TP</sub> was derived from a GTV<sub>TP</sub> contoured on the pCT using visual cross-reference with the unregistered FDG PET-CT scan and the endoscopic ultrasound (EUS). The GTV<sub>TP</sub> was extended 2cm superiorly and inferiorly along the length of the oesophagus, and 1cm in all other directions to form a CTV<sub>TP</sub>. Finally the PTV<sub>TP</sub> was derived from the CTV<sub>TP</sub> plus a margin of 1cm superiorly and inferiorly, and 0.5cm in all other directions.

Treatment planning was carried out using the Xio (version 4.4) treatment planning system (Elekta CMS, Stockholm, Sweden) and a 3D conformal treatment technique with 6MV beams including an anterior and posterior field and two lateral fields angled away from the spinal cord. Each plan aimed to cover 95% of the PTV<sub>TP</sub> with 99% of the prescribed dose [26].

### Deformable and Rigid Image Co-registration

All DIR and rigid registrations were performed using Mirada (version 1.4, RTx, Mirada Medical, Oxford, UK). The DIR algorithm was evaluated in previous work [26]. For all 14 patients, the DIR was performed over the whole image. Rigid registrations were carried out by performing an initial manual co-registration followed by a local, automatic rigid registration within a region of interest defined by the GTV<sub>TP</sub> plus a 5cm margin in the superior/inferior and lateral directions and 8cm in the anterior/posterior direction. This region of interest was defined to allow the inclusion of sufficient anatomical landmarks to facilitate co-registration but to minimise the influence of positional differences distant from the GTV<sub>TP</sub>.

### Validation of Registration

#### *Qualitative assessment*

For each patient, the accuracy of the DIR, compared to rigid registration, was qualitatively reviewed by a radiation oncologist and physicist team blinded to method of co-registration. A visual assessment was carried out looking at the coincidence of anatomical landmarks

including oesophagus, trachea and aorta. The local deformation was evaluated by visually examining the deformation grid. Co-registrations were classified as clinically acceptable or unacceptable, and preference for which registration was considered superior was documented.

#### *Quantitative assessment*

A quantitative assessment was performed to evaluate the accuracy of co-registration. It involved comparing outlines of the trachea (from sternal notch to carina), oesophagus (from level of sternal notch to gastro-oesophageal junction) and descending aorta (from level of sternal notch to level of gastro-oesophageal junction) on the PET-CT, pCT and relapse CT.

Initially, intra-observer variability was assessed for contouring of the aorta, trachea and oesophagus. The contouring clinician contoured each structure twice with an interval of 1 week between contours for each structure to minimise the possibility of recall bias on 4 consecutive patients. The clinician was blinded to previous contours for this process. The DICE coefficient was used to compare both structure sets.

Structures sets were transferred from the PET-CT and relapse CT to the pCT, via rigid registration and DIR. Four positional metrics were calculated using ImSimQA software (v3.1.5, OSL, Shrewsbury, UK); conformity index (CI); dice similarity coefficient (DSC); sensitivity index (SI); and inclusion index (InI). The DSC is described as the size of the union of two datasets divided by the average size of the datasets. Values range from 0 to 1 with 0 describing structure with no overlap and 1 describing structures that overlap completely. The CI is defined as the ratio of the overlapping region of two structures to the total area covered by both structures. The InI describes the probability that a voxel of one structure is really a voxel of a reference structure. The SI describes the probability that one structure matches a reference structure and can be referred to as the overlapping index.

$$DSC = \frac{2(V_{ref} \cap V_{eval})}{V_{ref} + V_{eval}} \quad CI = \frac{V_{ref} \cap V_{eval}}{V_{ref} \cup V_{eval}} \quad InI = \frac{V_{ref} \cap V_{eval}}{V_{eval}} \quad SI = \frac{V_{ref} \cap V_{eval}}{V_{ref}}$$

Note that  $V_{ref}$  is the volume/area of a reference structure (in this case, the structure contours on the pCT) and  $V_{eval}$  is the volume/area of the structure to be evaluated (i.e. the structure contoured on the PET-CT and relapse CT).

#### **GTV delineation using PET-CT by side-by-side assessment**

GTV delineations were performed manually taking into account both CT images and the pattern of uptake on the PET images using all diagnostic imaging including results of endoscopic ultrasound (EUS). A GTV was delineated on the pCT using side-by-side visual assessment of the PET-CT.

#### **DIR in deriving a PET-CT based GTV**

Following the co-registration feasibility investigation, DIR was used to derive a GTV using a combination of PET-CT and pCT. For all 14 patients, the metabolically active volumes were contoured by a physicist on the PET-CT images, using 50% of maximum SUV thresholding.

Volumes were reviewed by a dual-certified nuclear medicine physician and radiologist, and contours edited manually using CT images and diagnostic imaging including EUS data. Structures were transferred to the pCT using DIR. Contours were reviewed by a radiation oncologist and the entire circumference of the involved oesophagus, as determined by the PET-CT, was outlined to define the GTV (GTV<sub>PET-CT</sub>). This volume was grown according to the clinical protocol to produce a PET-CT derived PTV (PTV<sub>PET-CT</sub>).

### Relapse analysis

For 6 patients who experienced local recurrence, the relapse volume (GTV<sub>relapse</sub>) was contoured on the diagnostic relapse CT. DIR was used to transfer this volume to the pCT. Dose delivered to the site of relapse was determined by recalculating the original treatment plan.

### Comparison of Volumes

A visual comparison of the location of the relapse volumes (GTV<sub>relapse</sub>), relative to both the PTV<sub>PET-CT</sub> and PTV<sub>TP</sub>, determined whether the site of relapse was contained within these structures. The Incl was used to examine whether any correlation exists between GTV<sub>relapse</sub> and the PET-avid volume. Dosimetric analysis was carried out by measuring the V95%, i.e. the volume receiving 95% of the prescribed treatment dose, of each structure to assess coverage.

## RESULTS

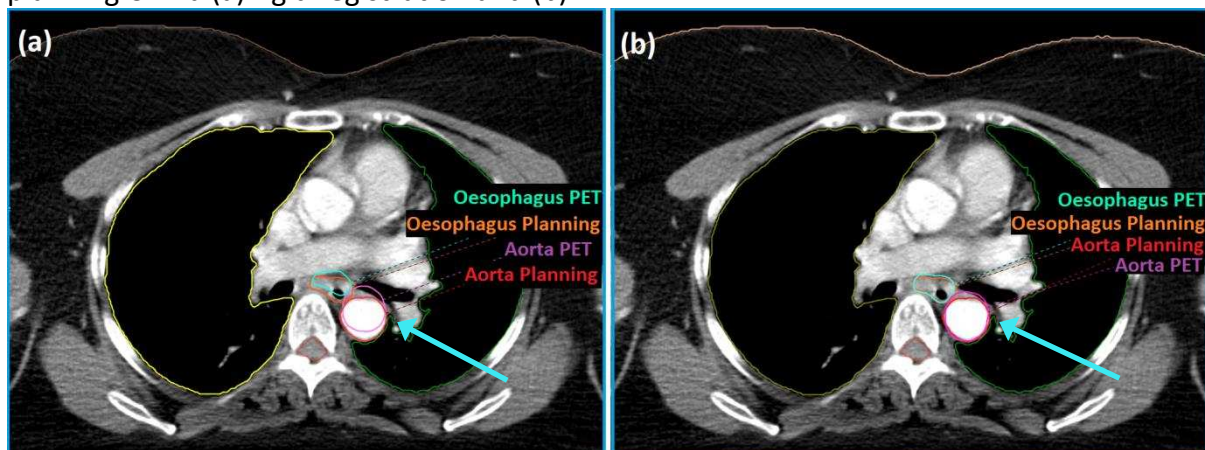
### Assessment of co-registration of PET-CT to planning CT

#### Qualitative Assessment

All co-registrations of PET-CT to pCT were considered clinically acceptable by qualitative visual assessment. DIR was rated as superior to rigid registration for all 14 patients. A representative example is shown in Figure 1.

**Figure 1**

A visual examination of the oesophagus and aorta structures mapped from the PET-CT to the planning CT via (a) rigid registration and (b) DIR.



## Quantitative Assessment

Intra-observer variability of contouring the aorta, oesophagus and trachea was tested to evaluate whether these structures were suitable for subsequent quantitative co-registration analysis. DICE coefficients of 0.9, 0.9 and 0.8 were measured for the trachea, descending aorta and oesophagus respectively, demonstrating that contouring of these structures was highly reproducible and suitable for using as regions of interest to determine the accuracy of image co-registration on subsequent analysis.

The positional metrics analysis of co-registration of the PET-CT to the pCT comparing co-registration of oesophagus, trachea and aorta are summarised in table 2. DIR was significantly superior to rigid registration for multiple metrics for each structure. Co-registration of the oesophageal structure was superior using DIR compared with rigid registration by all positional metrics, with statistical significance for CI, DSC and Incl.

For all patients, a volumetric comparison of the metabolically active tumour volumes (based on 50% automatic segmentation), before and after DIR, was used to examine the local deformation and ensure that the deformation algorithm conserved volume in these regions. An average absolute difference in volume of 1.4cm<sup>3</sup> (range -5 to 6.7cm<sup>3</sup>) was observed, with a maximum increase in volume of 6.7cm<sup>3</sup> for one patient (48.9cm<sup>3</sup> on PET-CT to 55.6cm<sup>3</sup> on planning CT).

**Table 2**

Quantitative evaluation of DIR and rigid registration between PET-CT and pCT using positional metrics

Structure	Registration	PET CT to Planning CT (n=14)			
		CI	DSC	Incl	SI
Oesophagus	DIR	0.59	0.75	0.8	0.72
	Rigid	0.48	0.65	0.67	0.65
	<i>p-value</i>	<i>0.003</i>	<i>0.009</i>	<i>0.001</i>	<i>0.001</i>
Trachea	DIR	0.78	0.88	0.86	0.91
	Rigid	0.51	0.65	0.65	0.65
	<i>p-value</i>	<i>0.0001</i>	<i>0.0004</i>	<i>0.002</i>	<i>0.0001</i>
Descending Aorta	DIR	0.86	0.93	0.94	0.92
	Rigid	0.76	0.86	0.86	0.87
	<i>p-value</i>	<i>0.006</i>	<i>0.006</i>	<i>0.0002</i>	<i>0.072</i>

**Table 3**

Quantitative evaluation of DIR and rigid registration between relapse CT and pCT using positional metrics

Structure	Registration	Relapse CT to Planning CT (n=6)			
		CI	DSC	Incl	SI
Oesophagus	DIR	0.61	0.74	0.87	0.65
	Rigid	0.37	0.51	0.59	0.45



	<i>p-value</i>	<i>0.006</i>	<i>0.004</i>	<i>0.03</i>	<i>0.003</i>
<b>Trachea</b>	DIR	0.83	0.91	0.93	0.90
	Rigid	0.51	0.66	0.63	0.70
	<i>p-value</i>	<i>0.02</i>	<i>0.03</i>	<i>0.11</i>	<i>0.08</i>
<b>Descending Aorta</b>	DIR	0.83	0.91	0.9	0.93
	Rigid	0.63	0.75	0.76	0.73
	<i>p-value</i>	<i>0.06</i>	<i>0.08</i>	<i>0.11</i>	<i>0.06</i>

### Comparison of GTV delineation using PET-CT and DIR compared with side-by-side visual assessment

Based upon the results of qualitative and quantitative analysis of rigid and deformable co-registration, DIR was selected as the optimal method for integrating PET-CT directly into the radiotherapy planning process. In order to assess the potential impact upon GTV delineation of DIR of the PET-CT, GTVs were contoured on the pCT using DIR or side-by-side viewing for all 14 patients. The mean DICE coefficient was 0.63 (range 0.13-0.84).

### Analysis of site of local recurrence

#### Assessment of co-registration of relapse CT to planning CT

##### Qualitative analysis

The co-registration of the relapse CT to pCT was considered acceptable for five of six patients for both rigid and deformable registration techniques; DIR was rated as superior for each of these five patients. For one patient, co-registration was not possible as the patient had had a stent inserted into the oesophagus at the time of the relapse CT. This resulted in large variations to the position of the trachea and aorta compared to the pCT.

##### Quantitative analysis

Quantitative analysis of co-registration of relapse CT to pCT was performed for the five patients for whom co-registration had been deemed clinically acceptable. Table 3 summarises these results, showing superiority of DIR for multiple metrics, with a trend towards DIR being superior to rigid registration for all positional metrics and all structures.

##### Dosimetric analysis of site of local relapse

Dosimetric analysis was also performed to assess the coverage of GTV<sub>relapse</sub> structures, relative to the PTV<sub>PET-CT</sub> and PTV<sub>TP</sub> structures. Patient 2 was omitted due to a stent inserted in the oesophagus prior to the relapse CT, which meant image co-registration was not possible. Dosimetric analysis showed that, with the exception of patient 2, 100% of the relapse volumes were contained within the V95%. The Incl was used to examine whether any correlation exists between the location of the relapse volume and the GTV<sub>PET-CT</sub> and PTV<sub>PET-CT</sub>. Results are summarised in table 4.



**Table 4**

The Incl looks at the probability that a voxel of  $GTV_{relapse}$  is contained within  $GTV_{PET-CT}$  and  $PTV_{PET-CT}$

Patient	Staging	Inclusiveness Index		
		$GTV_{relapse}$ to $GTV_{PET-CT}$	$GTV_{relapse}$ to $CTV_{PET-CT}$	$GTV_{relapse}$ to $PTV_{PET-CT}$
1	T3N1M0	0.69	0.99	1
2	T3N0M0	*	*	*
3	T3N0M0	0.84	1	1
4	T3N1M0	0.6	0.85	0.94
5	T3N1M0	0.45	0.88	1
6	T3N1M0	0.7	0.93	1

\*Omitted due to oesophageal stent insertion.

## DISCUSSION

The benefits of the integration of PET-CT into the planning process have been widely discussed [28-31]. However, this process is challenging, mainly due to the variations in patient setup between diagnostic and planning scans. The availability of a dedicated planning PET-CT for oesophageal carcinoma is not widely accessible. Therefore, the use of image co-registration to facilitate this integration is highly relevant. This is in view of the importance of improving the quality of GTV delineation in order to avoid a geographic miss. It can also assist in identifying a suitable target for future dose escalation studies. This study shows that image co-registration offers a suitable method of incorporating diagnostic PET-CT imaging to the treatment planning process.

There is no definitive method of validating the accuracy of a registration but fixed landmark placement and ROI-based comparisons have been used [32-33]. This study applied an ROI-based method of validation, choosing structures which were easy to identify and contour, and adjacent to the treatment field. Analysis of intra-observer variability showed that contouring of these structures was highly reproducible; these structures are therefore suitable for analysis of co-registration accuracy. Both qualitative and quantitative analysis showed that DIR was superior to rigid registration in accurately registering diagnostic PET-CT and relapse CT imaging to a pCT. Co-registration of PET-CT to pCT, using DIR, was significantly superior by multiple positional metrics, with a significant trend to superiority in all comparisons. Importantly, blinded clinical qualitative assessment found that the co-registration of PET-CT to pCT was clinically acceptable for planning purposes and superior with DIR. In order to assess the potential impact of incorporating diagnostic position PET-CT directly into the planning process with DIR, GTVs were delineated using PET-CT on the pCT, either by side-by-side visual assessment or DIR. The limited mean DICE coefficient (0.63) implies that using DIR to co-register the PET-CT could have a significant impact upon GTV delineation compared with current practice.

We went on to determine the feasibility of using DIR to analyse the pattern of local recurrences. Again, DIR was found to be superior to rigid co-registration by both qualitative and quantitative methods. Image registration was unable to overcome large anatomical

changes in one patient in whom an oesophageal stent had been inserted prior to relapse imaging.

DIR of relapse imaging was used to analyse the pattern of recurrence to determine whether any correlation exists between the site of these recurrences and the PTV<sub>PET-CT</sub>. This has previously been examined for head and neck patients [34]. Local recurrences were classified as 'infield', 'marginal' or 'out-of-field' if more than 95%, 20-94% and less than 20% of the recurrence volume was within the 95% isodose line [22]. Dosimetric analysis for the 5 relapse patients studied showed that all relapse volumes were in the high dose treatment field within both the PTV<sub>PET-CT</sub> and PTV<sub>TP</sub>. This is supported by previous work which examined the pattern of local recurrence and found that the majority of recurrences occurred within the treatment field [2]. The Incl was also used to determine whether this recurrence volume was contained within PTV<sub>PET-CT</sub> and PTV<sub>TP</sub> structures. An average Incl of 0.66 (range of 0.45-0.84) suggests some degree of correlation between the relapse volumes and the GTV<sub>PET-CT</sub>. A high correlation exists between the relapse volumes and CTV<sub>PET-CT</sub> with an average Incl of 0.93 (range of 0.85-1). Preliminary data suggest local recurrences are predominantly due to resistant disease rather than a geometric miss. Dose escalation using a synchronous boost may be necessary to reduce this likelihood of treatment failure. The suggested correlation between the relapse volumes and CTV<sub>PET-CT</sub> suggests that the metabolically active PET volume, plus a margin, could be used as a target in dose escalation studies. These findings support the planned UK SCOPE2 trial where dose escalation using a synchronous boost will be used. It should be recognised that this is hypothesis generating data in a small sample, and further work is required to validate this proof of principle for a larger patient cohort.

There are several limitations to this study. Only 6 patients had a local relapse of which 5 were suitable for analysis of the pattern of relapse. These data require confirmation in a larger cohort. There is a lack of a validated method of GTV delineation using PET-CT, including the optimum SUV maximum threshold for delineating the metabolically active volume on the PET-CT [10-13]. A prior study focusing on cervical cancer showed that the minimum threshold representing tumour volume was 40% of maximum SUV with values less than this included additional background uptake [35]. An additional study reported that values of greater than 80% SUV max should be avoided as tumour volumes are small and the partial volume effect is pronounced [36]. Consequently, this study uses a pragmatically determined value of 50% of maximum SUV thresholding. This reflects a compromise between the two and the cut off used by diagnostic PET radiologists when reporting on the length of the tumour.

This study has shown, through both quantitative and qualitative analysis, that DIR allows more accurate image co-registration than rigid registration for both PET-CT and relapse CT to pCT registration. However, the time interval between the pCT and PET-CT and, in particular, the relapse CT, means that significant changes to patient anatomy (e.g. weight loss) and tumour volume (e.g. disease progression) may have occurred. This can result in inaccuracies in the image co-registration. This was observed for one patient where an oesophageal stent had been inserted prior to acquisition of the relapse CT. A detailed check of image registration should be carried out prior to the transfer of PET-CT and relapse volumes to the pCT. This time interval is of critical importance in deciding whether it is appropriate to use a diagnostic PET-CT in the radiotherapy planning process; the potential for tumour progression in the intervening period needs to be considered.

## CONCLUSION

DIR is superior to rigid registration and represents a feasible and practical approach for integrating PET-CT imaging to the treatment planning process for oesophageal radiotherapy. Using DIR to examine the pattern of relapse is a valuable tool in assessing the quality of radiotherapy treatment. This study demonstrates the potential of using DIR to assess the pattern of local recurrence. Analysis of this pattern for five patients suggests geometric miss of the volume due to the initial treatment planning was unlikely, and treatment intensification using a synchronous boost could have clinical benefits; a metabolic, biological tumour volume derived from the PET-CT represents a potential target. However, the sample size is limited and the relation of relapse location to the pre-treatment metabolically active tumour location PET-CT requires validation in a large cohort.

## References

1. Cancer Research UK, One-, five- and ten-year survival for oesophageal cancer [<http://www.cancerresearchuk.org/health-professional/cancer-statistics/statistics-by-cancer-type/oesophageal-cancer/survival#heading-Zero>] Accessed November 2015
2. Button MR, Morgan CA, Croydon ES, Roberts SA & Crosby TDL. Study to determine adequate margins in radiotherapy planning for esophageal carcinoma by detailing patterns of recurrence after definitive chemoradiotherapy. *Int J Radiat Oncol Biol Phys* 2009; 73(3): 818-823.
3. Muijs CT, Beukema JC, Woutersen D, Mul VE, Baveling MJ, Pruim J et al. Clinical validation of FDG-PET/CT in the radiation treatment planning for patients with oesophageal cancer. *Radiother Oncol* 2014; 113: 188-192
4. Muijs C, Smit J, Karrenbeld A, Beuhema J, Mul V, van Dam G, et al. Residual Tumor After Neoadjuvant Chemoradiation Outside the Radiation Therapy Target Volume: A New Prognostic Factor for Survival in Esophageal Cancer. *Int J Radiat Oncol Biol Phys* 2014; 88(4): 845-852
5. Muijs CT, Beukema JC, Pruim J, Mul VE, Groen H, Plukker JT et al. A systematic review on the role of FDG-PET-CT in tumour delineation and radiotherapy planning in patients with esophageal cancer. *Radiat Oncol* 2010; 97: 165-171.
6. Konski A., Doss M., Milestone B., Haluszka O., Hanlon A., Freedman G et al. The integration of 18-Fluoro-deoxy-glucose position emission tomography and endoscopic ultrasound in the treatment planning process for esophageal carcinoma. *Int J Radiat Oncol Biol Phys* 2005; 61(4): 1123-1128.
7. Song SY, Kim JH, Ryu JS, Lee GH, Kim SB, Park SI et al. FDG-PET in the prediction of pathologic response after neoadjuvant chemoradiotherapy in locally advanced, resectable esophageal cancer. *Int J Radiat Oncol Biol Phys* 2005; 63(4): 1053-1059.

8. Roedl JB, Colen RR, Holalkere NS, Fischman AJ, Choi NC and Blake MA. Adenocarcinomas of the esophagus: Response to chemoradiotherapy is associated with decrease of metabolic tumor volume as measured on PET-CT. Comparison to histopathologic and clinical response evaluation. *Radiother Oncol* 2009; 89: 278-286.
9. Muijs CT, Schreurs LM, Busz DM, Beukema JC, van der Borden AJ, Pruim J et al. Consequences of additional use of PET information for target volume delineation and radiotherapy dose distribution for esophageal cancer. *Radiat Oncol* 2009; 93: 447-453.
10. Jayachandran P, Reetesh KP, Quon A, Graves E, Krakow TE, La T et al. Postchemoradiotherapy Positron Emission Tomography predicts pathologic response and survival in patients with esophageal cancer. *Int J Radiat Oncol Biol Phys* 2012; 84(2): 471-477.
11. Zhong X, Yu J, Zhang B, Mu D, Zhang W, Li D et al. Using 18F-Fluorodeoxyglucose Positron Emission Tomography to Estimate the Length of Gross Tumor in Patients with Squamous Cell Carcinoma of the Esophagus. *Int J Radiat Oncol Biol Phys* 2009; 73(1): 136-141
12. Vali FS, Nagda S, Hall W, Sinacore J, Gao M, Lee SH et al. Comparison of Standardised Uptake Value-Based Positron Emission Tomography and Computed Tomography Target Volumes in Esophageal Cancer Patients undergoing Radiotherapy. *Int J Radiat Oncol Biol Phys* 2010; 78(4): 1057-1063
13. Seol KH & Lee JE. PET/CT planning during chemoradiotherapy for esophageal cancer. *Radiat Oncol* 2014; 32(1): 31-42
14. Sabater S, del Rosario Pastor-Juan M, Berenguer R, Andres I, Sevillano M, Lozano-Setien E et al. Analysing the integration of MR images acquired in a non-radiotherapy treatment position into the radiotherapy workflow using deformable and rigid registration. *Radiother Oncol* 2016; 119: 179-84
15. Lu W, Olivera GH, Chen Q, Ruchala KJ, Haimerl J, Meeks SL et al. Deformable registration of the planning image (kVCT) and daily images (MVCT) for adaptive radiation therapy. *Phys Med Biol* 2006; 51: 4357-4374.
16. Elstrom UV, Wysocka BA, Muren LP, Petersen JBB & Grau C. Daily kV cone-beam CT and deformable image registration as a method for studying dosimetric consequences of anatomic changes in adaptive IMRT of head and neck cancer. *Acta Oncol* 2010; 49: 1101-1108.
17. Olteanu LAM, Madani I, De Neve W, Vercauteren T & De Gerssem W. Evaluation of deformable image coregistration in adaptive dose painting by numbers for head and neck cancer. *Int J Radiat Oncol Biol Phys* 2012; 83(2): 693-703
18. Anders LC, Stieler F, Siebenlist K, Schafer J, Lohr F & Wenz F. Performance of an atlas-based autosegmentation software for delineation of target volumes for radiotherapy of breast and anorectal cancer. *Radiother Oncol* 2012; 102: 68-73.

19. Speight R, Karakaya E, Prestwich R, Sen M, Lindsay R, Harding R et al. Evaluation of atlas based auto-segmentation for head and neck target volume delineation in adaptive/replan IMRT. *Journal of Physics: Conference Series* 2014; 489 (1) 012060.
20. Lee C, Langen KM, Lu W, Haimerl J, Schnarr E, Ruchala KJ et al. Assessment of parotid gland dose changes during head and neck cancer radiotherapy using daily megavoltage computed tomography and deformable image registration. *Int J Radiat Oncol Biol Phys* 2008; 71(5): 1563-1571.
21. Hardcastle N, van Elmp W, De Ruyscher D, Bzdusek K & Tome WA. Accuracy of deformable image registration for contour propagation in adaptive lung radiotherapy. *Radiat Oncol* 2013; 8:243-250.
22. Hardcastle N, Tome WA, Cannon DM, Brouwer CL, Witterndorp PWH, Dogan N et al. A multi-institution evaluation of deformable image registration algorithms for automatic organ delineation in adaptive head and neck radiotherapy. *Radiat Oncol* 2012; 7: 90-6
23. Dawson LA, Anzai YA, Marsh L, Martel ML, Paulino A, Ship JA et al. Patterns of local-regional recurrence following parotid-sparing conformal and segmental intensity-modulated radiotherapy for head and neck cancer. *Int J Radiat Oncol Biol Phys* 2000; 46(5): 1117-1126
24. Oksuz DC, Prestwich RJ, Carey B, Wilson S, Senocak M, Choudhury A, Dyker K et al. Recurrence patterns of locally advanced head and neck squamous cell carcinoma after 3D conformal (chemo-)radiotherapy. *Radiat Oncol* 2011; 6:54-64
25. Bayman E, Prestwich RJD, Speight R, Aspin L, Garratt, Wilson S et al. Patterns of failure after intensity-modulated radiotherapy in head and neck squamous cell carcinoma using compartmental clinical target volume delineation. *Clin Oncol (R Coll Radiol)* 2014; 26(10): 636-642
26. Crosby T, Hurt CN, Falk S, Gollins S, Mukherjee S, Staffurth J et al. Chemoradiotherapy with or without cetuximab in patients with oesophageal cancer (SCOPE1): a multicentre, phase 2/3 randomised trial. *Lancet Oncol* 2013; 14: 627-637
27. Larrue A, van Elmp W, Kaster F, Kadir T & Gooding M. Evaluation of deformable registration for correcting respiratory motion in 4DCT lung images. *Med Phys* 2014; 41: 196.
28. Barber TW, Duong CP, Leong T, Bressel M, Crummond EG & Hicks RJ. 18F-FDG PET/CT has a high impact of patient management and provides powerful prognostic stratification in the primary staging of esophageal cancer: a prospective study with mature survival data. *J Nucl Med* 2012; 53(6) 865-871.
29. Flamen P, Lerut A, van Cutsem E, De Wever W, Peeters M, Stroobants S et al. Utility of positron emission tomography for the staging of patients with potentially operable oesophageal carcinoma. *J Clin Oncol* 2000; 18(18): 3202-3210.

30. Duong CP, Demetriou H, Weih L, Thompson A, Williams D, Robert JS et al. Significant clinical impact of prognostic stratification provided by FDG-PET in the staging of esophageal cancer. *Eur J Nucl Med Mol Imaging* 2008; 35:2320-2333.
31. Lordick F, Ott K, Krause BJ. PET to assess early metabolic response and to guide treatment of adenocarcinoma of the oesophagogastric junction: the MUNICON phase II trial. *Lancet Oncol* 2007; 8: 797-805.
32. Rigaud B, Simon A, Castelli J, Gobeli M, Arango JO, Cazoulat G et al. Evaluation of deformable image registration methods for dose monitoring in head and neck radiotherapy. *BioMed Research International* 2015; Vol. 2015: Article ID 7262682015
33. Moureau-Zabotto L, Touboul E., Lerouge D, Deniaud-Alexandre E, Grahek D, Foulquier JN et al. Impact of CT and 18F-Deoxyglucose positron emission tomography image fusion for conformal radiotherapy in esophageal carcinoma. *Int J Radiat Oncol Biol Phys* 2005; 63(2): 340-345
34. Soto DE, Kessler ML, Piert M & Eisbruch A. Correlation between pre-treatment FDG-PET biological target volume and anatomical location of failure after radiation therapy for head and neck cancers. *Radiat Oncol* 2008; 89:13-18
35. Miller TR & Grigsby PW. Measurement of tumor volume by PET to evaluate prognosis in patients with advanced cervical cancer treated by radiation therapy. *Int J Radiat Oncol Biol Phys* 2002; 53(2): 353-359
36. Soret M, Bacharach SL & Buvat I. Partial-volume effect in PET tumor imaging. *J Nucl Med* 2017; 48(6) 932-945