

This is a repository copy of *Improving survival of retinoblastoma in Uganda*.

White Rose Research Online URL for this paper:

<https://eprints.whiterose.ac.uk/117378/>

Version: Accepted Version

Article:

Waddell, Keith M, Kagame, Kenneth, Ndamira, Andrew et al. (6 more authors) (2015) Improving survival of retinoblastoma in Uganda. *British Journal of Ophthalmology*. pp. 937-942. ISSN 1468-2079

<https://doi.org/10.1136/bjophthalmol-2014-306206>

Reuse

Items deposited in White Rose Research Online are protected by copyright, with all rights reserved unless indicated otherwise. They may be downloaded and/or printed for private study, or other acts as permitted by national copyright laws. The publisher or other rights holders may allow further reproduction and re-use of the full text version. This is indicated by the licence information on the White Rose Research Online record for the item.

Takedown

If you consider content in White Rose Research Online to be in breach of UK law, please notify us by emailing eprints@whiterose.ac.uk including the URL of the record and the reason for the withdrawal request.

Improving survival of retinoblastoma in Uganda

Keith M Waddell,^{1,2} Kenneth Kagame,^{1,2} Andrew Ndamira,² Amos Twinamasiko,² Susan V Picton,³ Ian G Simmons,³ Paul Revill,⁴ W Tom Johnston,⁵ Robert Newton^{5,6,7}

¹Ruharo Eye Hospital, Mbarara, Uganda

²Departments of Ophthalmology and Paediatrics, Mbarara University of Science and Technology, Mbarara, Uganda

³Departments of Ophthalmology and Paediatric Oncology, Leeds Teaching Hospitals NHS Trust, Leeds, UK

⁴Centre for Health Economics, University of York, York, UK

⁵Epidemiology and Cancer Statistics Group, Department of Health Sciences, University of York, York, UK

⁶Medical Research Council/Uganda Virus Research Institute (MRC/UVRI) Research Unit on AIDS, Entebbe, Uganda

⁷International Agency for Research on Cancer, Lyon, France

Correspondence to

Dr Robert Newton, MRC/UVRI Research Unit on AIDS, PO Box 49, Entebbe, Uganda; Rob.Newton@mrcuganda.org; Rob.Newton@ecsg.york.ac.uk

Received 30 September 2014

Revised 12 December 2014

Accepted 17 December 2014

ABSTRACT

Background Diagnostic delay results in relatively high mortality among children with retinoblastoma in Uganda, where treatment was limited to surgery and, for some, radiotherapy. In order to improve outcomes, a simple programme of neoadjuvant and adjuvant chemotherapy was introduced. Here we report survival before and after this change to medical practice.

Methods Affordable standard off-patent chemotherapy agents were administered by trained paramedical staff to groups of patients at the same time. Survival before and after the introduction of chemotherapy was monitored. Between 2006 and 2013 a total of 270 patients with retinoblastoma were included, 181 treated prior to chemotherapy and 89 after (beginning in 2009). We had 94% follow-up and 249 had histological verification of diagnosis.

Results Using a proportional hazards model adjusted for age, sex and laterality, children treated after chemotherapy was introduced had a 37% lower risk of dying (HR 0.63, 95% CI 0.41 to 0.99) compared with children treated before. Prior to the introduction of chemotherapy only 15% of children who survived bilateral disease retained vision after treatment compared with 71% after chemotherapy.

Conclusions The introduction of chemotherapy proved safe and cost-effective in non-specialist hands and was associated with significant improvements in survival and, among bilateral cases, in preserving vision.

INTRODUCTION

An estimated 250 000 cancers are diagnosed each year among children under the age of 15 years of which only about 20–30%, mainly those living in high income countries, receive adequate diagnostic evaluation and care.¹ Advances in paediatric oncology have resulted in dramatic improvements in survival in some countries, but much of this remains unavailable to patients in resource-constrained settings. For example, in western Europe and the USA, around 80% of children with cancer now survive compared with <25% in low and middle income countries (LMIC), notably those in sub-Saharan Africa.² A combination of many factors have an impact on survival in LMIC, including diagnostic delays resulting in advanced stage of disease at presentation, lack of availability of chemotherapeutic agents, cost of treatment leading to abandonment of care and limited access to surgery and radiotherapy.^{1 2}

For example, childhood eye cancer retinoblastoma is largely curable in high income settings.^{3 4} Usually diagnosed at an early stage, modern treatment can even avoid complete loss of vision in an affected eye. However, the situation is markedly different in sub-Saharan Africa.⁵ Until recently,

surgery had been the only treatment option available in Uganda, with a minority of children receiving radiotherapy from the country's only radiotherapy machine. In our recent nationwide study in which we documented current treatment practice, histology and survival for 282 children with retinoblastoma, it was evident that mortality rates were unacceptably high, largely because children present with late stage disease.⁶ Survival at 36 months was only 44% overall, with most cases being International Classification of Retinoblastoma (ICRB) group E, or already extraocular, at diagnosis.

With the aim of improving survival from this cancer we introduced a pragmatic programme of neoadjuvant and adjuvant chemotherapy in one referral centre in south-western Uganda. Here we describe that programme, which was designed specifically for LMIC settings, and document improvements in survival that followed.

METHODS

The efficacy of chemotherapy was assessed within the context of a clinical cohort of patients with retinoblastoma described in detail elsewhere.⁶ Between January 2006 and December 2010, ophthalmologists in Uganda were invited to enter cases into the study while retaining management. Some ophthalmologists in Uganda run mobile outreach teams, so cases came from all over the country; the degree of clinical investigation varied widely.⁶ At one centre (Ruharo Eye Hospital in Mbarara), recruitment continued throughout 2011. A standard form documented demography, clinical features, treatment and follow-up. Staging was according to the ICRB. Counsellors, using vernacular, gave information about the disease, its treatment and the study, and parents signed or thumb-printed that they understood and consented. Some patients received radiotherapy at Mulago Hospital, Kampala with the country's only machine (cobalt 60; dose 39 Gy in 13 fractions). A few patients with metastasis were referred to the Uganda Cancer Institute for late chemotherapy.

It became evident that mortality was unacceptably high, with a significant proportion of cases having extraocular spread at presentation and the use of chemotherapy was clearly indicated. Therefore, a clinical decision was made to introduce a pragmatic programme of neoadjuvant chemotherapy (not previously available in Uganda) within the framework of ongoing ethically approved research. The programme had four key features:

1. Affordable standard off-patent chemotherapy agents were used.

To cite: Waddell KM, Kagame K, Ndamira A, *et al*. *Br J Ophthalmol* Published Online First: [please include Day Month Year] doi:10.1136/bjophthol-2014-306206

- The drugs were administered by appropriately trained paramedical staff (with cover from an experienced paediatrician) in order to keep costs down and to allow a non-specialist centre to provide care.
- Children did not stay in hospital for the entire period of their chemotherapy but the cost of transport and food was provided for the child and carer during periods of treatment. This had the effect of reducing abandonment of care by parents who find a prolonged hospital stay impossible because of other family commitments. Between treatments, use was made of mobile telephones and home visits where necessary (with a home visiting team) to maintain contact.
- Chemotherapy treatment was provided to groups of patients at the same time. This had the advantage of allowing parents to benefit from peer support and also it reduced abandonment of care since parents of newly diagnosed children could see benefits for those further into treatment.

After 4 years of nationwide study and evident poor survival, an amendment to the ethical approval was sought to allow intensive follow-up of children provided with chemotherapy at Ruharo Eye Hospital, Mbarara, in south-western Uganda and additional informed consent was obtained. The protocol involved neoadjuvant chemoreduction using a standard chemotherapy protocol used routinely in the UK and elsewhere.⁷ There was no doubt that changes to management were required in order to improve outcomes and that chemotherapy was indicated. Our aim was to assess safety when given by non-specialists in an environment with high background child mortality rates and prevalence of infectious disease. This activity was supported by paediatric oncology and paediatric ophthalmology specialists from Leeds Teaching Hospitals, UK. The programme used vincristine 1.5 mg/m², carboplatin 600 mg/m² and etoposide 300 mg/m² (reduced below 1 year or 10 kg) intravenously by peripheral veins. Two courses were given before surgery, continuing up to six according to histology (occasionally more) with 21–28 days between. Blood was checked before each administration, proceeding provided haemoglobin was >70 g/L, platelets 100×10³/μL and neutrophils 1×10³/μL. Prophylaxis was given throughout for bacterial infection (ciprofloxacin) and malaria (mefloquine and bed nets) plus folic acid.

The first case was treated in June 2009 and the tenth in December 2009, without incident. It was therefore decided to continue chemotherapy as standard best practice, preferably starting before enucleation and with intensive follow-up of all patients. All programme costs including chemotherapy, surgery, transport and food were paid by donors.

Survival of patients was initially described using Kaplan–Meier plots. A comparison of survival was made between the periods

before and after the introduction of chemotherapy; a randomised trial is unethical in such situations since chemotherapy, once available, was indicated for almost all cases. Survival in the two time periods was compared using a proportional hazards regression model adjusting for age at diagnosis, sex and tumour extent at diagnosis. Appropriate tests of the proportional hazards assumption were carried out. Active follow-up of 270 of the 282 patients in the clinical cohort up to June 2013 is presented here and remains ongoing. Twelve patients are not included because they died before treatment of any kind could be started (five patients), had missing survival information (one patient) or due to recurrence (or disclosure) of a primary tumour in the previously unaffected eye thereby receiving treatment in both time periods (six patients).

RESULTS

A total of 270 children with retinoblastoma participated in the study, 181 treated prior to the introduction of chemotherapy and 89 treated after its introduction (figure 1). We achieved 94% follow-up of cases and 249 had histological verification of diagnosis; 68 children (25%) had bilateral disease. On the basis of attendance at Ruharo Eye Hospital, 70 of 89 children in the latter time period received chemotherapy during initial management. Of those, all were group E or extracocular at diagnosis except for two patients who were group C; all were HIV negative. Among the 181 children treated prior to chemotherapy becoming available, 82 (45%) were alive after 24 months of follow-up compared with 58/89 (65%) children treated after chemotherapy became available (figure 1).

Survival was improved among children treated after chemotherapy was available (figure 2); these children had a 37% lower risk of dying (HR 0.63, 95% CI 0.41 to 0.99) compared with children treated before chemotherapy became available. Age at diagnosis, sex and laterality did not have a statistically significant impact on survival. However, extent of the tumour did have an impact on survival, with children with extraocular involvement having an increased risk of dying (HR 4.6, 95% CI 2.8 to 7.8) compared with those with intraocular involvement only. Although the impact of chemotherapy on survival among children with extraocular involvement might be greater than in those with only intraocular involvement, there is as yet limited evidence of this since confidence limits overlap (figure 2B). Case mix in terms of laterality did not differ between patients treated before and after chemotherapy became available ($p=0.47$), but there was a higher proportion of cases with undetermined extent in the children treated before the availability of chemotherapy ($p<0.0001$). Furthermore, among children who survived with bilateral disease, the introduction of chemotherapy was associated with an increase in the number in whom some vision was saved (figure 3). Overall, 3 of 13 (77%)

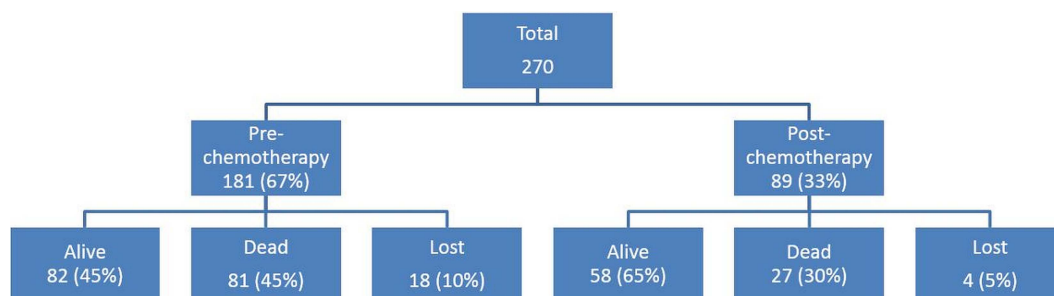

Figure 1 Summary of survival to 24 months after treatment for all children demonstrating an improvement in the post-chemotherapy era compared with the pre-chemotherapy era. Of the 89 children treated after chemotherapy was introduced, 70 received the drugs and 19 had surgery only. The case mix was similar for both periods.

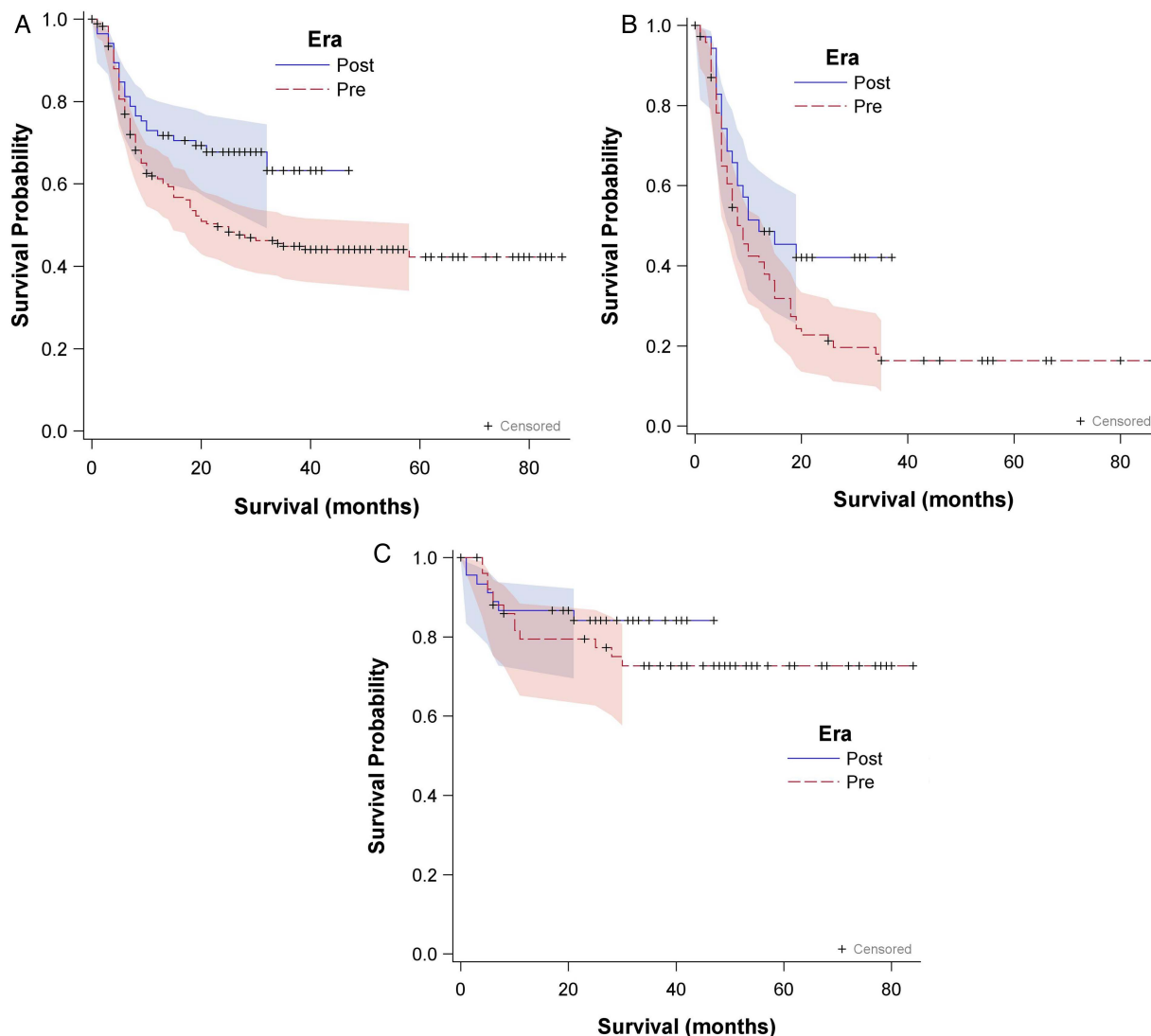


Figure 2 Kaplan–Meier survival estimates (with 95% confidence limits) for children with retinoblastoma stratified by whether the child was treated before or after the availability of chemotherapy for (A) all children, (B) children with extraocular tumour extent and (C) for children with only intraocular involvement. The treatment strata did not differ among children with intraocular involvement only ($p=0.33$) but there was evidence of divergence between the treatment strata among children with extraocular involvement ($p=0.06$). There was, however, no significant interaction between the effects of these factors in the proportional hazards regression analysis. Extraocular extent: optic nerve or sclera involved or orbital tumour present at diagnosis; either eye if bilateral. Intraocular extent: none of the above or optic disc visibly uninvolved; both eyes if bilateral. Era Pre: children diagnosed and treated before chemotherapy was available; Era Post: children diagnosed and treated after chemotherapy was available but not necessarily used for all children depending on attendance.

survivors with bilateral disease had sight after chemotherapy compared with 3 of 20 (15%) without chemotherapy.

A total of 324 courses of chemotherapy were given. Three were delayed by low blood counts; one case required a blood transfusion. Side effects were minor, mostly vomiting for 1 or 2 days which was controlled with oral metoclopramide and dexamethasone intravenously 1 mg/kg at the start and end of chemotherapy. One small vincristine extravasation resolved uneventfully and two developed mild urticaria in their last courses. One child twice had fever causing convulsion. One child died 20 days after chemotherapy, the only death in which leucopenia could be causal (see details below).

For many children included in the study the precise mode of death is uncertain since the study was nationwide. Orbital fungation was common in patients without radiotherapy but there was only one known case after radiotherapy, so it was palliative.

The common sites of metastasis were the skull or spine with paraplegia. There was one known hepatic metastasis and one to local lymph nodes. One bilateral heritable case died with primary sarcoma of the femur. Five children died in remission after short febrile illnesses, apparently unrelated infections. However, mode of death is known for the 20 chemotherapy cases. Fifteen had extraocular extension (seven with macroscopic orbital tumour) and most died with apparent intracranial extension following headache, convulsions or unconsciousness. Of the five who were still intraocular, an 8-month-old child died at home 20 days after the first course following 2 days of cough. This was the only death in which leucopenia from chemotherapy might have resulted in an infection, all others being later. Two patients reportedly died while on treatment for malaria after prophylaxis had ended, one in remission and one after chemoreduction but delayed enucleation. One had loss of

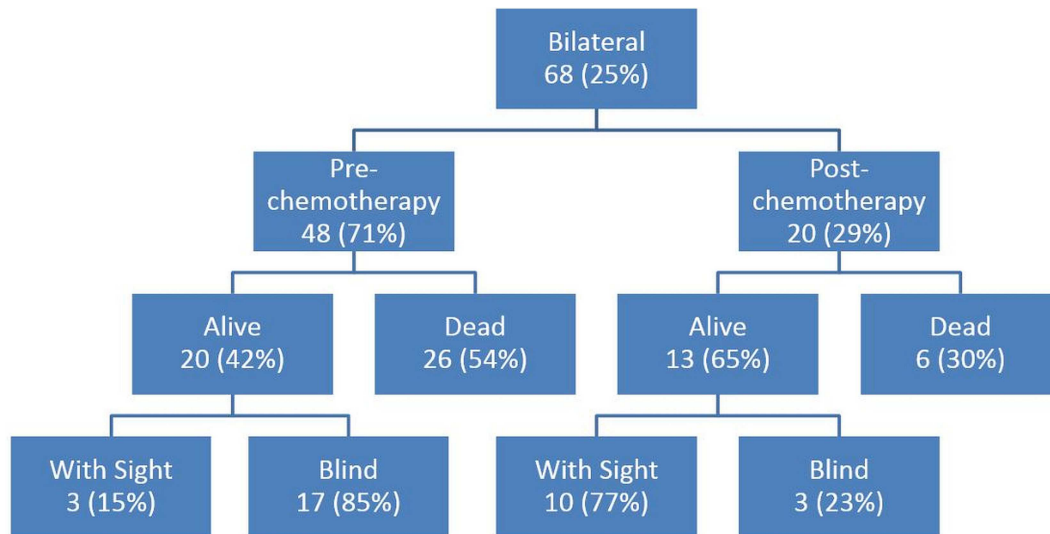


Figure 3 Survival at 24 months after treatment and sight preservation among children with bilateral retinoblastoma illustrating improved outcomes in the post-chemotherapy era compared with the pre-chemotherapy era.

consciousness and was treated for pyogenic and tuberculous meningitis although lumbar puncture did not confirm these; he died after 3 weeks. Although unilateral and with uninvolved nerve, intracranial features suggest pineal tumour in which case he had an extraocular tumour. One infant with bilateral disease died of socket recurrence and metastasis although both optic nerves were reported to be uninvolved; this was the only case of complete failure of chemotherapy.

DISCUSSION

Diagnostic delay results in relatively high mortality among children with retinoblastoma in Uganda; nearly half of tumours were already extraocular at the time of diagnosis. The introduction of neoadjuvant and adjuvant chemotherapy proved safe in non-specialist hands and was associated with significant improvements in survival. In addition, the initiation of chemotherapy has improved survival and, among bilateral cases, together with laser therapy and cryotherapy is helping to preserve vision in the second affected eye.

Follow-up was nearly complete with home visiting and mobile telephones (92%; median 35 months for survivors). This contrasts with other African series and allows firm conclusions about outcome. Also, in striking contrast to Western countries, it confirmed high mortality.^{3 4} This was expected with extraocular extension but high mortality when the disease still intraocular (as far as could be assessed from limited histology) was one reason for the introduction of chemotherapy.⁶ Survival curves show substantial improvement with chemotherapy although mortality is still very high with extraocular extension, mostly because of intracranial involvement. The comparison group preceded chemotherapy so is in that sense historical, but the case mix was similar and it was within the study period so marked bias is unlikely. The use of historical comparison is inevitable for assessing the impact of chemotherapy as improved survival precludes randomised comparison.

It became clear during the study that chemotherapy was essential for reducing mortality. To become widely available in Africa it cannot be confined to specialists in university hospitals which currently exist in only three places in the East African

Community. It must be done by or with ophthalmologists to manage the surgery, cryotherapy and laser. Therefore, to study its safety by non-specialists, ethical approval was obtained for 10 cases at Ruharo Eye Hospital, supported by the Leeds team using their protocol and an onsite paediatrician. Treatment usually comprised six courses, occasionally with more to save the second eye, since toxicity is non-cumulative and fertility undamaged.⁸ It was found to be safe and was extended to subsequent cases. Preoperative chemoreduction (two courses) was preferred unless the eye was already enucleated or diagnosis was in doubt. Enucleation was planned for all group E first eyes in accordance with guidelines for developing countries.⁹ There is debate about preoperative versus postoperative chemotherapy, but this study cannot address that.^{10 11} In the West it is used for a minority of patients selected by detailed histology and anterior segment ultrasound.^{12 13} However, such selection is not possible in Uganda at present because (1) about half the cases are extraocular at diagnosis so require chemotherapy; (2) a quarter are bilateral so need it to conserve the second eye; and (3) even apparent intraocular cases have substantial mortality (figure 2C), presumably they already have disseminated micrometastatic disease at which stage chemotherapy can be curable. Initial chemotherapy is therefore currently required for almost all cases. Selection may become possible when detailed histology becomes available but, even then, correlation between histology and outcome derives mostly from other continents so may not apply in Africa.^{14–16}

The side effects of chemotherapy were minimal and peripheral veins were adequate, sometimes using ketamine sedation for cannulation. The interval between courses was 28 days, with the child returning home between courses. Although it may be preferable for the period to be shorter in order to limit tumour escape, in this environment parents found this too pressing. Retaining them in hospital throughout would be ideal in case leucopenia caused infection, but home responsibilities make this impractical and it would increase costs. The interval was monitored by telephone contact and home visits (where necessary) with few problems. Treating children together in the same weeks produced a family atmosphere, giving parents peer

support during stressful times and limiting drop-out. Starting with chemoreduction enabled parents to interact with already operated cases so that subsequent refusal of enucleation was uncommon. Prosthetic eyes were important for parent satisfaction and avoiding teasing at school. Ready-made prostheses gave acceptable cosmetic results, although contracted sockets from radiotherapy sometimes prevented this. Grafts of oral mucosa are being used to enlarge sockets, and myoconjunctival socket closure over implants has been introduced to improve prosthesis mobility.¹⁷

Survival has improved since chemotherapy has become available. Deaths still occur despite chemotherapy but most had extraocular extension, emphasising the need for parents not to delay. Only one death occurred when leucopenia could have been the cause. The near hopeless prognosis for orbital extension or recurrence (one of 72 surviving even after having chemotherapy and radiotherapy) was disappointing and contrasts with other centres reporting better survival.¹⁶ This indicates a need for introduction of other treatments such as high-dose chemotherapy, brachytherapy or conformal radiotherapy when these become practical.^{18–19} Surgical debulking of orbital tumour was unnecessary because a few courses of chemotherapy have the same effect and also give valuable palliation for those in whom death occurs from metastases. Mortality in children aged <5 years in Uganda is still substantial (national data show it was 13.7% when our study started), so some deaths were probably unrelated.²⁰

For the first time, among cases with bilateral tumour, more eyes are being saved with good vision, thereby preventing blindness. These conserved eyes need repeated examination under anaesthesia with cryotherapy and laser treatment as necessary, and so represent a significant workload. The tumours can reactivate even after 1 or 2 years, and cure of group D tumours in this study is not yet assured.

In a secondary analysis we estimate that the average cost per child, including food and transport, was around US\$1000. A formal cost-effectiveness analysis has not yet been performed but the results indicate that chemotherapy is very likely to be cost-effective, even in the most resource-constrained African health systems. The 37% reduction in absolute risk of death with chemotherapy indicates a cost per child saved of US\$2703 ($\$1000 \times (1/0.37)$). Each surviving child could expect to live at least another 40 healthy years²¹ which, following discounting at 3% per annum, would provide approximately 20 healthy years in present value terms. Even ignoring the benefits of sight preservation for surviving children who would otherwise be blind, this would indicate a cost of US\$135 per disability-adjusted life year (DALY) averted ($\$2703/20$), ranking it among the most cost-effective interventions available for low-income countries.²² To provide context, the WHO has recently recommended use of routine viral load testing for monitoring of patients on anti-retroviral therapy at a cost of >US\$4000 per DALY averted; this is currently being made available in many countries.²³ One dollar of resources spent on chemotherapy would produce 30 times the health benefits of a dollar spent on routine viral load monitoring ($\$4000$ vs $\$135$). Thus, the costs of this intervention are not prohibitive and it should be possible for health systems to make it widely available.

In summary, the main obstacle to reducing mortality from retinoblastoma in Uganda is delayed presentation, but chemotherapy is significantly improving survival and saving sight among bilateral cases. It is safe in non-specialist hands and should be made available in other centres. It is currently needed in this environment for almost all cases and the financial constraints

can be overcome. With a safe and effective treatment programme in place, there is an urgent need in Uganda and other countries in sub-Saharan Africa to address diagnostic delay with national education campaigns encouraging people to come forward with affected children earlier, but there is little point in initiating such schemes in the absence of effective treatment. It is important to note that the approach used here in relation to chemotherapy is applicable to some other childhood cancers for which mortality remains unacceptably high, in particular the most common childhood cancer in Uganda and some other parts of Africa—namely, Burkitt lymphoma.

Acknowledgements We thank colleagues for referring cases, the pathologists for histology, Dr J Kigula-Mugambe for radiotherapy, Mr J Kwehangana for follow-up, the nurses (especially Sr G Kemugisha and Mr C Bidwell) for care of the children and chemotherapy.

Funding The study was financed by Cancer Research UK, Yorkshire Eye Research and Children with Cancer.

Contributors RN was the Principal Investigator and KMW the Project Leader in Uganda. KK, AN, AT, SP and IS provided clinical support. PR provided health economic advice and WTJ provided statistical support. All authors contributed to the research and production of the final manuscript.

Competing interests None.

Patient consent Obtained.

Ethics approval The original study was approved by the Ethics Committee of Mbarara University (Ruharo is affiliated; reference DMS 6), with a subsequent amendment to allow follow-up of children given chemotherapy. It was also approved by the Uganda National Council for Science and Technology (UNCST; reference HS 1044). We certify that all applicable institutional and governmental regulations concerning the ethical use of human volunteers were followed during this research. Registration with UNCST is equivalent to formal trial registration in Uganda, but this follow-up study did not fulfil the criteria for registration as a clinical trial with an international register.

Provenance and peer review Not commissioned; externally peer reviewed.

Data sharing statement All relevant data are presented in the manuscript.

REFERENCES

- Ribeiro RC, Steliarova-Foucher E, Magrath I, *et al*. Baseline status of paediatric oncology care in ten low-income or mid-income countries receiving My Child Matters support: a descriptive study. *Lancet Oncol* 2008;9:721–9.
- Kellie SJ, Howard SC. Global child health priorities: what role for paediatric oncologists? *Eur J Cancer* 2008;44:2388–96.
- Sanders B, Draper G, Kingston J. Retinoblastoma in Great Britain 1969–1980: incidence, treatment and survival. *Br J Ophthalmol* 1988;72:576–83.
- MacCarthy A, Birch J, Draper G, *et al*. Retinoblastoma: treatment and survival in Great Britain 1963 to 2002. *Br J Ophthalmol* 2009;93:38–9.
- Bowman R, Mafwiri M, Luthert P, *et al*. Outcome of retinoblastoma in east Africa. *Paediatr Blood Cancer* 2008;50:160–2.
- Waddell KM, Kagame K, Ndamira A, *et al*. Clinical features and survival among children with retinoblastoma in Uganda. *Br J Ophthalmol*. Published Online First: 12 Sept 2014.
- Dimaras H, Kimani K, Dimba EA, *et al*. Retinoblastoma. *Lancet* 2012;379:1436–46.
- Shields C, Fulco E, Arias J, *et al*. Retinoblastoma frontiers with intravenous, intra-arterial, periocular and intravitreal chemotherapy. *Eye* 2013;27:253–64.
- Chantada G, Luna-Fineman S, Sitorus R, *et al*. SIOP-PODC Recommendations for graduated-intensity treatment of retinoblastoma in developing countries. *Paediatr Blood Cancer* 2013;60:719–27.
- Zhao J, Dimaras H, Massey C, *et al*. Pre-enucleation chemotherapy for eyes severely affected by retinoblastoma masks risk of tumour extension and increases death from metastasis. *J Clin Oncol* 2011;29:845–51.
- Chantada G, Leal-Leal C, Brisse H, *et al*. Is it pre-enucleation chemotherapy or delayed enucleation of severely involved eyes with intraocular retinoblastoma that risks extraocular dissemination and death? *J Clin Oncol* 2011;29:3333–4.
- Uusitalo M, Van Quill K, Scott I, *et al*. Evaluation of chemoprophylaxis in patients with unilateral retinoblastoma with high-risk features on histopathologic examination. *Arch Ophthalmol* 2001;119:41–8.
- Vasquez L, Giuliani G, Halliday W, *et al*. Ultrasound biomicroscopy in the management of retinoblastoma. *Eye* 2011;25:142–6.
- Ajaiyeoba I, Komolafe O, Olusanya B, *et al*. Histological determinant of mortality in retinoblastoma in Ibadan. *Br J Ophthalmol* 2008;92:1297–8.

Clinical science

- 15 Chantada G, Dunkel I, de Dávila M, *et al.* Retinoblastoma patients with high risk ocular pathological features: who needs adjuvant therapy? *Br J Ophthalmol* 2004;88:1069–73.
- 16 Sastre X, Chantada G, Doz F, *et al.* Proceedings of the consensus meetings from the International Retinoblastoma Staging Working Group on the pathology guidelines for the examination of enucleated eyes and evaluation of prognostic risk factors in retinoblastoma. *Arch Pathol Lab Med* 2009;133:1199–202.
- 17 Yadava U, Sachdeva P, Arora V. Myoconjunctival enucleation for enhanced implant motility; result of a randomised prospective study. *Indian J Ophthalmol* 2004;52:221–6.
- 18 Chantada G, Fandino A, Casak S, *et al.* Treatment of overt extraocular retinoblastoma. *Med Pediatr Oncol* 2003;40:158–61.
- 19 Stannard C, Maree G, Munro R, *et al.* Iodine-125 orbital brachytherapy with a prosthetic implant in situ. *Strahlenther Onkol* 2011;187:322–7.
- 20 Demographic and Health Survey 2006. Uganda: Uganda Bureau of Statistics, 2007. <http://www.ubos.org>
- 21 World Health Organization. *Global Health Observatory Data Repository, disease and injury country estimates*. Health Life Expectancy (HALE), 2004.
- 22 World Bank. *Disease Control Priorities in Developing Countries*. 2nd edn. April 2006.
- 23 Keebler D, Revill P, Braithwaite S, *et al.* Cost effectiveness of different strategies to monitor adults on antiretroviral treatment: a combined analysis of three mathematical models. *Lancet Global Health* 2014;2:1.



Improving survival of retinoblastoma in Uganda

Keith M Waddell, Kenneth Kagame, Andrew Ndamira, Amos Twinamasiko, Susan V Picton, Ian G Simmons, Paul Revill, W Tom Johnston and Robert Newton

Br J Ophthalmol published online January 12, 2015

Updated information and services can be found at:
<http://bjo.bmj.com/content/early/2015/01/12/bjophthalmol-2014-306206>

References

These include:

This article cites 19 articles, 6 of which you can access for free at:
<http://bjo.bmj.com/content/early/2015/01/12/bjophthalmol-2014-306206#BIBL>

Email alerting service

Receive free email alerts when new articles cite this article. Sign up in the box at the top right corner of the online article.

Topic Collections

Articles on similar topics can be found in the following collections

[Epidemiology](#) (924)
[Public health](#) (436)
[Paediatrics](#) (332)

Notes

To request permissions go to:
<http://group.bmj.com/group/rights-licensing/permissions>

To order reprints go to:
<http://journals.bmj.com/cgi/reprintform>

To subscribe to BMJ go to:
<http://group.bmj.com/subscribe/>