



Deposited via The University of Leeds.

White Rose Research Online URL for this paper:

<https://eprints.whiterose.ac.uk/id/eprint/93454/>

Version: Accepted Version

Article:

Almukhtar, A, Ayoub, A, Khambay, B et al. (2016) State-of-the-art three-dimensional analysis of soft tissue changes following Le Fort I maxillary advancement. *British Journal of Oral and Maxillofacial Surgery*, 54 (7). pp. 812-817. ISSN: 0266-4356

<https://doi.org/10.1016/j.bjoms.2016.05.023>

© 2016. This manuscript version is made available under the CC-BY-NC-ND 4.0 license
<http://creativecommons.org/licenses/by-nc-nd/4.0>

Reuse

Items deposited in White Rose Research Online are protected by copyright, with all rights reserved unless indicated otherwise. They may be downloaded and/or printed for private study, or other acts as permitted by national copyright laws. The publisher or other rights holders may allow further reproduction and re-use of the full text version. This is indicated by the licence information on the White Rose Research Online record for the item.

Takedown

If you consider content in White Rose Research Online to be in breach of UK law, please notify us by emailing eprints@whiterose.ac.uk including the URL of the record and the reason for the withdrawal request.

State-of-the art analysis of soft tissue changes in response to Le Fort I maxillary advancement

- A. A. Almkhtar,
PhD Student
Scottish Craniofacial Research Group, University of Glasgow, MVLS College, School of Medicine, Dental School, Glasgow, UK
- B. A. Ayoub
Professor of Oral & Maxillofacial Surgery
MVLS college, School of Medicine, the University of Glasgow, Glasgow, UK
- C. B. Khambay
Professor of Orthodontics
Dental school, Leeds University, UK.
- D. J. McDonald
Honorary Professor of Orthodontics
Biotechnology and Craniofacial Sciences (BACS) Research Group, Glasgow Dental School, University of Glasgow, Glasgow, UK
- E. X. Ju
Senior Software Engineer
Medical Device Unit, Department of Clinical Physics and Bioengineering, NHS Greater Glasgow and Clyde, Glasgow, UK
Honorary Research Fellow, Glasgow Dental School, University of Glasgow, Glasgow, UK

Corresponding author:

Ashraf F Ayoub

Professor of Oral & maxillofacial Surgery

The University of Glasgow, MVLS College, School of Medicine, Dental School

378 Sauchiehall street, Glasgow G2 3JZ, the UK

Email:ashraf.ayoub@glasgow.ac.uk

State-of-the art analysis of soft tissue changes in response to Le Fort I maxillary advancement

Abstract:

Aim; This study was carried out to provide a comprehensive description of facial changes following Le Fort I osteotomy and introducing a novel tool for facial anthropometric analysis. **Materials & methods;** This study was carried out on 33 patients who had had Le Fort I maxillary advancement with or without posterior vertical impaction. The investigation was conducted on the CBCT images which were captured one month before surgery and 6 to 12 months postoperatively. Two types of the analysis were applied in this study, the Euclidian corresponding distances and the directional distance analysis. The average antero-posterior surgical movement of the maxilla was the advancement of $5.9\text{mm}\pm 1.7\text{mm}$ with minor anterior and posterior vertical maxillary impaction of $0.1\text{mm}\pm 1.7\text{mm}$ and $0.6\text{mm}\pm 1.45\text{mm}$ respectively. There were a distinctive forward soft tissue movements combined with a marked lateral expansion at the upper lip and paranasal regions; the right and left alar curvatures and the columella showed a marked upward movement. The effect on the nose was limited to the widening and advancement of the nostrils as well as the base of the nose (Subnasale and alar base) region with a minimal forward change but a noticeable upward movement at the nasal tip. The changes at the cheeks were to a lesser extent, with minor but consistent upward and forward movements. **Conclusion,** Dense anatomical surface correspondence is a novel method and produced a comprehensive visual analysis of the facial morphology changes in response to surgery, Le Fort I advancement osteotomy widened the mid-face and upper lip, compressed and widened the nostrils and shortened the lower lip. The effect of surgery may extend to the chin and lower lip secondary to maxillary impaction.

Introduction

The majority of the 3D facial analyses are based on individual landmarks which are digitized on the captured image.¹⁻³ However, this method fails to describe the facial morphology adequately, the analysis is limited to the soft tissue at a few selected points and the anatomical characteristics between these landmarks are not considered. In addition, the reproducibility of facial landmarks is limited.^{4,5} To overcome these deficiencies the colour coded inter-surface distance maps were introduced. This method gained a wide popularity for its simplicity in describing facial changes. It has been widely applied to characterise facial shape amongst various populations⁶⁻⁸ and to describe facial changes following orthognathic surgery.^{9,10} The method was applied to evaluate facial shape variations based on the closest point on the corresponding facial surfaces. However, the lack of anatomical correspondence between the points of the examined soft tissue surfaces is one of its major short comings.¹¹

The application of generic meshes for analysing biological geometry has been reported.¹² The generic mesh is a mathematically constructed facial surface mask that resembles the human face morphology, it is composed of a standard number and equal sized triangles with their vertices indexed. The generic mesh is elastically deformed to adapt more specifically on the shape of the 3D facial image in a process known as “conformation”, this allows tracking of the displaced vertices of the surface mesh due to morphological changes of the imaged face secondary to surgery, pathology or facial growth, using the index of the generic mesh vertices.¹³ This approach provides an anatomical correspondence (dense surface correspondence) between the matched 3D facial images, which are the preoperative and postoperative images in this study, to detect and quantify surgical changes.

Analysis of facial morphology using dense surface correspondences is relatively new to the field of orthognathic surgery. It has been shown that the method could be applied to study the human faces.¹³ Anthropometric facial mask was applied to

described the soft tissue changes due to growth and orthognathic correction of asymmetric face. The analysis produced a visual display of the Euclidean distances between dense surface correspondences of a series of images which represented the facial morphological changes.¹⁴⁻¹⁵

The aim of this study is to provide a comprehensive description of facial changes following Le Fort I osteotomy and introduce a novel tool for facial anthropometric analysis.

Materials and methods

This study was carried out on 33 patients who had had Le Fort I maxillary advancement with or without posterior vertical impaction. Standard osteotomy was carried out, nasal cinching stitch was performed in addition to the trimming of the anterior nasal spine. Patients were white Caucasian, mixed gender and aged between 17 and 46. The investigation was conducted on the CBCT images which were captured one month before surgery and between 6 to 12 months following Le Fort I osteotomy. Full facial scan at 0.4 mm voxel size resolution was performed using the i-Cat cone beam CT machine. Ethical approval was obtained from the local ethics committee.

The magnitude of maxillary surgical movements were measured according to the reported novel method based on the superimposition of the preoperative and postoperative CBCT scans.¹⁶ To quantify maxillary movements measurements were taken as the mean displacement of three anatomical landmarks on the maxilla (incisive foramen, right and left greater palatine foramina) and the mean of three landmarks on the mandible (genial tubercle, right and left mental foramina) due to surgery. The differences between the preoperative and postoperative position of these points in relation to the common reference planes in the x, y, z directions were recorded as the skeletal displacements.

The novel soft tissue analysis is based on the concept of creating an anatomical dense correspondence using a generic facial mesh. The generic facial mesh was elastically deformed to take the shape each patient's face by the process of

“Conformation”. The process involved two stages; first was the initial deformation which was guided by manual placement of 20 anatomical landmarks and a second automated stage for conformation refinement. For each patient, the generic facial mesh was conformed twice, into the preoperative 3D facial image and into the postoperative one. Procrustes superimposition was applied to the conformed 3D preoperative images and also applied to the conformed 3D postoperative images to obtain an average postsurgical and postsurgical image of all the cases. This allowed the application of the dense surface correspondence analysis between the two averaged images as they share the same number and vertices index. Facial soft tissue changes in response to Le Fort I maxillary osteotomy was then quantified in each of the three directions (x, y, z).

Two types of analysis were applied in this study, the Euclidian corresponding distances and the directional distance analysis. For the first, the distance between each pair of the corresponding vertices (carrying the same index) was calculated and given a specific colour on a scale ranging from deep red (positive) for the changes in outward direction from the geometric centre of the face to deep blue (negative). For the changes in inward direction toward the geometric centre of the face whereas the middle of the scale is green representing minimal changes between the two measured surfaces.

For the directional analysis, a right hand coordinate system was adopted (figure 1). If the change of surface points due to surgery was toward the right side or upward or toward the observer, this was considered a positive change and highlighted in red. While points which changed their position, as a result of surgery, toward the left side or downward or away from the observer, were considered as negative changes and were highlighted in blue. Green colour was for the regions where no changes were detected in response to Le Fort I osteotomy. The intensity of the colour indicated the magnitude of the change at the examined region (figure 3). The colour bar categorises the changes into the central green colour (zero movement), the red part of the scale with yellow, orange, red and dark red, correspond to 0.5mm, 1mm, 1.5mm and >2mm movements respectively. The blue part of the scale with sky blue, sea blue, blue and dark blue correspond to 0.5mm, 1mm, 1.5mm and >2mm movements respectively.

Since the initial stage of generic mesh conformation required the manual digitization of 20 anatomical landmarks, a landmarking error study was carried out by repeating the digitisation process of five facial meshes, by the same operator, at two weeks interval.

Results

Table (1) shows mean and standard deviation of the repeated measurements at each of the 20 landmarks. The error ranged from $(0.22\text{mm}\pm 0.17\text{mm})$ to $(1.24\text{mm}\pm 0.79\text{mm})$ with a mean of $(0.56\text{mm}\pm 0.31\text{mm})$.

The average antero-posterior surgical movement of the maxilla was the advancement of $5.9\text{mm}\pm 1.7\text{mm}$ with minor anterior and posterior vertical maxillary impaction of $0.1\text{mm}\pm 1.7\text{mm}$ and $0.6\text{mm}\pm 1.45\text{mm}$ respectively, there was a minimal lateral displacement of $0.04\text{mm}\pm 0.9\text{mm}$. The associated mandibular autorotation produced an advancement of $2.8\text{mm}\pm 2.1\text{mm}$ with vertical upward displacement due to mandibular autorotation of $2.1\text{mm}\pm 1.8\text{mm}$ with a minimal lateral shift of $0.2\text{mm}\pm 0.9\text{mm}$.

Figure 2 shows the colour coded distance map based on the Euclidian distance between the corresponding vertices of the average 3D facial images before and after surgery.

1. **The nose:** The nasal bridge area showed no changes due to surgery, whereas the difference gradually increased toward the nasal cartilage and the tip of the nose. The most obvious changes in response to surgery were observed at the alar cartilage which was highlighted in red, the intensity of the red colour increased close to the nasolabial groove. This indicates widening of the nostrils following Le Fort I surgery. The region at the columella and the lower part of the nasal tip was highlighted in blue which indicates an inward and or upward movement toward the geometric centre of the face secondary to Le Fort I osteotomy.
2. **The upper lip:** The upper lip region is bounded by the nasolabial junction superiorly, extends to the inferior end of the vermillion border and to the

oral commissures bilaterally. The majority of the region showed a uniform dark red highlight which indicates a marked forward displacement in the upper lip region in response to surgery. A change in colour to light green at the commissures was observed which indicated the limited effect of the maxillary advancement on this region.

3. **The lower lip:** the region of the lower lip is anatomically bounded by the upper border of the lower lip vermilion border superiorly, extends to the labiomental fold inferiorly and to the oral commissures laterally. The majority of this region displayed a light red highlight due to the slight forward displacement at the lower lip. A colour change into a light blue at the area below the vermilion border extending to the labiomental fold downward and about 50% of the lip width was observed which indicates a backward and or upward displacement of the lower lip at this region.
4. **The chin:** The chin area extends from the labiomental fold to the lower border of the face and extends laterally to the area marked by an imaginary vertical lines descending from the oral commissures. The majority of the area was highlighted in red which appeared darker centrally at the pogonion region. A blue strip at the lower border of the chin was also observed (figure 2A). This together with the red colour at 'pogonion' point indicates a minor combined upward and forward change at chin region.
5. **Para nasal regions:** The red colour display forward displacement extended bilaterally to the nose and limited laterally to a vertical line from the outer canthai. Superiorly, there was a display of the red colour immediately below the malar eminence which extended down to the level of the oral commissures.
6. **The cheeks:** The light red colour highlight in this area indicates a minor forward change in response to maxillary surgery. A change to the blue colour at the lower border was noted. This was continuous with the strip of blue colour below the chin area. These findings indicated a minor upward movement of the soft tissue at the lower border of the mandible associated with the shortening of the lower facial height.

Soft tissue changes in X direction (Medio-lateral direction)

Figure (3) shows the soft tissue surface changes in the x direction only. Minimal changes were noted around the eye regions and the nasal bridge; these were highlighted in green. The colour changed to yellowish red toward the nasal tip. A mixed yellow and orange colour patch on the right side at the lower part of the dorsum of the nose and a blue colour patch on the right side indicate a minor narrowing of the nose at this region in response to Le Fort I osteotomy. The right ala of the nose displayed a blue colour while the left ala of the nose displayed a red colour, indicating widening of the nostrils. The alar base region displayed a light yellow colour indicating a minimal change in response to Le Fort I osteotomy, this might be due to the effect of nasal cinching which was performed during surgery in all cases.

Most of the soft tissue changes in response to Le Fort I osteotomy were in the region of the upper lip and paranasal area. This was demonstrated by the well-defined distribution of the red colour on the left side and the blue colour on the right side of these two regions which indicates a tendency toward lateral expansions along these anatomical regions. The changes were limited to the anatomical boundaries of the paranasal region and upper lip. The changes at the oral commissures at the corners of the mouth, the lower lip and the chin were minimal.

Soft tissue changes in Y direction (Vertical change)

Figure (4) shows the vertical component of soft tissue changes in the Y direction (vertical) only in response to Le Fort I osteotomy. Most of the region around the eyes and the nasal bridge displayed green colour which confirms the minimal vertical changes in these areas. The dorsum of the nose showed minimal change and displayed a green strip which extended toward the tip of the nose. The tip of the nose, the right and left alar curvatures and the collumella showed a marked upward movement which displayed a distinctive red colour.

The paranasal areas showed a homogenous but small upward movement coinciding with the adjacent cheek areas which displayed a predominantly yellow colour. The

upper lip displayed mostly green colouration with small patches of mixed yellow and orange colours. This indicates a minimal vertical displacement of the upper lip in response to Le Fort I maxillary advancement. The lower lip showed two types of response to maxillary surgery, the region above the vermillion border showed minimal vertical change highlighted in green to light yellow, the region below the vermillion border showed a clear vertical change, it displayed red colour with a central dark red patch. This indicates an upward movement in this region and reduction of the lower lip length. However the chin area showed a distinctive and well defined dark red colour with less density posteriorly toward the cheek areas on both sides, which is indicative of an upward movement of the chin area secondary to Le Fort I maxillary osteotomy.

Soft tissue changes in Z direction (Antero-posterior changes)

Figure (5) shows the soft tissue changes in the Z direction. The region around the eyes and the nasal bridge showed minimal change. A change to yellow colour was evident at the nasal tip. The columella together with the right and left alae of the nose, showed a well-defined dark red colour indicating a marked forward movement of this region in response to Le Fort I maxillary osteotomy.

A well-defined dark red region covered the upper lip and the bilateral paranasal regions was detected which indicates a marked forward displacement in response to surgery. The colour was confined to the anatomical boundaries of these two regions. The effect of surgery on the commissures at the corner of the mouth was minimal which displayed as a yellow/green colour. The lower lip showed a predominantly green colour with a red stripe on the vermillion border close to the oral fissure (mouth opening). The chin showed a relatively homogenous, mostly orange in colour which indicates a moderate forward displacement. Similar changes were evident on the cheeks where the colour intensity reduced posteriorly.

In summary, there were a distinctive forward soft tissue movements combined with a marked lateral expansion at the upper lip and paranasal regions; the changes were limited by the anatomical boundaries of these regions (Figure 6).

The commissures showed minor changes in all dimensions. The effect extended to the chin area where a marked vertical and to a lesser extent, forward displacement were evident. The lower lip showed minimal changes in all dimensions except a marked vertical movement at the region between the vermilion borders and the labiomental fold. The effect on the nose was limited to the widening and advancement of the nostrils as well as the base of the nose (Subnasale and alar base) region with a minimal forward change but a noticeable upward movement at the nasal tip. The changes at the cheeks were to a lesser extent, with minor but consistent upward and forward movements.

Discussion

Inter-surface distance measurements in a form of colour distance map, have been commonly used as a descriptive analysis in conjunction with other measurement types.¹⁷ This was mainly due to the absence of information related to the 3D directional changes. The earlier landmark based analysis helped in identifying the direction of the displacement at selected regions¹⁶⁻¹⁹ but it was difficult to determine the extent of these changes. Researchers modified this approach to overcome this problem, four horizontal and two vertical planes were anatomically oriented to segment the facial surface into ten regions.²⁰ The method provided additional regional information without the need for landmarking. However, the segmentation process did not reflect true anatomical regions of the face. It was also assumed that most of the changes were in the A-P direction. The same study commented on the region of lower lip and chin as areas associated with minimal changes. On the other hand, they suggested a significant change in upward direction of the submandibular region. The reason behind this discrepancy is the method of evaluation, the authors applied the closest surface distance analysis which is not particularly sensitive to detect 3D surface mesh sliding that may have occurred at the lower lip and chin area. In our study, anatomical correspondence (dense correspondence analysis) solved this problem by providing the actual correspondence for each vertex rather than using the closest distance correspondence between the matched 3D facial surfaces which improved the reliability of the measurements.

Figure 2 showed a satisfactory accuracy of superimposing the average preoperative 3D facial image and the postoperative one which is demonstrated by the predominant green colour of the areas which were not affected by surgery including the orbital regions. The method applied in this study detects sliding of 3D facial meshes during image superimposition which was completely overlooked in the previous classical colour surface analysis. Figure 7 showed the difference between the two analyses (the closest point analysis and the corresponding distances) for the same average face mesh following Le Fort I advancement osteotomy. Figure 7A shows clearly that major areas around the cheeks, nose and chin were completely overlooked or misinterpreted when the closest surface distance was applied for facial analysis. Figure 7B shows the extensive changes involving chin, cheeks and nose region in response to surgery.

It is pertinent to emphasise that the blue colour patch on the forehead is the result of the mathematical facial averaging process of the preoperative and the postoperative 3D facial images, these areas were not affected by surgery.

The subdivision of the soft tissue response to Le Fort I osteotomy into the three main directions of movements was innovative and provided an unprecedented insight to the understanding of facial changes in response to surgery. Most of previous studies focused on the A-P changes at the mid-facial region²¹⁻²⁷, other directional changes of facial soft tissue in response to surgery were largely overlooked. The four striking features observed in this analysis were the lateral stretching and expansion of the upper lip and paranasal areas; the limited change of the lower lip and oral commissures; the vertical and forward chin movement due to minor mandibular autorotation and lastly the shortening of the nostril height associated with flaring of the alar cartilages.

The detected changes in X direction on the nose, including the widening of the nostrils is in agreement with the vast majority of previous published studies.^{2,20,28-30} However, this effect was more evident at the alar curvature than the alar base. The nasal cinch stitch which was applied in all the cases might have reduced the alar base width but was not lateral enough to control the width of the alar cartilages. This observation was in agreement with Metzler et al 2014 who also

reported on the increase in the philtrum width following Le Fort I osteotomy.²³ This was contrary to our findings. The reason behind this disagreement was that in their study the philtrum width was measured as the linear distance between the two oral commissures. Our findings suggest that Le Fort I osteotomy has a limited effect at these regions.

Limited anterior and posterior vertical skeletal maxillary displacement ($0.1\text{mm}\pm 1.7\text{mm}$ and $0.6\text{mm}\pm 1.45\text{mm}$ respectively) was confirmed in this study sample. Soft tissue vertical displacement was only observed at the nostrils and chin. Minimal vertical changes were observed at the upper lip region (within 0.5mm). This was combined with a relatively higher upward displacement observed at the nasolabial junction and subalar area. The combined observations led to the conclusion there was an increase in lip length following Le Fort I maxillary advancement, partially due to the V-Y lip closure, which is in agreement with previous studies⁽³¹⁾. The lower lip on the other hand showed a generalised upward displacement in response to Le Fort I osteotomy. However, the changes at lower lip vermilion border were minimal ($0\text{mm}-0.5\text{mm}$), this observation led to the conclusion there was shortening of the lower lip secondary to mandibular autorotation as a result of posterior maxillary impaction.

The red colour at the nostrils and nasal tip suggested an upward movement of this region secondary to Le Fort I advancement osteotomy. This result was in agreement with most previous studies.^{22,29}

In the Z direction there was an obvious forward movement of the mid face region at the upper lip, paranasal areas and nostrils with a lesser extent at the chin region and were in agreement with previous studies.^{2,20}

Interestingly, the tip of the nose did not show significant change in the antero-posterior direction; this was associated with a significant forward displacement of the alar cartilages and columella of the nose. The combined effect in the x y and z direction of Le Fort I osteotomy could be described as compression of the nostrils in the antero-posterior direction which were expressed as shortening of the collumella and widening of the alar cartilage curvature. This result was in partial

agreement with previous studies which suggested shortening of the nostrils and increase of the alar width.^{22,32} However, the majority of the studies observed a significant forward shift of the nasal following Le Fort I osteotomy(32-34). The reason behind this disagreement might be the removal of the anterior nasal spine which was performed during surgery in all the cases.

The bilateral group of muscles of facial expressions which originated from the side of the bridge of the nose, played a marked role in the expression of the overlying soft tissue changes. These include the *levator labii superioris alaeque nasi* and from the zygomatic bone including *zygomatico major*, *zygomatico minor* and *levatorlabiisuperioris muscles* are inserted in the fascia of the upper lip and the muscle fibres of the *orbicularis oris* muscle. This group of muscles were stretched by the advancement of the maxilla, which contributed to the augmentation of the relatively depressed paranasal region. The impact of Le Fort I maxillary osteotomy was limited superiorly by the origin of these muscles and laterally by anterior superficial fibres of *masseter* muscle which were not affected by the surgery.

Conclusions

Dense anatomical surface correspondence is a novel method which produced a comprehensive visual analysis of the changes in response to Le Fort I osteotomy. It is possible to separate soft tissue changes into x, y and z directions. Le Fort I advancement osteotomy widened the mid-face and upper lip, compressed and widened the nostrils and shortened the lower lip. The effect of surgery may extend to the chin and lower lip secondary to posterior maxillary impaction.

Legends of the figures:

Figure 1 The right hand coordinate system

Figure 2 Dense anatomical correspondence showing soft tissue changes following Le Fort I maxillary advancement surgery

Figure 3 corresponding soft tissue changes in X dimension

Figure 4 corresponding soft tissue changes in Y dimension

Figure 5 corresponding soft tissue changes in Z dimension

Figure 6 3D image of one of the cases showing the impact of Le Fort I osteotomy of the facial soft tissue

Figure 7. A comparisons between classical colour map on the left showing the areas of differences according to the closest surface distance method. The image on the left demonstrates the surgical changes measured by the corresponding differences of the same two images.

References

1. Baik H-S, Jeon J-M, Lee H-J. Facial soft-tissue analysis of Korean adults with normal occlusion using a 3-dimensional laser scanner. *Am J Orthod Dentofacial Orthop* 2007;**131**:759-66.
2. Baik H-S, Kim S-Y. Facial soft-tissue changes in skeletal Class III orthognathic surgery patients analyzed with 3-dimensional laser scanning. *Am J Orthod Dentofacial Orthop* 2010;**138**:167-78.
3. Luximon Y, Ball R, Justice L. The Chinese face: a 3D anthropometric analysis. *Proceeding of the TMCE2010* 2010.
4. Toma M, Zhurov A, Playle R, Ong E, Richmond S. Reproducibility of facial soft tissue landmarks on 3D laser-scanned facial images. *Orthod Craniofac Res* 2009;**12**:33-42.
5. Fuyamada M, Nawa H, Shibata M, Yoshida K, Kise Y, Katsumata A. Reproducibility of landmark identification in the jaw and teeth on 3-dimensional cone-beam computed tomography images. *Angle Orthod* 2011;**81**:843-9.
6. Kau CH, Richmond S, Zhurov A, Ovsenik M, Tawfik W, Borbely P. Use of 3-dimensional surface acquisition to study facial morphology in 5 populations. *Am J Orthod Dentofacial Orthop* 2010; **137**(4 Suppl):S56.e1-9.
7. Zhurov A, Playle R, Richmond S. S Richmond A three-dimensional look for facial differences between males and females in a British-Caucasian sample aged 15½ years old. *Orthod Craniofac Res* 2008;**11**:180-5.
8. Stephen R, Ovsenik N. Facial Morphology of Slovenian and Welsh White Populations Using 3-Dimensional Imaging. *Angle Orthod* 2009;**79**:640-5.
9. Heymann GC, Cevidanes L, Cornelis M, De Clerck HJ, Tulloch JFC. Three-dimensional analysis of maxillary protraction with intermaxillary elastics to miniplates. *Am J Orthod Dentofacial Orthop* 2010;**137**:274-84.
10. Verzé L, Bianchi FA, Schellino E, Ramieri G. Soft tissue changes after orthodontic surgical correction of jaws asymmetry evaluated by three-dimensional surface laser scanner. *J Craniofac Surg* 2014;**23**:1448-52.
11. Miller L, Morris DO, Berry E. Visualizing three-dimensional facial soft tissue changes following orthognathic surgery. *Eur J Orthod* 2014;**29**:14-20.

12. Claes P, Walters M, Improved JC. Improved facial outcome assessment using a 3D anthropometric mask. *Int J Oral Maxillofac Surg* 2012;**41**:324-30.
13. Mao Z, Ju X, Siebert PJ, W. Cockshott P, Ayoub A . Constructing dense correspondences for the analysis of 3D facial morphology. *Pattern Recognition Letters* 2006;**27**:597-608.
14. Claes P, Walters M, Vandermeulen D, Clement JG. Spatially-dense 3D facial asymmetry assessment in both typical and disordered growth. *J Anat* 2011;**219**:444-55.
15. Walters M, Claes P, Kakulas E, Robust JGC. Robust and regional 3D facial asymmetry assessment in hemimandibular hyperplasia and hemimandibular elongation anomalies. *Int J Oral Maxillofac Surg* 2013;**42**:36-42.
16. Almkhatar A, Khambay B, Ayoub A, Ju X, Al-Hiyali A, Macdonald J. “Direct DICOM Slice Landmarking” A Novel Research Technique to Quantify Skeletal Changes in Orthognathic Surgery. *PLoS One* 2015;**10**:e0131540.
17. Kim B-R, Oh K-M, Cevidanes LHS, Park J-E, Sim H-S, Seo S-K. Analysis of 3D soft tissue changes after 1- and 2-jaw orthognathic surgery in mandibular prognathism patients. *J Oral Maxillofac Surg* 2013;**71**:151-61.
18. Oh K-M, Seo S-K, Park J-E, Sim H-S, Cevidanes LHS, Kim Y-JR Post-operative soft tissue changes in patients with mandibular prognathism after bimaxillary surgery. *J Craniomaxillofac Surg* 2013;**41**:204-11.
19. Nkenke E, Vairaktaris E, Kramer M, Schlegel A, Holst A, Hirschfelder U. Three-dimensional analysis of changes of the malar-midfacial region after LeFort I osteotomy and maxillary advancement. *Oral Maxillofac Surg* 2008;**12**:5-12.
20. Verdenik M, Ihan Hren N. Differences in three dimensional soft tissue changes after upper, lower or both jaw orthognathic surgery. *Int J Oral maxillofac Surg* 2014;**43**:1345-51
21. Soncul M, Bamber MA. Evaluation of facial soft tissue changes with optical surface scan after surgical correction of Class III deformities. *J Oral Maxillofac Surg* 2004;**62**:1331-40.
22. Vasudavan S, Jayaratne YSN, Padwa BL. Nasolabial Soft Tissue Changes After Le Fort I Advancement. *J Oral Maxillofac Surg* 2012;**70**:e270-7.
23. Metzler P, Geiger EJ, Chang CC, Sirisoontorn I, Steinbacher DM. Assessment of three-dimensional nasolabial response to Le Fort I advancement. *J Plast Reconstr Aesthet Surg* 2014;**67**:756-63.
24. Carlotti AE, Aschaffenburg PH, Schendel S. Facial changes associated with surgical advancement of the lip and maxilla. *J Oral Maxillofac Surg* 1986;**44**:593-6.

25. Ko EW-C, Figueroa A, Polley JW. Soft tissue profile changes after maxillary advancement with distraction osteogenesis by use of a rigid external distraction device: A 1-year follow-up. *J Oral Maxillofac Surg* 2000;**58**:959-69.
26. Legan H. An evaluation of soft-tissue changes resulting from Le Fort I maxillary surgery. *Am J Orthod* 1983; **84**:37-47.
27. Louis PJ, Austin RB, Waite PD, Mathews CS. Soft tissue changes of the upper lip associated with maxillary advancement in obstructive sleep apnea patients. *J Oral Maxillofac Surg* 2001;**59**:151-6.
28. Ubaya T, Sherriff A, Ayoub A, Khambay B. Soft tissue morphology of the naso-maxillary complex following surgical correction of maxillary hypoplasia. *Int J Oral Maxillofac Surg* 2012;**41**:727-32.
29. Dantas WRM, da Silveira MMF, do Egito Vasconcelos BC, Porto GG. Evaluation of the nasal shape after orthognathic surgery. *Braz J Otorhinolaryngol* 2015;**81**:19-23.
30. Van Loon B, van Heerbeek N, Bierenbroodspot F, Verhamme L, Xi T, de Koning MJJ, et al. Three-dimensional changes in nose and upper lip volume after orthognathic surgery. *Int J Oral Maxillofac Surg* 2015;**44**(1):83-9.
31. Park S-B, Kim Y-I, Hwang D-S, Lee J-Y. Midfacial soft-tissue changes after mandibular setback surgery with or without paranasal augmentation: cone-beam computed tomography (CBCT) volume superimposition. *J Craniomaxillofac Surg* 2013;**41**:119-23.
32. Agur AMR, Dalley AF. *Grants Atlas of Anatomy* 2013; 13th Ed. 13th ed. Wolter Kluwer;PP

Table 1 Mean of the landmarking distance error

	Landmark acronym	Landmark name	Mean	SD
1	Ex(R)	Exocanthion-R	0.24	0.17
2	En(R)	Endocanthion-R	0.47	0.5
3	Na	Nasion	0.44	0.25
4	Ex(L)	Exocanthion-L	0.27	0.31
5	En(L)	Endocanthion-L	0.24	0.18
6	Ab(R)	Alar base-R	0.23	0.17
7	Prn	Pronasale	0.41	0.3
8	Ab(L)	Alar base-L	0.28	0.12
9	Sn	Subnasale	0.35	0.31
10	Ch(R)	Cheilion-L	0.54	0.3
11	Fl(R)	Philtrum crest-R	0.53	0.29
12	Ls	Labial superius	0.75	0.37
13	FL(L)	Philtrum crest-L	0.3	0.16
14	Ch(L)	Cheilion-L	0.75	0.3
15	Li	Labial inferius	0.91	0.47
16	Mid Ls-Ch(R)	Mid way SL(R) to Ch(R)	1.13	0.34
17	Mid Ls-Ch(L)	Mid way SL(R) to Ch(L)	1.25	0.79
18	Mid Li-Ch(R)	Mid way SL(R) to Ch(R)	0.92	0.41
19	Mid Li-Ch(L)	Mid way SL(L) to Ch(R)	0.63	0.29
20	Pog	Pogonion	0.68	0.37
Mean			0.57	
SD			0.31	

Table 1 Mean of the landmarking distance error

	Landmark acronym	Landmark name	Mean	SD
1	Ex(R)	Exocanthion-R	0.24	0.17
2	En(R)	Endocanthion-R	0.47	0.5
3	Na	Nasion	0.44	0.25
4	Ex(L)	Exocanthion-L	0.27	0.31
5	En(L)	Endocanthion-L	0.24	0.18
6	Ab(R)	Alar base-R	0.23	0.17
7	Prn	Pronasale	0.41	0.3
8	Ab(L)	Alar base-L	0.28	0.12
9	Sn	Subnasale	0.35	0.31
10	Ch(R)	Cheilion-L	0.54	0.3
11	Fl(R)	Philtrum crest-R	0.53	0.29
12	Ls	Labial superius	0.75	0.37
13	FL(L)	Philtrum crest-L	0.3	0.16
14	Ch(L)	Cheilion-L	0.75	0.3
15	Li	Labial inferius	0.91	0.47
16	Mid Ls-Ch(R)	Mid way SL(R) to Ch(R)	1.13	0.34
17	Mid Ls-Ch(L)	Mid way SL(R) to Ch(L)	1.25	0.79
18	Mid Li-Ch(R)	Mid way SL(R) to Ch(R)	0.92	0.41
19	Mid Li-Ch(L)	Mid way SL(L) to Ch(R)	0.63	0.29
20	Pog	Pogonion	0.68	0.37
Mean			0.57	
SD			0.31	

Figure 1

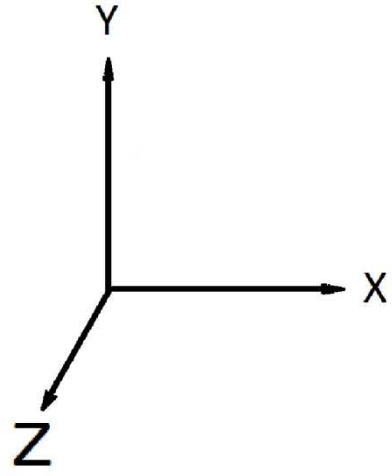


Figure 2

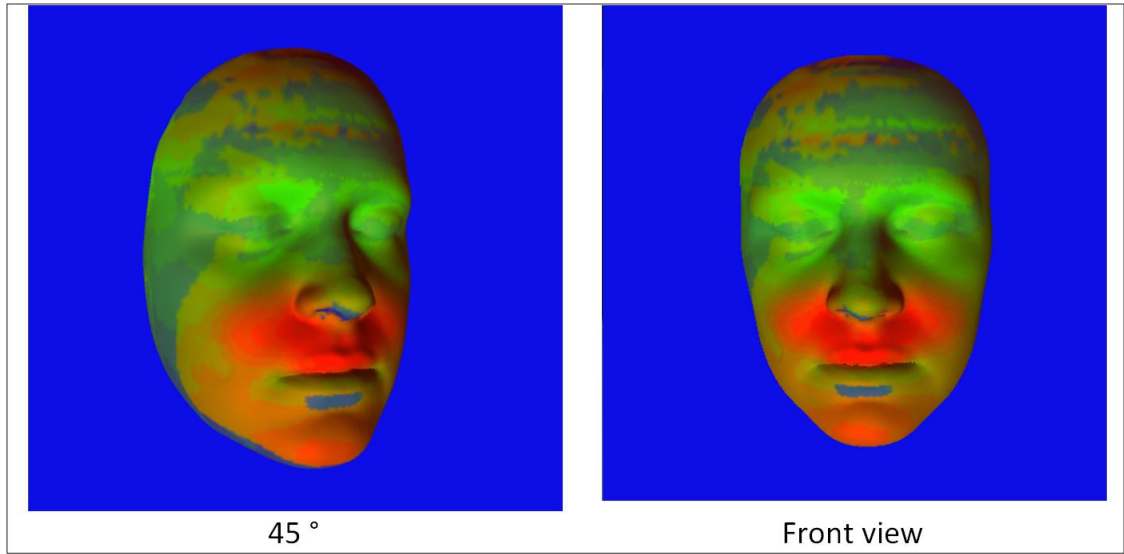


Figure 3

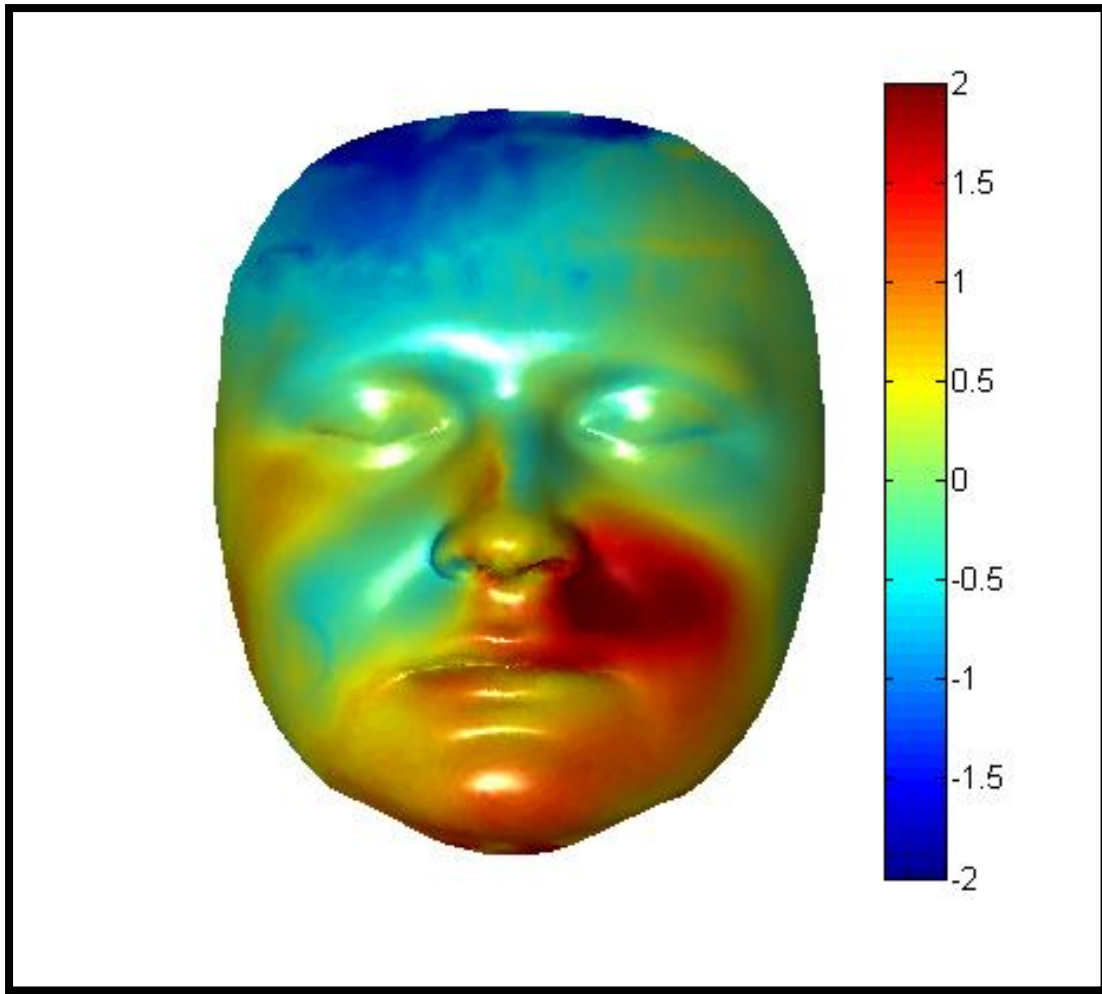


Figure 4

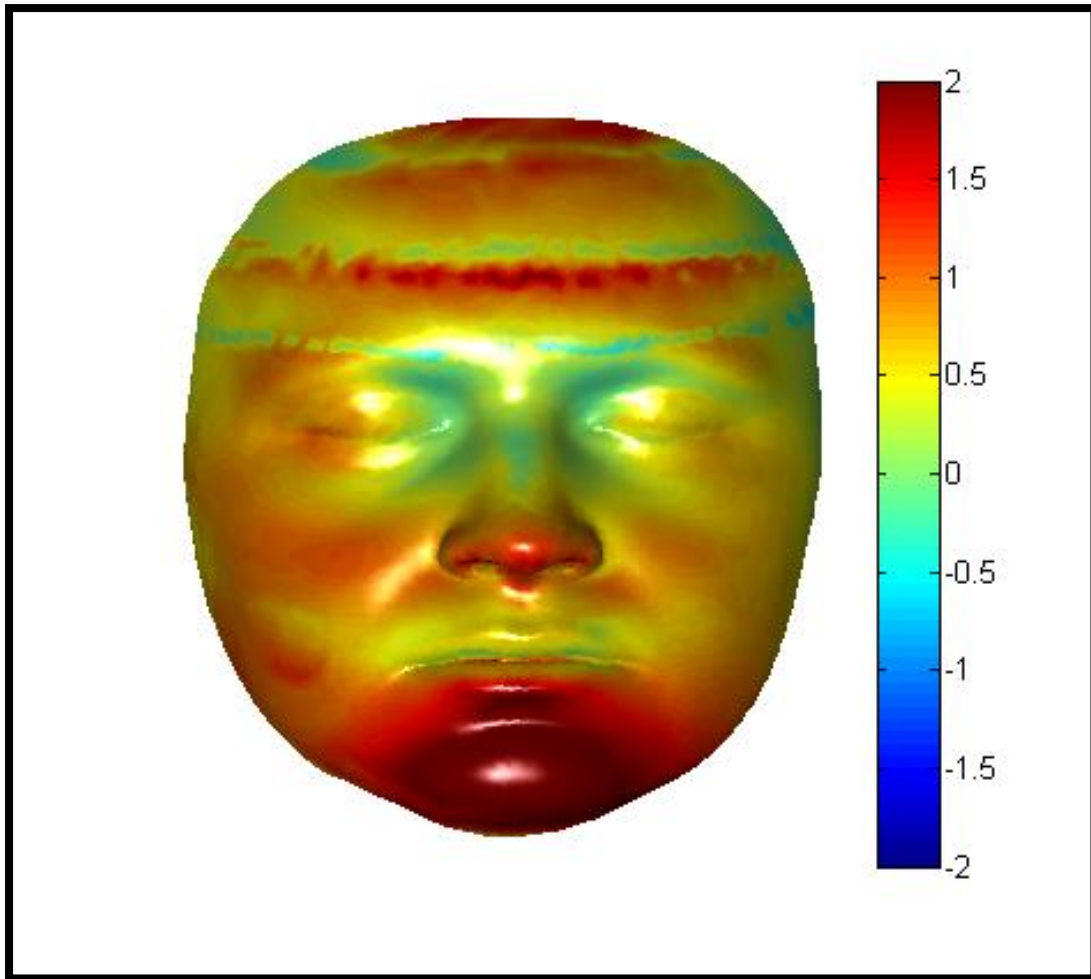


Figure 5

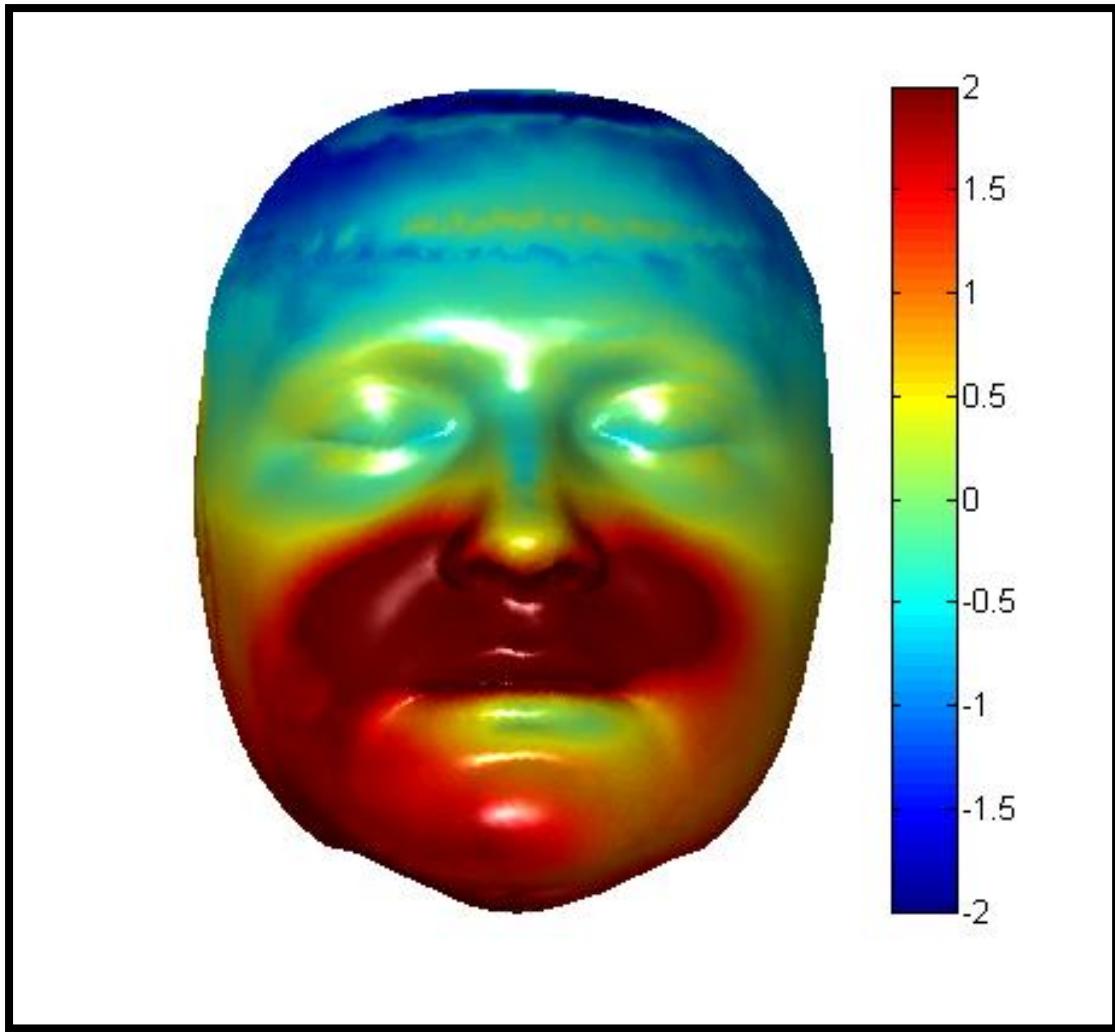
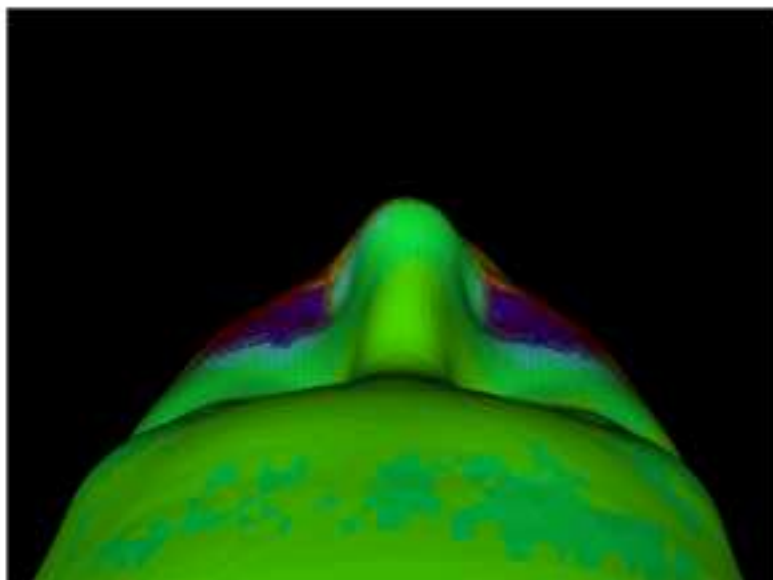
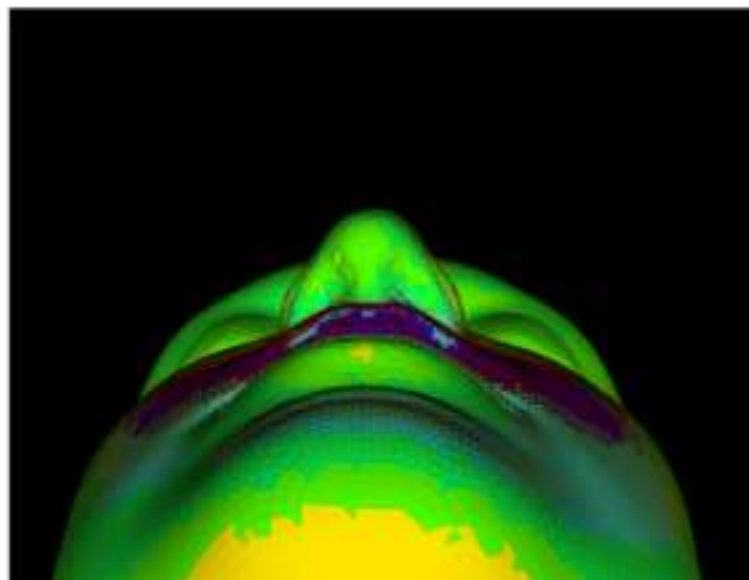


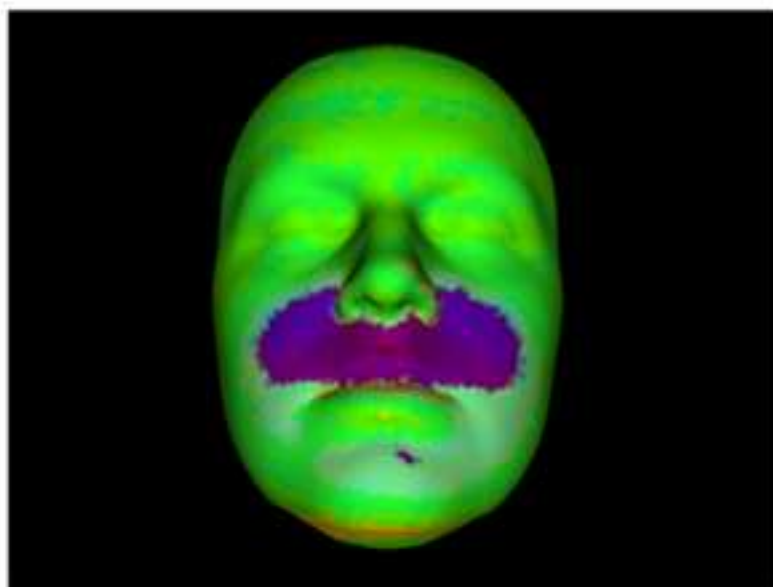
Figure 6
[Click here to download high resolution image](#)




Top View



Bottom view



Front view



Lateral view

Figure 7

