



Deposited via The University of Sheffield.

White Rose Research Online URL for this paper:

<https://eprints.whiterose.ac.uk/id/eprint/89068/>

Version: Accepted Version

Article:

Sandler, J., Benson, P.E., Doyle, P. et al. (2007) Palatal implants are a good alternative to headgear: A randomized trial. *American Journal of Orthodontics and Dentofacial Orthopedics*, 133 (1). 51 - 57. ISSN: 0889-5406

<https://doi.org/10.1016/j.ajodo.2007.04.032>

Reuse

Items deposited in White Rose Research Online are protected by copyright, with all rights reserved unless indicated otherwise. They may be downloaded and/or printed for private study, or other acts as permitted by national copyright laws. The publisher or other rights holders may allow further reproduction and re-use of the full text version. This is indicated by the licence information on the White Rose Research Online record for the item.

Takedown

If you consider content in White Rose Research Online to be in breach of UK law, please notify us by emailing eprints@whiterose.ac.uk including the URL of the record and the reason for the withdrawal request.

Palatal implants – The Chesterfield Study

P.J. Sandler
P.E. Benson
P.Doyle
J.J. O'Dwyer
A Majumder
P. Speight
B.Thiruvengkatachari
D. Tinsley

Address for correspondence:

Mr P J Sandler
Chesterfield Royal Hospital
Chesterfield
S44 5BL
United Kingdom

JonSandler@AOL.com

Keywords: RCT; Palatal implants; Headgear; Orthodontics; Anchorage

Abstract

Objective: To compare the efficiency and effectiveness of the mid-palatal implant with headgear as methods of supplementing anchorage during orthodontic treatment.

Design: A prospective, randomized, clinical trial

Setting: Chesterfield and North Derbyshire Royal Hospital NHS Trust and the Charles Clifford Dental Hospital, Sheffield.

Subjects and Methods: 51 orthodontic patients between the ages of 12 and 39, with 'absolute anchorage' requirements were randomly allocated to either receive a mid-palatal implant or headgear to reinforce orthodontic anchorage. The outcome measures of the trial were surgical and orthodontic success rates of the implants, the number of visits and length of time of treatment, the success of treatment as judged by PAR score reductions and the patients attitude to implant placement.

Results:

Surgical success rate of implants was 75% and the orthodontic success rate was >90%. In this study both implants and headgear also proved to be an effective method of reinforcing anchorage. The total number of visits was greater in the implant group but the overall treatment times were almost identical. There were no statistically significant differences between the two groups in the PAR scores either at the start of, or at the end of treatment and the % PAR score reductions were almost identical. Patients had no problems whatsoever accepting mid palatal implants as a method of reinforcing anchorage.

Conclusions: Mid-palatal implants are an acceptable technique for reinforcing anchorage in the orthodontic patient and are a good solution for patients who do not wish to wear headgear.

Introduction

Since Creekmore and Radney first presented their paper in the JCO in 1984¹ there has been increasing interest in the use of metal implants in orthodontics. Many papers have been written which feature mid-palatal implants or micro-screws to assist a variety of tooth movements. Metal on-plants and bone plates have also been used successfully to provide a rigid site from which force can be delivered to the teeth with the aim of avoiding unwanted movement of the anchorage unit.

Headgear has also been shown to be a very effective method of supplementing anchorage in orthodontic patients but the technique is not without its disadvantages. Cases of 'eye-damage' have been documented² and many efforts have been made to increase the safety of this technique³.

Mid-palatal implants as a source of anchorage were first described in the mid 90s⁴ and further skull studies were carried out to look at the appropriateness of the mid palatal area for the placement of these fixtures⁵.

Much has been written on the use of metal implants as a method of supplementing anchorage. As clinicians practicing in the 21st Century it is incumbent upon us to practice, as far as is possible, evidence-based medicine. Before embarking on the wholesale prescription of a new technique it is important to evaluate the quality of evidence available to support its use.

An excellent systematic review was published as a Masters Thesis⁶ in 2005 which evaluated the evidence for the use of implants in orthodontics, using the Cochrane systematic methodology. All the papers published in English speaking journals up until 2004 were electronically searched on both the MEDLINE and the EMBASE databases, in addition all English speaking journals on orthodontics, dentistry and implantology were hand searched. References of all research trials were also checked and letters sent to all authors on implant related papers asking for other unpublished data. Unpublished studies were sought by trawling the journals and conference proceedings. Implant manufacturers were also written to for details of all research being carried out in the subject of implant anchorage.

A total of 157 papers on implants were identified and 90 were immediately excluded as non-relevant citations and out of the 67 left, which were evaluated in detail, 57 were excluded as being inappropriate for evaluation as according to the predetermined checklist. Of the final 10 papers scrutinised against the checklist, every single paper was excluded from the meta-analysis as it did not reach the high standards set out by the Cochrane collaboration. It was against this background of a serious lack of scientific evidence for the use of implants in orthodontics that we set up the Chesterfield implant study.

Method and Materials

Patients assessed at Chesterfield Royal Hospital and Sheffield Dental Hospital as having 'absolute anchorage' requirements, were invited to take part in this Randomised Controlled

Trial for which ethical approval had been obtained in the usual manner. The clinical requirement was defined as patients in whom forward movement of the molar teeth on one or both sides of the upper arch would prevent achievement of the desired occlusal result. A number of exclusion criteria existed and included: unsatisfactory oral hygiene, unwillingness to accept the treatment modality to which they were assigned and a Medical History precluding fixed appliance therapy.

Start records were obtained for all patients, and if felt suitable for inclusion, the study was described in detail to the patients and in addition written information was given to them outlining what would be involved. The patients were then reviewed a couple of weeks later to see if they wished to be involved. If they did, written consent was obtained and they were then randomly allocated to either the Headgear or the Implant group.

Block randomisation involved computer generated random numbers and a sealed envelope was given to the patients detailing which group they were allocated to, once consent had been obtained. 42 patients were recruited at Chesterfield and 9 at Sheffield and the two groups were treated to a similar standard at both centres, the only difference between the patients being the method of anchorage reinforcement used.

Headgear group – a Nitom³ safety headgear bow was used connected to a snap-away headcap to deliver the extra-oral forces to the upper molar teeth. The headgear direction chosen was that thought appropriate to the patients clinical situation and 450 grams force was

applied on fitting. The patients were given detailed instructions in the use of headgear and were asked to wear the headgear for 100-120 hours per week. Headgear charts were provided for all patients and the patients were reviewed regularly to check co-operation and comfort with headgear wear. Extractions were only prescribed once the level of cooperation with headgear had been ascertained.

Implant group – a Straumann mid-palatal implant[®] was placed by one of two maxillofacial surgeons using a standardised technique involving radiographic and surgical stents⁷. The implant was then left for a period of 3 months to integrate, after which the fixed appliances were placed for the patient and the implant was used with a variety of palatal arches to supplement the anchorage.

An implant questionnaire was given to the patients both immediately following the implant placement and on removal of the implant. The patients were asked to indicate on the form the grade they would assign to the surgery from 1 - indicating totally comfortable, to 6 – very uncomfortable. They were also asked to grade discomfort over the few days following the surgery and were invited to make comments on the form, about their impressions of the procedure.

The standard approach to fixed appliance treatment involved .016 and 18/25 Nickel Titanium aligning archwires followed by 19/25 Stainless Steel working archwires and the majority of cases were finished using .016 regular Stainless Steel.

Outcome measures

The aspects of treatment in which the authors were particularly interested were:

- did the patients complete the treatment
- the overall quality of treatment as measured by the Peer Assessment Rating (PAR),
- the treatment process including duration of treatment and the number of 'extra' visits
- the patients perception of the treatment (particularly how they cope with the placement and removal of the palatal implants)
- the cephalometric changes as assessed by the modified Pancherz analysis

Results

Who was included in the study?

In total 51 patients were included, 25 randomly allocated to the Headgear group and 26 allocated to the Implant group. Female patients accounted for 38 subjects; 20 allocated to the Headgear group and 18 were allocated implants. Of the 13 males, 6 had headgear and 7 were in the implant group. The average age of patients in the study was 15.2 years (Headgear average 14.8, implant average 15.7) with a range of 12-39.

How many patients completed treatment?

Two patients, having been randomly assigned to the implant group, dropped out before the implant treatment actually started (one moved out of the area and one family was splitting up). There were two other patients assigned to the implant group whose implants failed to

osseointegrate on two consecutive occasions. For these two patients an alternative approach to treatment had to be decided. Patient D.G. ended up with a compromise extraction pattern involving a second premolar on one side and a canine on the other side of the upper arch and patient M.Y. swapped to headgear as the method of supplementing anchorage.

Patient S.R. dropped out of the study before headgear treatment was started (as her family was moving out of the area). As far as Headgear is concerned, there were three 'failures'; patient H.D. swapped over to an implant as the method of providing anchorage and there were two 'compromise' extraction patterns after it was evident that headgear was not going to provide sufficient anchorage. Patient K.T. had both upper lateral incisors extracted and A.R. had both upper canines extracted (Figure 1).

Did the treatment process differ between groups?

With the headgear group the average number of visits per course of treatment was 19 compared to 26 with the patients who had been randomly allocated to the implant group (Table 1). Despite this the total active treatment times were almost identical at 2.23 years for the headgear group and 2.15 years with the implant group. The mean number of unscheduled visits was 1 with the headgear group and 1.55 with the implant group

Were there any differences between the cephalometric analyses?

A modified Pancherz cephalometric analysis (Figure 2) was used to assess dental and skeletal changes in the two groups. The maxillary position was assessed by measuring the distance

from A point to a constructed vertical line through Sella and the implant group showed an average -0.7mm (range -0.4 to 0.0) compared with the headgear group who showed +0.3mm (range -0.8 to 1.3).

The mandibular base was assessed by measuring Pogonion to the constructed vertical and the implant group changed on average 0.2mm (Range 2.8 to 4.23) and the headgear group 1.7mm (Range 0.1 to 3.3).

As far as molar changes were concerned the maxillary molars moved forwards 1.5mm (range 0.4 to 2.7) in the Implant group and 3mm (Range 1.6 to 4.5) in the Headgear group. The mandibular molars moved forwards 2.9mm (range 1.8 to 4.0) in the Implant group and 3.4mm (Range 2.0 to 4.8) in the Headgear group. None of the treatment changes between the two groups were statistically significantly different and these have been reported in more detail elsewhere⁸.

Was the quality of treatment different between the groups?

The PAR score is now an accepted method of assessing malocclusion both at the start and at the end of treatment as well as assessing the quality of the improvement as a result of treatment. The PAR scores at the start of treatment were 35.9 for the Headgear group and 35.7 for the Implant group. At the end of treatment the PAR scores were 6.73 for the Headgear group and 7.38 for the Implant group. Both groups therefore fell within the 'greatly improved' category at 78.08% reduction in the Headgear group and 78.33% reduction in the

Implant group. The statistical significance was investigated using an independent sample t-test and it was seen that there were no statistically significant differences between the results (Table 2).

How reliable are the implants?

Twenty five patients were originally randomised to this group and 23 actually started treatment. The mean age of the implant group was 15.7 with a range of 12-39 years.

There were six 'surgical' failures prior to orthodontic loading and therefore the surgical success rate was 74%.

All six patients in whom the first implant failed, opted to have a second implant placed and four of the replacement implants osseointegrated successfully. The 'orthodontic success rate' of implants could therefore be argued to be greater than 90% as only two of the implant patients out of 23 did not end up with implant assisted supplementation of anchorage.

How did the patients feel about the implants?

On the six point scale from 1 – comfortable to 6 – uncomfortable 75% of the respondents scored between 4 and 6, i.e. the comfortable end of the scale for implant placement, and not one patient scored 1 indicating that the placement of implants was generally acceptable to the patients.

These scores were repeated when the patients were asked to assess the comfort over the first 3 days i.e. 75% scored 4-6 at the comfortable end of the spectrum and none scored 1.

On implant removal the questionnaire was again distributed and 40% scored 5, 40% 3, 20% 1 indicating that implant removal was found to be slightly less comfortable than implant placement.

Discussion

It was with some trepidation that the authors (PJS and DT) approached the Chesterfield Local Research and Ethics Committee asking for approval to place implants in the jaws of children. Surprisingly to us, the assembled group of experts had no problem whatsoever with the concept of intra-oral titanium implants being placed under local anaesthesia. They expressed some reservations however about the use of headgear after they heard about some of the problems that have been encountered in the past using this particular technique. They wondered if headgear, with its rare but potentially damaging side effects, will continue to get ethical committee approval once there is scientific evidence of an acceptable alternative.

The headgear patients in the study surprised the clinicians with the speed and efficiency of this method of anchorage supplementation. In some cases the headgear was discontinued after as little as five months and on average headgear was continued for 9 months. What we feel we were witnessing was the 'Hawthorne effect'. This phenomenon was originally described by a Professor from Harvard Business School after studying the workers of the Western Electric Company of Cicero, Illinois He noticed that the attitudes of the employees to their working conditions changed noticeably and he felt this was a direct result of them being included within the study. We feel that because so much time had been spent with all the

patients both in advance of the randomisation, explaining the RCT, explaining the randomisation, getting written consent and then afterwards collecting detailed documentation of their response to treatment, that they were motivated to cooperate beyond the level that clinicians we would normally have expected. Maybe the answer with all our headgear patients is to spend significantly more time with them trying to achieve a similar level of enthusiasm and motivation as witnessed in this particular study.

It also came as some surprise, the ease with which the patients accepted the relatively new technique involving mid-palatal implants. Perhaps the patients just see it is an extension of the trend towards lip, nose, and tongue studs as well as eyebrow and other body part piercing. Certainly this theory is strengthened by the 6 implant patients who have, at the end of treatment, refused to have the implant removed preferring to keep it in place. As far as the placement of the implant was concerned, it was a technique that was readily accepted by children as young as 12 years of age. Most patients indicated there was no real pain, rather a feeling of discomfort for the two or three days after the surgery and a few patients just commented that the implant felt 'bulky' and temporarily interfered with speech.

The majority of the 'failed' first implants were the earlier ones placed and it could well be that there is also a learning curve for the surgeons with this relatively new technique. All implant workers stress the need for slow drill speeds, Straumann recommend a maximum drill speed of 700rpm, and copious irrigation during the preparation of the implant site and placement of the implant. This is felt to significantly lower the temperature in the surrounding bone which is

meant to increase chances of true osseointegration. Ground sections were carried out for six of the implants and each implant sectioned showed intimate approximation of the cancellous bone with the threads screws, suggestive of successful osseointegration (Figure 3).

The 6mm implants with a 2.5mm neck length were used in the majority of the cases however on four occasions the 'emergency' implant was required. The indication for the emergency implant is when primary stability with the usual 3.3mm diameter implant is unobtainable, due to slight over drilling of the implant site. The 'emergency' implant is 4.0mm diameter and primary stability was achieved in all four cases.

The implant cases were all reviewed at three days, one week, at three weeks and again at six weeks. Five of the six failed implants were noticed to be slightly loose at 3 weeks and in only one case was it not recorded as being loose until the 12 week follow up appointment. With every one of the failed implants, the screw was simply unscrewed from the soft tissues. On no occasion was local anaesthetic required for removal, nor did the patients experience any discomfort during the procedure and the tissues healed uneventfully in every case. At this stage the patients were given a choice of another approach to management of the anchorage either headgear or alternative extractions and every patient wanted the implant procedure to be repeated, indicating the universal acceptability of the technique. No implants, identified as firm at 12 weeks, failed subsequently under orthodontic forces.

Patients reported slightly more discomfort on implant removal than on implant placement and six patients expressed a preference to keep their implants in place. The usual disclaimers were issued warning the patients about the possibility of infection around this fixture however their wishes were, of course, respected. They were all told to return immediately if they experienced any problems around the implant.

In any 'intention to treat' analysis it is important to report on every case. A number of cases were listed as failed headgear or failed implant cases. This doesn't mean for a moment that they were a 'failed' orthodontic treatment as can be seen in Figure 1. A more than satisfactory aesthetic and functional result was still obtained in these cases by altering the extraction pattern to reduce the reliance on the randomly chosen method of anchorage supplementation e.g extraction of canines or lateral incisors.

The one big difference between the two groups was the number of treatment appointments, with a significantly higher number in the implant group (Table 1). This was totally expected, as with this new technique the patients were required to see the surgeons for a pre-operative check as well as the appointment for surgery. We were keen to identify if, and when, the implants became loose therefore all implant patients were all seen at three days, 1,3,6 and 12 weeks after implant placement. They also had an additional visit for implant removal. Despite the increased number of visits the total treatment time was almost identical between the two groups.

The palatal arches used to attach the implants to the teeth varied throughout the study. We began the study using palatal arches bonded to the premolars. These were easy for the technician to construct however the problem was that they tended to debond thus allowing the posterior teeth to come forwards (Figure 4). Bands soldered to molar teeth were also tried however these were difficult to place unless the 'path of insertion' of the two bands were not only similar to each other but also similar to the path of insertion of the internal hexagon on the implant abutment over the implant. The method of attachment we found to be most successful was use of the 'Lingual Hinge Cap Assembly'[®] produced by Ormco (Figure 5). This attachment was easy to make, versatile and allowed easy discontinuation of the anchorage supplementation when appropriate. It also allowed 'Distal Jet's' to be used if distalisation of the molar tooth was required (Figure 6) and allowed a simple palatal arch to control all movement of the molars.

Conclusions

1. No statistically significant difference in PAR score reduction existed between Headgear and Implant cases
2. Treatment times were similar between Headgear and Implant cases
3. Spending time with patients who require Headgear may elicit the 'Hathorne' effect
4. The lingual Hinge Cap is the best attachment to use with palatal arches from implants
5. Mid-palatal implants are an acceptable technique for anchorage reinforcement
6. The patient may not want the implant removed after treatment
7. Surgical success rate is 75% however orthodontic success rate is >90%

8. Osseointegration after 12 weeks is unlikely to subsequently fail
9. Failed implants simply unscrew from the soft tissues
10. This study offers a scientific basis for the use of mid-palatal implants for anchorage reinforcement in orthodontics

Acknowledgements

We would like to thank the Straumann company for their generous support of this study, the British Orthodontic Society for awarding the Houston prize to Dr Tinsley in 2002, Chesterfield Royal Hospital for the 2004 research bursary which also supported this study. Thanks are due to Dr Paul Speight for producing the ground sections and Dr B.Thiruvengkatachari for help with the statistics.

References

1. Creekmore, T.D. and M.K. Eklund, *The possibility of skeletal anchorage*. J Clin Orthod, 1983. **17**(4): p. 266-9.
2. Booth-Mason, S. and D. Birnie, *Penetrating eye injury from orthodontic headgear-a case report*. Eur J Orthod, 1988. **10**(2): p. 111-4.
3. Samuels, R.H. and M.L. Jones, *Orthodontic facebow injuries and safety equipment*. Eur J Orthod, 1994.
4. Wehrbein, H., et al., *The use of palatal implants for orthodontic anchorage. Design and clinical application of the orthosystem*. Clin Oral Implants Res, 1996. **7**(4): p. 410-6.

5. Wehrbein, H., J. et al *Appropriateness of mid palate – a clinical and radiological study Eur J Orthod* 1999: 65-70.
6. R M Skeggs *A Systematic Review of Surgical Reinforcement of Anchorage during Orthodontic Treatment*: Submitted MSc Thesis, University of Sheffield 2005
7. Tinsley, D., et al., *Orthodontic palatal implants: clinical technique*. J Orthod, 2004. **31**(1): p. 3-8.
8. Benson P.E. et al., *Mid-Palatal Implants for Orthodontic Anchorage– a Randomized Clinical Trial*: Am J Orthod and Dento Orthop – Accepted for publication

Table 1 Process of treatment

	IMPLANT GROUP		HEADGEAR GROUP		95% Confidence Interval		P Value
	Mean	Std. Deviation	Mean	Std. Deviation	Lower	Upper	
Duration of Treatment	2.15	0.59	2.23	0.62	-0.28	4.34	0.667
Casualties	1.26	1.25	1.54	1.92	-0.70	1.26	0.561
Failed appointments	1.55	2.83	1.00	1.64	-2.01	.92	.450
Number of Visits	26.21	7.49	19.20	4.58	-10.70	-3.31	.000

Table 2- independent sample t-test for par scores

	IMPLANT GROUP		HEADGEAR GROUP		95% Confidence Interval		<i>P</i> Value
	Mean PAR Score	Std. Deviation	Mean PAR Score	Std. Deviation	Lower	Upper	
PAR Score before treatment	35.67	8.78	35.91	14.05	-6.97	7.46	.946
PAR Score after treatment	7.38	4.23	6.73	4.71	-3.41	2.10	.634
PAR Score Difference	28.29	8.07	29.09	14.49	-6.43	8.04	.822

Figure 1 'Failed' headgear treatment

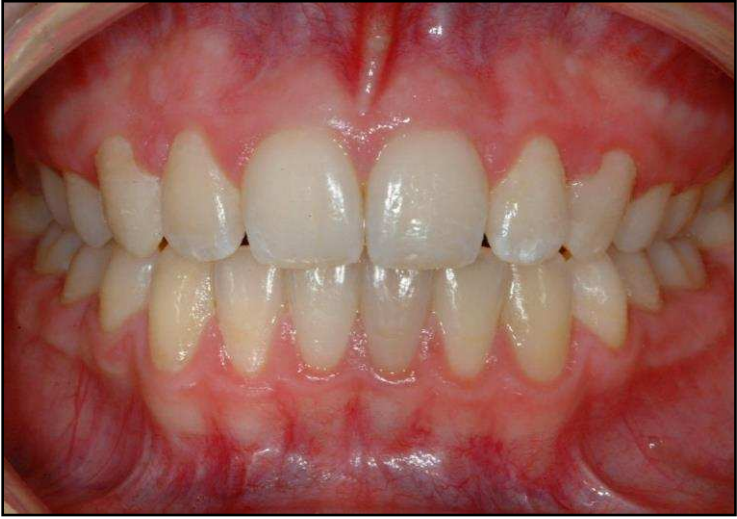

Figure 2 Modified Pancherz Analysis

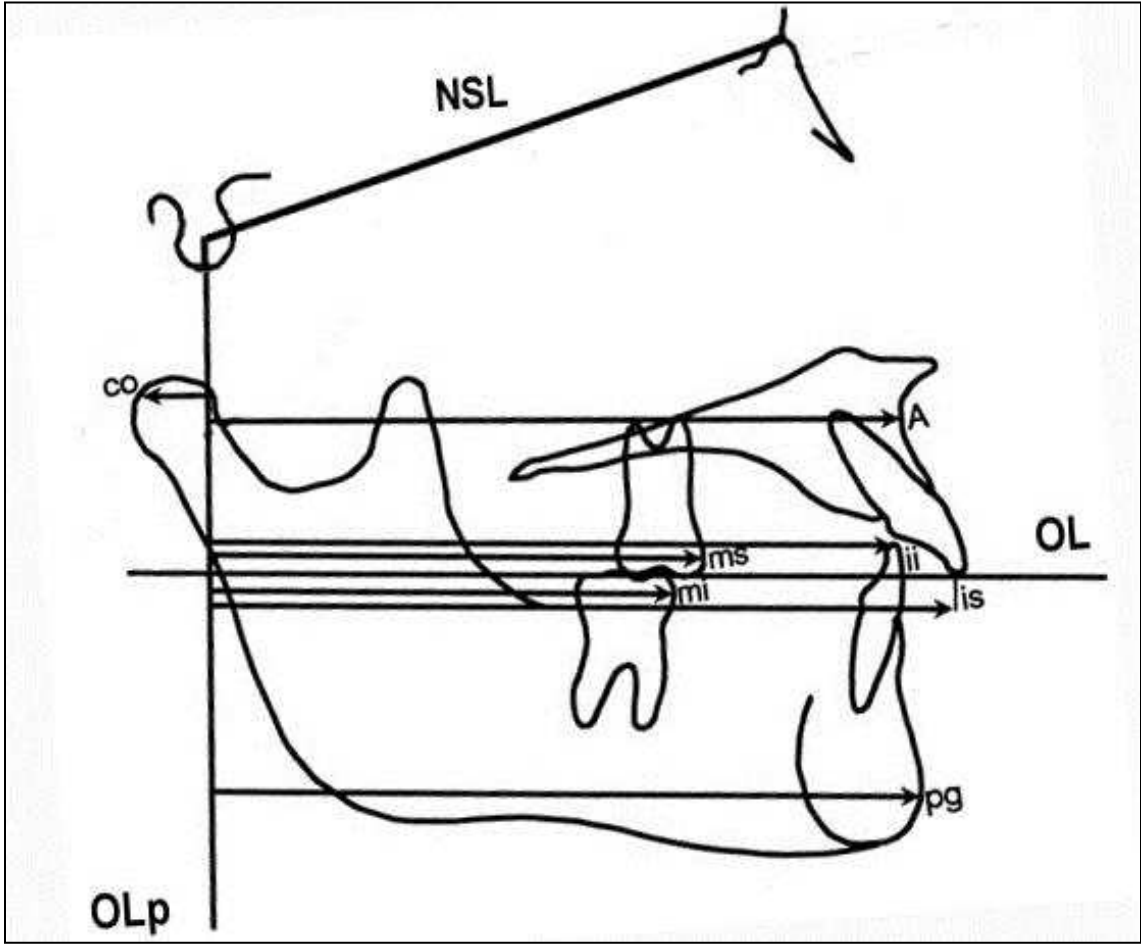


Figure 3 Ground section: Tight proximity between implant threads and cancellous bone indicating effective Osseointegration

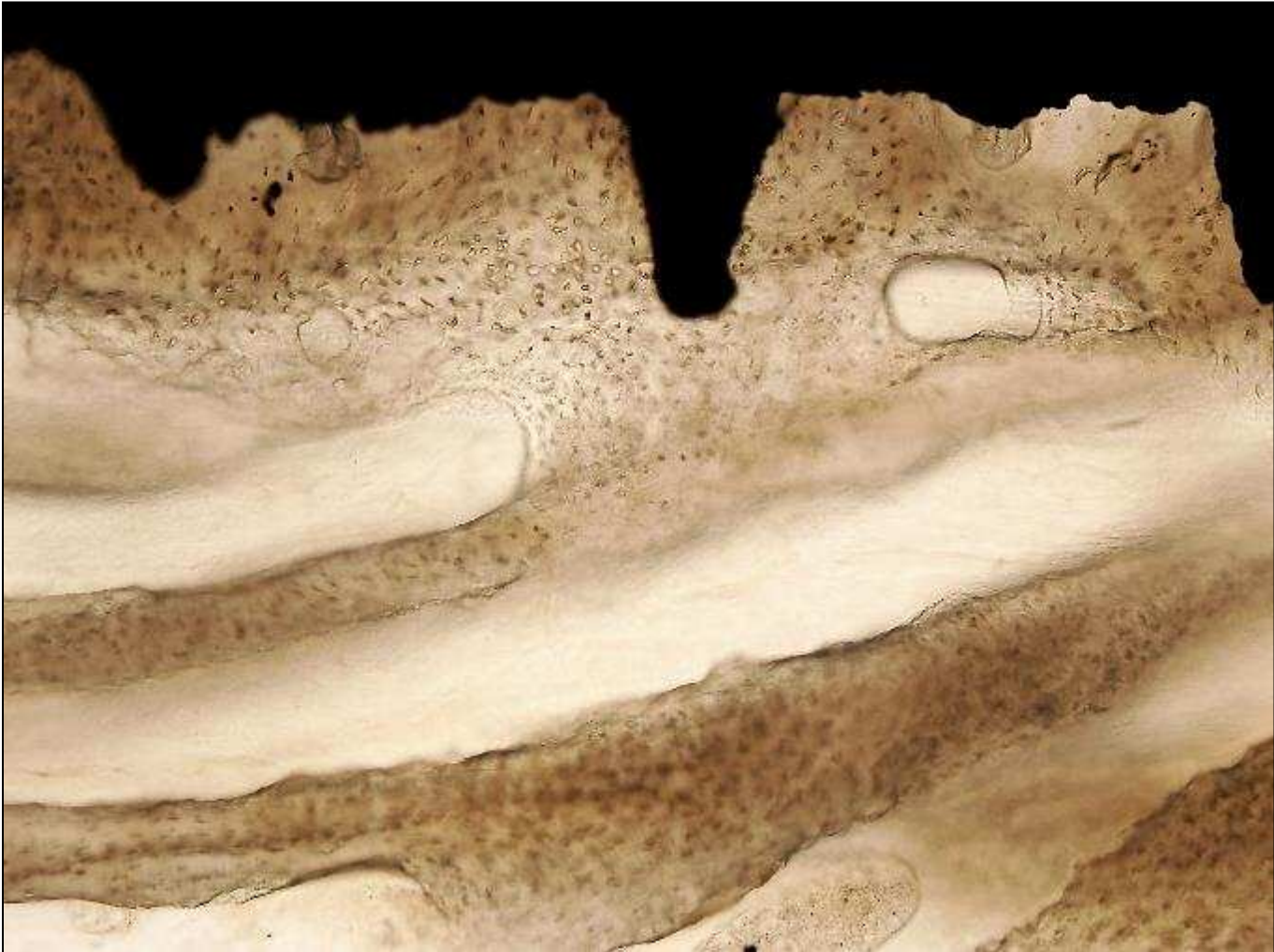


Figure 4. Bonded palatal arch, loss of anchorage on right where premolar bond has failed

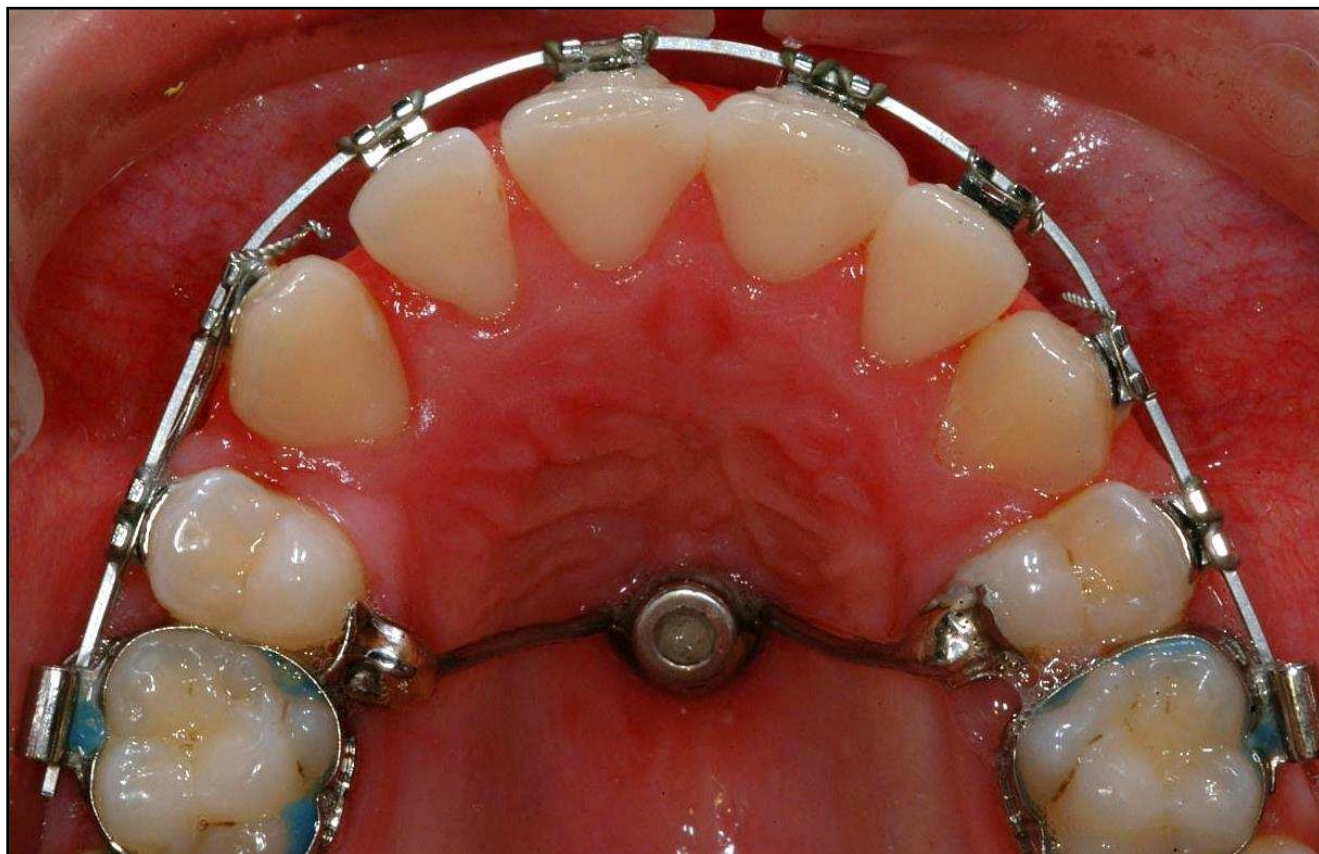

Figure 5. Lingual Hinge Cap assembly from Ormco.

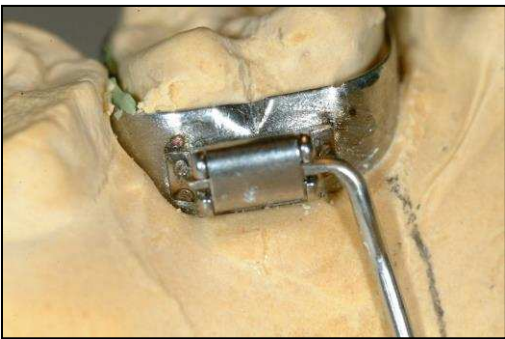



Figure 6 Distal-jets to distalise 6s, attached via lingual hinge caps

