



Deposited via The University of Leeds.

White Rose Research Online URL for this paper:

<https://eprints.whiterose.ac.uk/id/eprint/87032/>

Version: Accepted Version

Article:

Rowbotham, EL, Freeston, JE, Emery, P et al. (2015) The prevalence of tenosynovitis of the interosseous tendons of the hand in patients with rheumatoid arthritis. *European Radiology*. ISSN: 0938-7994

<https://doi.org/10.1007/s00330-015-3859-0>

Reuse

Items deposited in White Rose Research Online are protected by copyright, with all rights reserved unless indicated otherwise. They may be downloaded and/or printed for private study, or other acts as permitted by national copyright laws. The publisher or other rights holders may allow further reproduction and re-use of the full text version. This is indicated by the licence information on the White Rose Research Online record for the item.

Takedown

If you consider content in White Rose Research Online to be in breach of UK law, please notify us by emailing eprints@whiterose.ac.uk including the URL of the record and the reason for the withdrawal request.

The prevalence of peri-tendinous inflammation of the interosseous tendons of the hand in patients with rheumatoid arthritis

Emma L Rowbotham FRCR

Musculoskeletal Radiology Department, Leeds Teaching Hospitals NHS Trust

Jane E Freeston FRCP

Consultant Rheumatologist and Honorary Senior Lecturer,
Leeds Teaching Hospitals NHS Trust

Paul Emery MA MD FRCP

Arthritis Research UK Professor of Rheumatology Leeds
Musculoskeletal Biomedical Research Unit, LTHT Leeds
Institute of Rheumatic Musculoskeletal Medicine University of
Leeds

Andrew J Grainger FRCR

Department of Musculoskeletal Radiology, Leeds Teaching
Hospitals Trust, Leeds NIHR Leeds Musculoskeletal Biomedical
Research Unit, Chapel Allerton Hospital, Leeds

This is an original research paper

Leeds Biomedical Medical Research Unit Chapel Allerton
Hospital Leeds Teaching Hospitals Trust Leeds

LS7 4SA

(0113) 392 4474 Corresponding author –
emmarowbotham@nhs.net

The prevalence of tenosynovitis of the interosseous tendons of the hand in patients with Rheumatoid Arthritis

Abstract:

Aim: The aim of this study was to establish the prevalence of tenosynovitis affecting the interosseous tendons of the hand in a rheumatoid arthritis (RA) population; also to assess for association with metacarpophalangeal (MCP) joint synovitis, flexor tendon tenosynovitis or ulnar drift.

Methods: 44 patients with RA underwent MRI of the hand along with 20 normal controls. Coronal 3D T1 VIBE sequences pre and post contrast were performed and reconstructed. The presence of interosseous tendon tenosynovitis was recorded alongside MCP joint synovitis, flexor tendon tenosynovitis and ulnar drift.

Results: 21 (47.7%) patients with RA showed interosseous tendon tenosynovitis. 52 (14.8%) interosseous tendons showed tenosynovitis amongst the RA patients. Interosseous tendon tenosynovitis was more commonly seen in association with adjacent MCP joint synovitis ($p < 0.001$), but 9 MCP joints (5.1%) showed adjacent interosseous tenosynovitis in the absence of joint synovitis. Interosseous tendon tenosynovitis was more frequently seen in fingers which also showed flexor tendon tenosynovitis ($p < 0.001$) and in patients with ulnar drift of the fingers ($p = 0.01$).

1
2 **Conclusion**
3

4 Tenosynovitis of the hand interosseous tendons was found in 47.7% of patients
5
6
7 with RA. In the majority of cases this was adjacent to MCP joint synovitis;
8
9
10 however, interosseous tendon tenosynovitis was also seen in isolation.
11
12
13
14
15
16
17
18

19 **Key Points:**
20

- 21
22 1. Tenosynovitis of the interosseous tendons of the hand occurs in
23
24 rheumatoid arthritis
25
26
27 2. Interosseous tendon tenosynovitis has a prevalence of 47.7% in patients
28
29 with RA
30
31
32 3. Interosseous tendon tenosynovitis is related to MCP joint synovitis in the
33
34 adjacent joints
35
36
37
38

39 **Keywords:** Rheumatoid Arthritis; interosseous tendons;Magnetic Resonance
40

41 **Imaging**
42
43

44 **Inflammation; synovitis**
45
46
47
48
49
50
51
52
53
54
55
56
57
58
59
60
61
62
63
64
65

The prevalence of tenosynovitis of the interosseous tendons of the hand in patients with Rheumatoid Arthritis

Introduction:

Synovitis of the joints of the hands is the characteristic abnormality in patients with rheumatoid arthritis (RA) [1]. Tendon disease, including tenosynovitis, tendinopathy and tendon rupture are also well-recognized findings in this condition occurring frequently in both the hands and the wrist. Tenosynovitis of both the flexor and extensor tendons is common and well documented with a reported incidence in RA patients of approximately 48% [2, 3]. Indeed it has recently been reported to be the first sign of pathology in the pre-clinical phase of RA [3, 4]. Tendinopathy is linked to an increased risk of tendon rupture which in turn can contribute to deformity and abnormal angulation at the small joints. Imaging is usually employed in cases of inflammatory arthropathy, being objective and more sensitive than clinical examination [5-7]. Conventional radiographs, ultrasound and MRI may all be used both for diagnostic purposes, and as a means of assessing disease progression and response to treatment. Ultrasound and MRI are both able to demonstrate associated tenosynovitis in the flexor and extensor tendons, although the sensitivity of MRI for this form of the disease has been shown to be higher [2].

The interosseous muscles of the hand arise from the metacarpal shafts and insert variably onto the proximal phalanx of each finger, the extensor hood and the volar plate through a short tendon [8] (Figure 1). There are four dorsal and three palmar interosseous muscles which act through their respective tendons across the metacarpo-phalangeal (MCP) joints; their principal action is to abduct

1 (dorsal interossei) and adduct (palmar interossei) the digits. Each finger is
2 provided with two interosseous muscles. Abduction and adduction of the fingers
3 is described relative to the middle finger, which therefore only abducts and is
4 consequently served by two dorsal interosseous muscles. The index and ring
5 fingers each have a dorsal and a palmar interosseous muscle. The little finger has
6 a palmar interosseous muscle, but the place of the dorsal interosseous muscle is
7 taken by the abductor digiti minimi (ADM) muscle also acting through a short
8 tendon. Tenosynovitis associated with these interosseous tendons has not, to our
9 knowledge, been previously documented.

10 The aim of this study was to report the presence of interosseous tendon
11 tenosynovitis, a feature we have observed in patients with RA, and establish its
12 prevalence. Given the close relationship of the interosseous tendons to the joints
13 we also looked to see if inflammation involving the interosseous tendons existed
14 independently of joint synovitis. Finally, since the interosseous tendons are
15 responsible for abduction and adduction at the MCP joints and ulnar drift is a
16 recognised feature of RA [9, 10], we examined whether there was an association
17 between ulnar drift and tenosynovitis involving the interosseous tendons. Given
18 the action of ADM is to abduct the little finger, this was also assessed and the
19 term interosseous tendons is used to include the tendons of the dorsal and
20 palmar interosseous muscles, along with the tendon of ADM throughout this
21 paper.

Methods:

Patient population:

The study population comprised 44 patients with inflammatory arthritis fulfilling ACR/EULAR 2010 classification criteria [11] for RA and 20 control subjects. The control subjects were negative for rheumatoid factor and anti-citrullinated protein antibodies and had no history, symptoms or clinical evidence of inflammatory arthritis. All subjects had consented to inclusion and approval had been given by the local ethics committee. Two groups of patients were included. A group of newly diagnosed patients comprising 16 patients enrolled at the time of initial disease presentation and diagnosis who had not received disease modifying therapy. These patients had mean symptom duration of 15.4 months (3 to 33 months) before presentation. The remaining 28 patients comprised those with an established diagnosis of RA for at least 1 year, these patients had a mean disease duration from diagnosis of 11.2 years (range 1 to 24 years).

MRI scanning:

All patients and controls underwent MRI of the hand and wrist, selecting the most symptomatic side for imaging. MRI was undertaken on either a 1.5T Siemens Avanto or 3T Siemens Verio system (Siemens, Erlangen Germany), using a protocol which included pre and post contrast coronal 3D T1 spoiled gradient echo (VIBE) sequences, with isotropic voxels allowing subsequent reconstruction in three planes. The parameters for the VIBE sequences at 1.5T were Repetition Time (TR)=30ms, Echo Time (TE)=6.82ms and Flip Angle (FA)=30 degrees. For the 3T sequences these parameters were TR=12ms,

1 TE=3.06ms and FA=30 degrees. On both systems the voxel size was 0.5mm³. An
2 8 channel knee coil was used.
3
4
5
6

7 Image analysis:
8

9
10 Two experienced fellowship trained MSK radiologists independently reviewed
11 the MRI studies of all the subjects. The studies were presented in random order
12 and the observers were blind to disease status (control, newly diagnosed or
13 established RA). The presence or absence of tenosynovitis associated with the
14 interosseous tendons was recorded. This was defined as the presence of
15 enhancing tissue surrounding the tendon and evident in at least two planes. 8
16 tendons were evaluated in each hand, those of the dorsal interossei (1 to 4), the
17 palmar interossei (1 to 3) and the abductor digiti minimi. The observers were
18 careful to distinguish inflammatory change relating to the interosseous tendon
19 from synovitis in the adjacent MCP joints. However the presence or absence of
20 joint synovitis in the MCP joints adjacent to the interosseous tendons (index,
21 middle, ring and little MCP joints) was also recorded. Any discrepancies between
22 the observers were reviewed and agreed by consensus.
23
24
25
26
27
28
29
30
31
32
33
34
35
36
37
38
39
40
41

42 Tenosynovitis affecting the flexor tendons to the index, middle, ring and little
43 fingers was also recorded. This was identified as the presence of peritendinous
44 effusion and/or synovial proliferation with enhancement, and in keeping with
45 other published work was only recorded if visible over a length of 6 mm
46 [12](Figure 2). For the purposes of the study the flexor tendons were evaluated
47 distal to the carpometacarpal joints.
48
49
50
51
52
53
54
55
56

57 Angulation at the third MCP joint was measured on PA radiographs for each case.
58

59 An angle of greater than 10 degrees was recorded as ulnar drift in keeping with
60
61
62
63
64
65

1 definitions from previous work [13]. The Chi Squared test was used for statistical
2 analysis, and the kappa statistic was used to assess interobserver agreement.
3
4
5

6
7 **Results:**
8

9
10 The demographics for the control subjects and two patient groups (newly
11 diagnosed and established RA) are given in table 1.
12
13

14 Agreement between observers:
15

16
17 The two observers showed an excellent level of agreement for the identification
18 of interosseous tendon tenosynovitis: kappa (k) = 0.91, (Standard Error (SE) =
19 0.03). High levels of agreement were also seen for the assessment of metacarpal
20 phalangeal joint synovitis ($k=0.84$, $SE=0.03$) and flexor tendon tenosynovitis
21 ($k=0.84$, $SE=0.04$).
22
23
24
25
26
27
28
29
30
31

32 Interosseous tendon tenosynovitis:
33

34 Amongst the control group no tenosynovitis was identified involving the tendons
35 of the interosseous muscles.
36

37
38 21 of 44 (47.7%) patients showed tenosynovitis in one or more interosseous
39 tendons and/or in the ADM (Figure 3, 4 5). The majority of these patients
40 showed involvement of only 1 (7 patients) or 2 (8 patients) tendons, although 3
41 patients showed tenosynovitis in 4 tendons, 2 showed it in 5 tendons and 1
42 patient had involvement of 7 of the 8 tendons.
43
44
45
46
47
48
49
50

51
52 8 interosseous tendons in each hand meant that amongst the 44 patients there
53 were a total of 352 tendons. In the patient group 52 of 352 interosseous tendons
54 showed tenosynovitis (14.8%) (Table 2). The most commonly involved tendon
55 was that of the first dorsal interosseous. As can be seen from table 2 the
56
57
58
59
60
61
62
63
64
65

1 tenosynovitis was more prevalent in the patients with established RA (40/224
2 17.9%) compared to those with newly diagnosed disease (12/128 9.4%). No
3
4 cases of tendon rupture were identified
5
6
7
8
9

10 MCP joint synovitis:

11
12 Synovitis was seen in 96 (54.4%) of the 176 MCP joints in the patient group (39
13 of 44 patients). In the control group 7 MCP joints (8.8%) showed synovitis (4
14 subjects) (Table 3). Each finger MCP joint is associated with two of the
15 interosseous muscle tendons evaluated (Figure 1); these pass adjacent to the
16 joint capsule. In 35 (19.9%) MCP joints synovitis was seen along with
17 interosseous tenosynovitis in one or both of the adjacent interosseous tendons.
18
19 In 9 (5.1%) MCP joints (5 patients) one or both of the adjacent interosseous
20 tendons showed tenosynovitis with no evidence of inflammation in the MCP joint
21 itself. Interosseous tendon tenosynovitis was more frequently seen adjacent to
22 MCP joints with synovitis than those without ($p<0.001$).
23
24
25
26
27
28
29
30
31
32
33
34
35
36
37
38
39

40 Flexor Tendon tenosynovitis:

41
42 Amongst the patient group 74 of 176 (42.0%) flexor tendons showed
43 tenosynovitis (29 of 44 patients). One control subject showed flexor
44 tenosynovitis in a single tendon (Table 4). 26 (14.8%) fingers in the patient
45 group showed both flexor tenosynovitis and tenosynovitis in one or both of the
46 interosseous tendons. Interosseous tendon tenosynovitis without flexor tendon
47 tenosynovitis was seen in 18 (10.2%) fingers. Tenosynovitis in the interosseous
48 tendons was more frequently seen in fingers also showing flexor tenosynovitis
49 compared to those without ($p<0.001$).
50
51
52
53
54
55
56
57
58
59
60
61
62
63
64
65

1
2 Ulnar drift:
3

4
5 12 patients showed evidence of ulnar drift. Interosseous tendon tenosynovitis
6
7 was more commonly seen amongst patients with ulnar drift (9/12, 75%),
8
9 compared to patients with normal MCP joint alignment (10/32, 31%), p=0.01.

10
11 Ulnar drift was not seen amongst the control subjects.
12
13
14
15

16 17 **Discussion:**

18
19 The interosseous muscles of the hand have been described as the “foundation of
20
21 hand function” having an important role in finger balance, grip and pinch
22
23 function[14]. The complex distal insertions of the tendons from these muscles
24
25 into the extensor expansion of the fingers as well as into bone, have been the
26
27 subject of extensive study and it is clear that the view of the interosseous
28
29 muscles as merely acting to abduct and adduct the fingers is simplistic, with the
30
31 muscles also acting to assist with flexion at the MCP joints and extension of the
32
33 interphalangeal joints, balancing the actions of other muscles on the fingers [15].
34
35 There is little pathology related to these tendons and muscles documented in the
36
37 literature, dysfunction usually being the result of nerve palsy, ischaemic
38
39 contracture and fractures [15]. Overuse tendinitis of the interosseous muscles of
40
41 the hands, although relatively rare, is a recognised phenomenon and occurs as a
42
43 result of overuse usually related to occupation, for instance it is well described in
44
45 pianists. However, our study suggests that there is a high prevalence of
46
47 inflammation about the interosseous tendons in patients with RA, a phenomenon
48
49 that has not previously been recognized.
50
51
52
53
54
55
56
57
58
59
60
61
62
63
64
65

1 For the purposes of this study we have described the inflammatory change
2 associated with the tendons of the interosseous muscles and ADM as
3 tenosynovitis. However we recognise that the microstructure of these tendons
4 has not been well described despite the fact that several papers exist describing
5 the complex, and often very variable, tendon insertions [16]. It is therefore
6 unclear whether these tendons have a true tenosynovium or whether the
7 observation would be better described as paratenonitis, a term used for
8 inflammation around tendons without tendon sheaths such as the Achilles
9 tendon. Frequently tenosynovitis is also associated with fluid in the tendon
10 sheath and this was not a feature identified in association with any of the
11 interosseous tendons. However, further studies are needed to confirm the
12 presence or absence of a tenosynovium associated with these tendons before we
13 can be more specific as to the nature of the inflammation observed. The changes
14 we observed were of post-gadolinium contrast enhancement of the tissue
15 surrounding the tendons, similar to the well recognised appearance of enhancing
16 joint and tenosynovium. Further studies will determine whether these
17 abnormalities can be seen without the use of contrast medium; although a recent
18 report has highlighted the continued need for gadolinium contrast for the
19 sensitive and specific detection of synovitis and tenosynovitis in patients with
20 inflammatory arthritis [17].
21
22
23
24
25
26
27
28
29
30
31
32
33
34
35
36
37
38
39
40
41
42
43
44
45
46
47
48

49 We did not specifically interrogate either the myotendinous junction or the
50 enthesis and this may form the basis of further work in this area, particularly in
51 patients with seronegative arthritis. We acknowledge other limitations of this
52 study, which had the primary aim of identifying and describing an apparently
53 new finding in patients with RA. It was not possible to image all study subjects
54
55
56
57
58
59
60
61
62
63
64
65

1 on the same scanner due to constraints within our department. Protocols were
2 optimised to produce images of the same resolution on each system. It should
3
4 also be noted that both systems identified patients with interosseous
5
6
7
8
9 tenosynovitis.

10 A knee coil was used to image the hands in this study in accordance with our
11
12 departmental protocol for imaging the hand and wrist in rheumatoid arthritis.
13
14 This coil provides coverage of all the interphalangeal joints and the wrist joint in
15
16
17 a single field of view. However we recognise that higher resolution imaging of
18
19 the small interosseous tendons may be achieved with an optimised coil such as a
20
21
22 wrist coil. The potential for high resolution imaging with a surface coil in
23
24
25 arthritis of the hand has been demonstrated and represents a potential area for
26
27 further work to investigate the interosseous tendons in these conditions [18].

28
29 It is likely that tenosynovitis associated with the interosseous tendons may be a
30
31
32 cause of symptoms and therefore should be documented and potentially treated
33
34
35 with the same clinical importance as both joint synovitis and tenosynovitis
36
37
38 elsewhere in patients with inflammatory arthritis. Further studies in this area
39
40
41 with clinical correlation to symptoms are needed to determine whether this
42
43
44 phenomenon is symptomatic or not. It remains to be identified whether or not
45
46
47 the inflammatory change we report predisposes the affected tendon to
48
49
50 dysfunction or rupture. If this proved to be the case it may be a predisposing
51
52
53 factor for the development of hand deformities in patients with RA. None of the
54
55
56 cases in our study showed evidence of tendon rupture.

57 In the majority of cases synovitis was seen at the MCP joint adjacent to the
58
59
60 interosseous tendons displaying tenosynovitis. This is in keeping with previous
61
62
63 studies showing that, in patients with RA, pathology involving both the joints and
64
65

1 the tendons often coexists, particularly in advanced disease. Previous studies
2 have found that flexor and extensor tenosynovial inflammation is frequently
3 found adjacent to areas of synovitis at the wrist and it has been suggested that
4 inflammatory change within the tenosynovium mirrors that of the synovial
5 membrane, particularly in early disease [19]. We also found interosseous tendon
6 tenosynovitis was more likely to be seen in digits where there was also flexor
7 tendon tenosynovitis, than in those without. It is unclear from our data whether
8 inflammatory change associated with the interosseous tendons is a primary or
9 secondary phenomenon. However, it is important to recognize that we identified
10 9 cases of interosseous peri-tendinous inflammation without inflammation in the
11 adjacent MCP joint. This may be one explanation for the presence of MCP joint
12 symptoms in the absence of active joint synovitis using clinical or imaging
13 criteria. This is of particular relevance given the recent finding that flexor
14 tenosynovitis may be the first pathology in RA [3] [4].

15 We have also demonstrated that interosseous tendon tenosynovitis is more
16 frequently seen in patients with ulnar drift at the MCP joints. This may simply
17 reflect the increased severity of the disease in these patients or may be a
18 consequence of the increased mechanical stress consequent of ulnar drift.

19 In conclusion, we have identified the presence of enhancing tissue around the
20 tendons of the interosseous muscles in the hands of patients with both newly
21 diagnosed and established RA. This is felt to be inflammatory in nature, in
22 keeping with well-documented similar changes associated with other tendons in
23 patients with RA. While the significance of this observation remains to be
24 established it does have implications for those undertaking imaging of RA, both
25 as a potential further site for the detection of inflammation and as a pitfall if it is

1
2
3
4
5
6
7
8
9
10
11
12
13
14
15
16
17
18
19
20
21
22
23
24
25
26
27
28
29
30
31
32
33
34
35
36
37
38
39
40
41
42
43
44
45
46
47
48
49
50
51
52
53
54
55
56
57
58
59
60
61
62
63
64
65

confused with MCP joint synovitis. Given the close relationship of these tendons to the MCP joints, inflammation associated with the interosseous tendons may also be a cause of joint symptomatology in the absence of clinical or imaging evidence of joint inflammation. Further studies will elucidate whether there is a correlation with early morning stiffness of the hands, a characteristic feature of RA, which correlates poorly with synovitis [20].

Summary Statement: Tenosynovitis of the interosseous tendons of the hand is a newly described phenomenon in patients with RA. This is an important new finding which may potentially be symptomatic in patients previously thought to have painful MCP joint synovitis.

Figures:

Figure 1a Anatomy - Illustration of the anatomy of the dorsal interosseous tendons of the hand. This illustration demonstrates the origin of the interossei from the medial and lateral aspects of the metacarpals. The attachments into the extensor hood and proximal phalanx of each finger is also demonstrated. The little finger is abducted by the abductor digiti minimi (not shown).

Figure 1b Anatomy - Illustration of the anatomy of the palmar interosseous tendons. There are three palmar interossei which attach to the index, ring and little fingers. They are smaller than the dorsal interossei of the hand.

1
2
3
4
5
6
7
8
9
10
11
12
13
14
15
16
17
18
19
20
21
22
23
24
25
26
27
28
29
30
31
32
33
34
35
36
37
38
39
40
41
42
43
44
45
46
47
48
49
50
51
52
53
54
55
56
57
58
59
60
61
62
63
64
65

Figure 1c: Anatomy – axial MR image through the hand to illustrate the anatomy of the palmar (yellow arrows) and dorsal (red arrows) interosseous tendons on cross sectional imaging. The abductor digiti minimi is also shown (white arrow)

Figure 2 – Interosseous tendon tenosynovitis was defined as high signal change around the tendon on post contrast images (blue circle)

Figure 3 – Coronal reformat of the first dorsal interosseous tendon showing tenosynovitis. There is no adjacent MCP joint synovitis seen in this case.

Figure 4 - Axial post contrast image showing tenosynovitis of the fourth dorsal interosseous tendon (blue circle). A prominent erosion within the radial aspect of the ring finger metacarpal head (asterix) is seen in this patient with established RA. This patient also had MCP joint synovitis in all of the MCP joints (only fourth MCP joint synovitis seen on this figure - arrows)

Figure 5 - Axial post contrast image showing florid tenosynovitis of the index and ring finger flexor tendons and interosseous peri tendinous inflammation affecting the third palmar interosseous tendon (blue circle).

References:

1. Brook, A. and M. Corbett, *Radiographic changes in early rheumatoid disease*. Ann Rheum Dis, 1977. **36**(1): p. 71-3.
2. Wakefield, R.J., et al., *Finger tendon disease in untreated early rheumatoid arthritis: a comparison of ultrasound and magnetic resonance imaging*. Arthritis Rheum, 2007. **57**(7): p. 1158-64.

3. Navalho, M., et al., *Bilateral MR imaging of the hand and wrist in early and very early inflammatory arthritis: tenosynovitis is associated with progression to rheumatoid arthritis*. Radiology, 2012. **264**(3): p. 823-33.
4. Rakieh, C., et al., *OP0180 Risk of Developing Clinical Synovitis in ACPA Positive Patients with Non-specific Musculoskeletal Symptoms*. Annals of the Rheumatic Diseases 2013. **72**(Suppl 3): p. A114.
5. Wakefield, R.J., et al., *The value of sonography in the detection of bone erosions in patients with rheumatoid arthritis: a comparison with conventional radiography*. Arthritis Rheum, 2000. **43**(12): p. 2762-70.
6. Brown, A.K., et al., *New approaches to imaging early inflammatory arthritis*. Clin Exp Rheumatol, 2004. **22**(5 Suppl 35): p. S18-25.
7. Goupille, P., et al., *Magnetic resonance imaging: a valuable method for the detection of synovial inflammation in rheumatoid arthritis*. J Rheumatol, 2001. **28**(1): p. 35-40.
8. Eladoumikdachi, F., et al., *Anatomy of the intrinsic hand muscles revisited: part I. Interossei*. Plast Reconstr Surg, 2002. **110**(5): p. 1211-24.
9. Hastings, D.E. and J.A. Evans, *Rheumatoid wrist deformities and their relation to ulnar drift*. J Bone Joint Surg Am, 1975. **57**(7): p. 930-4.
10. Johnsson, P.M. and K. Eberhardt, *Hand deformities are important signs of disease severity in patients with early rheumatoid arthritis*. Rheumatology (Oxford), 2009. **48**(11): p. 1398-401.
11. Aletaha, D., et al., *2010 rheumatoid arthritis classification criteria: an American College of Rheumatology/European League Against Rheumatism collaborative initiative*. Ann Rheum Dis, 2010. **69**(9): p. 1580-8.
12. Haavardsholm, E.A., et al., *Introduction of a novel magnetic resonance imaging tenosynovitis score for rheumatoid arthritis: reliability in a multireader longitudinal study*. Ann Rheum Dis, 2007. **66**(9): p. 1216-20.
13. DiBenedetto, M.R., L.M. Lubbers, and C.R. Coleman, *Relationship between radial inclination angle and ulnar deviation of the fingers*. J Hand Surg Am, 1991. **16**(1): p. 36-9.
14. Kozin, S.H., *Arthroplasty of the hand and wrist: surgeon's perspective*. J Hand Ther, 1999. **12**(2): p. 123-32.
15. Liss, F.E., *The interosseous muscles: the foundation of hand function*. Hand Clin, 2012. **28**(1): p. 9-12.
16. Ikebuchi, Y., T. Murakami, and A. Ohtsuka, *The interosseous and lumbrical muscles in the human hand, with special reference to the insertions of the interosseous muscles*. Acta Med Okayama, 1988. **42**(6): p. 327-34.
17. Stomp, W., et al., *Aiming for a simpler early arthritis MRI protocol: can Gd contrast administration be eliminated?* Eur Radiol, 2015. **25**(5): p. 1520-7.
18. Tan, A.L., et al., *High-resolution magnetic resonance imaging for the assessment of hand osteoarthritis*. Arthritis Rheum, 2005. **52**(8): p. 2355-65.
19. Jain, A., et al., *Production of cytokines, vascular endothelial growth factor, matrix metalloproteinases, and tissue inhibitor of metalloproteinases 1 by tenosynovium demonstrates its potential for tendon destruction in rheumatoid arthritis*. Arthritis Rheum, 2001. **44**(8): p. 1754-60.
20. Yazici, Y., et al., *Morning stiffness in patients with early rheumatoid arthritis is associated more strongly with functional disability than with*

1
2
3
4
5
6
7
8
9
10
11
12
13
14
15
16
17
18
19
20
21
22
23
24
25
26
27
28
29
30
31
32
33
34
35
36
37
38
39
40
41
42
43
44
45
46
47
48
49
50
51
52
53
54
55
56
57
58
59
60
61
62
63
64
65

joint swelling and erythrocyte sedimentation rate. J Rheumatol, 2004.
31(9): p. 1723-6.

1
2
3
4
5
6
7
8
9
10
11
12
13
14
15
16
17
18
19
20
21
22
23
24
25
26
27
28
29
30
31
32
33
34
35
36
37
38
39
40
41
42
43
44
45
46
47
48
49
50
51
52
53
54
55
56
57
58
59
60
61
62
63
64
65

Table 1: Demographics of the control subjects and patients

	n	Sex (Male/Female)	Mean Age (range)
Control Subjects	20	5/15	49 (25-64)
Newly Diagnosed RA	16	6/10	51 (24-73)
Established RA	28	2/26	51 (29-76)

Table 2: Intrinsic tendons showing peritendinous inflammation (number of tendons)

	n	Dorsal Interossei				Palmar Interossei			ADM	TOTAL (%)
		1	2	3	4	1	2	3		
Newly Diagnosed RA	128	4	1	0	1	0	1	1	4	12 (9.4)
Established RA	224	9	6	1	6	3	4	8	3	40 (17.9)
Total	352	13	7	1	7	3	5	9	7	52 (14.8)

Table 3: Distribution of MCP joint synovitis (number of joints)

	n	Index	Middle	Ring	Little	Total (%)
Controls (20 subjects)	80	2	0	1	4	7 (8.8)
Patients (44 subjects)	176	27	25	21	23	96 (54.4)

Table 4: Distribution of Flexor Tendon tenosynovitis

	n	Index	Middle	Ring	Little	Total (%)
Controls (20 subjects)	80	1	0	0	0	1 (1.3)
Patients (44 subjects)	176	22	17	17	18	74 (42.0)

Figure 1a
[Click here to download Figure: Figure 1a.tiff](#)

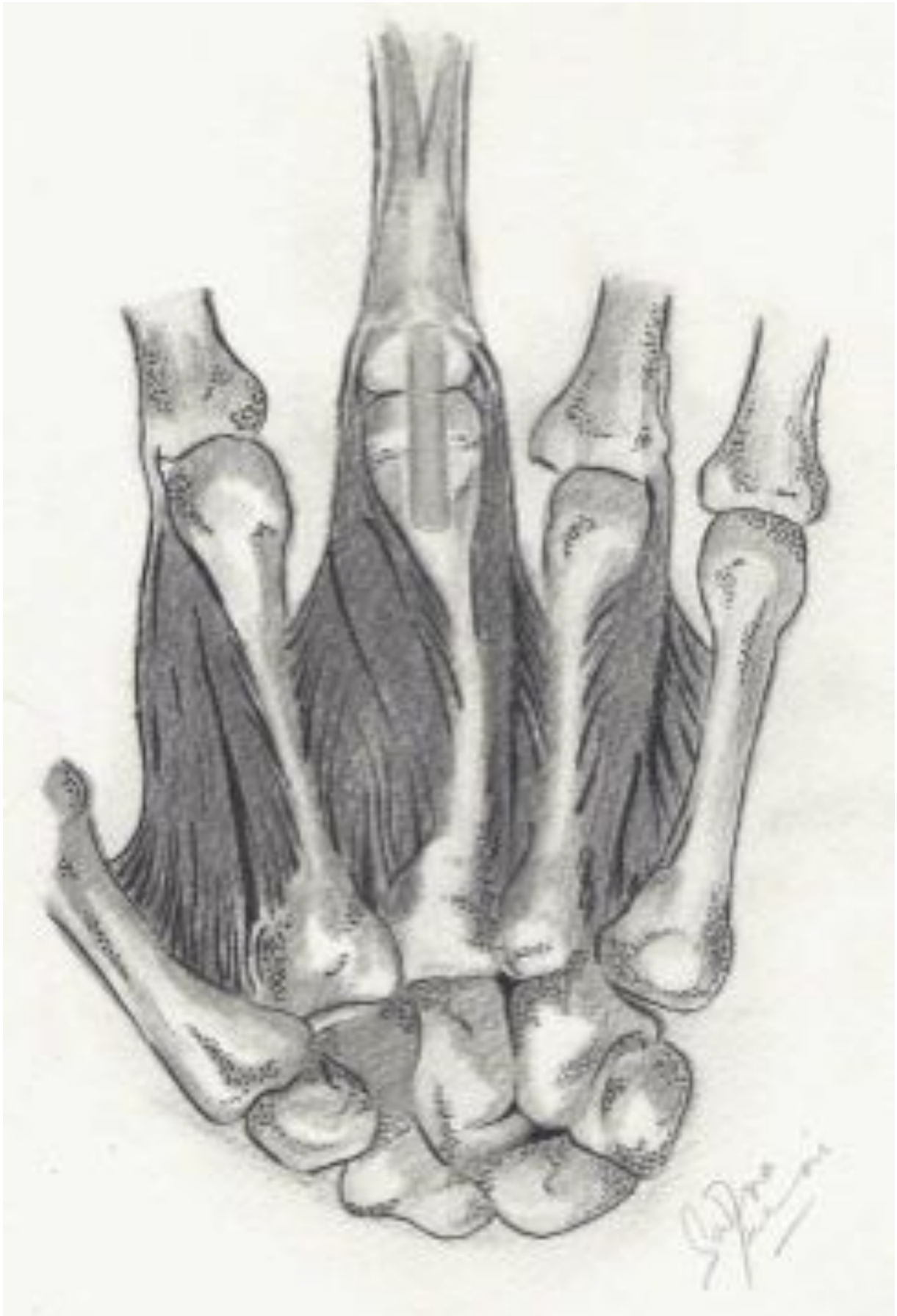

Figure 1b
[Click here to download Figure: Figure 1b.tiff](#)

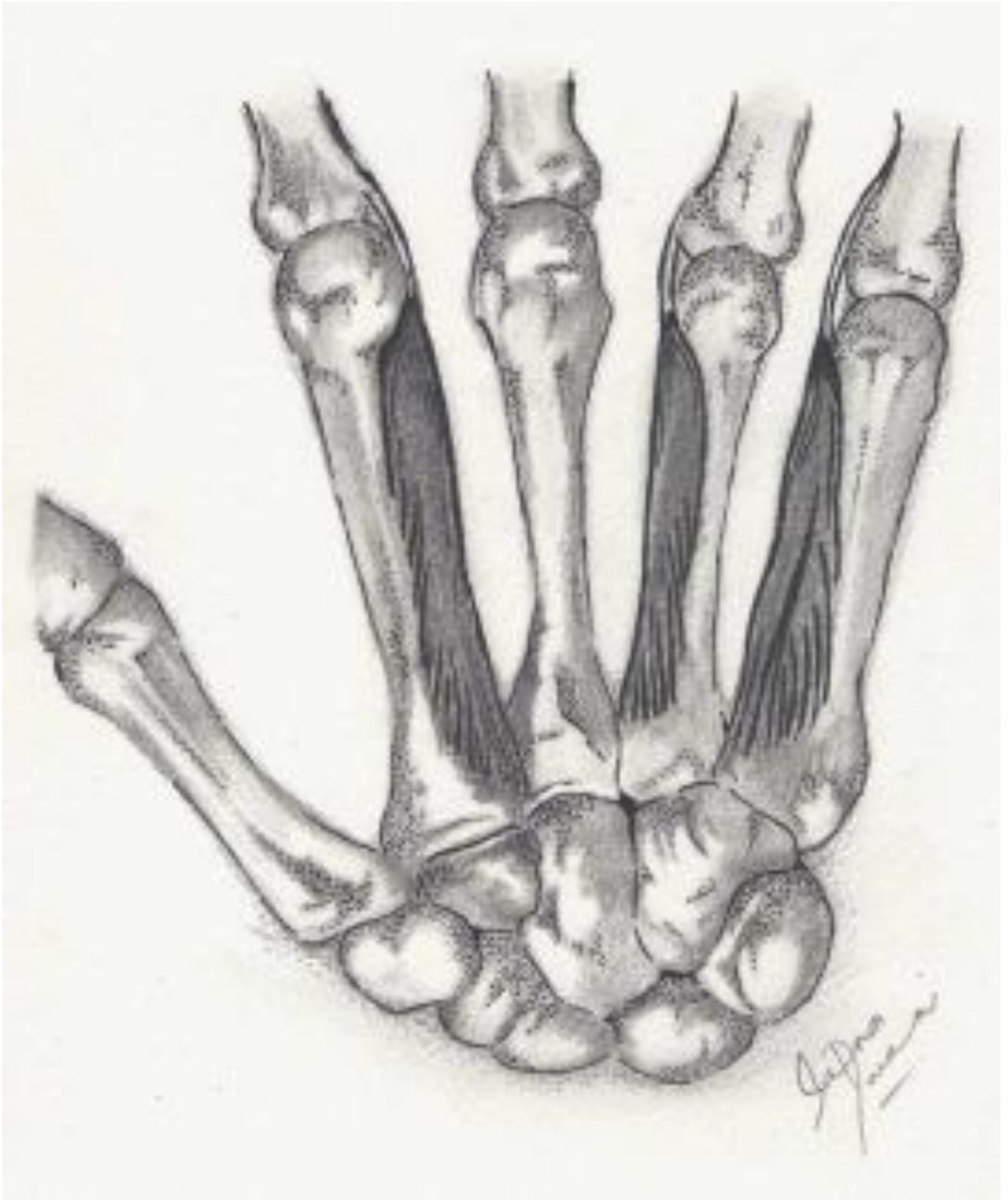


Figure 1c
[Click here to download Figure: Figure 1c.tiff](#)

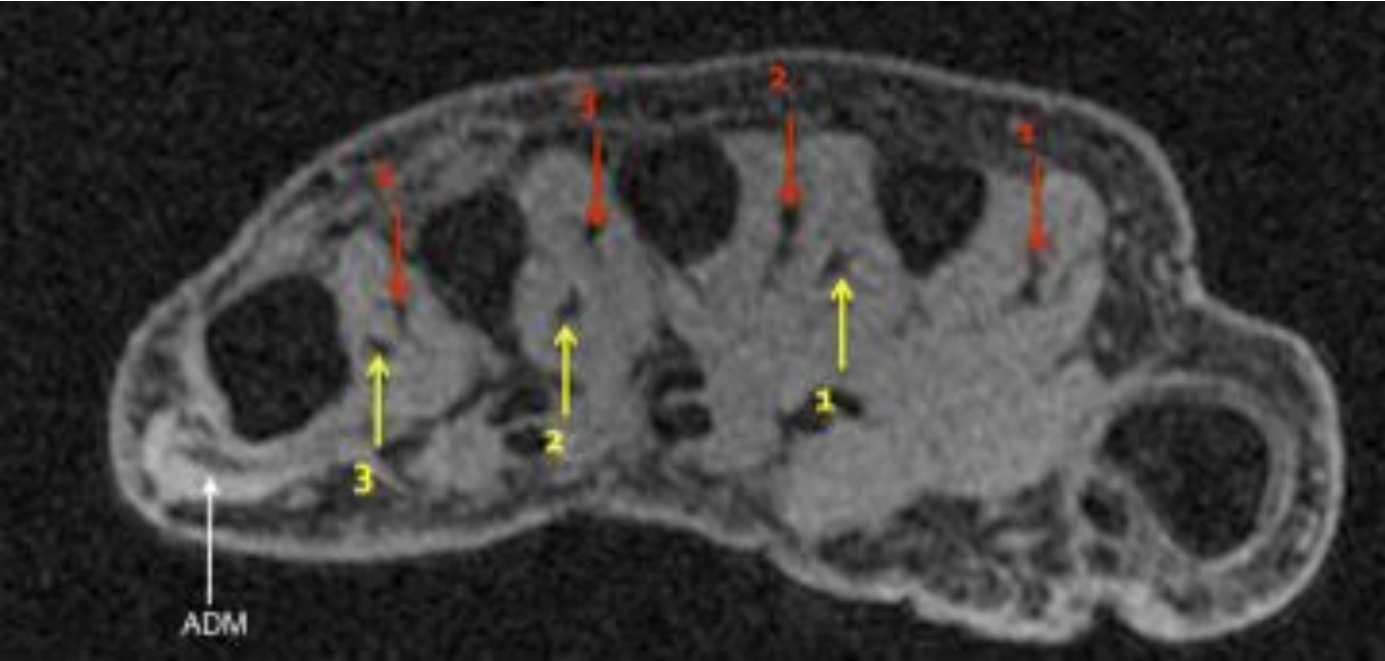


Figure 2
[Click here to download Figure: Figure 2.tiff](#)

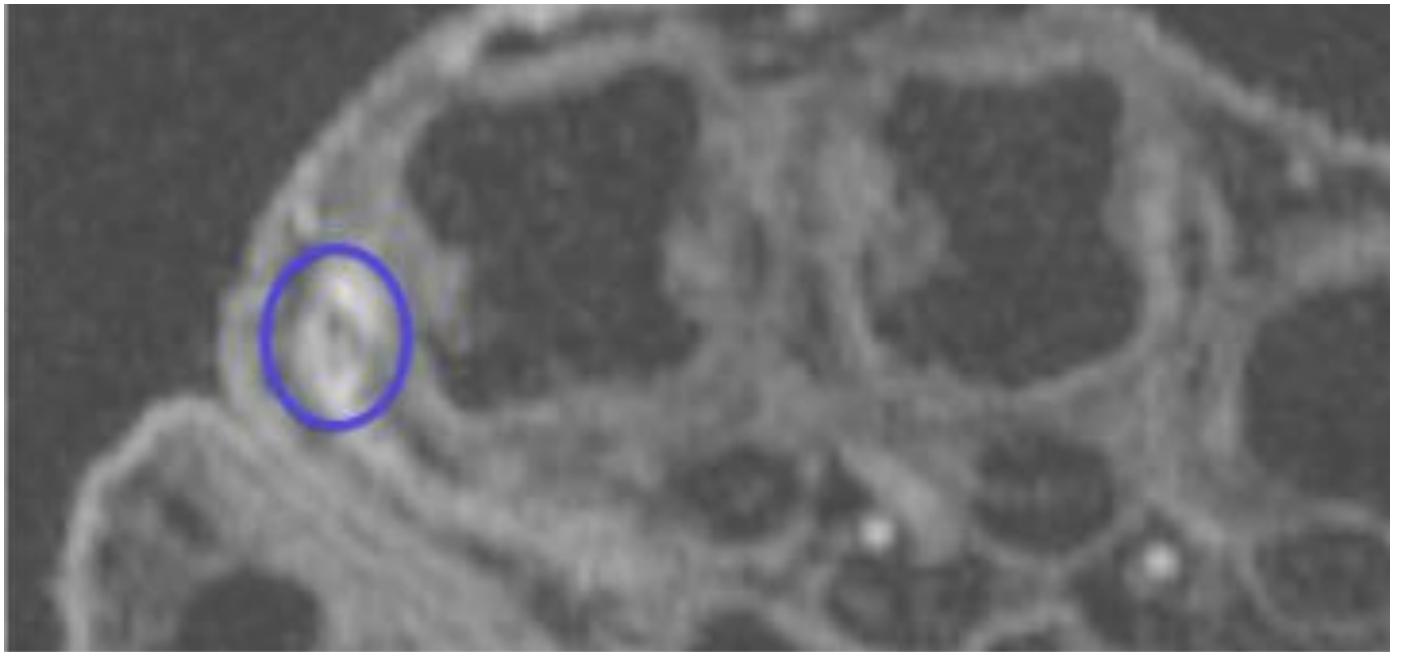


Figure 3

[Click here to download Figure: Figure 3.tiff](#)

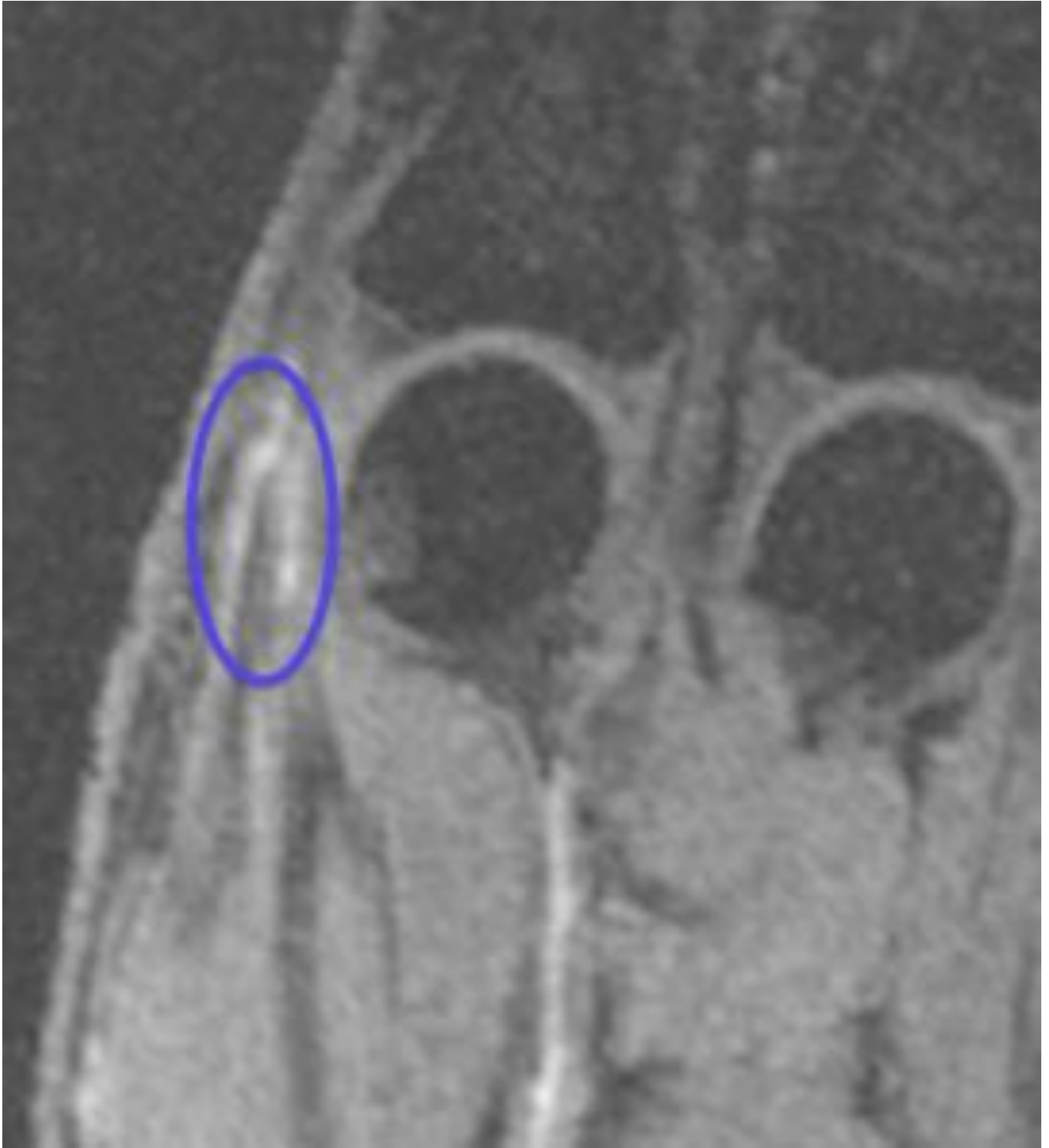

Figure 5
[Click here to download Figure: Figure 5.tiff](#)

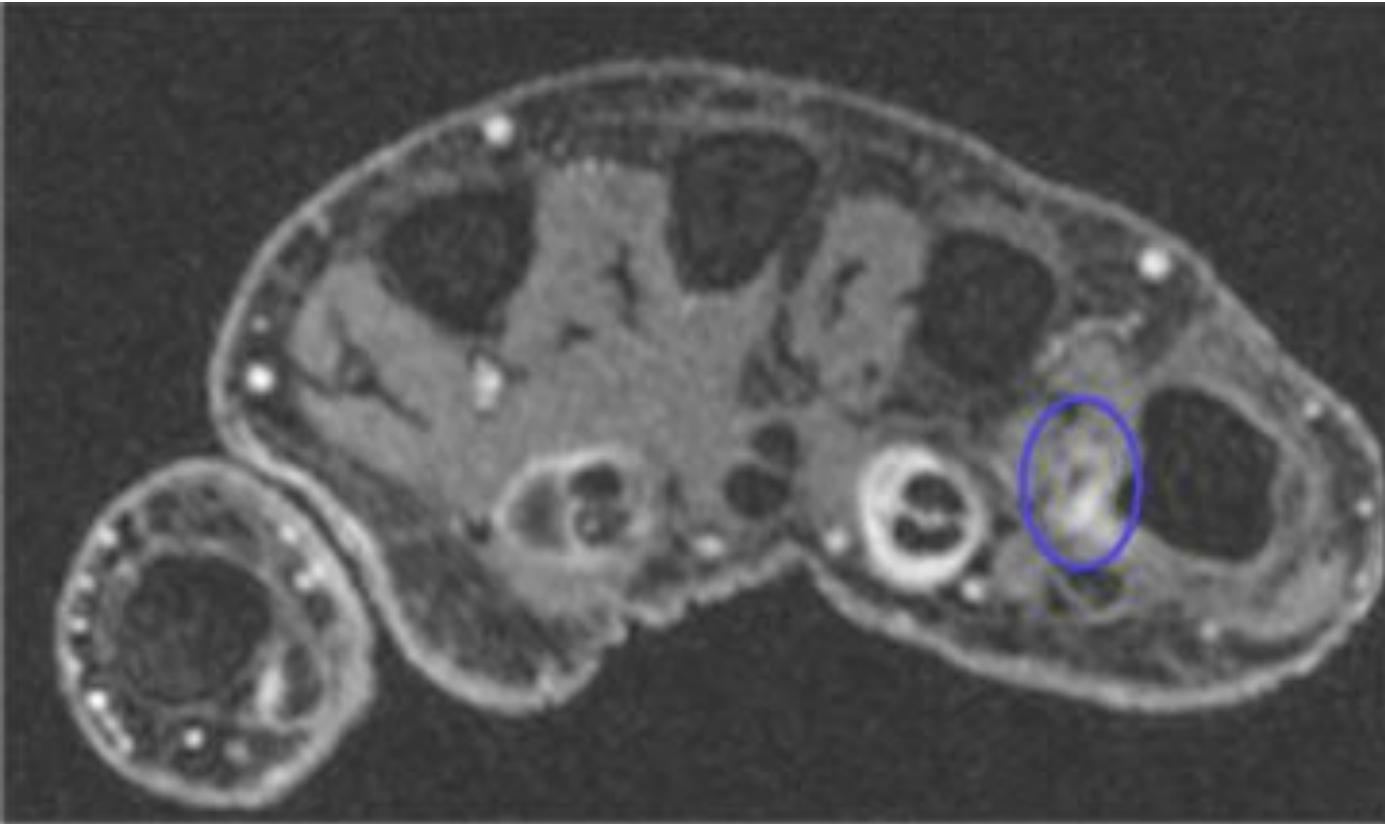
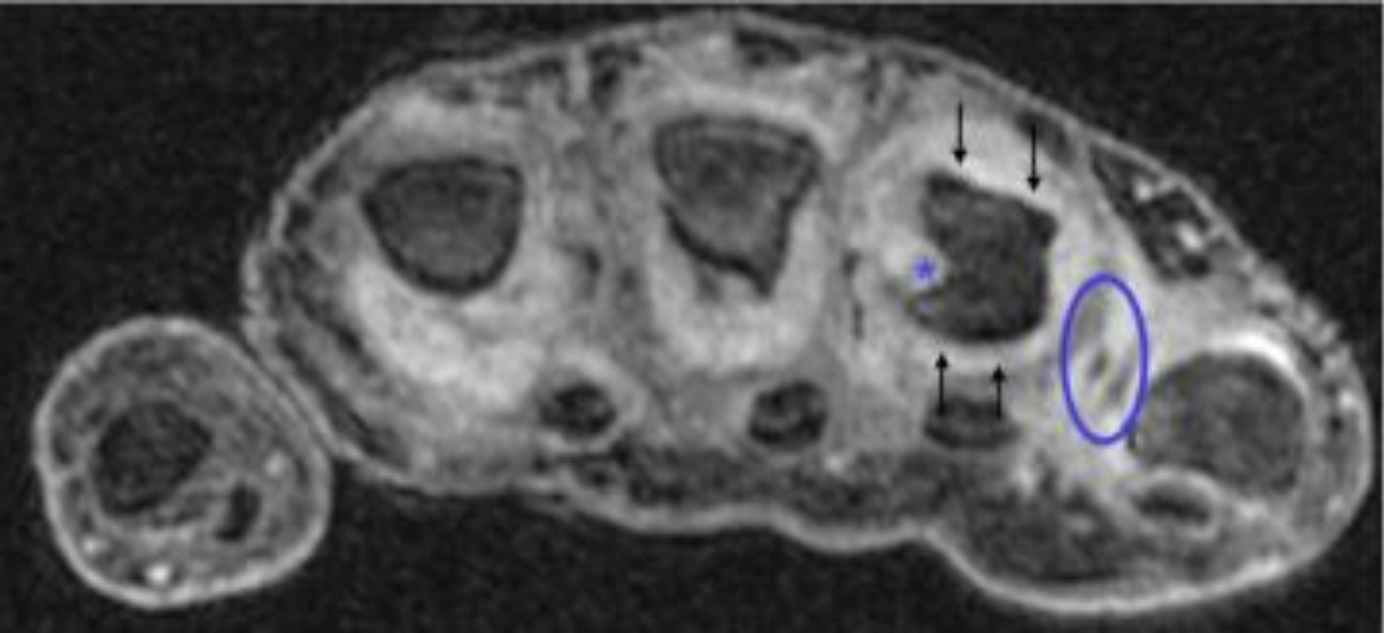


Figure 4
[Click here to download Figure: Figure 4.tiff](#)



Please fill in the appropriate responses as indicated in the menu point *Additional Information*, and delete the sentences that are not applicable for your manuscript. Upload the completed Disclosure document together with your manuscript files, with the file designation „Disclosure Paragraph“.

The paragraph will be published in the acknowledgements section of your paper.

Disclosure paragraph:

- 1) The scientific guarantor of this publication is Dr Andrew Grainger
- 2) The authors of this manuscript declare no relationships with any companies, whose products or services may be related to the subject matter of the article.
- 3) The authors state that this work has not received any funding.
- 4) No complex statistical methods were necessary for this paper.
- 5) Institutional Review Board approval was obtained.
- 6) *Only if the study is on human subjects:*
Written informed consent was obtained from all subjects (patients) in this study.
- 7) *Only if the study is on animals: N/A*
- 8) N/A
- 9) Methodology:
 - prospective
 - observational
 - performed at one institution