



Deposited via The University of Sheffield.

White Rose Research Online URL for this paper:

<https://eprints.whiterose.ac.uk/id/eprint/3552/>

Article:

Benson, P.E., Tinsley, D., O'Dwyer, J.J et al. (2007) Midpalatal implants vs headgear for orthodontic anchorage - a randomized clinical trial: Cephalometric results. *American Journal of Orthodontics and Dentofacial Orthopedics*, 132 (5). pp. 606-615. ISSN: 0889-5406

<https://doi.org/10.1016/j.ajodo.2006.01.040>

Reuse

Items deposited in White Rose Research Online are protected by copyright, with all rights reserved unless indicated otherwise. They may be downloaded and/or printed for private study, or other acts as permitted by national copyright laws. The publisher or other rights holders may allow further reproduction and re-use of the full text version. This is indicated by the licence information on the White Rose Research Online record for the item.

Takedown

If you consider content in White Rose Research Online to be in breach of UK law, please notify us by emailing eprints@whiterose.ac.uk including the URL of the record and the reason for the withdrawal request.

promoting access to White Rose research papers



Universities of Leeds, Sheffield and York
<http://eprints.whiterose.ac.uk/>

This is an author produced version of a paper published in **American Journal of Orthodontics and Dentofacial Orthopedics**.

White Rose Research Online URL for this paper:
<http://eprints.whiterose.ac.uk/3552/>

Published paper

Benson, P.E., Tinsley, D., O'Dwyer, J.J., Majumdar, A., Doyle, P. and Sandler, P.J. (2007) *Midpalatal implants vs headgear for orthodontic anchorage - a randomized clinical trial: Cephalometric results*, American Journal of Orthodontics and Dentofacial Orthopedics, Volume 132 (5), 606 - 615.

Mid-Palatal Implants v Headgear for Orthodontic Anchorage- a Randomized Clinical Trial: Cephalometric results

Philip E. Benson, Senior Lecturer in Orthodontics

David Tinsley, Orthodontic Specialist Practitioner

Jonathan J. O'Dwyer, Orthodontic Specialist Practitioner

Arun Majumdar, Consultant in Oral and Maxillofacial Surgery

Peter Doyle, Consultant in Oral and Maxillofacial Surgery

P. Jonathan Sandler, Consultant Orthodontist

Address for correspondence:

Dr PE Benson

Department of Oral Health & Development,

School of Clinical Dentistry,

Sheffield

S10 2TA

p.benson@sheffield.ac.uk

Keywords: RCT; Dental implants; Orthodontics; Anchorage; Cephalometrics

Abstract

Objective: To compare the clinical effectiveness of the mid-palatal implant as a method of reinforcing anchorage during orthodontic treatment with that of conventional extra-oral anchorage.

Design: A prospective, randomized, clinical trial

Setting: Chesterfield and North Derbyshire Royal Hospital NHS Trust and the Charles Clifford Dental Hospital, Sheffield.

Subjects and Methods: 51 orthodontic patients between the ages of 12 and 39, with a class II division 1 malocclusion and 'absolute anchorage' requirements were randomly allocated to either receive a mid-palatal implant or headgear to reinforce orthodontic anchorage. The main outcome of the trial was to compare the mesial movement of the molars and incisors of the two treatment groups between T1 (start) and T2 (end of anchorage reinforcement) as measured from cephalometric radiographs.

Results: The reproducibility of the measuring technique was acceptable. There were significant differences between the T1 and T2 measurements within the implant group for the position of the maxillary central incisor ($p < 0.001$), position of the maxillary molar ($p = 0.009$) and position of the mandibular molar ($p < 0.001$). There were significant differences within the headgear group for the position of the mandibular central incisor ($p < 0.045$), position of the maxillary molar ($p < 0.001$) and position of the mandibular molar ($p < 0.001$). All the skeletal and dental points moved mesially more in the headgear group during treatment than in the implant group. These ranged from an average of 0.5mm more mesial for the mandibular permanent molar to 1.5mm more mesial for the maxillary molar and mandibular base. None of the treatment changes between the implant and headgear groups were statistically significant.

Conclusions: Mid-palatal implants are an acceptable technique for reinforcing anchorage in the orthodontic patient.

Introduction

Anchorage is of fundamental importance in orthodontic treatment. A common method of reinforcing anchorage in the upper arch is to use an extra-oral attachment to the first molars, however this headgear is not popular with patients and is frequently not worn as prescribed¹, leading to poor treatment results. The dangers associated with headgear wear are well documented², the most severe of which is damage to the eyes³.

Endosseous dental implants have proved to be an effective method of restoring edentulous spaces and are now being used as a means of supporting orthodontic anchorage⁴. There are various different types of implant used for orthodontic anchorage including bone screws⁵, bone plates⁶ and palatal implants⁷. They are relatively simple to place; however complications include soft or hard tissue infection and failure of the implant. Implants that are placed on the buccal aspect, such as the mini-screws, risk damage to adjacent tooth roots.

To-date there has been no published randomized clinical trial comparing an orthodontic implant system with a conventional form of anchorage control. The aim of this study was to compare the clinical effectiveness of the mid-palatal implant as a method of reinforcing anchorage during orthodontic treatment with extra-oral anchorage reinforcement. This paper will present the cephalometric results.

Subjects and Methods

Ethical approval to carry out this study was obtained from North Derbyshire Health and South Sheffield Local Research Ethics committees. Subjects were recruited from the Orthodontic Departments of Chesterfield and North Derbyshire Royal Hospital NHS Trust and the Charles Clifford Dental Hospital, Sheffield.

Patients were required to fulfil the following criterion for inclusion in the study:

- Patients had 'absolute anchorage' requirements where no forward movement of either one or both molar teeth could be allowed if the case was to be successfully treated

The following exclusion criteria were applied:

- Poor oral hygiene.

- Unwilling to wear fixed appliances.
- Unwilling to wear headgear or have the implant placed.
- Medical history precluding fixed appliance treatment.

Once a patient was judged suitable they were given information about the study. Initial (T1) records were obtained involving study models, intra-oral and extra-oral photographs and appropriate radiographs, including a lateral cephalometric radiograph. The two treatment options of either headgear or a palatal implant were explained in detail and written information sheets given to patients and parents. The patients were given a review appointment at least two weeks later to discuss the study further. If they subsequently agreed to enter the study they were consented and randomly allocated to one of two treatment groups.

Group 1 (implant) - a mid-palatal implant (6mm Ortho implant, Straumann, Waldenburg, Switzerland) was surgically placed according to the manufacturers guidelines by one of two Oral and Maxillofacial Surgeons . A standard technique was used, including a stent to ensure safe and accurate implant positioning^{8, 9}. After a 3-month integration period the implants were connected by means of a laboratory manufactured trans-palatal arch to bands on the upper molars (Figure 1).

Group 2 (headgear) - Extra-oral anchorage in the form of a Nitom² Locking Facebow (Ortho-Care, Bradford, UK) was fitted to bands on the upper molars. A variable pull headgear was used with a force of 450g on each side. Patients were given detailed instructions on the use of headgear and requested to wear it 100-120 hours per week. A chart was supplied to the patient for recording the hours of headgear wear. The patient was reviewed two weeks after fitting the headgear to assess cooperation.

The randomization was carried out using computer generated random numbers in a block design by a researcher unconnected with the recruitment of the majority of the patients (PEB). Allocation was concealed in consecutively numbered, sealed and opaque envelopes, which were opened after the patient and parent had agreed to enter the trial and had signed the consent form. Extractions were undertaken in the upper and lower arches if a space analysis suggested that this was required to achieve the treatment objectives.

The majority of patients (42) were recruited, assigned and treated at Chesterfield and North Derbyshire Royal Hospital NHS Trust by three orthodontists (DT, JOD, PJS). The remaining nine

patients were recruited and treated at the Charles Clifford Dental Hospital by three orthodontists (DT, JOD, PEB). The two groups were treated identically, except for the method of anchorage reinforcement.

Once the clinician was satisfied that the anchorage reinforcement was secure the extractions were carried out. Stainless steel pre-adjusted edgewise brackets with a 0.022" slot size (MBT-American Orthodontics, Marlow, UK) were bonded to all teeth mesial to the first molars in the upper and lower arches and an initial 0.016" nickel titanium aligning wire was placed. The subsequent archwire sequence was a 0.018" x 0.025" nickel titanium archwire, followed by a posted 0.019" x 0.025" stainless steel wire, with curves where appropriate to manage the overbite. Spaces were closed and upper anterior labial segments were retracted with nickel titanium closing springs (12mm, medium force) using sliding mechanics. Intermaxillary elastics were utilized, when considered necessary by the treating clinician.

Anchorage reinforcement was continued until the lower arch was aligned and the upper canines were in a class I relationship with the lower canines. At this stage the patient was instructed to stop wearing the headgear or the implant was disconnected from the molar bands. At the same appointment a lateral cephalogram was taken (T2).

The main outcome of the trial was to compare the mesial movement of the molars and incisors of the two treatment groups between T1 (start records) and T2 (end of anchorage reinforcement records). This was carried out on the lateral cephalograms using the Pancherz analysis¹⁰. Other measures such as treatment outcome, patient acceptability, compliance and discomfort and implant stability and discomfort will be reported elsewhere.

Cephalometric analysis

Blinding of the operator and the patient to treatment allocation was not possible during this study; however all the radiographs were anonymized with patient details obscured. The implants were concealed using an opaque marker on both sides of the radiograph (Figure 2). An opaque marker was also placed in the approximate position of an implant on the radiographs of the headgear group, so the assessor was unaware to which treatment group the radiograph belonged.

The pre-treatment (T1) radiographs were number consecutively in a random order by one researcher (PEB) and traced on a light box in a darkened room by a second researcher (JOD). A

grid was constructed from the first radiograph (T1) using two reference planes, the occlusal line (OL) and the occlusal line perpendicular (OLp) (Figure 3). The grid was transferred to the second radiograph by superimposition on the nasion-sella line (NSL) with sella as the registering point. Linear measurements from OLp to one of six landmarks were obtained with a digital calliper by a third researcher (DT). The landmarks as defined by Pancherz¹⁰ were used:

A - the deepest point on the anterior contour of the maxilla

Pg - the most anterior point on the bony chin

IsSu - the incisal tip of the most prominent maxillary central incisor

Li - the incisal tip of the most prominent central mandibular incisor

Sm - the mesial contact point of the maxillary first permanent molar

Lm - the mesial contact point of the mandibular first permanent molar

After two weeks the measurements were repeated on the radiographs of 10 randomly selected implant patients and 10 randomly selected headgear patients. Both T1 and T2 radiographs were placed in a random order and assessed, therefore 20 radiographs from each group were remeasured.

Statistical Analysis

Statistical advice was obtained, which suggested that a sample size of 40 patients would be sufficient to detect a 2mm (± 1.5 mm) difference in mesial molar movement between the treatment groups, at a significance level of 0.05 and a power of 0.85. A 20 percent dropout rate was anticipated, therefore a final sample size of 50 patients was recommended.

The repeat readings from the 40 radiographs measured twice were assessed with a paired *t* test for systematic error. The intraclass correlation coefficient was calculated for the repeat readings to monitor the random error.

The distribution of the data was examined and found to be normal, therefore parametric statistics were applied. The measurements of the T1 radiographs from the two treatment groups were assessed with an independent *t* test to check for pre-treatment equivalence. The difference within each treatment group in the skeletal and dental positions from the T1 and T2 radiographs was examined with a paired *t* test and the change in the skeletal and dental positions between the groups was compared with an independent *t* test. The statistical significance level was set at $p < 0.05$.

Results

Recruitment to the trial began in January 2001 and continued until December 2002. A total of 51 patients were enrolled, 25 in the implant group and 26 in the headgear group. There were 38 females and 13 males (Headgear 20F, 6M; Implant 18F, 7M) with an average age 15.2 years (Headgear 14.8; Implant 15.7).

Figure 4 shows the flow of participants through the trial. Two patients from the implant group and one from the headgear group withdrew before receiving treatment. Two patients had failed implants; one received headgear and the other had a compromise extraction pattern. Four patients were unable to wear the headgear; three received a compromise extraction pattern and one received an implant. One patient was excluded because a T2 radiograph was not obtained. All patients were analysed on an intention to treat basis. Therefore the data from 23 out of the 25 patients allocated to the implant group were included in the analysis and 24 out of the 26 patients allocated to the headgear group.

Table 1 shows the results of the repeat readings of the 40 radiographs. The mean difference between the readings was small and there were no systematic differences detected. The intraclass correlation coefficients for the repeat readings are shown in Table 2. There was substantial or excellent agreement between all the measurements.

The descriptive statistics of the readings from the T1 and T2 radiographs for the implant and headgear groups are shown in Table 3. An independent *t* test for pre-treatment equivalence showed no significant differences between the implant and headgear groups at the start of treatment.

The skeletal and dental changes between the T1 and T2 radiographs within the implant and headgear groups are shown in Table 4. There were significant differences between the T1 and T2 measurements within the implant group for the position of the maxillary base ($p=0.048$), position of the maxillary central incisor ($p<0.001$), position of the maxillary molar ($p=0.009$) and position of the mandibular molar ($p<0.001$).

There were significant differences between the T1 and T2 measurements within the headgear group for the position of the mandibular base ($p=0.040$), position of the mandibular central

incisor ($p < 0.045$), position of the maxillary molar ($p = < 0.001$) and position of the mandibular molar ($p < 0.001$).

Table 5 shows the T1 and T2 differences in the skeletal and dental changes between the implant and headgear groups. This demonstrates that all the skeletal and dental points moved mesially more in the headgear group during treatment than in the implant group. These ranged from an average of 0.5mm more mesial for the mandibular permanent molar to an average of 1.5mm more mesial for the maxillary molar and the mandibular base, but none of the treatment changes between the implant and headgear groups were statistically significant.

The ratio of incisor retraction to mesial molar movement was calculated for each patient ($IsSu-OLpT2 - IsSu-OLpT1$) / ($Sm-OLpT2 - Sm-OLpT1$). This showed that for every millimetre of mesial movement of the molar there was an average 2.3mm of incisor retraction in the implant group compared with an average forward movement of the incisor of 1.2mm in the headgear group.

Discussion

This is the first report of a randomized clinical trial comparing the use of a palatal implant with a conventional extra-oral method for anchorage reinforcement. It has shown that although there were some significant differences in the movement of skeletal and dental points within each group, the differences between the groups were not statistically significant.

There are several problems conducting randomised clinical trials in the area of orthodontics, however this approach is generally accepted to produce a high level of evidence, when comparing two alternative treatment methods. The fundamental question with this study was, Are midpalatal implants as good as conventional methods of reinforcing anchorage in the orthodontic patient? The answer to this question is a clear yes. There were no statistically significant differences between the tooth movements carried out in patients with implants and those with headgear.

To go a step further and ask whether implants are more efficient than headgear in reinforcing anchorage is not so clear. The differences in the movement of the dental points are interesting. The reduction of overjet in the Implant group was principally by retracting the upper incisors (average 2.1mm), which was highly significant. Retraction of the upper incisors in the Headgear group was much lower (average 0.7mm) and not statistically significant. Overjet reduction in the

Headgear group was helped by a considerable proclination of the lower incisors (average 1.7mm), whereas the change in the position of the lower incisors in the Implant group was not very marked.

The average retraction of the upper incisors might appear small considering the nature of the malocclusions treated. Wehrbein et al⁷ found a mean reduction in the overjet of 6.2mm, measured from study casts in a group of nine patients with class II malocclusions treated with mid-palatal implants to support anchorage. The method of measuring upper incisor movement used in this study is related to, but is not a direct measurement of overjet reduction. The change in the position of the maxillary incisor in the implant group (-2.1mm) is comparable to changes found in similar groups of patients involved in an RCT comparing treatment with a twin block (-3.1mm) and a Herbst appliance (-2.4mm) using the same cephalometric technique¹¹.

The mesial movement of the upper molars could be said to represent the mean anchorage loss in this study, because the cases were all class II malocclusions. By this measure the mean anchorage loss was twice as much in the Headgear group (mean 3.0 \pm 3.4mm) compared with the implant group (mean 1.5 \pm 2.6mm). Wehrbein et al⁷ found a lower mean anchorage loss of 0.9mm (\pm 0.3mm) measured from cephalograms with a technique of superimposing on ANS/PNS and measuring the mesial movement of the cusp tip point. They suggested that part of the anchorage loss was due to bending of the transpalatal bar used to connect the anchor teeth to the implant. They advised increasing the size of the archwire from a square 0.8 x 0.8mm wire to one of higher rigidity such as 1.2 x 1.2mm. We used a 0.8mm wire and therefore some of the anchorage loss in the implant group might be attributed to this. Other loss might be due to early failures of the transpalatal arch⁸. It was the clinical impression that the implants did not move under normal orthodontic forces, however this is the subject of a further investigation.

There were no statistically significant differences in the tooth movements between the two groups, but the upper confidence limits ranged from 2.2mm to 3.7mm, whereas the lower limits ranged from -0.3mm to -1.2mm. This non-symmetrical arrangement of the confidence intervals around the differences suggests that there might in fact be a significant difference, but this study was lacking the power to detect it. The main reason for the discrepancy between the predicted outcomes and what was observed is that the sample size was calculated on the basis of data from two studies^{10, 12}. Both found much smaller variations in the treatment changes than occurred in this study. It should be noted that the results of these previous studies were from samples selected on the basis of the availability of records¹² and consecutively treated cases¹⁰,

which may have been subjected to bias¹³. As a result of this we based our sample size on a smaller standard deviation than was actually found. Using the actual standard deviation (3.0) we extrapolate that a sample size of 80 (40 in each group) would be required to find a significant difference of 2mm between the two groups ($\alpha = 0.05$; $1-\beta = 0.85$). This sample size should be used as a starting point of any study looking into the same outcome in the future.

All patients in this trial were analysed on an intention to treat basis. This means that even those in which the implant failed or who did not comply with the instructions for wearing the headgear were analysed in the groups they were originally allocated to. This might have altered the outcome of the trial, but is considered the best way of avoiding bias and possibly over-estimating the effect of a new form of treatment¹³.

The effects on the skeletal landmarks were interesting. There was no restraining effect on the forward growth of the maxilla in patients who wore headgear. In fact there appeared to have been more mandibular growth in this group. This is contrary to findings in other studies. Tulloch et al¹⁴ found that there was an average reduction in the SNA angle of 0.92° per year in a group allocated to early correction of a class II malocclusion with headgear. This compared with an increase of 0.26° per year in a control group, however these differences were lost by the end of a second phase of treatment¹⁵. The reason for this lack of skeletal effect from the headgear is unclear. Compliance with headgear wear was assessed by the experienced clinicians treating the patient and reinforced with charts completed at home. However, it is known that clinical indicators of compliance with headgear wear can be misleading¹⁶.

The drop-out rate in this study was similar between the two groups. Nineteen percent (5 out of 26) of patients allocated to the Headgear group failed to complete treatment compared with 16 percent (4 out of 25) in the Implant group, although two failures in the Implant group were due to surgical failure of the implant, rather than patient compliance. All patients who had failed implants requested further implant placement. This failure rate is very similar to those quoted for other studies, including early treatment with a twin block functional appliance¹⁷, a prospective cohort study of the twin block appliance¹⁸ and for the Herbst appliance¹¹ but much less than later treatment with a twin block¹¹.

There is extensive reporting in the literature of high levels of success (>95%) with osseointegrated implants used to restore the dentition¹⁹. Wehrbein et al 1999⁷ reported a one hundred percent success rate in a prospective trial involving the Straumann palatal implant

placed in nine patients. Bernhart et al²⁰ reported the results of a prospective study of orthodontic treatment carried out with palatal implant support in 21, mainly adult patients. All their implants achieved primary stability; however two became mobile shortly after the start of orthodontic treatment and one after 8 months of treatment.

The surgical failure rate of the implants in this study was quite high, with implants in six out of the 24 implant patients (25%) failing to achieve primary stability at the first attempt. Four patients subsequently received a second implant, which achieved osseointegration, but in two patients the second implant failed and they underwent a compromise treatment. The failed implants were amongst the first placed by the surgeon and there was an improvement in the failure rate as the trial progressed. In addition it should be noted that none were lost once they successfully achieved primary stability.

The palatal implant is only one type of implant used for orthodontic anchorage and relies on osseointegration for stability. There are other types of implants that do not rely on osseointegration, but are mechanically retained. These can potentially be loaded with orthodontic forces immediately²¹, however there are few published failure rates for these implants. The use of implants for aiding orthodontic tooth movement is an exciting and fast moving field. It is essential that future research work documents all failures and investigates the acceptability of this form of treatment to patients as well as the efficiency of achieving planned movements.

There are several reasons for suggesting that implants are an acceptable alternative to other forms of anchorage reinforcement. One reason would be the lower complication rate with implants compared with headgear. A survey of 1117 practitioners in the UK and Eire reported 33 injuries from the use of Kloehn type facebows². The most serious injury is damage to the eye, with subsequent loss of sight²². There are few reported complications from mid-palatal implants. Wehrbein⁷ also found few complications, with five out of the nine patients reporting no post-operative pain following implant placement. The patient acceptability in this trial was also good, with only one patient experiencing some minor post-operative pain requiring a single dose of analgesic on the evening of implant placement⁸.

Conclusions

Mid-palatal implants are an acceptable technique for reinforcing anchorage in the orthodontic patient.

This RCT was unable to show any statistically significant differences in the tooth movements achieved between a group of patients with orthodontic anchorage supported with a mid-palatal implant compared with conventional headgear, however there were important differences in the movement of teeth within the groups.

Further studies should examine patient based measure of acceptability for implant treatment, as well as clinical efficiency.

References

1. Cole WA. Accuracy of patient reporting as an indication of headgear compliance. *Am J Orthod Dentofacial Orthop* 2002;121:419-23.
2. Samuels RH, Willner F, Knox J, Jones ML. A national survey of orthodontic facebow injuries in the UK and Eire. *Br J Orthod* 1996;23:11-20.
3. Blum-Hareuveni T, Rehany U, Rumelt S. Blinding endophthalmitis from orthodontic headgear. *N Engl J Med* 2004;351:2774-5.
4. Huang LH, Shotwell JL, Wang HL. Dental implants for orthodontic anchorage. *Am J Orthod Dentofacial Orthop* 2005;127:713-22.
5. Park YC, Lee SY, Kim DH, Jee SH. Intrusion of posterior teeth using mini-screw implants. *Am J Orthod Dentofacial Orthop* 2003;123:690-4.
6. Sugawara J, Daimaruya T, Umemori M, Nagasaka H, Takahashi I, Kawamura H, et al. Distal movement of mandibular molars in adult patients with the skeletal anchorage system. *Am J Orthod Dentofacial Orthop* 2004;125:130-8.
7. Wehrbein H, Feifel H, Diedrich P. Palatal implant anchorage reinforcement of posterior teeth: A prospective study. *Am J Orthod Dentofacial Orthop* 1999;116:678-86.
8. Tinsley D, O'Dwyer JJ, Benson PE, Doyle PT, Sandler J. Orthodontic palatal implants: clinical technique. *J Orthod* 2004;31:3-8.
9. Majumdar A, Tinsley D, O'Dwyer J, Doyle PT, Sandler J, Benson P, et al. The 'Chesterfield stent': an aid to the placement of midpalatal implants. *Br J Oral Maxillofac Surg* 2005;43:36-9.

10. Pancherz H. The mechanism of Class II correction in Herbst appliance treatment. A cephalometric investigation. *Am J Orthod* 1982;82:104-13.
11. O'Brien K, Wright J, Conboy F, Sanjie Y, Mandall N, Chadwick S, et al. Effectiveness of treatment for Class II malocclusion with the Herbst or twin-block appliances: a randomized, controlled trial. *Am J Orthod Dentofacial Orthop* 2003;124:128-37.
12. Luecke PE, 3rd, Johnston LE, Jr. The effect of maxillary first premolar extraction and incisor retraction on mandibular position: testing the central dogma of "functional orthodontics". *American Journal of Orthodontics Dentofacial Orthopedics* 1992;101:4-12.
13. Altman DG. *Practical Statistics for Medical Research*. London: Chapman & Hall; 1991.
14. Tulloch JF, Phillips C, Koch G, Proffit WR. The effect of early intervention on skeletal pattern in Class II malocclusion: a randomized clinical trial. *Am J Orthod Dentofacial Orthop* 1997;111:391-400.
15. Tulloch JF, Proffit WR, Phillips C. Outcomes in a 2-phase randomized clinical trial of early Class II treatment. *Am J Orthod Dentofacial Orthop* 2004;125:657-67.
16. Cureton SL, Regennitter FJ, Yancey JM. Clinical versus quantitative assessment of headgear compliance. *Am J Orthod Dentofacial Orthop* 1993;104:277-84.
17. O'Brien K, Wright J, Conboy F, Sanjie Y, Mandall N, Chadwick S, et al. Effectiveness of early orthodontic treatment with the Twin-block appliance: a multicenter, randomized, controlled trial. Part 1: Dental and skeletal effects. *Am J Orthod Dentofacial Orthop* 2003;124:234-43; quiz 339.
18. Harradine NW, Gale D. The effects of torque control spurs in twin-block appliances. *Clin Orthod Res* 2000;3:202-9.
19. Orenstein IH, Tarnow DP, Morris HF, Ochi S. Factors affecting implant mobility at placement and integration of mobile implants at uncovering. *J Periodontol* 1998;69:1404-12.
20. Bernhart T, Freudenthaler J, Dortbudak O, Bantleon HP, Watzek G. Short epithetic implants for orthodontic anchorage in the paramedian region of the palate. A clinical study. *Clin Oral Impl Res* 2001;12:624-31.
21. Cope JB. Temporary Anchorage Devices in Orthodontics: A paradigm shift. *Seminars in Orthodontics* 2005;11:3-9.
22. Booth-Mason S, Birnie D. Penetrating eye injury from orthodontic headgear--a case report. *Eur J Orthod* 1988;10:111-4.

Figure 1

Mid-palatal implant connected with a transpalatal arch to molar bands

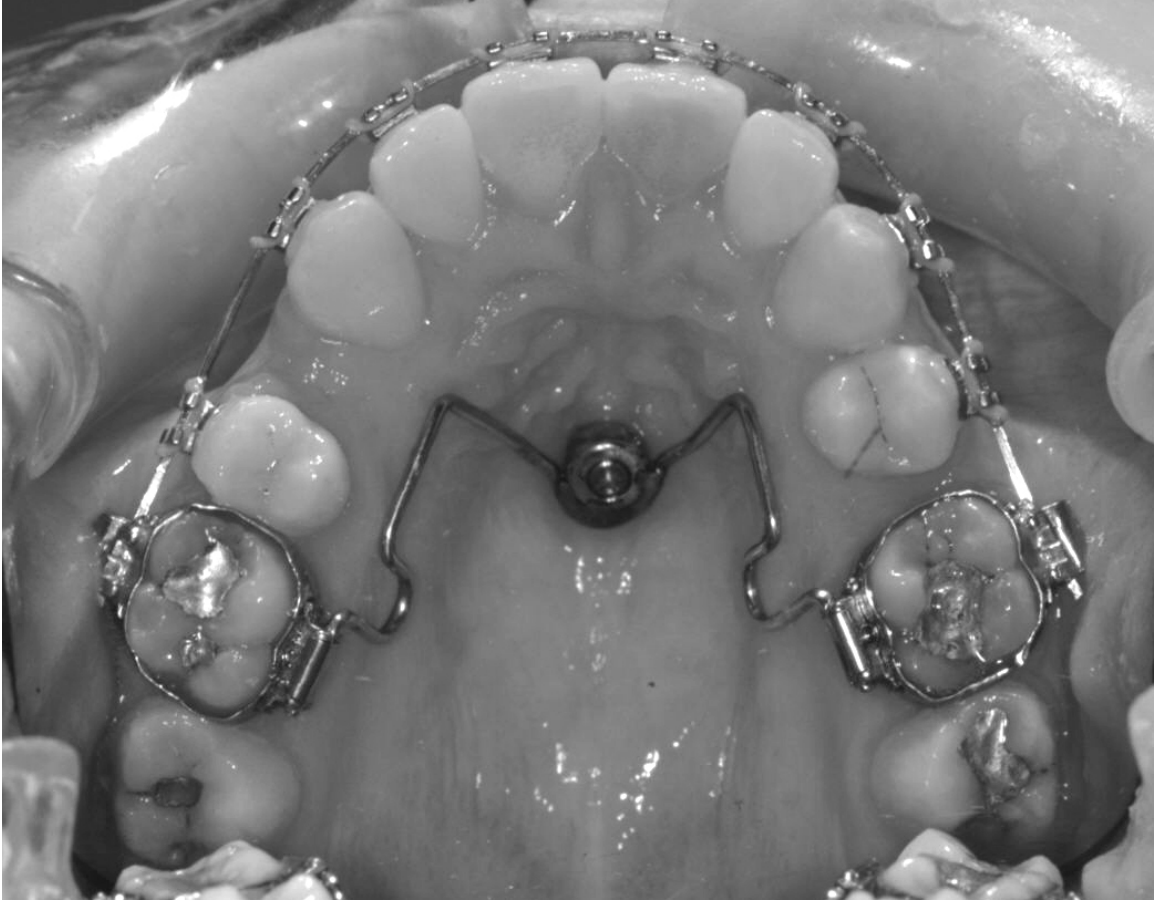

Figure 2

Cephalometric radiograph with the implant blanked out.

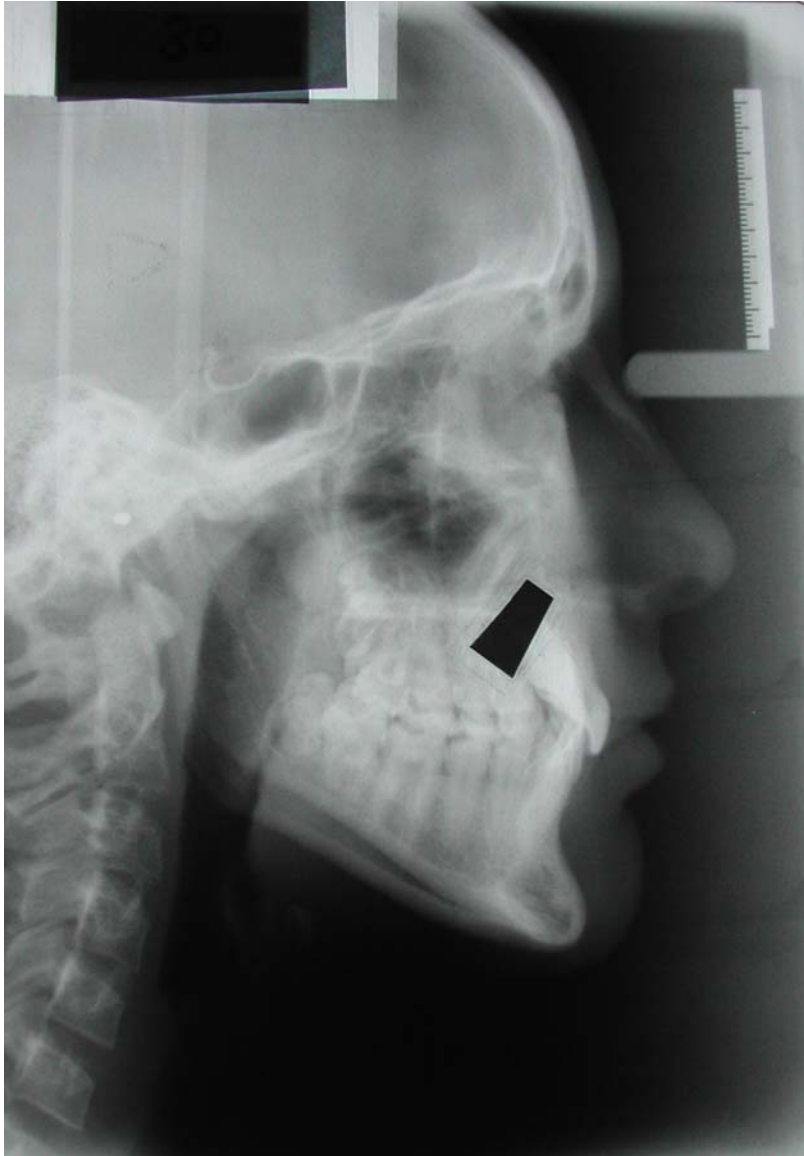


Figure 3

Diagram of the reference planes and measurements carried out for the Pancherz analysis (Reprinted from American Journal of Orthodontics, Vol 82, Hans Pancherz, The mechanism of Class II correction in Herbst appliance treatment : A cephalometric investigation, page 10, Copyright (1982), with permission from Elsevier.

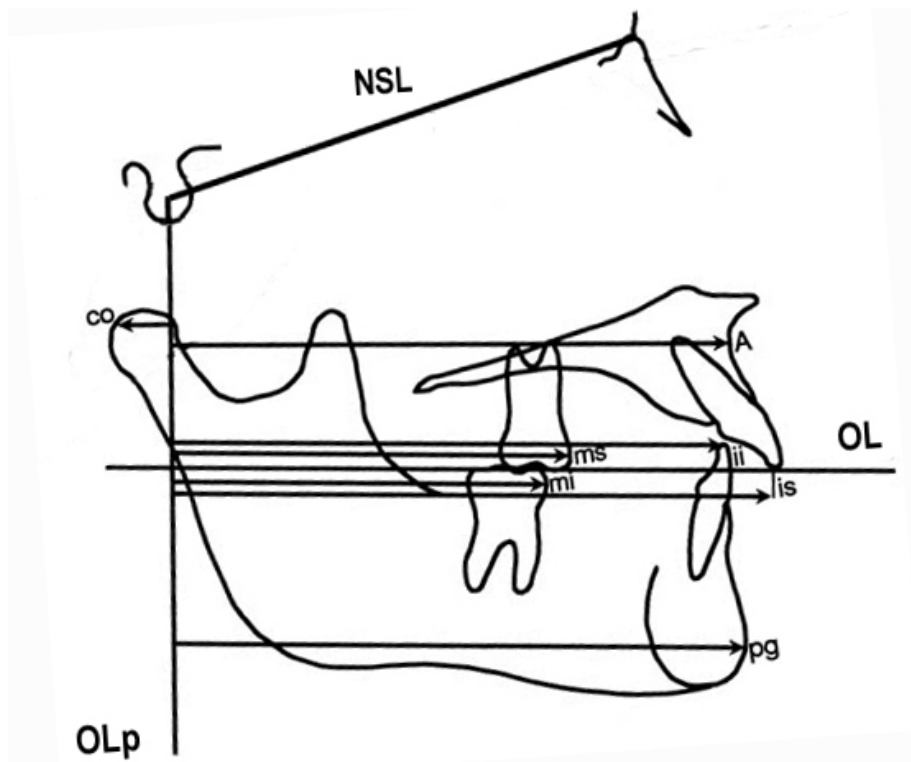


Figure 4

Diagram showing the flow of participants through each stage of the trial

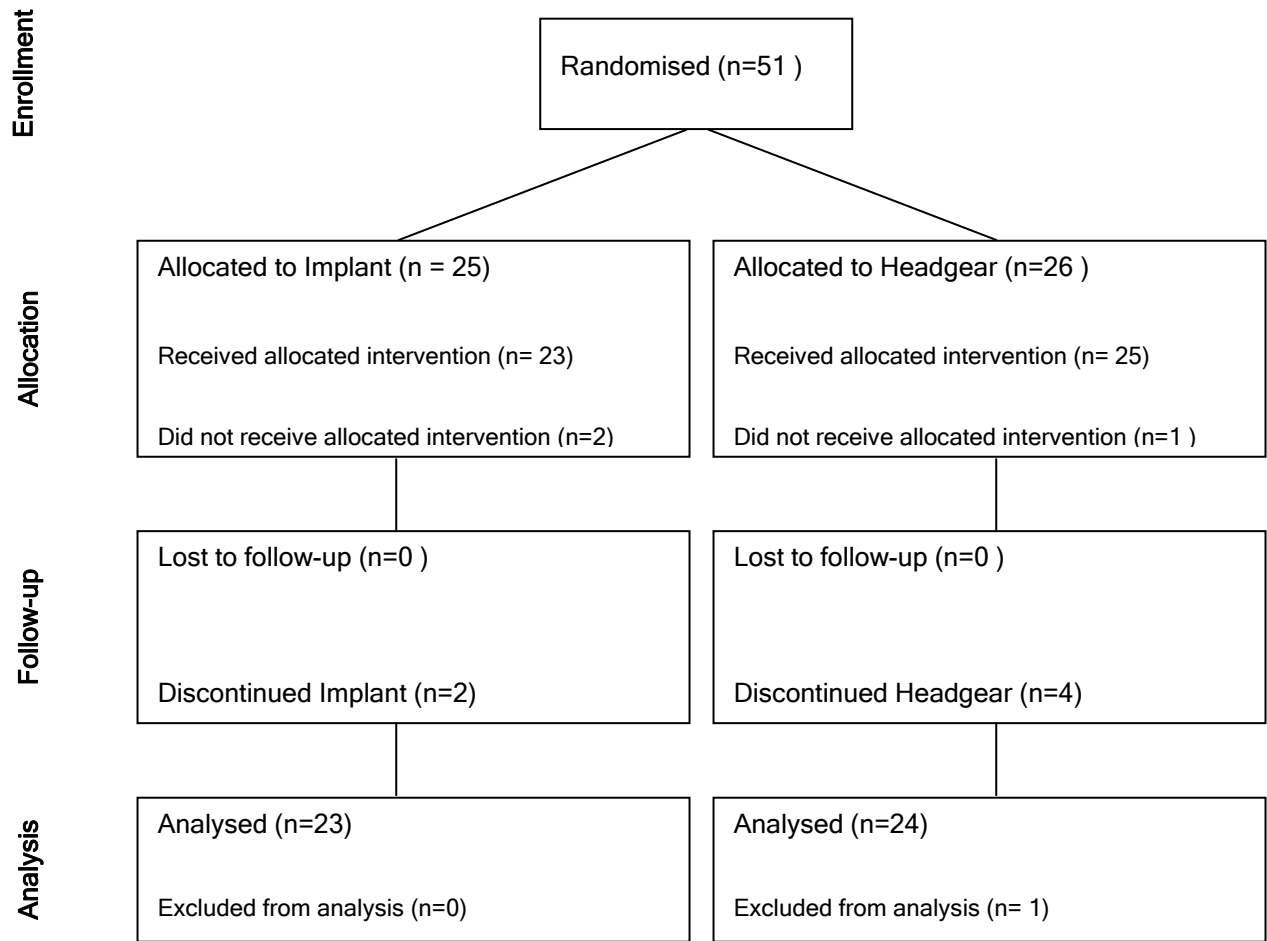


Figure 5

Diagram showing the mean direction and amount of tooth and skeletal movements (mm) between the T1 and T2 in the implant group

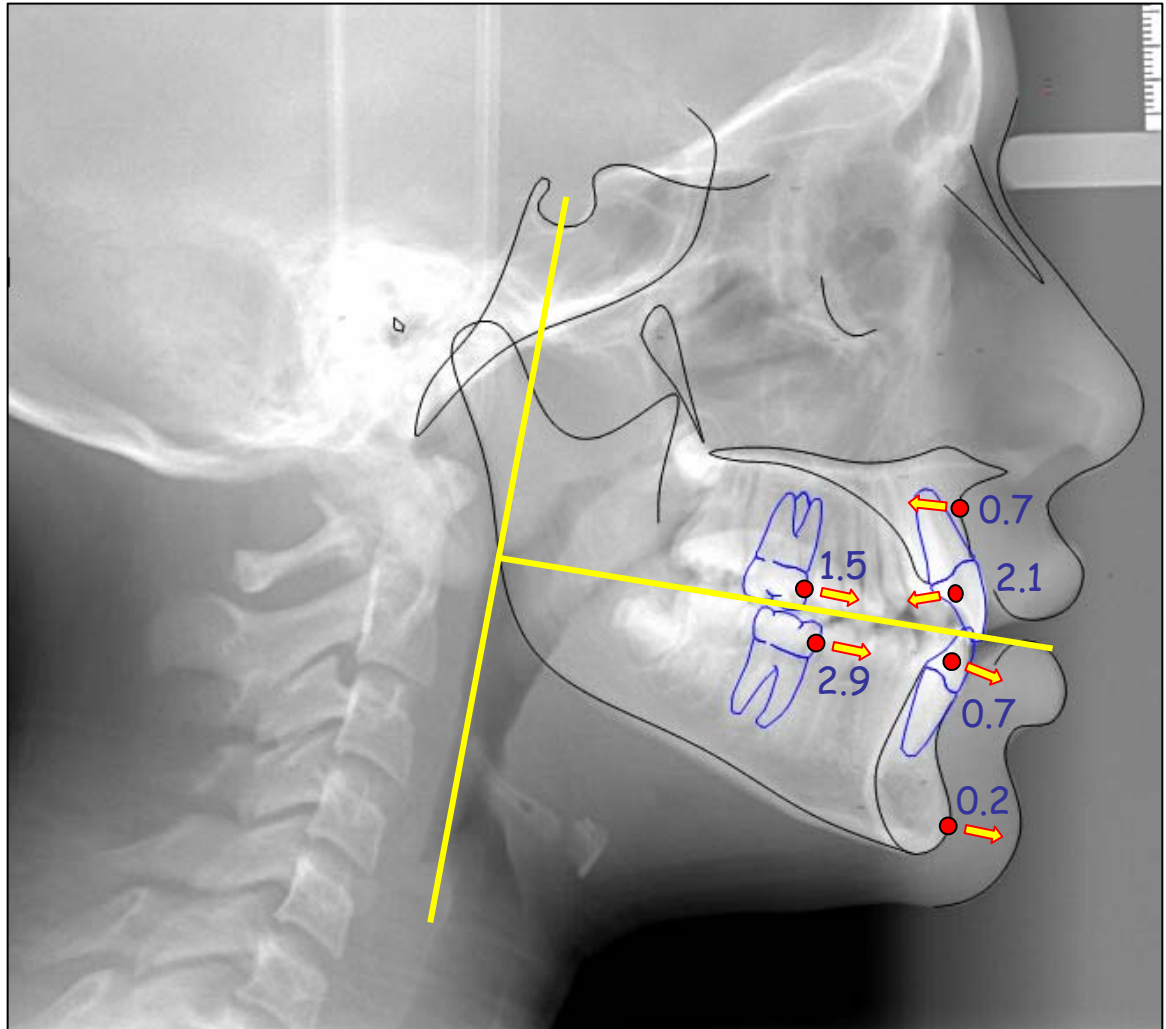


Figure 6

Diagram showing the mean direction and amount of tooth and skeletal movements (mm) between the T1 and T2 in the headgear group

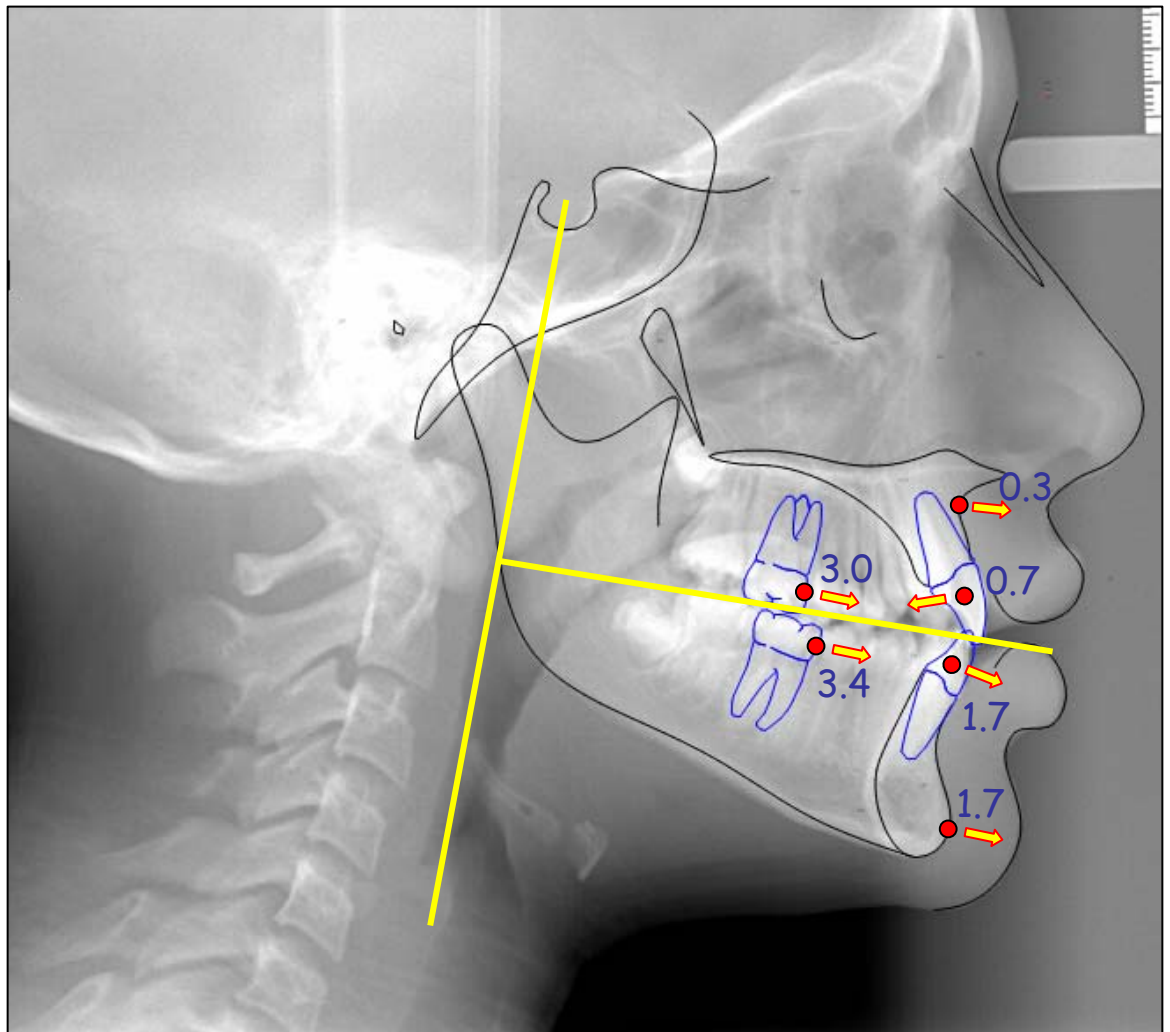


Table 1

Differences between the 1st & 2nd readings of the 20 implant and 20 headgear radiographs and a paired *t* test for systematic error

		Mean	Sd	95% CI		Min	Max	p
		Difference (mm)		Lower	Upper			
Position of Maxillary Base (A-OLp)	Implant Reading 1 v Reading 2	0.4	1.5	-0.3	1.1	-2.9	3.7	0.239
	Hg Reading 1 v Reading 2	0.4	1.4	-0.2	1.1	-2.5	2.2	0.173
Position of Mandibular Base (Pg-OLp)	Implant Reading 1 v Reading 2	0.4	2.7	-0.9	1.6	-5.5	4.7	0.563
	Hg Reading 1 v Reading 2	0.2	2.1	-0.7	1.2	-3.8	3.6	0.634
Position of Maxillary Central Incisor (IsSu-OLp)	Implant Reading 1 v Reading 2	0.1	1.8	-0.8	0.9	-4.1	3.0	0.884
	Hg Reading 1 v Reading 2	0.0	1.4	-0.7	0.6	-2.7	2.2	0.987
Position of Mandibular Central Incisor (Li-OLp)	Implant Reading 1 v Reading 2	0.1	1.7	-0.7	1.0	-4.0	2.6	0.722
	Hg Reading 1 v Reading 2	-0.1	1.4	-0.7	0.6	-2.5	2.5	0.828
Position of Maxillary Permanent Molar (Sm-OLp)	Implant Reading 1 v Reading 2	-0.2	1.5	-0.9	0.5	-3.5	2.3	0.589
	Hg Reading 1 v Reading 2	-0.3	1.4	-1.0	0.4	-2.6	2.2	0.363
Position of Mandibular Permanent Molar (Lm-OLp)	Implant Reading 1 v Reading 2	-0.1	2.2	-1.2	0.9	-6.7	2.8	0.814
	Hg Reading 1 v Reading 2	0.2	1.4	-0.4	0.9	-2.6	3.0	0.455

Table 2

Intraclass correlation coefficients for the repeat readings of the 20 implant and 20 headgear radiographs

	Implant	Headgear
Position of Maxillary Base (A-OLp)	0.88	0.93
Position of Mandibular Base (Pg-OLp)	0.86	0.84
Position of Maxillary Central Incisor (IsSu-OLp)	0.87	0.96
Position of Mandibular Central Incisor (Li-OLp)	0.89	0.95
Position of Maxillary Permanent Molar (Sm-OLp)	0.89	0.93
Position of Mandibular Permanent Molar (Lm-OLp)	0.89	0.93

Table 3

Descriptive statistics of the readings from T1 (pre-treatment) and T2 (end of anchorage) radiographs for the implant and headgear groups (n=23 implant and 24 headgear patients).

		Mean (mm)	Sd	95% CI	Min	Max
Position of Maxillary Base (A-OLp)	Implant T1	71.8	3.2	70.4 - 73.2	65.2	77.3
	Implant T2	71.1	3.7	69.5 - 72.7	63.4	78.7
	Hg T1	71.5	4.6	69.5 - 73.5	60.4	78.8
	Hg T2	71.7	4.5	69.8 - 73.6	63.1	79.6
Position of Mandibular Base (Pg-OLp)	Implant T1	72.3	3.8	70.6 - 74.0	63.8	78.5
	Implant T2	72.5	5.4	70.2 - 74.9	62.1	80.4
	Hg T1	72.2	4.3	70.3 - 74.1	63.4	79.7
	Hg T2	73.8	4.7	71.8 - 75.9	64.5	82.6
Position of Maxillary Central Incisor (IsSu-OLp)	Implant T1	77.1	3.8	75.4 - 78.7	70.2	86.1
	Implant T2	74.9	4.1	73.1 - 76.7	66.2	84.4
	Hg T1	76.6	6.1	74.0 - 79.3	61.3	89.5
	Hg T2	76.1	4.9	74.0 - 78.2	67.9	83.9
Position of Mandibular Central Incisor (Li-OLp)	Implant T1	72.1	3.8	70.4 - 73.7	64.4	78.8
	Implant T2	72.8	4.5	70.8 - 74.7	64.0	83.1
	Hg T1	71.8	5.1	69.6 - 74.0	58.5	79.9
	Hg T2	73.4	4.8	71.3 - 75.5	65.2	82.0
Position of Maxillary Permanent Molar (Sm-OLp)	Implant T1	49.9	4.7	47.8 - 51.9	37.2	55.0
	Implant T2	51.4	5.2	49.2 - 51.9	41.7	59.8
	Hg T1	49.9	4.6	47.9 - 51.9	40.3	59.0
	Hg T2	52.9	4.1	51.1 - 54.6	44.3	61.9
Position of Mandibular Permanent Molar (Lm-OLp)	Implant T1	50.2	4.6	48.2 - 52.2	38.2	57.0
	Implant T2	53.1	4.7	51.0 - 55.1	43.2	60.3
	Hg T1	50.1	4.3	48.3 - 52.0	40.5	59.7
	Hg T2	53.3	4.0	51.6 - 55.1	43.8	59.1

Table 4

Changes between T1 (pre-treatment) and T2 (end of anchorage) radiographs for implant and headgear groups (n=23 implant and 24 headgear patients).

		Mean change (mm)	Sd	95% CI of the Difference		Min	Max	p
				Lower	Upper			
Position of Maxillary Base (A-OLp)	Implant T2 - T1	-0.7	1.6	-1.4	0.0	-3.5	3.2	0.048
	Hg T2 - T1	0.3	2.5	-0.8	1.3	-8.3	8.3	0.611
Position of Mandibular Base (Pg-OLp)	Implant T2 - T1	0.2	2.5	-0.9	1.3	-4.1	5.7	0.684
	Hg T2 - T1	1.7	3.8	0.1	3.3	-4.6	13.6	0.040
Position of Maxillary Central Incisor (IsSu-OLp)	Implant T2 - T1	-2.1	2.0	-3.0	-1.3	-5.8	3.2	<0.001
	Hg T2 - T1	-0.7	4.9	-2.8	1.4	-7.1	12.7	0.493
Position of Mandibular Central Incisor (Li-OLp)	Implant T2 - T1	0.7	2.6	-0.4	1.8	-6.4	5.4	0.219
	Hg T2 - T1	1.7	3.9	0.0	3.3	-4.1	12.9	0.045
Position of Maxillary Permanent Molar (Sm-OLp)	Implant T2 - T1	1.5	2.6	0.4	2.7	-4.2	6.5	0.009
	Hg T2 - T1	3.0	3.4	1.6	4.5	-2.0	11.1	<0.001
Position of Mandibular Permanent Molar (Lm-OLp)	Implant T2 - T1	2.9	2.5	1.8	4.0	-1.6	8.2	<0.001
	Hg T2 - T1	3.4	3.3	2.0	4.8	-2.0	9.7	<0.001

Table 5

Differences in treatment changes between the Implant and Headgear groups (n=23 implant and 24 headgear patients).

	Mean	95% CI of the		p
	Difference (mm)	Lower	Upper	
Position of Maxillary Base (A-OLp)	1.0	-0.3	2.2	0.124
Position of Mandibular Base (Pg-OLp)	1.5	-0.4	3.4	0.123
Position of Maxillary Central Incisor (IsSu-OLp)	1.4	-0.8	3.7	0.195*
Position of Mandibular Central Incisor (Li-OLp)	1.0	-0.9	2.9	0.309
Position of Maxillary Permanent Molar (Sm-OLp)	1.5	-0.3	3.2	0.110
Position of Mandibular Permanent Molar (Lm-OLp)	0.5	-1.2	2.2	0.547

*Equal variances not assumed