



Deposited via The University of Sheffield.

White Rose Research Online URL for this paper:

<https://eprints.whiterose.ac.uk/id/eprint/210758/>

Version: Published Version

Article:

Griffin, J. (2023) Digital pathology: a crucial piece of the rural and remote cancer care puzzle. *Rural and Remote Health*, 23 (4). 8724. ISSN: 1445-6354

<https://doi.org/10.22605/rrh8724>

Reuse

This article is distributed under the terms of the Creative Commons Attribution (CC BY) licence. This licence allows you to distribute, remix, tweak, and build upon the work, even commercially, as long as you credit the authors for the original work. More information and the full terms of the licence here:

<https://creativecommons.org/licenses/>

Takedown

If you consider content in White Rose Research Online to be in breach of UK law, please notify us by emailing eprints@whiterose.ac.uk including the URL of the record and the reason for the withdrawal request.

EDITORIAL

Digital pathology: a crucial piece of the rural and remote cancer care puzzle

AUTHOR



Jon Griffin¹ PhD, FRCPath, NIHR Clinical Lecturer in Histopathology *

CORRESPONDENCE

*Dr Jon Griffin jon.griffin@nhs.net

AFFILIATIONS

¹ School of Medicine and Population Health, Faculty of Health, University of Sheffield, Beech Hill Rd, Sheffield, UK

PUBLISHED

7 November 2023 Volume 23 Issue 4

HISTORY

RECEIVED: 12 September 2023

ACCEPTED: 13 September 2023

CITATION

Griffin J. Digital pathology: a crucial piece of the rural and remote cancer care puzzle. *Rural and Remote Health* 2023; 23: 8724. <https://doi.org/10.22605/RRH8724>

ETHICS APPROVAL

Not applicable

This work is licensed under a [Creative Commons Attribution 4.0 International Licence](https://creativecommons.org/licenses/by/4.0/)

FULL ARTICLE:

Pathology and laboratory medicine are essential components of effective cancer care. Histopathology is the gold standard for cancer diagnosis; the contents of a histopathology report are geared towards informing patient care. Cancer stage and grade, assessment of surgical margins and assessment of other histological features that portend worse outcomes are all determined by histopathologists. Furthermore, molecular markers of response to targeted therapies are often measured in tissue submitted for histopathology, and molecular pathology has become an essential part of modern pathology practice. Despite this central importance of pathology in cancer care, laboratory medicine is understaffed and underresourced globally. This paucity of capacity is amplified in rural and remote healthcare settings and contributes to inequalities in rural cancer outcomes¹.

Over the past two decades digital pathology has emerged as a novel technology in histopathology. Instead of viewing glass slides using a traditional microscope, pathologists now have the option of scanning the same slides at high resolution, making whole slide images (known as whole slide imaging, WSI) and viewing these on

a screen. The digital slide can be viewed anywhere with a suitable internet connection, and this has proposed benefits in safety, quality and efficiency². For example, second or specialist opinions can be sought more easily and the removal of physical slides from a laboratory workflow may reduce administrative burden and errors owing to lost or misidentified slides. Digital pathology initially found uses in teaching, external quality assurance and intradepartmental review for multidisciplinary team meetings. Subsequently it has been validated as a safe alternative for primary diagnosis^{3,4}. The COVID-19 pandemic acted as a catalyst for primary digital reporting as pathology departments looked for ways to maintain diagnostic capacity while ensuring social distancing⁵. In addition, digital pathology can facilitate a hub-and-spoke or networked model of pathology⁶ (Fig1).

Digital pathology therefore can remove the need for colocalization of pathologist and pathology slide. This has obvious applications in the rural and remote healthcare setting, where distance from and access to specialist services may be limited. In this issue of *Rural and Remote Health*, Kawakami et al report the

implementation of WSI and remote pathologist review for intraoperative frozen section diagnosis of sentinel lymph nodes in breast cancer⁷. Following the Fukushima triple disaster of an earthquake, tsunami and consequent nuclear disaster, this region suffered well-documented severe consequences including 18 000 deaths and the displacement of 150 000 people⁸. Among the deleterious effects on healthcare provision was a reduction in pathology workforce. Using WSI, frozen sections could be assessed by pathologists at a hospital 5 km away, thus maintaining breast cancer surgery in the local hospital.

Frozen section diagnosis is one of the most challenging tasks in diagnostic histopathology. A diagnosis must be made under time pressure, using slides whose preparation is suboptimal owing to rapid fixation and processing. Furthermore, a frozen section diagnosis often has an immediate and profound effect on patient care because it informs the extent of surgery. In lung cancer surgery, the frozen section result can determine if a patient has a small wedge of lung removed or an entire lobe, highlighting the importance of this element of pathology⁹. Frozen section of sentinel lymph nodes in breast cancer is established practice and can determine if a patient requires axillary lymph node dissection intraoperatively, potentially sparing the patient a second operation¹⁰.

In their study, Kawakami et al demonstrated good concordance between glass and digital slide diagnoses⁷. Crucially the authors compared diagnoses from digital frozen section with those from the corresponding traditional light microscopic interpretation and not simply the final diagnosis. This is a subtle yet important point: when making the final diagnosis the pathologist has the benefit of seeing the entire specimen in optimally fixed and sectioned slides. Therefore, comparing this with one frozen section slide is not a fair assessment of the microscopy method used to interpret the frozen section. Similarly to other work in this space¹¹, Kawakami et al showed that it is the challenges of frozen section diagnosis itself rather than the digitization of slides that leads to most discordant diagnoses.

The data reported by Kawakami et al mirror that of previous studies. One of the largest examples of a remote intraoperative consultation is the Eastern Québec Telepathology Network¹². This long-running initiative provides frozen section diagnosis in a sparsely populated region where nearly 30% of hospitals do not have a pathology department. Reporting of frozen section WSI images by pathologists more than 200 km from the operating theatre showed good concordance with glass slide diagnoses across a range of specimen types, including lymph nodes in lung and breast cancer, and surgical resection margins. A recent report of more than 2000 cases over 12 years showed similar concordance after slide scanning and remote diagnosis was implemented in South Tyrol in Italy, linking three peripheral hospitals with a central hub over distances of up to 75 km¹³. Both studies showed good concordance between digital and traditional glass slide diagnoses. A further study demonstrated similar concordance in the frozen section setting and contains a comprehensive literature review¹¹.

Rural and remote cancer care takes place in a variety of contexts, economies and levels of health resource. In high-income countries patients in rural areas often have worse cancer survival compared to patients in urban areas. A systematic review showed this to be the case for at least lung, colorectal and prostate cancer¹⁴. The

disparities between urban and rural healthcare are magnified in middle- and low-income countries, and countries with poorly resourced healthcare systems. The reasons underlying this disparity are multifactorial, but access to laboratory medicine and cancer histopathology services are critically important factors¹⁵. This raises two questions: Can digital pathology help address a lack of access to diagnostic histopathology? Is digital pathology with remote reporting feasible and useful in these settings?

As with much innovation, digital pathology is an evolution of an earlier technology: telepathology. In the pre-WSI era this allowed transmission of still photographs of regions of interest from a glass slide, or remote robotic control of a light microscope with an attached digital camera¹⁶. Still-image telepathology has an unsurprising reduction in diagnostic fidelity compared to WSI as only selected areas are imaged at a reduced range of magnifications. However, still-image diagnosis can still achieve good accuracy¹⁷. Training of technical staff to acquire useful images is crucial, which can be challenging in rural and remote settings. The choice between WSI and traditional telepathology is therefore not necessarily clear-cut. Infrastructure may present a major challenge to implementation. The storage and transmission of digital pathology slides are non-trivial problems. Without image compression a single WSI image may be more than 4 GB in size. The required image storage capacity for a laboratory expands rapidly as workload increases. The need to archive scanned slides compounds storage requirements. Sufficient bandwidth is also required to transmit digital slides.

In the study by Kawakami et al, a dedicated digital fibre was used for image transfer⁷. However, in settings where this isn't available, slide transmission may be unreliable, nullifying the benefits of slide scanning. In their study of digital pathology in Rwanda, Mpunga et al¹⁸ implemented static image acquisition rather than WSI owing to an unreliable internet connection with low bandwidth¹⁸. A study in Cameroon described the development of a system where initially still images were taken from a light microscope with an iPhone and digitally transferred to Austria for diagnosis¹⁹. When WSI was introduced the time to diagnosis and non-diagnostic images were reduced, indicating an improvement in the system. However, the authors identified an unreliable power supply as an issue when scanning and transferring WSI images. The changing landscape of internet connectivity may provide an opportunity to overcome low bandwidth in rural and remote areas. Up to 90% of internet connectivity in Africa is mobile rather than wired broadband²⁰. As 5G networks replace the existing 3G and 4G infrastructure this enhanced connectivity could facilitate digital slide transmission in local/regional pathology networks or abroad, as required. Together these various challenges represent considerations for implementation of digital pathology (Table 1).

Digital pathology also offers benefits beyond the provision of a diagnostic service. Training and mentorship have been identified as key areas for development in rural and remote pathology. Surveys of laboratory medicine professionals in low- and middle-income countries have identified mentorship as a key aspect of improving pathology services¹⁵. Digital pathology can facilitate mentorship and training by various routes. There are thousands of WSI images available online to aid learning as part of histopathology training programs²¹. This same technology can be adapted to provide course-specific training and WSI incorporated into asynchronous learning programs. Furthermore, WSI images can be annotated to provide granular instruction when this may not be available

locally. Many external quality assurance schemes now provide digital slides and are another route to accessing expertise and staying up to date with diagnostic practice. One issue identified with implementing a pathology training program in Zambia was the difficulty of securing time for external clinicians to attend physically to supplement training provided by local doctors²². This program started in 2011, while WSI was still a nascent technology. If implemented today, access to external trainers could be provided digitally, leveraging WSI and videoconferencing.

In addition to widening access to training materials, the digitization of glass slides presents new opportunities in image analysis and deep learning. The past 10 years have seen an explosion of interest in applying deep learning techniques to histology slides to predict survival and response to treatment, and also to better quantify assessment traditionally made by the naked eye such as tumour grade and quantification of protein expression by immunohistochemistry²³. These technologies could be enormously useful in the remote and rural healthcare setting, potentially acting as triage for cases that need urgent review or supplementing existing expertise, particularly if local exposure to a certain case type is limited. To date, there is little evidence assessing deep learning and image analysis specifically in rural and

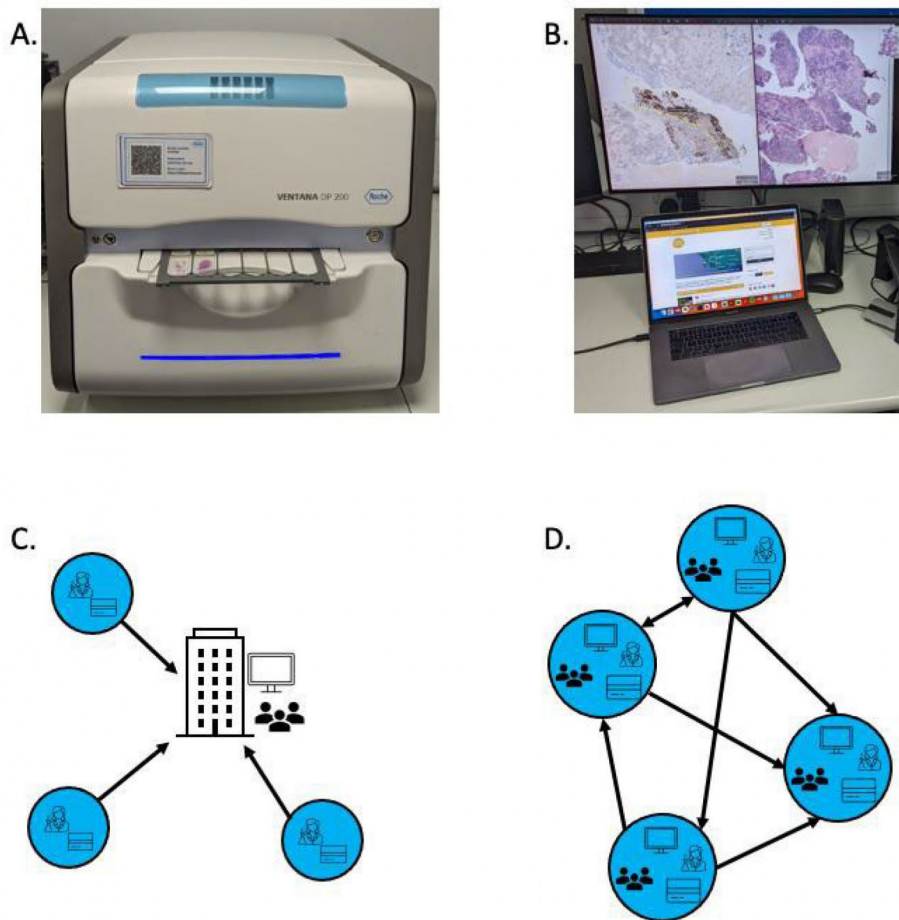
remote cancer care. There will be variability between settings but it is important that systems and tools developed in urban settings are also validated for use in less populated environments, as the case mix and system requirements may well be different. Remote environments may have common themes for which pathology services require support (eg frozen section diagnosis), and deep learning adjuncts should be tailored towards these areas.

Digital pathology has the potential to transform rural and remote cancer pathology, providing faster diagnoses, building local expertise through training and mentorship and potentially through computer-aided diagnostics. There are many challenges including infrastructure and the specifics of implementation for each healthcare setting. Rural and remote digital pathology is relatively underrepresented in the literature and future research should be designed with this in mind, including the areas of:

- systematic review of digital pathology in rural and remote health care
- development of deep learning tools for specific rural and remote digital pathology applications
- use of digital pathology in training and mentorship
- analysis of available and projected infrastructure and its ability to support digital pathology.

Table 1: Considerations in implementing a digital pathology system

Component	Considerations
Pathology network design	Hub-and-spoke v reporting network; sharing of skills and expertise across centres; governance and management responsibilities
Slide preparation	Training of laboratory staff, awareness of preparation artefacts affecting the scanning process
Slide scanner	Required throughput, scan speed, scan resolution, size of image file
IT network	Reliable internet connectivity; access to 5G networks; security
Slide viewing	Appropriate software for navigating slides and cases; suitable monitors with correct resolution, field of view and colour balance
Laboratory information system	Local, or central and linked with hub hospital; integration with health records; integration with slide viewing software
Archiving	Onsite and offsite storage; costs of archiving; projection of storage needs as system matures



A. Example of a slide scanner. This has a desktop footprint and can scan six slides at a time. Higher throughput scanners are also available, and the type of scanner is a key consideration in designing a digital pathology network (Table 1).
 B. Typical digital pathology workstation with high resolution WSI images of H&E and immunohistochemistry slides displayed on a dedicated monitor. This will also include integration with laboratory information management systems and videoconferencing software.
 C. Hub-and-spoke model of digital pathology reporting. The central hub (building icon) houses pathologists and digital pathology workstations. The spoke hospitals require laboratory and scientific staff together with slide scanners. All reporting is performed at the central hub.
 D. Network model. Each hospital in the network has scanners, pathologists, digital pathology workstations and laboratory staff. There is no central hub; instead, workload is balanced between centres depending on the nature of work taking place at each centre and available pathology expertise. A hybrid model is also possible with elements of both systems.

Figure 1: Digital pathology: the hub-and-spoke and networked models.

REFERENCES:

- Wilson ML, Fleming KA, Kuti MA, Looi LM, Lago N, Ru K. Access to pathology and laboratory medicine services: a crucial gap. *The Lancet* 2018; **391**: 1927-1938. DOI link, PMID:29550029
- Griffin J, Treanor D. Digital pathology in clinical use: where are we now and what is holding us back? *Histopathology* 2017; **70**: 134-145. DOI link, PMID:27960232
- Goacher E, Randell R, Williams B, Treanor D. The diagnostic concordance of whole slide imaging and light microscopy: a systematic review. *Archives of Pathology and Laboratory Medicine* 2017; **141**: 151-161. DOI link, PMID:27399211
- Hanna MG, Ardon O, Reuter VE, Sirintrapun SJ, England C, Klimstra DS, et al. Integrating digital pathology into clinical practice. *Modern Pathology* 2022; **35**: 152-164. DOI link, PMID:34599281
- Browning L, Fryer E, Roskell D, White K, Colling R, Rittscher J, et al. Role of digital pathology in diagnostic histopathology in the response to COVID-19: results from a survey of experience in a UK tertiary referral hospital. *Journal of Clinical Pathology* 2021; **74**: 129-132. DOI link, PMID:32616541
- Temprana-Salvador J, López-García P, Castellví Vives J, de Haro L, Ballesta E, Rojas Abusleme M, et al. DigiPatICS: Digital Pathology Transformation of the Catalan Health Institute Network of 8 Hospitals – planification, implementation, and preliminary results. *Diagnostics* 2022; **12**: 852. DOI link, PMID:35453900
- Kawakami H, Here N, Ozaki A, Yudai K, Asano S, Inai K, et al. Telepathology in intraoperative frozen section consultation of breast cancer sentinel node biopsy in Fukushima, Japan following the 2011 triple disaster: diagnostic accuracy and required time during the early implementation phase. *Rural and Remote Health* 2023; **23**: 8496. DOI link
- BBC. *Fukushima disaster: What happened at the nuclear plant?* 23 August 2023. Available: web link (Accessed 28 September 2023).

- 9** Griffin J, Kitsanta P, Perunovic B, Suvarna SK, Bury J. Digital pathology for intraoperative frozen section diagnosis of thoracic specimens: an evaluation of a system using remote sampling and whole slide imaging diagnosis. *Journal of Clinical Pathology* 2020; **73**: 503-506. DOI link, PMID:31806732
- 10** Poling JS, Tsangaris TN, Argani P, Cimino-Mathews A. Frozen section evaluation of breast carcinoma sentinel lymph nodes: a retrospective review of 1,940 cases. *Breast Cancer Research and Treatment* 2014; **148**: 355-361. DOI link, PMID:25318925
- 11** Kantasiripitak C, Laohawetwanit T, Apornvirat S, Niemnapa K. Validation of whole slide imaging for frozen section diagnosis of lymph node metastasis: a retrospective study from a tertiary care hospital in Thailand. *Annals of Diagnostic Pathology* 2022; **60**: 151987. DOI link, PMID:35700561
- 12** Perron E, Louahlia S, Nadeau L, Boilard F, Orain M, Têtu B. Telepathology for intraoperative consultations and expert opinions: the experience of the Eastern Québec telepathology network. *Archives of Pathology and Laboratory Medicine* 2014; **138**: 1223-1228. DOI link, PMID:25171705
- 13** Girolami I, Neri S, Eccher A, Brunelli M, Hanna M, Pantanowitz L, et al. Frozen section telepathology service: efficiency and benefits of an e-health policy in South Tyrol. *Digital Health* 2022; **8**. DOI link, PMID:35923756
- 14** Afshar N, English DR, Milne RL. Rural-urban residence and cancer survival in high-income countries: a systematic review. *Cancer* 2019; **125**: 2172-2184. DOI link, PMID:30933318
- 15** Sayed S, Cherniak W, Lawler M, Tan SY, El Sadr W, Wolf N, et al. Improving pathology and laboratory medicine in low-income and middle-income countries: roadmap to solutions. *The Lancet* 2018; **391**: 1939-1952. DOI link, PMID:29550027
- 16** Weinstein RS, Graham AR, Lian F, Braunhut BL, Barker GR, Krupinski EA, et al. Reconciliation of diverse telepathology system designs. Historic issues and implications for emerging markets and new applications. *Apmis* 2012; **120**: 256-275. DOI link, PMID:22429209
- 17** Voelker H-U, Stauch G, Strehl A, Azima Y, Mueller-Hermelink H-K. Diagnostic validity of static telepathology supporting hospitals without local pathologists in low-income countries. *Journal of Telemedicine and Telecare* 2020; **26**: 261-270. DOI link, PMID:30595076
- 18** Mpunga T, Hedt-Gauthier BL, Tapela N, Nshimiyimana I, Muvugabigwi G, Pritchett N, et al. Implementation and validation of telepathology triage at cancer referral center in rural Rwanda. *Journal of Global Oncology* 2016; **2**: 76-82. DOI link, PMID:28717686
- 19** Gruber-Mösenbacher U, Katzell L, McNeely M, Neier E, Jean B, Kuran A, et al. Digital pathology in Cameroon. *JCO Global Oncology* 2021; 1380-1389. DOI link, PMID:34524835
- 20** Mwangama J, Malila B, Douglas T, Rangaka M. What can 5G do for healthcare in Africa? *Nature Electronics* 2020; **3**: 7-9. DOI link
- 21** Hassell LA, Absar SF, Chauhan C, Dintzis S, Farver CF, Fathima S, et al. Pathology education powered by virtual and digital transformation now and the future. *Archives of Pathology and Laboratory Medicine* 2023; **147**: 474-491. DOI link, PMID:35878400
- 22** Mudenda V, Malyangu E, Sayed S, Fleming K. Addressing the shortage of pathologists in Africa: creation of a MMed programme in pathology in Zambia. *African Journal of Laboratory Medicine* 2020; **9**: a974. DOI link
- 23** Wen Z, Wang S, Yang DM, Xie Y, Chen M, Bishop J, et al. Deep learning in digital pathology for personalized treatment plans of cancer patients. *Seminars in Diagnostic Pathology* 2023; **40**: 109-119. DOI link, PMID:36890029