



This is a repository copy of *Review of hyperpolarized pulmonary functional ^{129}Xe MR for long-COVID.*

White Rose Research Online URL for this paper:

<https://eprints.whiterose.ac.uk/202386/>

Version: Published Version

Article:

Wild, J.M. orcid.org/0000-0002-7246-8660, Gleeson, F.V. orcid.org/0000-0002-5121-3917, Svenningsen, S. orcid.org/0000-0002-6225-1863 et al. (8 more authors) (2023) Review of hyperpolarized pulmonary functional ^{129}Xe MR for long-COVID. *Journal of Magnetic Resonance Imaging*. ISSN 1053-1807

<https://doi.org/10.1002/jmri.28940>

Reuse

This article is distributed under the terms of the Creative Commons Attribution (CC BY) licence. This licence allows you to distribute, remix, tweak, and build upon the work, even commercially, as long as you credit the authors for the original work. More information and the full terms of the licence here:

<https://creativecommons.org/licenses/>












Takedown

If you consider content in White Rose Research Online to be in breach of UK law, please notify us by emailing eprints@whiterose.ac.uk including the URL of the record and the reason for the withdrawal request.



eprints@whiterose.ac.uk
<https://eprints.whiterose.ac.uk/>

Review of Hyperpolarized Pulmonary Functional ^{129}Xe MR for Long-COVID

Jim M. Wild, PhD,¹  Fergus V. Gleeson, MBBS,²  Sarah Svenningsen, PhD,³ 
 James T. Grist, PhD,²  Laura C. Saunders, PhD,¹  Guilhem J. Collier, PhD,¹ 
 Maksym Sharma, BSc,^{4,5}  Sam Tchner, BSc,^{4,5}  Ali Mozaffaripour, BMSc,^{4,5} 
 Alexander M. Matheson, PhD,^{4,5}  and Grace Parraga, PhD^{4,5,6*} 

The respiratory consequences of acute COVID-19 infection and related symptoms tend to resolve 4 weeks post-infection. However, for some patients, new, recurrent, or persisting symptoms remain beyond the acute phase and persist for months, post-infection. The symptoms that remain have been referred to as long-COVID. A number of research sites employed ^{129}Xe magnetic resonance imaging (MRI) during the pandemic and evaluated patients post-infection, months after hospitalization or home-based care as a way to better understand the consequences of infection on ^{129}Xe MR gas-exchange and ventilation imaging. A systematic review and comprehensive search were employed using MEDLINE via PubMed (April 2023) using the National Library of Medicine's Medical Subject Headings and key words: post-COVID-19, MRI, ^{129}Xe , long-COVID, COVID pneumonia, and post-acute COVID-19 syndrome. Fifteen peer-reviewed manuscripts were identified including four editorials, a single letter to the editor, one review article, and nine original research manuscripts (2020–2023). MRI and MR spectroscopy results are summarized from these prospective, controlled studies, which involved small sample sizes ranging from 9 to 76 participants. Key findings included: 1) ^{129}Xe MRI gas-exchange and ventilation abnormalities, 3 months post-COVID-19 infection, and 2) a combination of MRI gas-exchange and ventilation abnormalities alongside persistent symptoms in patients hospitalized and not hospitalized for COVID-19, 1-year post-infection. The persistence of respiratory symptoms and ^{129}Xe MRI abnormalities in the context of normal or nearly normal pulmonary function test results and chest computed tomography (CT) was consistent. Longitudinal improvements were observed in long-term follow-up of long-COVID patients but mean ^{129}Xe gas-exchange, ventilation heterogeneity values and symptoms remained abnormal, 1-year post-infection. Pulmonary functional MRI using inhaled hyperpolarized ^{129}Xe gas has played a role in detecting gas-exchange and ventilation abnormalities providing complementary information that may help develop our understanding of the root causes of long-COVID.

Level of Evidence: 1

Technical Efficacy: Stage 5

J. MAGN. RESON. IMAGING 2023.

The coronavirus disease of 2019 (COVID-19) and the ensuing global pandemic has led to an explosion of scientific manuscripts. These publications describe the symptoms and lung findings in people infected and in those with long-COVID who remain with new or continuing symptoms once the virus has been cleared. More than 3 years into the pandemic, it still remains difficult to manage patients with

symptoms, post-COVID-19 infection (or long-COVID) and to understand the pathophysiologic source of their symptoms. This review article summarizes the constellation of symptoms and pathophysiology associated with long-COVID and observations in such patients using pulmonary functional MR imaging and spectroscopy with inhaled hyperpolarized ^{129}Xe gas.

View this article online at [wileyonlinelibrary.com](https://onlinelibrary.com/doi/10.1002/jmri.28940). DOI: 10.1002/jmri.28940

Received Jun 28, 2023, Accepted for publication Jul 24, 2023.

*Address reprint requests to: G.P., Room 5235, 1151 Richmond St N, London, ON, Canada N6A 5B7. E-mail: gparraga@uwo.ca

From the ¹POLARIS, Department of Infection, Immunity and Cardiovascular Disease, University of Sheffield, Sheffield, UK; ²Department of Radiology, Oxford University Hospitals, Oxford, UK; ³Department of Medicine, Firestone Institute for Respiratory Health, McMaster University, Hamilton, Ontario, Canada; ⁴Robarts Research Institute, Western University, London, Ontario, Canada; ⁵Department of Medical Biophysics, Western University, London, Ontario, Canada; and ⁶Division of Respiriology, Department of Medicine, Western University, London, Ontario, Canada

This is an open access article under the terms of the [Creative Commons Attribution](https://creativecommons.org/licenses/by/4.0/) License, which permits use, distribution and reproduction in any medium, provided the original work is properly cited.

COVID-19 Infection and Long-COVID

COVID-19 describes the novel coronaviral respiratory infection that emerged in December 2019 and which rapidly developed over a few months into a global pandemic. Estimates in Q1 2023 suggest that approximately 760 million people have been infected worldwide including about 103 million confirmed cases in the United States,¹ 4.6 million confirmed cases in Canada² and 240 million cases in the European Union and United Kingdom (as of April 2023; <https://covid19.who.int/>).

The respiratory consequences of acute COVID-19 infection and the related signs and symptoms experienced during infection tend to resolve by approximately 4 weeks post-infection, when the virus has also mainly cleared.³ For patients who suffered severe infection, there is chest X-ray computed tomography (CT) evidence of fibrotic and non-fibrotic abnormalities in a wide range of participants up to 2 years post-infection.^{4–7} In addition, in some patients, new or recurrent symptoms remain beyond the acute phase of infection.⁸ The signs and symptoms that remain have been referred to as post-acute COVID-19 syndrome (PACS),⁹ post-acute sequelae of COVID-19⁹ post-COVID condition, or more colloquially as “long-COVID.” These umbrella terms derive from a number of slightly different, emerging definitions for the onset of long-COVID, between 4 and 12 weeks post-infection.^{10,11}

Definitions

In Table 1, a summary is provided of the evolving and emerging definitions of “long-COVID.” As one example, the term *post-COVID-19 condition* was coined to help explain the phenomenon of persistent symptoms. The CDC defines post-COVID-19 conditions as “a wide range of new, returning, or ongoing health problems people can experience four or more weeks after first being infected with the virus that causes COVID-19.”¹²

The World Health Organization (WHO) also developed a consensus definition for the *post-COVID-19 condition*¹³ which makes note that symptoms may be new, subsequent to recovery from acute COVID-19 infection or persistent over time. The term *Long-COVID*¹⁴ may also be referred to as *post-acute COVID-19 syndrome*, *subacute COVID-19*, or *chronic COVID-19*, respectively.¹⁰

Regardless of the emerging nomenclature, the prevalence of long-COVID is difficult to ascertain with one estimate placing the number of worldwide cases at 65 million.¹⁵ Perhaps because of differences in infection severity over time, different studies have reported widely different results with more recent global meta-analyses report averages between 6% and 43%.^{16,17} As COVID-19 has become endemic, self-reported long-COVID numbers have doubled in the UK between April 2021 and 2022.¹⁸

Symptoms and Pathology

While it is now well-understood that the COVID-19 virus gains entry to the body via the respiratory system, long-COVID is now also understood to be a multi-organ syndrome presenting with a wide variety of symptoms. As shown in Fig. 1, pulmonary symptoms include fatigue, reduced exercise capacity, dyspnea, cough, hypoxia, exertional hypoxia, and chest pain.¹⁰ Other common symptoms include cardiac symptoms, myalgia, brain fog or cognitive difficulties, and bone pain. Moreover, it has been shown that long-COVID can develop in people regardless of COVID-19 infection severity.¹⁹ Early studies focused on hospitalized individuals^{20–22} but recent research has also evaluated those patients who reported a relatively mild viral infection course, not requiring hospital-based care.^{23,24} Whilst the exact pathophysiology of long-COVID is unknown, similarities to acute respiratory distress syndrome (ARDS), middle eastern respiratory syndrome (MERS), and SARS-CoV-1 (SARS1) offer clues.^{10,19}

Damage from COVID-19 infection itself may also result in long-COVID. The upper airways are the primary route of viral entry and infection,²⁵ where SARS-CoV-2 binds to angiotensin-converting enzyme 2 receptors (ACE2).²⁶ In some individuals, COVID-19 infection progresses to viral pneumonia, filling large portions of the peripheral airways and causing alveolar damage. A hyperintense immune response driven by a proliferation of cytokines (a “cytokine storm”) has been described in early waves of the COVID-19 pandemic and this has been hypothesized to be related to COVID-19 severity.^{27,28} A hyper-coagulant state has also been noted, and an elevated risk of thromboembolic events persists chronically after infection²⁹ including cardiovascular findings such as pulmonary venous infarction, thrombosis, and embolism. How this state changes from acute infection to long-COVID is still not well-understood, but proposed physiological mechanisms include viral damage to endothelial and epithelial cells, lingering inflammatory damage, microvascular injuries, and metabolic abnormalities.¹⁰ Fibrotic changes in the lung have been hypothesized^{30–32} to contribute to long-COVID.

To date, there has been published evidence to suggest that after acute COVID-19 infection, there are CT findings of ground glass opacities (GGO), honeycombing, reticulation, and fibrotic-like changes.^{7,33,34} These have mainly been observed after severe COVID-19 infection requiring hospital-based care. For example, a recent, interim analysis of the UKILD Post-COVID-19 study estimated a moderate to very high risk of residual lung abnormalities at approximately 8%–11%.³⁵ A list of the most common CT findings post-COVID infection is provided in Table 2.

Clinical and Knowledge Gaps

As shown in Fig. 2, the knowledge gap remains large. Regardless of the symptoms, etiology, and mechanisms, it has been

Date	Reference	Definition
February 2021	National Institute of Health and Care Excellence ¹¹	<i>Long-COVID:</i> 1. Ongoing symptomatic COVID-19 for people who still have symptoms between 4 and 12 weeks after the start of acute symptoms. 2. Post-COVID-19 syndrome for people who still have symptoms for more than 12 weeks after the start of acute symptoms.
March 2021	Nalbandian et al ¹⁰	<i>Post-acute COVID-19:</i> Persistent symptoms and/or delayed or long-term complications of SARS-CoV-2 infection beyond 4 weeks from the onset of symptoms.
April 2021	Al-Aly et al ⁹⁷	<i>Post-acute sequelae of COVID-19:</i> Symptoms in those who survived at least the first 30 days following a COVID-19 diagnosis.
July 2021	Centers for Disease Control and Prevention ¹²	<i>Post-COVID-19 condition:</i> A wide range of new, returning, or ongoing health problems people can experience four or more weeks after first being infected with the virus that causes COVID-19.
October 2021	Soriano et al ¹³	<i>Post-COVID-19 condition:</i> A condition that occurs in individuals with a history of probable or confirmed SARS CoV-2 infection, usually 3 months from the onset of COVID-19 with symptoms and that last for at least 2 months and cannot be explained by an alternative diagnosis.

very difficult to find the root cause of long-COVID in most patients because there is a wide range of different body system symptoms involved. Whilst symptoms can be quantified using validated chronic obstructive pulmonary disease

(COPD) questionnaires, such as the St. George's Respiratory Questionnaire (SGRQ),³⁶ many other clinical results related to pulmonary function testing (forced expiratory volume in 1 s [FEV₁], forced vital capacity [FVC]), chest computed

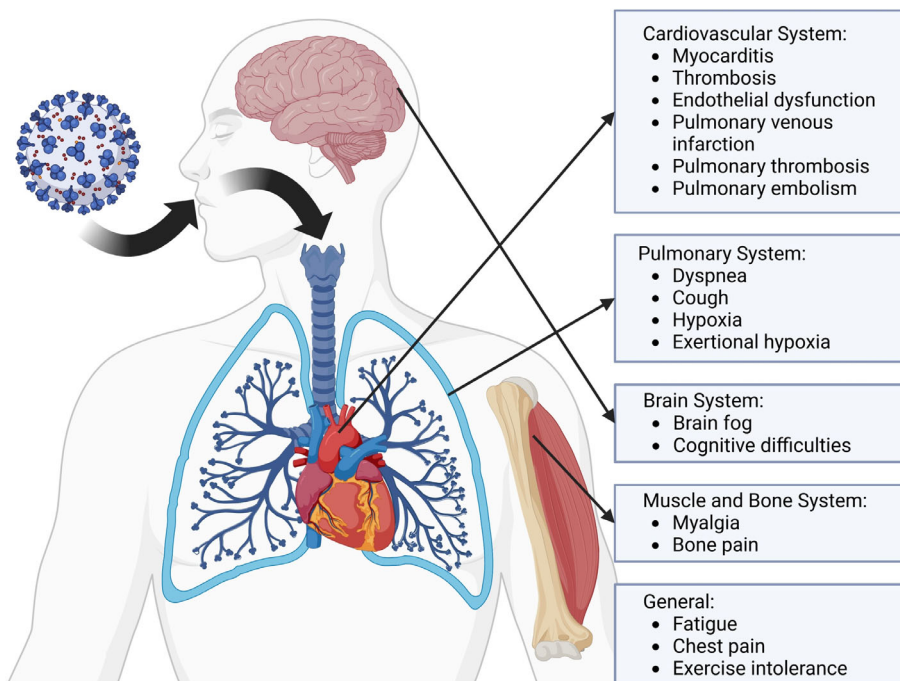


FIGURE 1: Schematic diagram of the multi-organ systems involved in long-COVID. COVID-19 infection occurs via inhalation through the respiratory system. Cardiac, respiratory, brain, gut, and musculoskeletal systems are involved in long-term COVID-19 symptoms.

Pulmonary CT Findings	Acute/ Post- Acute	Post- Infection
Pneumonia	✓	
Pneumonitis	✓	✓
Ground glass opacities	✓	✓
Honeycombing		✓
Reticulations		✓
Fibrotic traction bronchiectasis		✓
Fibrotic-like changes		✓

tomography (CT), and echocardiogram are typically found to be normal or only mildly abnormal. In the absence of abnormal test results, it remains difficult, if not impossible to explain symptoms and hence identify treatment strategies.

Given the fact that pulmonary function tests (PFT) including the diffusing capacity of the lung for carbon monoxide (DL_{CO}) is often normal or mildly abnormal in people reporting symptoms consistent with long-COVID, it was hypothesized that sensitive novel pulmonary functional MR imaging methods such as inhaled hyperpolarized gas might reveal causal or at least correlative pathologies. As shown in Fig. 3, the search for the key pathologies that drive symptoms in long-COVID necessarily focused on the heart, lung

airways, pulmonary vasculature, and the terminal airways and alveoli.

The Opportunity: Pulmonary Functional MRI Using Inhaled Hyperpolarized ^{129}Xe Gas

Injected paramagnetic contrast methods mainly rely on changes in blood-tissue perfusion and endothelial changes that may be detected by contrast-induced changes in relaxation, as in the case of conventional ^1H MRI. Instead, ^{129}Xe MRI directly and simultaneously measure inhaled (and not injected) xenon atoms in the airspaces, alveolar tissue, and red blood cells. The detection of ^{129}Xe signal in MRI is challenging, due to the much lower concentration of gas xenon atoms (as compared to tissue ^1H) and the four times lower gyromagnetic ratio of ^{129}Xe in comparison to ^1H .³⁷ Taken together these factors reduce the net magnetization available for ^{129}Xe MRI. While the first factor may have limited solutions due to the fixed amount of gas that may be inhaled, increasing the fraction of spin-up atoms (or polarization) can be addressed through hyperpolarization, which may be accomplished using a laser-excited rubidium vapor to increase the “spin-up” xenon atom population beyond thermal equilibrium.

Like ^1H atoms in a magnet, ^{129}Xe experiences locally different magnetic environments in different tissues and states that result in chemical shift. As shown in Fig. 4, at least three distinct ^{129}Xe spectroscopic resonance frequencies exist in equilibrium when ^{129}Xe gas is inhaled in the lung. The gas signal is arbitrarily set at 0 ppm, with the alveolar membrane tissue peak residing at 197 ppm, and the combination of the blood plasma and red blood cell (RBC) signals shifted to

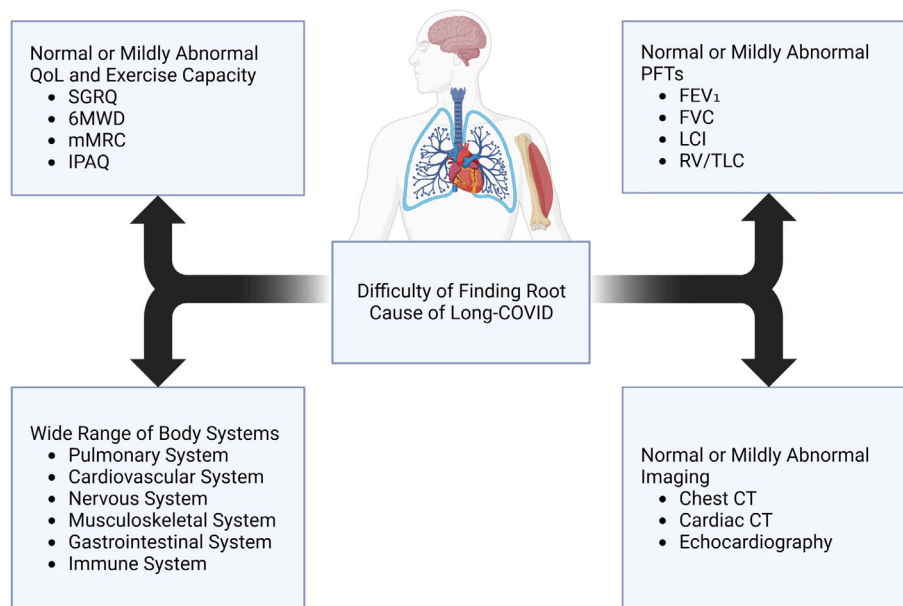


FIGURE 2: Schematic diagram of potential causes of long-COVID. The wide range of body systems and absence of abnormal test results hinder explanations and treatment of long-COVID symptoms. FEV₁ = forced expiratory volume in 1 s; FVC = forced vital capacity; LCI = Lung Clearance Index; RV = residual volume; TLC = total lung capacity; SGRQ = St. George's Respiratory Questionnaire; 6MWD = 6-minute walk distance; mMRC = modified Medical Research Council; IPAQ = International Physical Activity Questionnaire; PFT = pulmonary function test; CT = computed tomography.

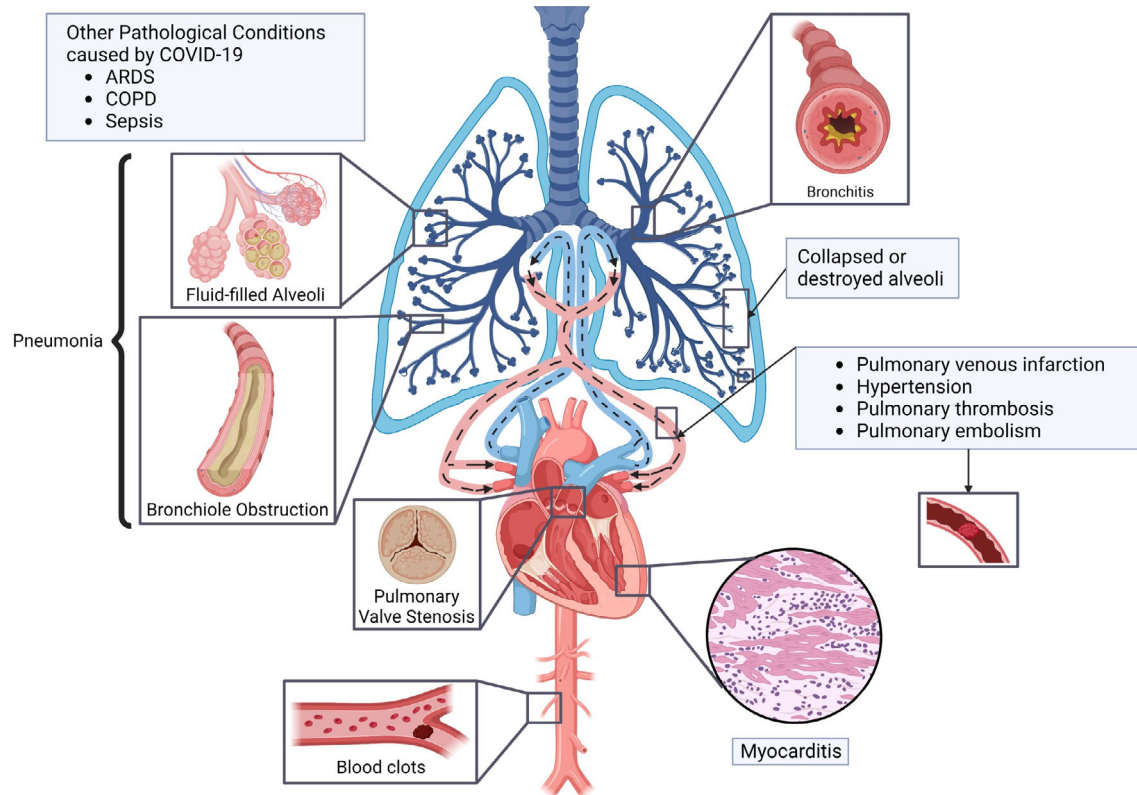


FIGURE 3: Pathologies potentially involved in long-COVID. Pulmonary airways and vessels (including micro-vascular perfusion), as well as terminal airways/alveolar, cardiac abnormalities may play a role in the expression of respiratory symptoms in long-COVID. ARDS = acute respiratory distress syndrome; COPD = chronic obstructive pulmonary disease.

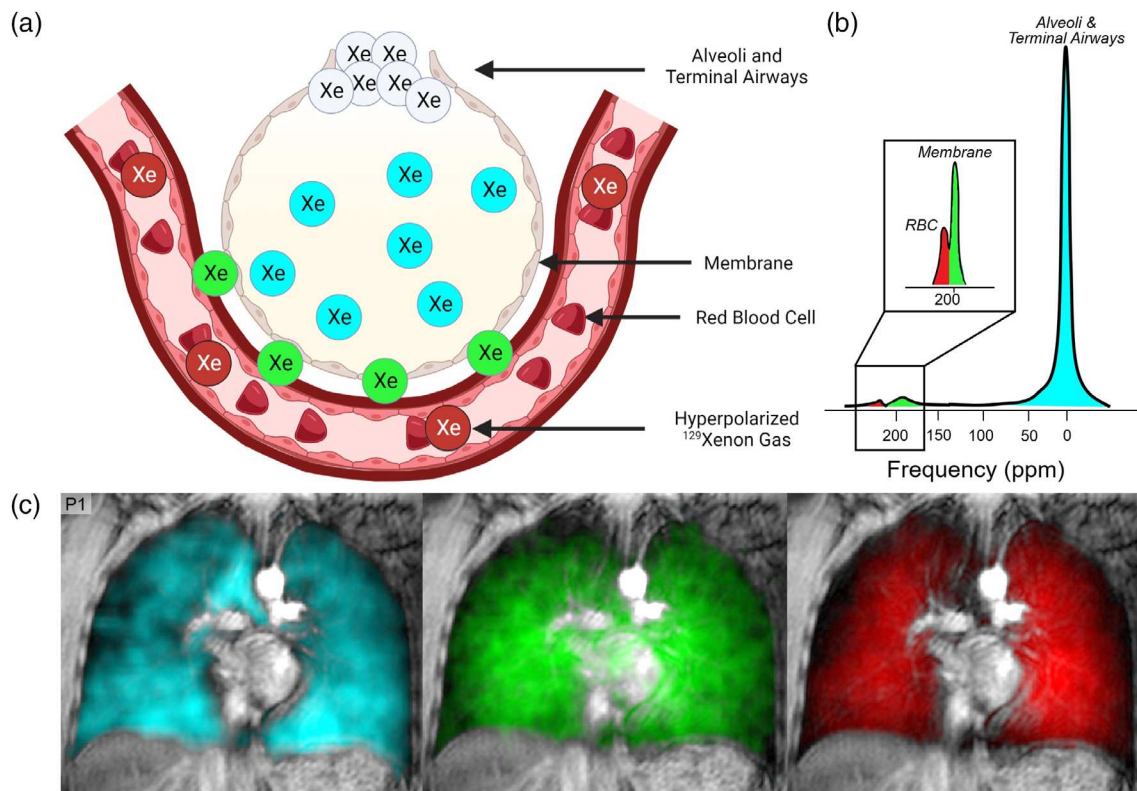


FIGURE 4: ^{129}Xe ventilation, alveolar membrane, and red blood cell images. (a) Alveolar-capillary interface whereby hyperpolarized ^{129}Xe diffuses into the alveolar membrane, and then binds to RBC hemoglobin. (b) ^{129}Xe spectroscopic resonance frequencies. Gas signal = 0 ppm, alveolar membrane peak = 197 ppm, blood plasma and RBC signal at 218–222 ppm. (c) ^{129}Xe ventilation, membrane and RBC maps where cyan = ^{129}Xe ventilation signal in alveoli and terminal airways, green = alveolar membrane, red = RBC.

approximately 218–222 ppm.^{38,39} By using a radio-frequency (RF) pulse with sufficient spectral selectivity in the frequency domain, all ^{129}Xe compartments may be excited and images generated simultaneously and with a single, inhaled ^{129}Xe gas dose.

The inhaled gas or ventilation ^{129}Xe signal was historically prescient and the first to be discovered and developed.⁴⁰ The inhaled ^{129}Xe gas signal can be exploited to generate static ventilation maps in healthy participants and patients with lung disease. As shown in Fig. 4, such images have been used to generate ventilation heterogeneity, or ventilation defect percent (VDP) measurements reflecting airway abnormalities including airway inflammation,⁴¹ obliteration,⁴² and airway luminal occlusions including mucus.⁴³

By virtue of the fact that ^{129}Xe has modest Ostwald solubility in biologic membranes, the alveolar membrane and RBC spectroscopic signals are much smaller and hence, it is modestly challenging to generate high spatial resolution images of these compartments. The most commonly reported inhaled ^{129}Xe gas spectroscopic measurement is the ratio of the RBC signal area-under-the-curve (AUC) to alveolar membrane signal (RBC:membrane).^{44–48} The RBC:membrane signal ratio represents the transfer of Xe gas through the alveolar membrane via membrane diffusion and then its high affinity binding to the four ferrous iron heme units bound to each of the ~250 million hemoglobin molecules hosted in each and every red blood cell.

This method and the measurements that may be derived from it (as summarized in Table 2), are well poised, especially in combination with chest CT, to investigate abnormalities in the airways (airways disease), pulmonary vasculature (capillary perfusion, thrombo-embolism in the larger vessels, and vascular pruning), alveolar microstructure and pulmonary gas-exchange in people with long-COVID, safely, rapidly, and longitudinally. In this review, results are

summarized from studies that prospectively acquired ^{129}Xe MRI and MR spectroscopy in people with new or recurrent symptoms at least 4 weeks post-COVID infection.

Methods

Literature Review

Systematic review methods were employed and a comprehensive search of the published literature was performed using MEDLINE via PubMed. The search was conducted for English language studies and closed on April 21, 2023, using a combination of the National Library of Medicine's Medical Subject Headings and the key words: post-COVID-19, MRI, ^{129}Xe , long-COVID, COVID pneumonia, post-acute COVID-19 syndrome. The senior author reviewed the references of the included studies and no additional relevant studies were identified. Fifteen peer-reviewed manuscripts were identified including four editorials (2021, 2022), a single letter to the editor (2023), a review article (2021), and nine original research manuscripts (2020–2023).

^{129}Xe MRI and MR spectroscopy methods are described first and then the original results from the published literature are summarized and discussed.

Ventilation MRI

During a relatively short 8–14 s breath-hold, 3D whole lung images may be acquired following inhalation of a modest 300–500 mL volume of an anoxic noble gas (now typically ^{129}Xe) mixture.^{49,50} As shown in Figs. 4 and 5, normal, healthy lungs fill immediately, completely, and homogeneously and accordingly, ventilation signal intensity is homogeneously distributed throughout the lung without patchiness or ventilation abnormalities. In contrast, in long-COVID patients shown in Fig. 6, patchy, heterogeneous ventilation may also be revealed. Typically acquired with volume-matched chest CT to

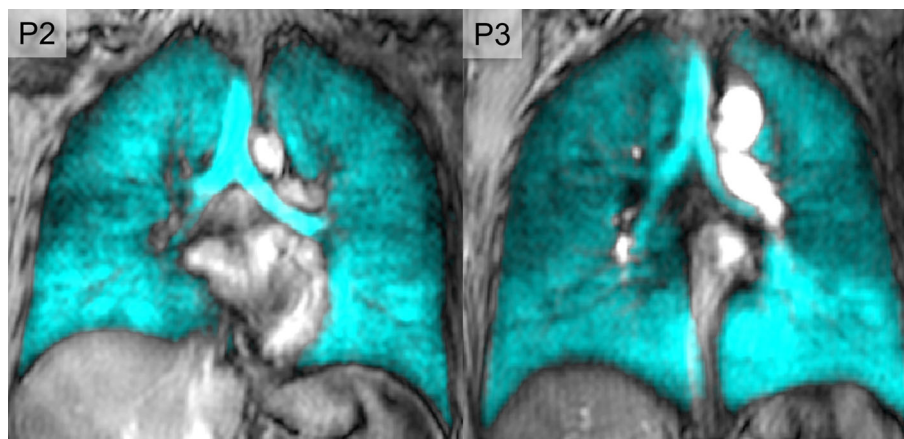


FIGURE 5: Hyperpolarized ^{129}Xe MRI ventilation MRI in representative healthy volunteers. Coronal ^{129}Xe MRI slices (cyan) co-registered with ^1H MRI thoracic cavity in two healthy participants (P2 and P3). Arrows identify ventilation abnormalities. P2 was a 30-year-old male with no prior diagnosis of chronic respiratory illness and $\text{FEV}_1 = 103\%$ and $\text{VDP} = 1\%$. FEV_1 = forced expiratory volume in 1 s; VDP = ventilation defect percent.

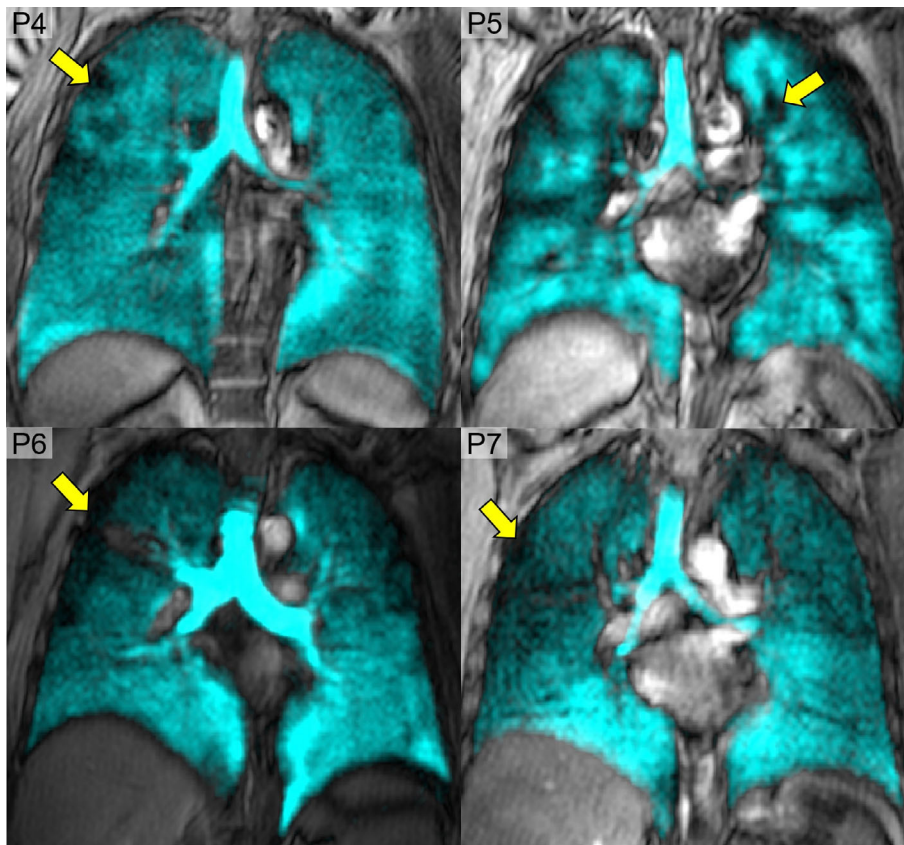


FIGURE 6: Abnormal ^{129}Xe MRI in participants with long-COVID. Coronal ^{129}Xe ventilation MRI slices (cyan) co-registered with ^1H MRI thoracic cavity in four participants with long-COVID and no previous diagnosis of chronic respiratory disease. Arrows identify ventilation abnormalities. P6 was a 53-year-old female with $\text{FEV}_1 = 84\%$, $\text{DL}_{\text{CO}} = 83\%$, $\text{SpO}_2 = 98\%$, $\text{LCI} = 8$, and $\text{VDP} = 3\%$. P7 was a 73-year-old male with $\text{FEV}_1 = 88\%$, $\text{DL}_{\text{CO}} = \text{ND}$, $\text{SpO}_2 = 98\%$, $\text{LCI} = \text{ND}$, and $\text{VDP} = 10\%$. P8 was a 65-year-old female with $\text{FEV}_1 = 95\%$, $\text{DL}_{\text{CO}} = 97\%$, $\text{SpO}_2 = 98\%$, $\text{LCI} = 9$, and $\text{VDP} = 7\%$. P9 was a 46-year-old male with $\text{FEV}_1 = 106\%$, $\text{DL}_{\text{CO}} = 96\%$, $\text{SpO}_2 = 98\%$, $\text{LCI} = 8$ and $\text{VDP} = 3\%$. ND = not done; SpO_2 = oxygen saturation measured using digital pulse oximetry; LCI = lung clearance index; VDP = ventilation defect percent.

generate the airway tree, hyperpolarized ^{129}Xe ventilation MRI provides a map of those regions that still function normally and those that do not.

As shown in Fig. 6 and summarized in Table 3, a number of ventilation heterogeneity measurements can be made,^{51–53} including ventilation defect percent (VDP)⁵⁴ generated using a signal intensity cluster algorithm, whereby the lowest signal intensity cluster is used to estimate the volume of signal void or ventilation defects and is normalized to the total thoracic cavity volume. Hyperpolarized ^{129}Xe MRI VDP is relevant for the study of potential airway disease and inflammation in long-COVID patients.

Gas-Exchange MRI

MR imaging and spectroscopy of an inhaled ^{129}Xe bolus, some of which has diffused into the membrane and RBC compartments (Fig. 4) has been historically challenging due to a number of technical and physiologic reasons. First, ^{129}Xe polarization values on the order of 10%–30% result in weak-modest membrane and RBC signals, due in part, to the low density of membrane and RBC tissue and the difficulty in

separating two spectral peaks separated by ~ 20 ppm are problematic. Relaxation via T_2^* (1.5–2.4 msec at 1.5 T)⁵⁵ is also augmented for ^{129}Xe in the tissue and RBC compartments and this limitation is further complicated by the practical requirement to complete imaging in patients during a single 8–15 s breath-hold scan. Technical improvements in polarization^{56–58} hardware, k-space trajectories^{59,60} and decomposition algorithms^{45,61–63} have made ^{129}Xe gas-exchange imaging, spectroscopy, and pulmonary measurements more feasible.

The splitting or parsing of the alveolar membrane and RBC ^{129}Xe signals is intuitively and practically similar to distinguishing the water and fat components measured using ^1H MRI, which has been solved using the so-called Dixon method.⁶⁴ Three-point Dixon and Iterative Decomposition of water and fat with Echo Asymmetry and Least-squares estimation (IDEAL) acquisitions were shown to be highly successful in differentiating RBC and tissue/membrane components of gas-exchange data.^{65,66} A one-point Dixon technique has emerged in consensus⁶⁷ as the method of choice for dissolved-phase ^{129}Xe MRI. Using the gas

TABLE 3. Overview of Hyperpolarized Noble Gas MRI Measurements

Hyperpolarized ^{129}Xe MRI	Significance to COVID-19
Quantitative measurements <ul style="list-style-type: none"> • Ventilation defect volume (VDV) • Percent ventilation volume (PVV) • Ventilated volume (VV) • Ventilation defect percent (VDP) • RBC:membrane, membrane:gas, RBC:gas, membrane:gas ratios 	<ul style="list-style-type: none"> • VDV, PVV, VV, and VDP offer a method of quantifying regional ventilation heterogeneity • The RBC:membrane, RBC:gas, membrane:gas ratios offer a method of quantifying gas exchange efficiency
Qualitative measurements <ul style="list-style-type: none"> • Regional patterns of ventilation and ventilation heterogeneity • Gas exchange efficiency between alveoli and pulmonary capillaries • Microstructural and functional information • Qualitative assessment and characterization of lung diseases 	<ul style="list-style-type: none"> • Provides insights beyond those attainable through conventional pulmonary function tests • Investigates the underlying pathophysiological mechanisms
Clinical opportunities <ul style="list-style-type: none"> • Non-invasive method for lung disease characterization • ^{129}Xe is well tolerated • High spatial and temporal resolution • Dynamic treatment response assessment without ionizing radiation 	<ul style="list-style-type: none"> • Early detection and characterization of lung abnormalities associated with COVID-19 • Evaluation of post-acute infection impairments • Identifies regions for targeted treatment response
Clinical challenges <ul style="list-style-type: none"> • Time-consuming image acquisition and analysis processes • Image analysis software, specialized equipment, and training required • Regulatory approval in UK as investigational medicinal product • FDA approved in USA 	<ul style="list-style-type: none"> • Some potential for clinical integration

compartment data acquired from interleaved imaging, a phase correction to account for field inhomogeneities may be applied to all compartments such that the gas compartment has a uniform phase. Finally, membrane and RBC compartments may not be exactly aligned to the coil acquisition channels, so the raw data are iteratively rotated in the complex plane until the whole-lung RBC:membrane value calculated from images matches that obtained during the spectroscopy calibration scan.

The ^{129}Xe MRI RBC:membrane ratio has been observed to correlate with DL_{CO} ⁶⁸ and abnormally values have been reported in patients with non-specific interstitial pneumonia⁶⁹ and pulmonary fibrosis,⁶¹ which is relevant to long-COVID.

Results

As of April 2023, there were nine original manuscripts published which describe hyperpolarized ^{129}Xe MR in long-COVID. Of the nine original articles, five described cross-

sectional data,^{70–74} and four papers and one editorial response described longitudinal findings.^{75–77} Six of the published manuscripts described gas-exchange abnormalities and three papers were focused solely on ventilation MRI.

First, we summarize the pulmonary functional MRI evidence that ventilation abnormalities may play a role in long-COVID. Then we focus attention on the ^{129}Xe MRI evidence of gas-exchange abnormalities in long-COVID and how these change over time. Table 4 provides an overview of cross-sectional and longitudinal study design and results. Because of study heterogeneity (time post-infection, inclusion, and exclusion criteria), we describe all the study results first and then summarize key, consistent findings across studies.

^{129}Xe MRI Ventilation Defects: Evidence of Airways Disease

The first preliminary report of such ventilation abnormalities was published in January 2021, less than 10 months after the declaration of a pandemic, and detailed ^{129}Xe MRI results

TABLE 4. Recruitment and Publication Information of Peer-Reviewed Manuscripts

Study	Time Point	Participant Status	Control	Location	Recruitment Window	Publish Date
Ventilation MRI main result: abnormal ventilation (VDP) in most participants which improved, 15 months post-infection but did not normalize						
Li et al ⁷⁰	Baseline	25 (13H/0NH)	Yes	China	Feb 2020–Mar 2020	Jan 2021
Kooner et al ⁷²	Baseline	76 (23H/53NH)	Yes	Canada	Jun 2020–Aug 2021	May 2022
Kooner et al ⁷⁶	Baseline	76 (23H/53NH)	Yes	Canada	Jun 2020–Aug 2021	Feb 2023
	Follow-up	53 (17H/36NH)	No			
Gas-exchange MRI main result: abnormal RBC:membrane in most participants, improved over time but not normalized, 12–15 months post-infection						
Grist et al ⁷³	Baseline	9 (9 H/0 NH)	Yes	UK	Aug 2020–Dec 2020	Oct 2021
Chen et al ¹⁷	Baseline	9 (9H/0NH)	No	China	Jun 2020–Aug 2021	Mar 2022
	Follow-up	4 (4H/0NH)	No			
Grist et al ⁷⁴	Baseline	23 (12H/11NH)	Yes	UK	Jun 2020–Aug 2021	Dec 2022
Matheson et al ⁷¹	Baseline	34 (12H/22NH)	Yes	Canada	Apr 2021–Oct 2021	Nov 2022
	Follow-up	23 (12H/11NH)	No			
Matheson et al ⁷⁵	Baseline	34 (12H/22NH)	No	Canada	Mar 2020–Apr 2021	Jan 2023
	Follow-up	21 (9H/12NH)	No			
Saunders et al ⁷⁸	Baseline	16 (16H/0NH)	No	UK	Nov 2020–Feb 2022	Mar 2023
	Follow-up	9 (9H/0NH)	No			

H = hospitalized for COVID-19; NH = never-hospitalized for COVID-19.

post-discharge from hospital in patients from Wuhan, China. These patients were evaluated on average 20–30 days after discharge from hospital for severe COVID-19 infection requiring hospital-based care.⁷⁰ While the main focus of this work was on ¹²⁹Xe MRI gas-exchange abnormalities, Li and colleagues also evaluated 13 patients and 12 healthy volunteers using pulmonary function tests and static ventilation MRI. They reported that ¹²⁹Xe MRI VDP was significantly greater (worse) in the 13 recently discharged post-COVID patients (compared to 12 healthy participants) although none of these patients met the then still emerging definition of long-COVID. Importantly, this manuscript provided the first early signs of potential ventilation abnormalities in patients with post-COVID-19 infection on average 25-days post-discharge from hospital for COVID-19 infection.

Another study published in 2022 described 76 COVID-19 survivors infected with COVID-19 variants (waves 1–4) who lived and were evaluated in two urban research centers in Ontario.⁷² In this report, long-COVID patients were evaluated on average 12 weeks post-infection. In contrast to the earlier report of Li and colleagues,⁷⁰ both never- and ever-hospitalized participants were evaluated as

well as a small group of nine healthy volunteers who were neither vaccinated, nor had experienced any respiratory infection in the 18 months prior to evaluation.¹²⁹Xe MRI VDP was significantly worse in ever- as compared to never-hospitalized patients ($P = 0.048$) and never-COVID-19 ($P < 0.001$) participants. The study included the measurement of the diffusing capacity of the lung for carbon monoxide (DL_{CO}), St George's Respiratory Questionnaire (SGRQ)³⁶ and six-minute walk distance (6MWD, $P = 0.005$) as well as post-exertional oxygen saturation ($P = 0.03$) were significantly worse in the previously hospitalized COVID-19 participants. Participants with abnormal VDP (some of whom are shown in Fig. 6) also had significantly worse 6MWD ($P = 0.003$) and post-exertional SpO₂ ($P = 0.03$) and there were significant relationships for VDP with 6MWD ($\rho = -0.31$; $P = 0.02$) and post-exertional SpO₂ ($\rho = -0.43$; $P = 0.002$). It is also worth noting that in UK participants with COVID, there was a longitudinal trend toward improved VDP at 12 and 24 weeks as compared to 6 weeks post-infection.⁷⁸

Of the original 76 participants, 53 participants were evaluated 12 months later, roughly 1/3 hospitalized during

their acute COVID-19 infection. Although normal at the baseline visit, surprisingly, FEV₁ ($P = 0.001$), FEV₁/FVC ($P = 0.003$), and DL_{CO} ($P = 0.002$) significantly improved 12 months later. In addition, SGRQ score ($P < 0.001$) and VDP ($P = 0.003$) were improved at 15 months but remained abnormal. CT airway wall area ($P = 0.04$), lung clearance index (LCI) ($P = 0.02$), and post-exertional SpO₂ ($P = 0.004$) were all variables predicting the change in VDP at 15 months. Finally, improved SGRQ was correlated with inhaled corticosteroid/long-acting bronchodilator (ICS/LABA) prescribed at 3 months (OR = 4.0, $P = 0.03$) but this did not influence FEV₁ or VDP improvement over time. The positive effect of ICS/LABA was observed in participants with a prior diagnosis of asthma or COPD and in participants with no pre-existing chronic lung disease.⁷⁷

¹²⁹Xe Spectroscopy and Imaging: Evidence of Abnormal Gas-Exchange

Within a year of the onset of COVID-19, in January 2021, Li and colleagues were the first to report on ¹²⁹Xe MRI gas-exchange measurements in 13 recently discharged patients (mean = 25 days, range = 14–32 days post-discharge in February–March 2020) who had been hospitalized for COVID-19 infection. Similar to their finding of ventilation abnormalities, they also reported that the ¹²⁹Xe MR gas-exchange time constant was abnormally augmented and RBC:membrane abnormally low in the discharged COVID-19 patients as compared to the never-infected healthy subgroup of participants. In the discharged COVID-19 patients, the spirometry measurement of FEV₁, FVC, and their ratio was normal; DL_{CO} was not reported, which was unfortunate given the ¹²⁹Xe MRI evidence suggestive of persistent gas-exchange abnormalities. In addition, no other symptomatic or quality-of-life measurements were evaluated. Li and colleagues also measured normal ¹²⁹Xe MRI apparent diffusion coefficients (ADC) which have been previously used to report on alveolar tissue destruction or thickening. Taken together, these results which report from very early in the pandemic, suggested that, similar to SARS chest CT findings 20 years prior, of pulmonary fibrosis.⁷⁹ ¹²⁹Xe MR gas exchange measurements were abnormal and worryingly similar to patients with well-documented diagnosis of interstitial lung disease (ILD).^{48,80}

Another investigation, published in October 2021, reported on nine dyspneic patients, nearly 6 months after hospital discharge for COVID-19 pneumonia.⁷³ Similar to the findings from Li et al, ¹²⁹Xe MRI RBC:membrane values were diminished and significantly different between patients and five never-infected healthy volunteers ($P = 0.001$). In an extension of this pilot work, 23 post-COVID-19 patients were evaluated approximately 6 months post-infection,⁷⁴ of whom 12 were hospitalized for COVID-19 care and 11 improved at home. DL_{CO} was significantly different

between hospitalized and never-hospitalized participants ($P = 0.04$), but there was no evidence of other differences in lung function. Importantly, the mean RBC:membrane value was significantly different for volunteers and hospitalized participants ($P = 0.02$) as well as never-hospitalized participants ($P = 0.03$) but not between these two subgroups ($P = 0.26$).

In another multicenter study, 40 participants were evaluated including 6 healthy never-COVID volunteers, 22 never-hospitalized, and 12 participants hospitalized for acute COVID-19 symptoms.⁷¹ These participants were evaluated with respiratory symptoms consistent with long-COVID, approximately 9 months post-infection. Similar to previous studies of post-COVID-19 patients,^{10,81,82} there were highly abnormal SGRQ⁸³ and mMRC dyspnea scores (>91st percentile general population)⁸⁴ both of which discordant with mainly normal or mildly abnormal spirometry and chest CT. The RBC:membrane ratio for ever- and never-COVID-19 participants ($P = 0.06$) trended toward a difference and these were significantly different than the ratio observed in the healthy (but younger) volunteers. ¹²⁹Xe MRI RBC:membrane ratio correlated with DL_{CO}, similar to findings in obstructive and restrictive lung disease.⁸⁵ The other finding was the significant correlation between the pulmonary vascular tree small vessel density and RBC AUC ($P = 0.03$), which supported a link between RBC gas uptake and small-vessel pulmonary vascular abnormalities. These findings suggest a mechanistic link between MRI and symptomatic measurements which may include microvascular remodeling, vascular resistance, shunt, thrombi, micro-embolism, or some combination of these.

In summary, these four manuscripts described cross-sectional findings 6–9 months post-COVID-19 and provided important clues about persistent gas-exchange abnormalities in hospitalized and more surprisingly in never-hospitalized post-COVID patients, the majority of whom had respiratory symptoms. The possibility remains that alveolar capillary abnormalities as previously reported by post-mortem studies of COVID-19 pneumonia⁸⁶ may be contributing to the persistence of so-called long-COVID gas-exchange and symptomatic findings.

However, a number of unanswered questions remained including: 1) Did the abnormal MRI gas-exchange measurements and symptoms persist even longer in people who remain symptomatic? 2) Were these findings reversible over time? and 3) How did MRI gas-exchange abnormalities co-exist in the context of normal DL_{CO} values and normal or mildly abnormal chest CT?

In order to answer some of these questions, longitudinal evaluations were required. The original study of 34 post-COVID-19 participants⁷⁵ also evaluated 21 participants who returned for another visit, 14 months post-infection. At follow-up, the ¹²⁹Xe RBC:membrane ratio trended toward improvement but remained abnormal, while DL_{CO} and

SGRQ also significantly improved with SGRQ also remaining abnormal, 14 months post-infection. Post-exertional dyspnea and DL_{CO} correlated with SGRQ-score, suggestive of a mechanistic link between improved dyspnea and gas-exchange with quality-of-life (QoL) improvements, which is physiologically intuitive.

The most comprehensive longitudinal study of ^{129}Xe MRI gas-exchange values was reported in the original nine participants with COVID.⁷⁸ As shown in Fig. 7, at 12-week follow-up, there was improved ^{129}Xe MRI RBC:membrane, but no longitudinal change was detected between 12 and 52 weeks, and median values remained abnormally lower than expected and than an age- and sex-matched healthy volunteer group of 12 participants. While the COVID participant sample size ($N = 9$) was not large, these findings agreed with the significantly lower RBC:membrane values previously reported.^{70,71,75} As shown in Fig. 8, in a participant with COVID, CT ground glass opacities, reticulation, and fibrotic-like changes, were observed 6 months post-discharge and this agreed with an augmented mean acinar airway dimension and gas-exchange results. More evidence for parenchymal abnormality improvement over time was provided by dynamic contrast-enhanced MRI measurements in the same

patients ($N = 9$) of capillary perfusion which showed increased regional pulmonary blood flow and volume between 6 and 12 weeks, suggestive of microvascular improvement.

Study Limitations

All of these studies involved necessarily small sample sizes ranging from 9 to 76 participants and were single or two-center studies. Small sample sizes in heterogeneous studies make it difficult to come to firm conclusions and limit the universality of the reported findings. Nevertheless, the message that post-infection gas-exchange and ventilation abnormalities persist alongside symptoms in patients hospitalized and not hospitalized for COVID-19, was observed. The studies all appeared to be generated de novo, and independently and hence, the timing of follow-up and the additional measurements made, were not harmonized. The persistence of respiratory symptoms in the context of normal or nearly normal pulmonary function test results and chest CT is important to note. In addition, the abnormal ventilation and gas-exchange findings in symptomatic patients with normal clinical test values are important to keep in mind. Unfortunately, most of the participants studied in these original manuscripts, did not have pre-COVID CT as most did not have pre-

Results – dissolved phase ^{129}Xe / xenon gas transfer

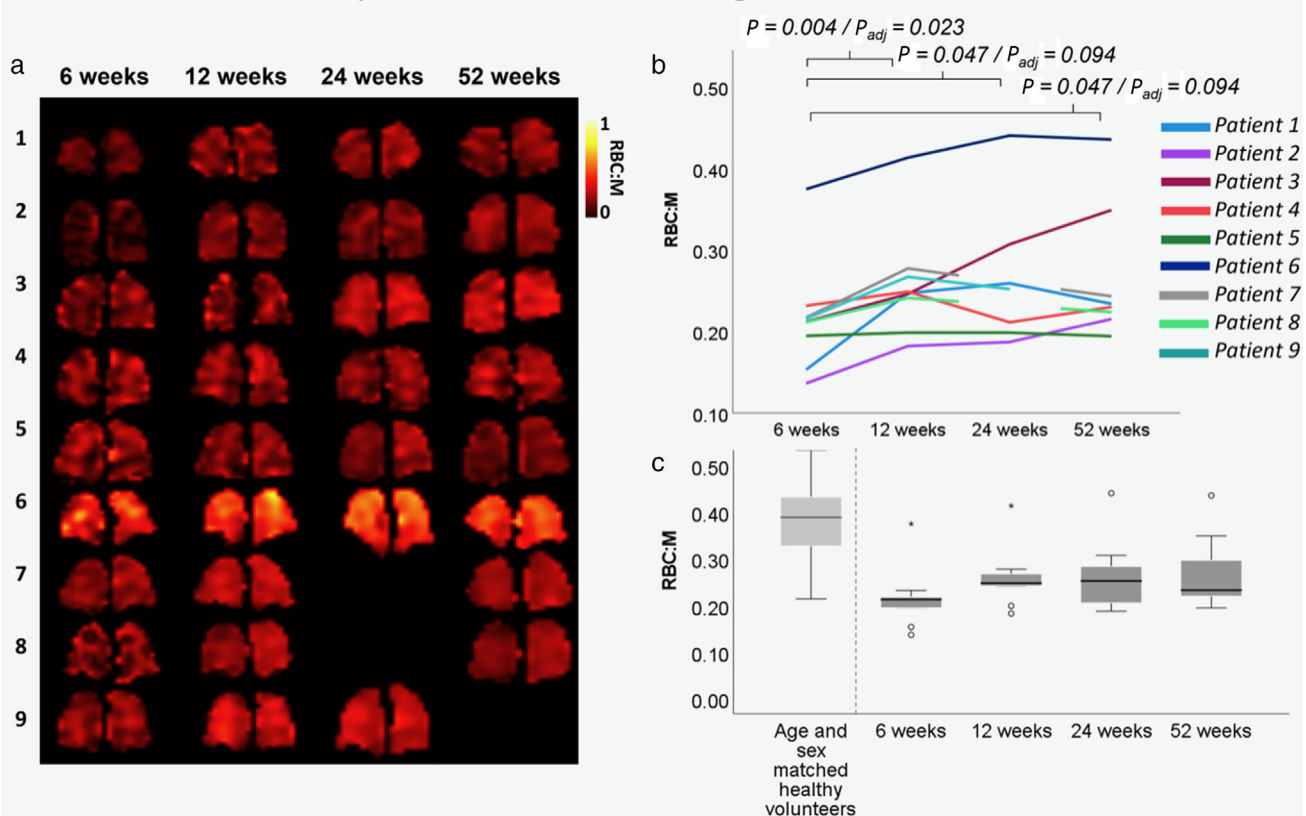


FIGURE 7: Longitudinal ^{129}Xe MRI gas-exchange measurements across four visits. (a) Centre coronal slice of ^{129}Xe RBC:membrane map for each participant and available visits. (b) Spaghetti plot of mean ^{129}Xe RBC:membrane for individual participants. (c) Box plot of ^{129}Xe RBC:membrane for age and sex matched healthy volunteers ($N = 12$, mean age 57 [41–68] years; 56% male) alongside same values for 9 participants followed over 4 visits (1 year).

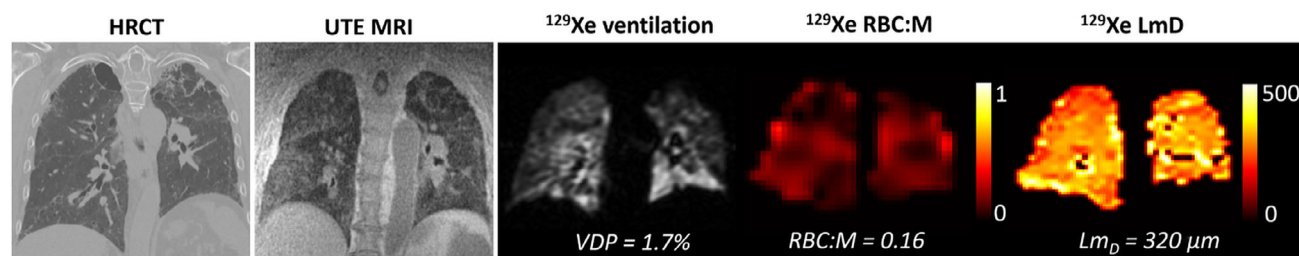


FIGURE 8: CT and MRI in long-COVID. Coronal images are shown for a 73-year-old male hospitalized due to COVID-19, with no prior respiratory disease. Left panel is chest CT acquired 6 months after hospital discharge with ground glass opacities, reticulation, and fibrotic-like changes. Next right panel is UTE MRI with similar findings. Middle and right panels show hyperpolarized ^{129}Xe MR ventilation, RBC:membrane map and diffusion-weighted map acquired 10 months after hospital discharge. HRCT = high resolution CT; RBC = red blood cell; VDP = ventilation defect percent; LmD = mean acinar airway dimension from diffusion-weighted map.

existing respiratory disease. Not all studies required symptoms consistent with long-COVID; moreover, participants were recruited as a convenience sample from February 2020 to October 2021 ranging from weeks post-infection to 15 months post-infection.

The trends, however, are clear. Regardless of the study or timeframe, in the patients evaluated in these studies, ventilation and gas-exchange abnormalities persisted for at least 1-year post-infection. While MRI measurements improved over time in all studies, these did not normalize nor did quality-of-life scores, nor exercise limitation measures. It is possible that more time is needed to observe complete normalization, or that this might not be achieved.

Discussion

What Do These MRI Ventilation and Gas-Exchange Abnormalities Mean for Patients?

Ventilation abnormalities^{76,87,88} improved that alongside improvements in FEV₁, DL_{CO}, exercise capacity, and SGRQ, 15 months post-infection. The novel finding that treatment with ICS-LABA was associated with 4-fold greater odds of SGRQ improvement agrees with predictions of airways disease early in the pandemic.⁸⁹ With respect to gas-exchange, a combination of lung perfusion abnormalities and/or alveolar/interstitial endothelial changes may be mechanistically driving the observation of diminished RBC:membrane values. This is supported by the correlations detected for the changes in ^{129}Xe gas transfer with changes in pulmonary blood volume in one of the longitudinal studies ^{129}Xe gas-exchange MRI.⁷⁸ Pilot dynamic contrast-enhanced MRI evidence of pulmonary microvasculature abnormalities in 10 participants, after SARS-CoV-2 infection⁹⁰ also supports this hypothesis. Another pilot study measuring lung perfusion using SPECT/CT in 14 children with long-COVID⁹¹ showed that 6 of 14 demonstrated perfusion defects without corresponding CT abnormalities. Together, these abnormal MRI and CT findings generate testable hypotheses about the role of the alveolar tissue barrier and pulmonary vascular compartments in long-COVID. As described in other work,⁹² it is possible that

micro-embolic or micro-thrombotic obstruction of small capillaries explains these results. Alternatively, vascular injury, vascular remodeling, or shunt may also be possible as previously described.^{10,82,93} Certainly, post-mortem micro-CT imaging provided evidence of abnormal alveolar-level structures and occluded capillaries.⁹⁴ Pulmonary vascular abnormalities observed may also stem from vascular remodeling or persistent micro-emboli which would agree with histological evidence of severe endothelial damage and distorted, elongated vessels alongside micro-emboli⁹⁵ and shunt.⁹⁶

Do airway and pulmonary vascular functional abnormalities occur together in the same patients? This question cannot yet be answered in the manuscripts recently published but it is mechanistically possible that post-COVID inflammation may affect both the airway and pulmonary vascular tree, compounding the requirements needed or at least delaying full symptomatic recovery for some patients. Nevertheless, the positive effects of ICS/LABA on recovery in some patients were not possible to ascertain otherwise.

Opportunities: What's Next?

Pulmonary imaging measurements have been at the vanguard of the clinical and research evaluation of patients with acute and chronic effects of COVID-19. While chest CT has been the mainstay clinical tool for patients with severe symptoms requiring hospital-based care, it is also the go-to for those at risk of interstitial abnormalities including fibrosis, post-infection. To our knowledge there has been no head-to-head comparison of ^{129}Xe MRI measurements in patients with persistent CT abnormalities, nor has there been a prospective comparison in patients with CT and MRI abnormalities with DL_{CO} and symptoms. This is an important area of future research for COVID-19 and in other patients with severe viral infection. As the clinical interest in long-COVID remains strong, these studies will be clinically important to provide context for the ventilation and gas-exchange results observed in symptomatic people with mainly normal CT and pulmonary function test results.

In people with symptoms of post-infection, ^{129}Xe MRI ventilation and gas-exchange measurements suggest

that such abnormalities occur together or independently. However, it is not known yet if these findings occur sequentially over time or simultaneously. The source of airways disease may stem from airway inflammation but this also requires more study to definitively ascertain. Multi-center studies using harmonized protocols for both MRI and CT are needed in people while symptomatic, in asymptomatic post-infection, and longitudinally after severe infection. The acquisition of dynamic contrast-enhanced lung perfusion MRI may also help build an understanding of the mechanisms responsible for the persistent MRI gas-exchange abnormalities. Finally, ^{129}Xe MRI does not require ionizing radiation (making repeated imaging sessions feasible), has high sensitivity (which decreases sample sizes and increases effect size) and speed (relative to other MRI exams), which makes it well suited for novel therapy and other studies of the post-COVID condition. We still have much to learn about how to prevent long-term structural and lung functional abnormalities after pulmonary viral infection. These preliminary ^{129}Xe MRI results provide snapshots of the post-COVID-19 recovery of the lung over time.

Conclusions

In less than 3 years, the COVID-19 global pandemic has led to nearly 1 billion people experiencing a novel respiratory viral infection. As citizens of the world and as imaging scientists too, this provided an unprecedented opportunity to measure and monitor the acute and chronic effects of nearly simultaneous, novel viral pulmonary infection on a global scale. While the first few waves of infection led to concerns about the acute effects of severe respiratory illness, within a few months, attention also turned to the long-term outcomes in patients who reported persistent or recurrent symptom burden, following the post-acute phase of infection. Such symptoms included, but were not limited to, dyspnea, fatigue, exercise and activity limitation, brain fog, myalgia, and headache.¹⁰ These symptoms appear to be weakly if not negligibly linked to the severity of the infection and paradoxically persist in people with normal or only mildly abnormal pulmonary function and chest CT results. ^{129}Xe MR imaging and spectroscopy has provided a way to sensitively detect gas-exchange and ventilation abnormalities in small numbers of patients, and during a time when face-to-face clinical research was seriously restricted. The sensitivity of the method allowed for significant relationships to be discerned which led to our understanding that both airways disease and gas-exchange abnormalities may play a role in symptomatic long-COVID. Pulmonary functional MRI using inhaled hyperpolarized ^{129}Xe gas has helped develop a preliminary understanding of the root causes of long-COVID.

Acknowledgments

We thank the research teams, clinical collaborators, and the participants in China, the UK, and Canada, who generated the evidence summarized here, making this research, insights into long-COVID and systematic review possible.

Conflict of Interest

None of the authors have relevant conflicts of interest to disclose. Figs. 1–8 were created de novo by the authors, in some cases, with the assistance of *BioRender*.

References

1. *Estimated COVID-19 burden*. Vol 2022. Atlanta, GA: United States Centers for Disease Control and Prevention; 2021.
2. Dong E, Du H, Gardner L. An interactive web-based dashboard to track COVID-19 in real time. *Lancet Infect Dis* 2020;20(5):533-534.
3. Wu X, Liu X, Zhou Y, et al. 3-month, 6-month, 9-month, and 12-month respiratory outcomes in patients following COVID-19-related hospitalisation: A prospective study. *Lancet Respir Med* 2021;9(7):747-754.
4. Solomon JJ, Heyman B, Ko JP, Condos R, Lynch DA. CT of post-acute lung complications of COVID-19. *Radiology* 2021;301(2):E383-E395.
5. Han X, Chen L, Fan Y, et al. Longitudinal assessment of chest CT findings and pulmonary function after COVID-19 infection. *Radiology* 2023;307(2):e222888.
6. Han X, Fan Y, Alwalid O, et al. Fibrotic interstitial lung abnormalities at 1-year follow-up CT after severe COVID-19. *Radiology* 2021;301(3):E438-E440.
7. Watanabe A, So M, Iwagami M, et al. One-year follow-up CT findings in COVID-19 patients: A systematic review and meta-analysis. *Respirology* 2022;27(8):605-616.
8. Jennings G, Monaghan A, Xue F, Mockler D, Romero-Ortuño R. A systematic review of persistent symptoms and residual abnormal functioning following acute COVID-19: Ongoing symptomatic phase vs. post-COVID-19 syndrome. *J Clin Med* 2021;10(24):5913.
9. Proal AD, VanElzakker MB. Long COVID or post-acute sequelae of COVID-19 (PASC): An overview of biological factors that may contribute to persistent symptoms. *Front Microbiol* 2021;12:698169.
10. Nalbandian A, Sehgal K, Gupta A, et al. Post-acute COVID-19 syndrome. *Nat Med* 2021;27(4):601-615.
11. National Institute of Health and Care Excellence. *COVID-19 rapid guideline: managing COVID-19*. London: NICE; 2021.
12. *Post-COVID conditions. COVID-19*. Vol 2022. Atlanta, GA: Centers for Disease Control and Prevention; 2021.
13. Soriano JB, Murthy S, Marshall JC, Relan P, Diaz JV, Condition WHOCCDWGoP-C. A clinical case definition of post-COVID-19 condition by a Delphi consensus. *Lancet Infect Dis* 2021;22:e102-e107.
14. *COVID-19 rapid guideline: managing the long-term effects of COVID-19. NICE guidance*. 1.8 ed. London: National Institute for Health and Care Excellence; 2021.
15. Davis HE, McCorkell L, Vogel JM, Topol EJ. Long COVID: Major findings, mechanisms and recommendations. *Nat Rev Microbiol* 2023;21:1-14.
16. Global Burden of Disease Long CC, Wulf Hanson S, Abbafati C, et al. Estimated global proportions of individuals with persistent fatigue, cognitive, and respiratory symptom clusters following symptomatic COVID-19 in 2020 and 2021. *JAMA* 2022;328(16):1604-1615.
17. Chen C, Hauptert SR, Zimmermann L, Shi X, Fritsche LG, Mukherjee B. Global prevalence of post-coronavirus disease 2019 (COVID-19)

- condition or Long COVID: A meta-analysis and systematic review. *J Infect Dis* 2022;226(9):1593-1607.
18. Ayoubkhani D, Pawelek P. In: Statistics OfN, editor. *Prevalence of ongoing symptoms following coronavirus (COVID-19) infection in the UK: 1 June 2022*; 2022. The United Kingdom: Office for National Statistics.
 19. Yong SJ. Long COVID or post-COVID-19 syndrome: Putative pathophysiology, risk factors, and treatments. *Infect Dis (Lond)* 2021;53(10):737-754.
 20. Bellan M, Baricich A, Patrucco F, et al. Long-term sequelae are highly prevalent one year after hospitalization for severe COVID-19. *Sci Rep* 2021;11(1):22666.
 21. Chopra V, Flanders SA, O'Malley M, Malani AN, Prescott HC. Sixty-day outcomes among patients hospitalized with COVID-19. *Ann Intern Med* 2021;174(4):576-578.
 22. Fernandez-de-las-Penas C, Palacios-Cena D, Gomez-Mayordomo V, et al. Long-term post-COVID symptoms and associated risk factors in previously hospitalized patients: A multicenter study. *J Infect* 2021;83(2):271-274.
 23. Bell ML, Catalfamo CJ, Farland LV, et al. Post-acute sequelae of COVID-19 in a non-hospitalized cohort: Results from the Arizona CoV-HORT. *PLoS One* 2021;16(8):e0254347.
 24. Bliddal S, Banasik K, Pedersen OB, et al. Acute and persistent symptoms in non-hospitalized PCR-confirmed COVID-19 patients. *Sci Rep* 2021;11(1):13153.
 25. Mulay A, Konda B, Garcia G Jr, et al. SARS-CoV-2 infection of primary human lung epithelium for COVID-19 modeling and drug discovery. *Cell Rep* 2021;35(5):109055.
 26. Scialo F, Daniele A, Amato F, et al. ACE2: The major cell entry receptor for SARS-CoV-2. *Lung* 2020;198(6):867-877.
 27. Gursoy B, Surmeli CD, Alkan M, et al. Cytokine storm in severe COVID-19 pneumonia. *J Med Virol* 2021;93(9):5474-5480.
 28. Hu B, Huang S, Yin L. The cytokine storm and COVID-19. *J Med Virol* 2021;93(1):250-256.
 29. Kanne JP, Little BP, Schulte JJ, Haramati A, Haramati LB. Long-term lung abnormalities associated with COVID-19 pneumonia. *Radiology* 2022;221806:e221806.
 30. Dhawan RT, Gopalan D, Howard L, et al. Beyond the clot: Perfusion imaging of the pulmonary vasculature after COVID-19. *Lancet Respir Med* 2021;9(1):107-116.
 31. Ojo AS, Balogun SA, Williams OT, Ojo OS. Pulmonary fibrosis in COVID-19 survivors: Predictive factors and risk reduction strategies. *Pulm Med* 2020;2020:6175964.
 32. Krishna Murthy P, Sivashanmugam K, Kandasamy M, Subbiah R, Ravikumar V. Repurposing of histone deacetylase inhibitors: A promising strategy to combat pulmonary fibrosis promoted by TGF-beta signalling in COVID-19 survivors. *Life Sci* 2021;266:118883.
 33. Fabbri L, Moss S, Khan FA, et al. Parenchymal lung abnormalities following hospitalisation for COVID-19 and viral pneumonitis: A systematic review and meta-analysis. *Thorax* 2023;78(2):191-201.
 34. Luger AK, Sonnweber T, Gruber L, et al. Chest CT of lung injury 1 year after COVID-19 pneumonia: The CovILD study. *Radiology* 2022;304(2):462-470.
 35. Stewart I, Jacob J, George PM, et al. Residual lung abnormalities after COVID-19 hospitalization: Interim analysis of the UKILD post-COVID-19 study. *Am J Respir Crit Care Med* 2023;207(6):693-703.
 36. Jones PW. St. George's respiratory questionnaire: MCID. *COPD* 2005;2(1):75-79.
 37. Schroder L. Xenon for NMR biosensing – Inert but alert. *Phys Med* 2013;29(1):3-16.
 38. Wolber J, Cherubini A, Dzik-Jurasz AS, Leach MO, Bifone A. Spin-lattice relaxation of laser-polarized xenon in human blood. *Proc Natl Acad Sci U S A* 1999;96(7):3664-3669.
 39. Marshall H, Stewart NJ, Chan HF, Rao M, Norquay G, Wild JM. In vivo methods and applications of xenon-129 magnetic resonance. *Prog Nucl Magn Reson Spectrosc* 2021;122:42-62.
 40. Albert MS, Cates GD, Driehuis B, et al. Biological magnetic resonance imaging using laser-polarized ¹²⁹Xe. *Nature* 1994;370(6486):199-201.
 41. Svenningsen S, Kirby M, Starr D, et al. What are ventilation defects in asthma? *Thorax* 2014;69(1):63-71.
 42. Eddy RL, Svenningsen S, Kirby M, et al. Is computed tomography airway count related to asthma severity and airway structure and function? *Am J Respir Crit Care Med* 2020;201(8):923-933.
 43. Svenningsen S, Haider E, Boylan C, et al. CT and functional MRI to evaluate airway mucus in severe asthma. *Chest* 2019;155(6):1178-1189.
 44. Kaushik SS, Freeman MS, Yoon SW, et al. Measuring diffusion limitation with a perfusion-limited gas—hyperpolarized ¹²⁹Xe gas-transfer spectroscopy in patients with idiopathic pulmonary fibrosis. *J Appl Physiol* (1985) 2014;117(6):577-585.
 45. Kaushik SS, Robertson SH, Freeman MS, et al. Single-breath clinical imaging of hyperpolarized (¹²⁹Xe) in the airspaces, barrier, and red blood cells using an interleaved 3D radial 1-point Dixon acquisition. *Magn Reson Med* 2016;75(4):1434-1443.
 46. Bier EA, Robertson SH, Schrank GM, et al. A protocol for quantifying cardiogenic oscillations in dynamic (¹²⁹Xe) gas exchange spectroscopy: The effects of idiopathic pulmonary fibrosis. *NMR Biomed* 2019;32(1):e4029.
 47. Willmering MM, Walkup LL, Niedbalski PJ, et al. Pediatric (¹²⁹Xe) gas-transfer MRI-feasibility and applicability. *J Magn Reson Imaging* 2022;56(4):1207-1219.
 48. Weatherley ND, Stewart NJ, Chan HF, et al. Hyperpolarised xenon magnetic resonance spectroscopy for the longitudinal assessment of changes in gas diffusion in IPF. *Thorax* 2019;74(5):500-502.
 49. de Lange EE, Altes TA, Patrie JT, et al. Changes in regional airflow obstruction over time in the lungs of patients with asthma: Evaluation with ³He MR imaging. *Radiology* 2009;250(2):567-575.
 50. de Lange EE, Altes TA, Patrie JT, et al. The variability of regional airflow obstruction within the lungs of patients with asthma: Assessment with hyperpolarized helium-3 magnetic resonance imaging. *J Allergy Clin Immunol* 2007;119(5):1072-1078.
 51. Fain SB, Gonzalez-Fernandez G, Peterson ET, et al. Evaluation of structure-function relationships in asthma using multidetector CT and hyperpolarized He-3 MRI. *Acad Radiol* 2008;15(6):753-762.
 52. Donnelly LF, MacFall JR, McAdams HP, et al. Cystic fibrosis: Combined hyperpolarized ³He-enhanced and conventional proton MR imaging in the lung—preliminary observations. *Radiology* 1999;212(3):885-889.
 53. Woodhouse N, Wild JM, Paley MN, et al. Combined helium-3/proton magnetic resonance imaging measurement of ventilated lung volumes in smokers compared to never-smokers. *J Magn Reson Imaging* 2005;21(4):365-369.
 54. Kirby M, Heydarian M, Svenningsen S, et al. Hyperpolarized ³He magnetic resonance functional imaging semiautomated segmentation. *Acad Radiol* 2012;19(2):141-152.
 55. Cleveland ZI, Cofer GP, Metz G, et al. Hyperpolarized Xe MR imaging of alveolar gas uptake in humans. *PLoS One* 2010;5(8):e12192.
 56. Hersman FW, Ruset IC, Ketel S, et al. Large production system for hyperpolarized ¹²⁹Xe for human lung imaging studies. *Acad Radiol* 2008;15(6):683-692.
 57. Freeman MS, Emami K, Driehuis B. Characterizing and modeling the efficiency limits in large-scale production of hyperpolarized ¹²⁹Xe. *Phys Rev A* 2014;90(2):023406.
 58. Norquay G, Collier GJ, Rodgers OI, Gill AB, Screaton NJ, Wild J. Standalone portable xenon-129 hyperpolariser for multicentre clinical magnetic resonance imaging of the lungs. *Br J Radiol* 2022;95(1132):20210872.
 59. Driehuis B, Cofer GP, Pollaro J, Mackel JB, Hedlund LW, Johnson GA. Imaging alveolar-capillary gas transfer using hyperpolarized ¹²⁹Xe MRI. *Proc Natl Acad Sci U S A* 2006;103(48):18278-18283.

60. Ruppert K, Brookeman JR, Hagspiel KD, Driehuis B, Mugler JP 3rd. NMR of hyperpolarized (129)Xe in the canine chest: Spectral dynamics during a breath-hold. *NMR Biomed* 2000;13(4):220-228.
61. Collier GJ, Eaden JA, Hughes PJC, et al. Dissolved (129)Xe lung MRI with four-echo 3D radial spectroscopic imaging: Quantification of regional gas transfer in idiopathic pulmonary fibrosis. *Magn Reson Med* 2021;85(5):2622-2633.
62. Qing K, Ruppert K, Jiang Y, et al. Regional mapping of gas uptake by blood and tissue in the human lung using hyperpolarized xenon-129 MRI. *J Magn Reson Imaging* 2014;39(2):346-359.
63. Kammerman J, Hahn AD, Cadman RV, Malkus A, Mummy D, Fain SB. Transverse relaxation rates of pulmonary dissolved-phase hyperpolarized (129)Xe as a biomarker of lung injury in idiopathic pulmonary fibrosis. *Magn Reson Med* 2020;84(4):1857-1867.
64. Dixon WT. Simple proton spectroscopic imaging. *Radiology* 1984;153(1):189-194.
65. Doganay O, Wade T, Hegarty E, McKenzie C, Schulte RF, Santyr GE. Hyperpolarized (129)Xe imaging of the rat lung using spiral IDEAL. *Magn Reson Med* 2016;76(2):566-576.
66. Muradian I, Patz S, Butler JP, et al. Hyperpolarized 129Xe human pulmonary gas exchange with 3-point Dixon technique. *Proc Int Soc Magn Reson Med* 2006;14:1297.
67. Niedbalski PJ, Hall CS, Castro M, et al. Protocols for multi-site trials using hyperpolarized (129)Xe MRI for imaging of ventilation, alveolar-airspace size, and gas exchange: A position paper from the (129)Xe MRI clinical trials consortium. *Magn Reson Med* 2021;86(6):2966-2986.
68. Wang JM, Robertson SH, Wang Z, et al. Using hyperpolarized (129)Xe MRI to quantify regional gas transfer in idiopathic pulmonary fibrosis. *Thorax* 2018;73(1):21-28.
69. Mummy DG, Bier EA, Wang Z, et al. Hyperpolarized (129)Xe MRI and spectroscopy of gas-exchange abnormalities in nonspecific interstitial pneumonia. *Radiology* 2021;301(1):211-220.
70. Li H, Zhao X, Wang Y, et al. Damaged lung gas exchange function of discharged COVID-19 patients detected by hyperpolarized (129)Xe MRI. *Sci Adv* 2021;7(1):eabc8180.
71. Matheson AM, McIntosh MJ, Kooner HK, et al. Persistent (129)Xe MRI pulmonary and CT vascular abnormalities in symptomatic individuals with post-acute COVID-19 syndrome. *Radiology* 2022;220492:466-476.
72. Kooner HK, McIntosh MJ, Matheson AM, et al. (129)Xe MRI ventilation defects in ever-hospitalised and never-hospitalised people with post-acute COVID-19 syndrome. *BMJ Open Respir Res* 2022;9(1):e001235.
73. Grist JT, Chen M, Collier GJ, et al. Hyperpolarized (129)Xe MRI abnormalities in dyspneic patients 3 months after COVID-19 pneumonia: Preliminary results. *Radiology* 2021;301(1):E353-E360.
74. Grist JT, Collier GJ, Walters H, et al. Lung abnormalities detected with hyperpolarized (129)Xe MRI in patients with long COVID. *Radiology* 2022;305(3):709-717.
75. Matheson AM, McIntosh MJ, Kooner HK, et al. Longitudinal follow-up of postacute COVID-19 syndrome: DL(CO), quality-of-life and MRI pulmonary gas-exchange abnormalities. *Thorax* 2023;78:418-421.
76. Kooner HK. Post-acute COVID-19 syndrome: 129Xe MRI ventilation defects and respiratory outcomes one year later. *Radiology* 2023;307:e222557.
77. Kooner HK, McIntosh MJ, Matheson AM, Svenningsen S, Parraga G. More data about (129)Xe MRI ventilation defects in Long COVID-19. *Radiology* 2023;307(4):e230479.
78. Saunders LC, Collier GJ, Chan HF, et al. Longitudinal lung function assessment of patients hospitalized with COVID-19 using (1)H and (129)Xe lung MRI. *Chest* 2023.1-17
79. Hon KLE, Leung CW, Cheng WTF, et al. Clinical presentations and outcome of severe acute respiratory syndrome in children. *Lancet* 2003;361(9370):1701-1703.
80. Stewart NJ, Leung G, Norquay G, et al. Experimental validation of the hyperpolarized (129)Xe chemical shift saturation recovery technique in healthy volunteers and subjects with interstitial lung disease. *Magn Reson Med* 2015;74(1):196-207.
81. Townsend L, Dowds J, O'Brien K, et al. Persistent poor health after COVID-19 is not associated with respiratory complications or initial disease severity. *Ann Am Thorac Soc* 2021;18(6):997-1003.
82. McFann K, Baxter BA, LaVergne SM, et al. Quality of life (QoL) is reduced in those with severe COVID-19 disease, post-acute sequelae of COVID-19, and hospitalization in United States adults from northern Colorado. *Int J Environ Res Public Health* 2021;18(21):1-9.
83. Ferrer M, Villasante C, Alonso J, et al. Interpretation of quality of life scores from the St George's respiratory questionnaire. *Eur Respir J* 2002;19(3):405-413.
84. Currow DC, Plummer JL, Crockett A, Abernethy AP. A community population survey of prevalence and severity of dyspnea in adults. *J Pain Symptom Manage* 2009;38(4):533-545.
85. Wang Z, Rankine L, Bier EA, et al. Using hyperpolarized (129)Xe gas-exchange MRI to model the regional airspace, membrane, and capillary contributions to diffusing capacity. *J Appl Physiol* (1985) 2021;130(5):1398-1409.
86. Villalba JA, Hilburn CF, Garlin MA, et al. Vasculopathy and increased vascular congestion in fatal COVID-19 and ARDS. *Am J Respir Crit Care Med* 2022;206:857-873.
87. Kooner HK, McIntosh MJ, Desai Goudar V, et al. Pulmonary functional MRI: Detecting the structure-function pathologies that drive asthma symptoms and quality of life. *Respirology* 2022;27(2):114-133.
88. Vogel-Claussen J. Ventilation defects at (129)Xe MRI in postacute COVID-19 syndrome: Back to normal after 1 year? *Radiology* 2023;307(2):e230113.
89. Adeloye D, Elneima O, Daines L, et al. The long-term sequelae of COVID-19: An international consensus on research priorities for patients with pre-existing and new-onset airways disease. *Lancet Respir Med* 2021;9(12):1467-1478.
90. Zhou IY, Mascia M, Alba GA, et al. Dynamic contrast-enhanced MRI demonstrates pulmonary microvascular abnormalities months after SARS-CoV-2 infection. *Am J Respir Crit Care Med* 2023;207(12):1636-1639.
91. Pizzuto DA, Buonsenso D, Morello R, et al. Lung perfusion assessment in children with long-COVID: A pilot study. *Pediatr Pulmonol* 2023;58(7):2059-2067.
92. Nurek M, Rayner C, Freyer A, et al. Recommendations for the recognition, diagnosis, and management of long COVID: A Delphi study. *Br J Gen Pract* 2021;71(712):e815-e825.
93. Lins M, Vandevenne J, Thillai M, et al. Assessment of small pulmonary blood vessels in COVID-19 patients using HRCT. *Acad Radiol* 2020;27(10):1449-1455.
94. Walsh CL, Tafforeau P, Wagner WL, et al. Imaging intact human organs with local resolution of cellular structures using hierarchical phase-contrast tomography. *Nat Methods* 2021;18:1532-1541.
95. Ackermann M, Verleden SE, Kuehnel M, et al. Pulmonary vascular endothelialitis, thrombosis, and angiogenesis in Covid-19. *N Engl J Med* 2020;383(2):120-128.
96. Brito-Azevedo A, Pinto EC, de Cata Preta Corrêa GA, Bouskela E. SARS-CoV-2 infection causes pulmonary shunt by vasodilatation. *J Med Virol* 2021;93(1):573-575.
97. Al-Aly Z, Xie Y, Bowe B. High-dimensional characterization of post-acute sequelae of COVID-19. *Nature* 2021;594(7862):259-264.