




# COVID-19-related adrenal haemorrhage: Multicentre UK experience and systematic review of the literature

Yasir S. Elhassan<sup>1,2</sup>  | Fizzah Iqbal<sup>3</sup> | Wiebke Arlt<sup>1,2</sup> | Stephanie E. Baldeweg<sup>4</sup> | Miles Levy<sup>5</sup>  | Paul M. Stewart<sup>6</sup> | John Wass<sup>7</sup> | Sue Pavord<sup>8</sup> | D. Aled Rees<sup>3</sup> | Cristina L. Ronchi<sup>1,2</sup> 

<sup>1</sup>Centre for Endocrinology, Diabetes and Metabolism, Birmingham Health Partners, Birmingham, UK

<sup>2</sup>Institute of Metabolism and Systems Research, College of Medical and Dental sciences, University of Birmingham, Birmingham, UK

<sup>3</sup>Neuroscience and Mental Health Research Institute, School of Medicine, Cardiff, UK

<sup>4</sup>Department of Diabetes & Endocrinology, Department of Experimental & Translational Medicine, Division of Medicine, University College London Hospitals & Centre for Obesity & Metabolism, University College London, London, UK

<sup>5</sup>Department of Endocrinology, University Hospitals of Leicester NHS Trust, Leicester, UK

<sup>6</sup>Faculty of Medicine & Health, University of Leeds, Leeds, UK

<sup>7</sup>Department of Endocrinology, Oxford Centre for Endocrinology, Diabetes and Metabolism, Churchill Hospital, Oxford, UK

<sup>8</sup>Department of Haematology, Oxford University Hospitals NHS Foundation Trust, Oxford, UK

## Correspondence

Cristina L. Ronchi, Institute of Metabolism and System Research, College of Medical and Dental Sciences, University of Birmingham, Edgbaston B15 2TT, UK.  
Email: [C.L.Ronchi@bham.ac.uk](mailto:C.L.Ronchi@bham.ac.uk)

## Abstract

**Objective:** Adrenal haemorrhage (AH) is an uncommon, usually incidental imaging finding in acutely unwell patients. AH has been reported during coronavirus disease 2019 (COVID-19) infection and following ChAdOx1 nCoV-19 (Oxford-AstraZeneca) vaccination. The Society for Endocrinology (SfE) established a task force to describe the UK experience of COVID-19-related AH.

**Design:** A systematic literature review was undertaken. A survey was conducted through the SfE clinical membership to identify patients with COVID-19-related AH using a standardized data collection tool.

**Results:** The literature search yielded 25 cases of COVID-19-related AH (19 bilateral; 13 infection-related, and 12 vaccine-related). Eight UK centres responded to the survey with at least one case. A total of 18 cases were included in the descriptive study, including 11 from the survey and 7 UK-based patients from the systematic review. Seven patients (4 males; median age 53 (range 26–70) years), had infection-related AH (four bilateral). Median time from positive COVID-19 test to AH detection was 8 (range 1–30) days. Eleven cases of vaccine-related AH (eight bilateral) were captured (3 males; median age 47 (range 23–78) years). Median time between vaccination (nine Oxford-AstraZeneca and two Pfizer-BioNTech) and AH was 9 (range 2–27) days; 9/11 AH occurred after the first vaccine dose. Acute abdominal pain was the commonest presentation (72%) in AH of any cause. All 12 patients with bilateral AH and one patient with unilateral AH required glucocorticoid replacement.

**Conclusion:** Adrenal haemorrhage with consequential adrenal insufficiency can be a complication of COVID-19 infection and vaccination. Adrenal function assessment is mandatory to avoid the potentially fatal consequences of unrecognized adrenal insufficiency.

## KEYWORDS

adrenal apoplexy, adrenal infarction, adrenal insufficiency, COVID-19 vaccine, SARS-CoV-2

This is an open access article under the terms of the Creative Commons Attribution-NonCommercial-NoDerivs License, which permits use and distribution in any medium, provided the original work is properly cited, the use is non-commercial and no modifications or adaptations are made.

© 2023 The Authors. *Clinical Endocrinology* published by John Wiley & Sons Ltd.

## 1 | INTRODUCTION

Adrenal haemorrhage (AH) is a heterogeneous condition that is most frequently detected incidentally on abdominal imaging in acutely unwell or trauma patients. It is considered uncommon but is likely underrecognized as no clinical features can immediately alert to the diagnosis.<sup>1</sup> Several risk factors are associated with an increased risk of atraumatic AH including underlying adrenal tumour, sepsis, and adrenal vein thrombosis.<sup>2</sup> Whereas unilateral AH can be clinically silent, bilateral AH leads to adrenal insufficiency in as many as 100% of patients<sup>3</sup> with the risk of fatal adrenal crisis without prompt recognition and glucocorticoid treatment.

The coronavirus disease 2019 (COVID-19), caused by the severe acute respiratory syndrome coronavirus 2 (SARS-CoV-2), is predominantly a respiratory illness but can also be associated with extra-pulmonary manifestations, that include the endocrine system.<sup>4</sup> Thrombotic complications are common during a COVID-19 illness, linked to the dramatic cytokine response; these occur in 9.5% of all patients<sup>5</sup> and up to 31% of patients in an intensive care setting.<sup>6</sup> Several vaccines against SARS-CoV-2 have been approved, with one of the most widely administered being the adenoviral vector-based ChAdOx1 nCoV-19 (Oxford-AstraZeneca). Shortly after rollout, concerns developed regarding a rare risk of thrombocytopenia and thrombosis among people who received the Oxford-AstraZeneca vaccine; a phenomenon subsequently termed vaccine-induced immune thrombocytopenia and thrombosis (VITT).<sup>7</sup>

We encountered patients identified to have unilateral or bilateral AH during COVID-19 illness or following the Oxford-AstraZeneca vaccine in the context of VITT. Indeed, in the last two years, an increasing number of case reports have emerged in the literature (see Table 1 for references). In response, the Society for Endocrinology established a task force to describe the United Kingdom's experience of COVID-19-related AH with the aim to improve awareness and rapid diagnosis of this potentially life threatening COVID-19 complication.

## 2 | METHODS

### 2.1 | Overview of the literature

To assess the international experience of COVID-19-related AH, a systematic review of the literature was undertaken. Systematic Ovid Medline search using the keywords "adrenal adj3 h?emorrhag\*" AND "COVID-19" combined with the MeSH terms "adrenal gland diseases" AND "haemorrhage" AND "COVID-19". Ovid Embase search using the keywords "adrenal adj3 h?emorrhag\*" AND "COVID-19". The search period was 1 January 2020 to 15 June 2022. Case reports in conference proceedings have also been considered. Two members of the task force independently identified the case reports of COVID-19 infection or COVID-19 vaccine-related AH. The complete list of identified reports is summarized in Table 1.

### 2.2 | Design of the United Kingdom national survey and data collection

The task force consisted of endocrinologists and a haematologist with expertise in thrombotic disorders. A survey was designed by the task force with the purpose of identifying specialists and centres that encountered patients with diagnosed AH during COVID-19 illness or following the Oxford-AstraZeneca vaccine in the context of VITT. An invitation to participate was emailed to the Society for Endocrinology UK clinical membership and separately to 150 clinical leads of endocrinology departments across the country between February and July 2022. Timelines to express an interest to participate in the survey were defined. Clinicians who responded to the survey and expressed their interest in the following national audit aimed to collect data regarding the presentation of patients with COVID-19 illness- or vaccine-related AH via a standard anonymized data capture EXCEL sheet that they completed and returned to the task force, adhering to the Caldicott Principles.

### 2.3 | Definition of COVID-19 illness- or vaccine-related adrenal haemorrhage

AH was defined as potentially COVID-19 illness-related if the patient had a positive PCR test within 30 days before the detection of the adrenal abnormality. AH was defined as COVID-19 vaccine-related if the adrenal mass was detected 5–30 days after receiving a COVID-19 vaccine.<sup>7</sup> For the diagnosis of VITT, the Expert Haematology Panel's case definition criteria were used, whereby VITT was classified as 'definite', 'probable', 'possible', or 'unlikely'. VITT was considered definite if symptom onset occurred 5–30 days post-COVID-19 vaccination, in the presence of thrombosis, thrombocytopenia (platelet count  $< 150 \times 10^9/L$ ), D-Dimer  $> 4000 \mu/mL$ , and positive antiplatelet factor 4 antibodies,<sup>7</sup> and probable if only four of these criteria were fulfilled.

### 2.4 | Data collection and interpretation

The requested data included: age of patients at diagnosis of AH, gender, COVID-19 PCR test result (if applicable), type of COVID-19 vaccine received and date of administration (if applicable), laterality of AH (right, left, or bilateral), radiological characteristics of the haematoma (size of haematoma, contrast enhancement and density on computerized tomography (CT), magnetic resonance imaging (MRI) characteristics, presence of surrounding soft tissue stranding or retroperitoneal haematoma), presence of other risk factors for haemorrhage (such as anticoagulants use or coagulopathy, underlying adrenal tumour), clinical features (such as asymptomatic, abdominal pain, fever, and hypotension), laboratory investigations (blood counts, clotting profile, platelet factor-3 ELISA, cortisol, renin, and aldosterone), presence of extra-adrenal thrombosis, details on treatment received, and adrenal function and medications taken at last follow

TABLE 1 Case reports of COVID-19-related adrenal haemorrhage or infarction.

COVID-19 infection-related adrenal haemorrhage or infarction						
Authors	Month/year of publication	City, Country	Sex/age (in years)	Unilateral or bilateral haemorrhage or infarction	Sex/age (in years)	Unilateral or bilateral haemorrhage or infarction
Rebollo-Román et al.	September 2021	Córdoba, Spain	M/62	Left adrenal haemorrhage – underlying phaeochromocytoma, previously unknown	M/62	Left adrenal haemorrhage – underlying phaeochromocytoma, previously unknown
Miranda R et al.	July 2021	Santiago, Chile	M/47	Bilateral haemorrhage	M/47	Bilateral haemorrhage
Machado I et al.	July 2021	Seo Paulo, Brazil	F/46	Bilateral infarction	F/46	Bilateral infarction
Asano Y et al.	June 2021	Nagano, Japan	F/76	Bilateral infarction	F/76	Bilateral infarction
Sreedharan R et al.	March 2021	Ohio, USA	Unavailable	Bilateral haemorrhage	Unavailable	Bilateral haemorrhage
Elkhoully M et al.	March 2021	London, UK	M/50	Bilateral haemorrhage	M/50	Bilateral haemorrhage
Jaiswal R and Schulman-Rosenbaum R	2021	New York, US	F/71	Bilateral haemorrhage	F/71	Bilateral haemorrhage
Shaamile F and O'Halloran DJ	2021	Cork, Ireland	M/61	Right adrenal haemorrhage	M/61	Right adrenal haemorrhage
Haider S et al.	2021	Michigan, US	M/71	Bilateral infarction	M/71	Bilateral infarction
Kumar R et al.	May 2020	London, UK	F/70	Bilateral infarction	F/70	Bilateral infarction
Sharrack N et al.	November 2020	Barnsley, UK	M/53	Right adrenal haemorrhage	M/53	Right adrenal haemorrhage
Frankel M et al.	August 2020	Jerusalem, Israel	F/66	Bilateral haemorrhage	F/66	Bilateral haemorrhage
Alvarez-Troncoso J et al.	2020	Madrid, Spain	M/70	Bilateral haemorrhage	M/70	Bilateral haemorrhage
COVID-19 vaccine-related adrenal haemorrhage or infarction						
Authors	Month/year of publication	Hospital, City, Country	Sex/age (in years)	Unilateral or bilateral haemorrhage	Sex/age (in years)	Time interval since the vaccine (in days)
Efthymiadis A et al	June 2022	Oxford, UK	F/23	Bilateral haemorrhage in the context of VITT	F/23	8
Tews H et al.	April 2022	Regensburg, Germany	M/39	Bilateral haemorrhage in the context of VITT	M/39	10
Graf A et al. (Case 1)	February 2022	London, UK	M/46	Bilateral haemorrhage in the context of VITT	M/46	8
Graf A et al. (Case 2)	February 2022	London, UK	F/38	Left adrenal infarction in the context of VITT	F/38	11
Tha T et al.	December 2021	Birmingham, UK	F/47	Bilateral haemorrhage in the context of VITT	F/47	8
Varona J et al.	September 2021	Madrid, Spain	M/47	Bilateral haemorrhage in the context of VITT	M/47	10
Douxflis J et al	August 2021	Namur, Belgium	F/83	Right adrenal haematoma and left adrenal infarction in the context of VITT	F/83	14

TABLE 1 (Continued)

COVID-19 vaccine-related adrenal haemorrhage or infarction						
Authors	Month/year of publication	Hospital, City, Country	Sex/age (in years)	Unilateral or bilateral haemorrhage	Type of vaccine	Time interval since the vaccine (in days)
Taylor P et al.	June 2021	Cardiff, UK	M/38	Bilateral haemorrhage in the context of VITT	AstraZeneca	8
Blauenfeldt et al.	April 2021	Aarhus, Denmark	F/60	Bilateral haemorrhage in the context of VITT	AstraZeneca	7
D'Agostino V et al.	April 2021	Naples, Italy	F/54	Bilateral haemorrhage in the context of VITT	Astrazeneca	12
Boyle L et al.	2021	London, UK	F/55	Left adrenal haemorrhage	AstraZeneca	8
Sabahat et al.	2021	Slough, UK	F/23	Bilateral haemorrhage in the context of probable VITT	AstraZeneca	10

up. Information about previous publication in a peer-reviewed journal or conference proceedings were also requested.

All the provided data were collated, and data consistency was verified by at least two members of the task force. Inconsistencies and incomplete data were raised with the local endocrinologists by specific queries until they were subsequently resolved.

The same clinical, radiological, biochemical and outcome data as above were extracted from the case reports available in the literature from UK-based centres that were not captured through the survey.

Final data were evaluated to highlight differences and similarities in terms of demographics, presentation, and clinical outcome of patients with COVID-19 illness- or vaccine-related AH.

## 2.5 | Statistical analysis

This is a descriptive study, and therefore no statistical analysis was involved. Wherever relevant, data are presented as median and range.

## 3 | RESULTS

### 3.1 | Overview of the literature

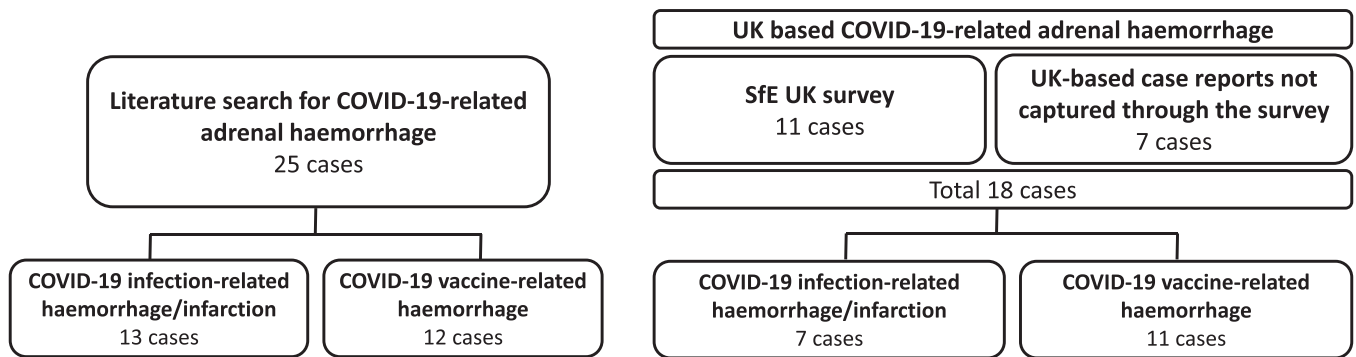
Our search identified a total of 25 cases of COVID-19-related AH (Figure 1). In particular, these included 9 cases of AH<sup>8-17</sup> and four cases of adrenal infarction<sup>18-21</sup> in the context of COVID-19 infection. All four cases of adrenal infarction were bilateral, with no radiological features of haemorrhage, while 6/9 cases of AH were bilateral (66%) with three unilateral (2 left and 1 right sided). The median age of the patients with COVID-19 infection-related AH or adrenal infarction was 64 years (range 46-76). The sex distribution was near equal with seven males and five females (excluding one case where sex was unknown).

Moreover, 12 cases<sup>22-32</sup> of AH following COVID-19 vaccination were identified. Eight (66.7%) of the reported cases were females, and median age was 46 years (range 23-83). All reported cases presented 7-12 days following COVID-19 AstraZeneca vaccination. Most cases (9/12) presented with bilateral AH (75%).

Of note, 10 of the 26 cases identified through the literature search originated from the UK (three COVID-19 infection-related and seven vaccine-related). A full description of available data from published reports is reported in Table 1.

### 3.2 | Overview of the survey and descriptive study

Eight UK centres reported encountering patients that met the definition criteria of COVID-19-related AH, while six centres replied that no such cases were faced. Overall, the survey returned 11 patients that met the definition criteria above for COVID-19-related AH. For a comprehensive overview, we also included 7 of the 10



**FIGURE 1** An outline of the number of patients identified through the systematic literature search and the UK survey and the cohort of patients included in the descriptive study. COVID-19, coronavirus disease 2019.

UK-based patients from the systematic review, who were not captured through the survey resulting in a total of 18 cases (Figure 1). The details regarding the patient's demographic and clinical characteristics, the clinical presentation, and the outcome are reported in Tables 2–4, respectively.

### 3.3 | COVID-19 infection-related adrenal haemorrhage

We identified seven patients (four men and three women) with COVID-19 infection-related AH (Table 2). The median age was 53 years (range 26–70). Four patients had bilateral AH (57%); diameters of adrenal haematoma/abnormality ranged from 42 mm to 125 mm. All patients had positive COVID-19 PCR tests and CT scan was initially undertaken to evaluate clinical deterioration. The median duration between the positive COVID-19 PCR test and radiological detection of AH was 8 days (range 1–30). Two patients (one bilateral and one unilateral AH) had associated pulmonary embolism and one (bilateral AH) had lower limb deep vein thrombosis.

Among the four patients with bilateral AH, two had other risk factors for haemorrhage, that is, one patient was on low molecular weight heparin, and another was known to have an underlying unilateral nonfunctioning adrenal adenoma. Moreover, three of them (75%) presented with acute abdominal pain whilst in one case the detection of AH was incidental on imaging undertaken to exclude pulmonary embolism (Table 3). Hypotension was evident in 50% of patients with bilateral AH and hyponatraemia occurred in another 50%. In two patients with bilateral AH, random cortisol levels were considered reassuring being 734 nmol/L and 625 nmol/L and therefore patients were not treated with glucocorticoids. In the other two patients with bilateral AH, the random cortisols were considered inconclusive at 458 nmol/L and 215 nmol/L and as the patients were symptomatic with hypotension and tachycardia, glucocorticoid, and mineralocorticoid replacement was commenced. One glucocorticoid-treated patient with bilateral AH subsequently failed an ACTH stimulation test (baseline cortisol 242 nmol/L; 30-min cortisol 264 nmol/L) and died of COVID-19 pneumonitis. The second

glucocorticoid-treated patient subsequently passed an ACTH stimulation test (baseline cortisol, 171 nmol/L; 30-min cortisol 458 nmol/L) and hydrocortisone and fludrocortisone were discontinued. One nonglucocorticoid treated patient died of massive pulmonary embolism (Table 4).

Unilateral AH was diagnosed incidentally in all three patients (two right sided and one left sided) who underwent imaging to evaluate COVID-19 chest infection or to exclude pulmonary embolism (Tables 2 and 3). One patient was pregnant at the time of the diagnosis of AH and had a previously unknown underlying indeterminate nonfunctioning adrenal tumour, but the other two had no identifiable risk factors for haemorrhage. None of the patients with unilateral AH presented with abdominal pain or hypotension, or had adrenal insufficiency based on cortisol assessments that were considered reassuring or no assessment was undertaken as adrenal insufficiency was not suspected.

### 3.4 | COVID-19 vaccine-related adrenal haemorrhage

We uncovered 11 cases of COVID-19 vaccine-related AH, eight of whom were women (Table 2). The median age of patients was 47 years (range 23–78). Most patients had bilateral AH ( $N = 8$ ; 73%). The size of AH ranged from 30 mm to 89 mm. In nine patients, AH followed Oxford-AstraZeneca vaccine administration (82%) while in two cases AH was associated with the Pfizer-BioNTech mRNA vaccine. The median time between the receipt of vaccine and detection of AH was 9 days (range 2–27). AH was reported in association with the first dose of the vaccine in nine patients (82%; eight Oxford-AstraZeneca vaccine and one Pfizer-BioNTech), one case (Pfizer-BioNTech) followed the second dose, and one (Oxford-AstraZeneca) followed booster dosing. At the time of AH detection, 27% ( $N = 3$ ) of patients were taking anti-coagulants (two on apixaban and one edoxaban), one of whom had bilateral AH on a background of bilateral adrenal adenomas. Another patient with unilateral AH showed fluorodeoxyglucose avid uptake at PET-CT scan suggestive of an underlying adrenal tumour. Otherwise, no pre-existing risk

TABLE 2 Characteristics of 18 UK patients with adrenal haemorrhage (AH) related to COVID-19 infection or vaccination.

Case	Centre	Publication status	Infection or vaccine-related	Days after PCR + or vaccine	Type of vaccine	Dose	Sex	Age	Unilateral/ bilateral AH	Maximum size of AH on imaging (mm)	Radiological characteristics	Extra-adrenal thrombosis	Risk factors
1	University Hospitals Birmingham NHS Foundation Trust	Submitted	Infection	15	NA	NA	F	26	Unilateral - left	125	Indeterminate lesion (heterogeneous)	No	None (adrenal tumour diagnosed later)
2	St George's University Hospitals NHS Foundation Trust	Unpublished	Infection	35	NA	NA	M	39	Bilateral	Unknown	Haziness with bulky adrenals	No	None
3	St George's University Hospitals NHS Foundation Trust	Unpublished	Infection	8	NA	NA	F	61	Unilateral - right	Unknown	Fluid around right kidney	No	Unknown
4	Salisbury NHS Foundation Trust	Unpublished	Infection	12	NA	NA	M	77	Bilateral	68	Hyperdense content (HU 60-65)	Yes (PE)	Heparin use
5	Mid and South Essex NHS Foundation Trust	Published in journal <sup>12</sup>	Infection	1	NA	NA	M	50	Bilateral	Unknown	Unknown	Yes (deep venous thrombosis)	History of adrenal tumour
6	Barnsley Hospital NHS Foundation Trust	Published in journal <sup>15</sup>	Infection	1	NA	NA	M	50	Unilateral - right	12	Heterogeneous lesion, surrounding soft tissue	Yes (PE)	None
7	London North West University Healthcare NHS trust	Published in journal <sup>21</sup>	Infection	1	NA	NA	F	70	Bilateral	Unknown	Enlarged adrenals,	Unknown	None

(Continues)

TABLE 2 (Continued)

Case	Centre	Publication status	Infection or vaccine-related	Days after PCR + or vaccine	Type of vaccine	Dose	Sex	Age	Unilateral/ bilateral AH	Maximum size of AH on imaging (mm)	Radiological characteristics	Extra-adrenal thrombosis	Risk factors
8	The Princess Alexandra Hospital NHS Trust	Unpublished	VITT-definite	9	AZ	First	F	47	Bilateral	Unknown	Hyperdense content (HU 58)	Yes (PE)	None
9	University Hospital of Wales	Published in journal <sup>29</sup>	VITT-definite	8	AZ	First	M	38	Bilateral	Unknown	Retropertitoneal fat stranding, fluid around adrenals	Yes (PE + CVST)	None
10	University Hospital of Wales	Unpublished	VITT-unlikely	27	Pfizer	Second	M	73	Unilateral - left	Unknown	High density lesion with retroperitoneal fat stranding	Yes (CVST)	None
11	Oxford University Hospitals NHS Trust	Published in journal <sup>22</sup>	VITT-definite	16	AZ	First	F	23	Bilateral	48	MRI T2 low signal lesions	Yes (PE + splenic vein thrombosis)	Anticoagulant use
12	The Leeds Teaching Hospitals NHS Trust	Unpublished	VITT-unlikely	20	Pfizer	First	F	78	Unilateral - right	70	AH with abnormal FDG avid soft tissue, suggestive of underlying tumour	No	None
13	Chelsea and Westminster Hospital NHS Foundation Trust	Published in conference proceedings <sup>32</sup>	VITT-Probable	8	AZ	First	F	55	Bilateral	35	Bilateral hyperplasia	Yes (PE + ovary)	None
14	University Hospitals of Leicester NHS Trust	Unpublished	VITT-possible	2	AZ	Booster	F	70	Bilateral	100	Periarenal and perinephric stranding	No	Anticoagulant use + history of bilateral adrenal adenomas

TABLE 2 (Continued)

Case	Centre	Publication status	Infection or vaccine-related	Days after PCR + or vaccine	Type of vaccine	Dose	Sex	Age	Unilateral/ bilateral AH	Maximum size of AH on imaging (mm)	Radiological characteristics	Extra-adrenal thrombosis	Risk factors
15	University College London Hospitals NHS Foundation Trust	Published in journal <sup>25</sup>	VITT-definite	8	AZ	First	M	46	Bilateral	Unknown	Surrounding soft tissue stranding	Yes (acute MI, occipital infarction, dural CVST, PE, portal and hepatic vein thrombosis, bilateral renal cortical infarcts)	None
16	University College London Hospitals NHS Foundation Trust	Published in journal <sup>25</sup>	VITT-definite	11	AZ	First	F	38	Unilateral - left	Unknown		No	None
17	Sandwell and West Birmingham Hospitals NHS Trust	Published in journal <sup>26</sup>	VITT-definite	8	AZ	First	F	47	Bilateral	Unknown	Hyperdense content (HU 54)	Yes (PE + renal infarcts)	None
18	Wexham Park Hospital	Published in conference proceedings <sup>24</sup>	VITT-probable	10	AZ	First	F	23	Bilateral	Unknown	Surrounding soft tissue stranding	Yes (CVST, splenic vein, right ventricle)	Anticoagulant use

Abbreviations: AZ, Astra Zeneca; CVST, cerebral venous sinus thrombosis; NA, not applicable; PE, pulmonary embolism, risk factors: heparin or anti-coagulant drug use, history of an adrenal tumour, anti-phospholipid syndrome.



TABLE 3 Presentation of 18 UK patients with adrenal haemorrhage (AH) related to COVID-19 infection or vaccination.

Case	Type of AH	Later AH	Symptoms/signs	Sodium/ potassium (mmol/L)	D-dimer	Fibrinogen (g/L)	PF4 ELISA antibody	Morning cortisol (nmol/L)	Cortisol peak at stimulation test (nmol/L)	Adrenal insufficiency	Replacement treatment given
1	Infection	Unilateral	Abdominal pain	Unknown	Unknown	Unknown	NA	209	Not done	No	No
2	Infection	Bilateral	Abdominal pain, Hypotension, Vomiting, Tachycardia	141/4.1	Unknown	7.6	NA	Unknown	458	Yes	Yes (HC + FC)
3	Infection	Unilateral	Unknown	Unknown	Unknown	Unknown	NA	Unknown	Unknown	Unknown	Unknown
4	Infection	Bilateral	Hypotension, Tachycardia	126/5.5	670	5.3	NA	Unknown	264	Yes	Yes (HC + FC)
5	Infection	Bilateral	Abdominal pain, fever	135/3.9	10613	Unknown	NA	Unknown	Unknown	No (random cortisol >700)	No
6	Infection	Unilateral	Fever	Unknown	3.9	7.75	NA	Unknown	Unknown	No (random cortisol >600)	No
7	Infection	Bilateral	Abdominal pain, fever	112/unknown	Unknown	Unknown	NA	Unknown	Unknown	No (random cortisol >600)	No
8	VITT-definite	Bilateral	Abdominal pain, Fatigue, Vomiting	138/3.9	24004	4.2	Positive	32	30	Yes	Yes (HC + FC)
9	VITT-definite	Bilateral	Abdominal pain, Headache	136/3.6	>20000	3.5	Positive	61	Not done	Yes	Yes (HC + FC)
10	VITT-unlikely	Unilateral	Abdominal pain	135/4.1	3467	4	Not done	Long-term prednisolone	Long-term prednisolone	Long-term prednisolone	Long-term prednisolone
11	VITT-definite	Bilateral	Headache, confusion, Fever, Hypotension, Seizures, Tachycardia	132/4	>100000	Unknown	Positive	25	Not done	Yes	Yes (HC + FC)
12	VITT-unlikely	Unilateral	None	133/4.8	Not done	>4.5	Unknown	Unknown	Unknown	Unknown	No
13	VITT-probable	Bilateral	Abdominal pain, Vomiting, Lethargy, Tachycardia	130/3.3	8099	6.98	Not done	151	157	Yes	Yes (HC)
14	VITT-possible	Bilateral	Abdominal pain, Hypotension	135/4.4	Unknown	6.7	Not done	Not done	Unknown	Not assessed	Yes (HC + FC)

TABLE 3 (Continued)

Case	Type of AH	Later AH	Symptoms/signs	Sodium/potassium (mmol/L)	D-dimer	Fibrinogen (g/L)	PF4 ELISA antibody	Morning cortisol (nmol/L)	Cortisol peak at stimulation test (nmol/L)	Adrenal insufficiency	Replacement treatment given
15	VITT-definite	Bilateral	Abdominal pain, Vomiting	Unknown	>80000	Unknown	Positive	16	17	Yes	Yes (HC + FC)
16	VITT-definite	Unilateral	Abdominal pain, Headache, Vomiting	Unknown	4160	Unknown	Positive	187	239	Yes	Yes (HC)
17	VITT-definite	Bilateral	Abdominal pain, Vomiting	Unknown	24000	4.2	Positive	Unknown	Failed	Yes	Yes (HC + FC)
18	VITT-probable	Bilateral	Abdominal pain, Headache, Tachycardia	Unknown	10000	Unknown	Not done	25	Unknown	Yes	Yes (HC)

Abbreviations: COVID-19, coronavirus disease 2019; FC, fludrocortisone; HC, hydrocortisone; NA, not applicable; PF4, platelet factor; SST, Short Synacthen Test

factors for AH were observed. Regarding the diagnosis of VITT, six patients were definite, two probable, one possible and two unlikely (Pfizer-BioNTech). Six patients had associated pulmonary embolism, four had cerebral venous sinus thrombosis, and other sites of thrombosis included cardiac ventricles (two patients), splenic vein (two patients), renal infarcts (two patients), and portal, hepatic and ovarian veins (one patient each).

Bilateral AH was always associated with the Oxford-AstraZeneca vaccine. Seven patients (88%) presented with acute abdominal pain and in one patient imaging was undertaken to re-evaluate pulmonary embolism (Table 3). Two patients with bilateral AH (25%) had hypotension, and none had hyponatraemia. In the acute setting, 5 patients with bilateral AH (63%) had very low cortisol levels ranging from undetectable to 87 nmol/L, and therefore glucocorticoid and mineralocorticoid replacement were commenced. Three patients were empirically treated with glucocorticoids before their adrenal function was checked, with the later addition of mineralocorticoids; two subsequently failed their ACTH stimulation test and one is awaiting further investigations. Two patients had ACTH stimulation tests during follow up which showed suboptimal response (Table 4).

Two of the three patients with unilateral AH received the Pfizer-BioNTech vaccine, 20 and 27 days beforehand (Table 2). In two patients, AH was left sided and one right sided. Two patients presented with acute abdominal pain whilst in the third the detection of haemorrhage was incidental; none had hypotension or electrolyte disturbance (Table 3). One patient had associated cerebral venous sinus thrombosis. One patient (presented with abdominal pain and vomiting) had adrenal insufficiency confirmed by an ACTH stimulation test, another was on long-term prednisolone, and the third patient was not treated with glucocorticoids and did not undergo adrenocortical function testing (Table 4).

## 4 | DISCUSSION

This survey describes the largest data set thus far characterizing patients with COVID-19-related AH. Early studies suggested that AH is an underrecognized entity as the incidence in autopsy of patients died in shock was 15%<sup>33</sup> compared with 0.14%–1.8% in unselected autopsies.<sup>34,35</sup> One cannot infer the incidence of AH from these data as the numerator is minute compared to a denominator of millions of people who contracted the COVID-19 infection and received the vaccines. However, these data enable us to make useful observations for clinicians in guiding timely recognition and treatment that may prevent fatal adrenal crisis.

The vascular structure of the adrenal glands makes them susceptible to turbulent flow or stasis due to their abundant arterial supply with relatively limited drainage via a single vein.<sup>36</sup> This so-called “adrenal dam” renders the adrenal gland highly susceptible to haemorrhage in any pro-thrombotic state, with adrenal vein thrombosis the likely primary event. COVID-19 illness represents a prothrombotic state in many cases<sup>5,6</sup> which may predispose to haemorrhage, though sepsis also increases the risk of AH by

**TABLE 4** Outcome at follow-up of 18 UK patients with adrenal haemorrhage (AH) related to COVID-19 infection or vaccination.

Case	Type of AH	Unilateral/ bilateral AH	Duration of hospital stay (days)	Outcome at last follow-up	Cause of death	Adrenal function re-tested	Morning cortisol (nmol/L)	Cortisol peak at SST (nmol/L)	Adrenal insufficiency	Radiological follow-up
1	Infection	Unilateral		Alive	NA	Yes - baseline		Not done	No	Yes - underlying adrenal tumour
2	Infection	Bilateral	7	Alive	NA	Yes - SST	171	458		-
3	Infection	Unilateral	Unknown	Unknown	NA	Unknown	Unknown	Unknown	Unknown	Unknown
4	Infection	Bilateral	86	Deceased	COVID-19 pneumonitis	No	-	-	-	-
5	Infection	Bilateral	5	Deceased	Massive pulmonary embolism	No	-	-	-	-
6	Infection	Unilateral	7	Alive	NA	Yes - SST	400	812	No	Yes
7	Infection	Bilateral	Unknown	Alive	NA	Unknown	Unknown	Unknown	Unknown	Unknown
8	VITT-definite	Bilateral	16	Alive	NA	No	-	-	-	-
9	VITT-definite	Bilateral	17	Alive	NA	Yes - SST	141	139	Yes	-
10	VITT-unlikely	Unilateral	5	Alive	NA	Yes - SST	145	385	Yes	-
11	VITT-definite	Bilateral	14	Alive	NA	Yes - SST	37	43	Yes	-
12	VITT-unlikely	Unilateral	0	Alive	NA	No	-	-	-	-
13	VITT-probable	Bilateral	27	Alive	NA	No	-	-	-	-
14	VITT-possible	Bilateral	6	Alive	NA	No	-	-	-	-
15	VITT-definite	Bilateral	23	Alive	NA	No	-	-	-	Yes
16	VITT-definite	Unilateral	Unknown	Alive	NA	No	-	-	-	Yes
17	VITT-definite	Bilateral	Unknown	Alive	NA	No	-	-	-	Unknown
18	VITT-probable	Bilateral	Unknown	Alive	NA	No	-	-	-	Unknown

Abbreviation: COVID-19, coronavirus disease 2019.

six-fold.<sup>37</sup> Adrenal vein thrombosis was evident in 6 out of 220 (3%) VITT patients in the UK<sup>7</sup> and associated with thrombosis in other sites.

Although there was no predilection to either sex in COVID-19 infection-related AH, most patients with vaccine-related haemorrhage were women (73% in the UK survey and 67% in the systematic review). This female predilection has previously been highlighted,<sup>38</sup> although the cause is unclear. Noteworthy, VITT-related AH was always associated with the first dose of Oxford-AstraZeneca vaccine.

Most patients (72%) underwent imaging for acute abdominal pain which was commoner with bilateral, compared with unilateral AH. Therefore, during the COVID-19 pandemic and as the vaccines roll out continues, it is important to consider AH in the differential diagnosis of acute abdominal pain, particularly in the context of VITT.

As expected, adrenal insufficiency was more evident in bilateral AH but also reported in unilateral AH associated with VITT. Adrenal insufficiency following unilateral AH has previously been observed,<sup>2,39,40</sup> likely suggesting microinfarction in the contralateral adrenal gland. Therefore, in bilateral AH, glucocorticoid treatment should be commenced without delay whilst clinicians should have a low threshold to start treatment in patients with unilateral AH, if they display features of adrenal insufficiency. Adrenal function testing should be undertaken when patients are stable, ideally in an outpatient setting. It is important to recognize that the rapidity of haemorrhage and primary adrenal insufficiency may not allow sufficient time for skin hyperpigmentation to manifest.

Patients with COVID-19 infection-related AH presented with more clinical manifestations of adrenal insufficiency (hypotension), compared to AH that followed vaccination, likely due to the added stress of the infection and cytokine storm. Furthermore, two patients with COVID-19 infection-related AH died while no death was recorded in the captured patients with vaccine-related AH. Of relevance, AH has been associated with poor clinical outcomes in patients with sepsis for possibly being a marker of severe physiological stress.<sup>2,41</sup>

Most patients in this study did not have other identifiable risk factors for AH. When AH is detected, it is important to exclude an underlying adrenal tumour as outside of the context of COVID-19 half of haemorrhagic adrenal masses turn out to be pheochromocytomas, and 20% are malignancy-related.<sup>42</sup> Therefore, a period of radiological surveillance is usually required to ensure the resolution of haematoma.<sup>1</sup>

There is a paucity of data that studied the natural history of primary adrenal insufficiency from AH, however, recovery of adrenal function was uncommonly observed in case series.<sup>2,3,43</sup>

The survey identified two patients who developed adrenal haemorrhage in the days following the Pfizer-BioNTech mRNA-based vaccine. The UK Medicines and Healthcare Products Regulatory Agency (MHRA) received reports of AH and thrombocytopenia following vaccination with Pfizer-BioNTech and Moderna. As mRNA-based vaccine will dominate future vaccine development, it remains important to be alert to this possible association.

More generally, as AH has no specific clinical features, vigilance is key to suspect the diagnosis in acutely unwell patients, particularly in prothrombotic and florid infective states.

The strengths of our study include the comparatively large number of cases reported, with data collection undertaken systematically after a widely circulated survey. However, our study was limited by the retrospective nature of the data collection and lack of long-term follow-up. Finally, whilst we highlight the importance of timely recognition and treatment of AH in relation to COVID-19 vaccination, it is crucial to emphasize that this complication appears to be rare. In the UK, the competent authority, MHRA, concluded that the benefits of the Oxford-AstraZeneca vaccine far outweigh any potential risks.<sup>44</sup>

## 5 | CONCLUSION

AH can be a serious complication of COVID-19 infection and vaccination. Adrenal insufficiency is present in most cases of bilateral AH and can occur in unilateral adrenal haemorrhage associated with VITT. A high index of suspicion for AH is required, particularly in the presence of unexplained abdominal pain, to avoid the potentially fatal consequences of unrecognised adrenal insufficiency.

## ACKNOWLEDGMENTS

We wish to acknowledge Dr Afroze Abbas, Dr Gul Bano, Dr Edson Nogueira, Dr Aparna Pal, Dr Rebecca Sagar, Dr Rachel Sinha, Dr Martin Smith, and Dr Aristeidis Vagenas for responding to the survey and providing data. We also wish to acknowledge Dr Jessica Davis, Clinical Practice Manager at the Society for Endocrinology for her assistance during this study. This work received no dedicated funding support.

## CONFLICT OF INTEREST STATEMENT

The authors declare no conflict of interest.

## ORCID

Yasir S. Elhassan  <http://orcid.org/0000-0002-2735-6053>

Miles Levy  <http://orcid.org/0000-0001-7256-7880>

Cristina L. Ronchi  <http://orcid.org/0000-0001-5020-2071>

## REFERENCES

1. Elhassan YS, Ronchi CL, Wijewickrama P, Baldeweg SE, Elhassan Y. Approach to the Patient with Adrenal Hemorrhage/adrenal hemorrhage. *J Clin Endocrinol Metab*. Published online November 21, 2022.
2. Vella A, Nippoldt TB, Morris JC. Adrenal hemorrhage: a 25-year experience at the Mayo Clinic. *Mayo Clin Proc*. 2001;76(2):161-168.
3. Ramon I, Mathian A, Bachelot A, et al. Primary adrenal insufficiency due to bilateral adrenal hemorrhage-adrenal infarction in the antiphospholipid syndrome: Long-Term outcome of 16 patients. *J Clin Endocrinol Metab*. 2013;98(8):3179-3189.
4. Lazartigues E, Qadir MMF, Mauvais-Jarvis F. Endocrine significance of SARS-CoV-2's reliance on ACE2. *Endocrinology*. 2020;161(9):1-7.
5. Al-Samkari H, Karp Leaf RS, Dzik WH, et al. COVID-19 and coagulation: bleeding and thrombotic manifestations of SARS-CoV-2 infection. *Blood*. 2020;136(4):489-500.

6. Klok FA, Kruip MJHA, van der Meer NJM, et al. Incidence of thrombotic complications in critically ill ICU patients with COVID-19. *Thromb Res.* 2020;191:145-147.
7. Pavord S, Scully M, Hunt BJ, et al. Clinical features of Vaccine-Induced immune thrombocytopenia and thrombosis. *N Engl J Med.* 2021;385(18):1680-1689.
8. Concepción-Zavaleta MJ, Ildefonso-Najarro SP, Plasencia-Dueñas E, et al. Bilateral neonatal adrenal hemorrhage associated with severe maternal COVID-19 infection. *Cureus.* 2021;13(11).
9. Rebollo-Román A, Alhambra-Expósito MR, Herrera-Martínez Y, et al. Catecholaminergic crisis after a bleeding complication of COVID-19 infection: a case report. *Front Endocrinol.* 2021;12(693004).
10. Miranda R, Raurich R, Aris R, Ramírez D, Hidalgo C. Hemorragia adrenal bilateral en paciente recuperado de neumonía COVID-19 Grave. Caso Radiológico. *Rev Med Chil.* 2021;149(7):1081-1084.
11. Sreedharan R, Factora F, Trombetta C, et al. Hypercoagulability resulting in adrenal hemorrhage in COVID-19. *Colomb J Anesthesiol.* 2022;50(e992).
12. Elkhoully MMN, Elazzab AA, Moghul SS. Bilateral adrenal hemorrhage in a man with severe COVID-19 pneumonia. *Radiol Case Rep.* 2021;16(6):1438-1442.
13. Jaiswal R, Schulman-Rosenbaum R. Abstract #1002785: A case of bilateral adrenal hemorrhage associated with COVID-19. *Endocrine Practice.* 2021;27(6):S12.
14. F. S, DJ O. SARS-COV-2 presenting with acute adrenal hemorrhage. *Ir J Med Sci.* 2021;190(SUPPL 3):S103.
15. Sharrack N, Baxter CT, Paddock M, Uchegbu E. Adrenal haemorrhage as a complication of COVID-19 infection. *BMJ Case Rep.* 2020;13(11):e239643.
16. Frankel M, Feldman I, Levine M, et al. Bilateral adrenal hemorrhage in coronavirus disease 2019 patient: a case report. *J Clin Endocrinol Metab.* 2020;105(12):3745-3749.
17. Álvarez-Troncoso J, Zapatero Larrauri M, Montero Vega MD, et al. Case report: COVID-19 with bilateral adrenal hemorrhage. *Am J Trop Med Hyg.* 2020;103(3):1156-1157.
18. Machado IFR, Menezes IQ, Figueiredo SR, et al. Primary adrenal insufficiency due to bilateral adrenal infarction in COVID-19. *J Clin Endocrinol Metab.* 2022;107(1):e394-e400.
19. Asano Y, Koshi T, Sano A, et al. A patient with mild respiratory COVID-19 infection who developed bilateral non-hemorrhagic adrenal infarction. *Nagoya J Med Sci.* 2021;83(4):883-891.
20. Haider SS, Shaikh F, Rayasam V, Kumar D, Helmstetter N. Bilateral adrenal gland infarction in the setting of COVID-19 infection. *Am J Respir Crit Care Med.* 2021;203:A4075.
21. Kumar R, Guruparan T, Siddiqi S, et al. A case of adrenal infarction in a patient with COVID 19 infection. *BJR | Case Rep.* 2020;6(3):20200075.
22. Efthymiadis A, Khan D, Pavord S, et al. A case of ChAdOx1 vaccine-induced thrombocytopenia and thrombosis syndrome leading to bilateral adrenal haemorrhage and adrenal insufficiency. *Endocrinol Diabetes Metab Case Rep.* 2022;2022(1).
23. Tews HC, Driendl SM, Kandulski M, et al. SARS-CoV-2 vaccine-induced immune thrombotic thrombocytopenia with venous thrombosis, pulmonary embolism, and adrenal haemorrhage: a case report with literature review. *Vaccines.* 2022;10(4):595.
24. Ahmad S, Zaman N, Almajali K, Mohammadi A, Baburaj R, Akavarapu S. A novel case of bilateral adrenal hemorrhage and acute adrenal insufficiency due to VITT (vaccine induced thrombosis and thrombocytopenia) syndrome. *Endocr Abstr.* 2021;74(OC2).
25. Graf A, Armeni E, Dickinson L, et al. Adrenal haemorrhage and infarction in the setting of vaccine-induced immune thrombocytopenia and thrombosis after SARS-CoV-2 (Oxford-AstraZeneca) vaccination. *Endocrinol Diabetes Metab Case Rep.* 2022;2022:21-0144.
26. Tha T, Martini I, Stefan E, Redla S. Bilateral adrenal haemorrhage with renal infarction after ChAdOx1 nCoV-19 AstraZeneca vaccination. *BJR|Case Rep.* 2022;8(2):20210139.
27. Varona JF, García-Isidro M, Moeinvaziri M, Ramos-López M, Fernández-Domínguez M. Primary adrenal insufficiency associated with Oxford-AstraZeneca ChAdOx1 nCoV-19 vaccine-induced immune thrombotic thrombocytopenia (VITT). *Eur J Intern Med.* 2021;91:90-92.
28. Douxfils J, Vayne C, Pouplard C, et al. Fatal exacerbation of ChadOx1-nCoV-19-induced thrombotic thrombocytopenia syndrome after initial successful therapy with intravenous immunoglobulins - a rationale for monitoring immunoglobulin G levels. *Haematologica.* 2021;106(12):3249-3252.
29. Taylor P, Allen L, Shrikrishnapalasuriyar N, Stechman M, Rees A. Vaccine-induced thrombosis and thrombocytopenia with bilateral adrenal haemorrhage. *Clin Endocrinol (Oxf).* 2022;97(1):26-27.
30. Blauenfeldt RA, Kristensen SR, Ernstsén SL, Kristensen CCH, Simonsen CZ, Hvas AM. Thrombocytopenia with acute ischemic stroke and bleeding in a patient newly vaccinated with an adenoviral vector-based COVID-19 vaccine. *J Thromb Haemostasis.* 2021;19(7):1771-1775.
31. D'agostino V, Caranci F, Negro A, et al. A rare case of cerebral venous thrombosis and disseminated intravascular coagulation temporally associated to the COVID-19 vaccine administration. *J Pers Med.* 2021;11(4):285.
32. Boyle LD, Morganstein DL, Mitra I, Nogueira EF A rare case of multiple thrombi and left adrenal haemorrhage following COVID-19 vaccination. *Endocr Abstr.* 2021;74(NCC4).
33. Russell P. The adrenal glands in shock. *Pathology.* 1972;4(1):5-8.
34. Botteri A, Orell SR. Adrenal hemorrhage and necrosis in the adult. *Acta Med Scand.* 1964;175(4):409-419. doi:10.1111/j.0954-6820.1964.tb00590.x
35. Xarli VP, Steele AA, Davis PJ, Buescher ES, Rios CN, Garcia-Bunuel R. Adrenal hemorrhage in the adult. *Medicine.* 1978;57(3):211-222.
36. Fox B. Venous infarction of the adrenal glands. *J Pathol.* 1976;119(2):65-89.
37. Kovacs KA, Lam YM, Pater JL. Bilateral massive adrenal hemorrhage: assessment of putative risk factors by the case-control method. *Medicine.* 2001;80(1):45-53.
38. Cines DB, Bussel JB. SARS-CoV-2 Vaccine-Induced immune thrombotic thrombocytopenia. *N Engl J Med.* 2021;384(23):2254-2256.
39. Knight B. Sudden unexpected death from adrenal haemorrhage. *Forensic Sci Int.* 1980;16(3):227-229.
40. Ly BA, Quintero L. Adrenal insufficiency from unilateral adrenal hemorrhage in a patient on rivaroxaban thromboprophylaxis. *AACE Clin Case Rep.* 2019;5(1):e70-e72.
41. Rao RH. Bilateral massive adrenal hemorrhage. *Med Clin North Am.* 1995;79(1):107-129.
42. Marti JL, Millet J, Sosa JA, Roman SA, Carling T, Udelsman R. Spontaneous adrenal hemorrhage with associated masses: etiology and management in 6 cases and a review of 133 reported cases. *World J Surg.* 2012;36(1):75-82.
43. Jahangir-Hekmat M, Taylor HC, Levin H, Wilbur M, Llerena LA. Adrenal insufficiency attributable to adrenal hemorrhage: long-term follow-up with reference to glucocorticoid and mineralocorticoid function and replacement. *Endocrine Practice.* 2004;10(1):55-61.
44. Coronavirus vaccine - summary of Yellow Card reporting - GOV.UK. Accessed September 14, 2022. <https://www.gov.uk/government/publications/coronavirus-covid-19-vaccine-adverse-reactions/coronavirus-vaccine-summary-of-yellow-card-reporting>

**How to cite this article:** Elhassan YS, Iqbal F, Arlt W, et al. COVID-19-related Adrenal Haemorrhage: multicentre UK Experience and Systematic Review of the Literature. *Clin Endocrinol (Oxf).* 2023;98:766-778. doi:10.1111/cen.14881