



This is a repository copy of *Periodontal disease affects oral cancer progression in a surrogate animal model for tobacco exposure*.

White Rose Research Online URL for this paper:
<https://eprints.whiterose.ac.uk/195649/>

Version: Published Version

Article:

Spuldaro, T., Wagner, V., Nör, F. et al. (5 more authors) (2022) Periodontal disease affects oral cancer progression in a surrogate animal model for tobacco exposure. *International Journal of Oncology*, 60 (6). 77. ISSN 1019-6439

<https://doi.org/10.3892/ijo.2022.5367>

Reuse

This article is distributed under the terms of the Creative Commons Attribution-NonCommercial-NoDerivs (CC BY-NC-ND) licence. This licence only allows you to download this work and share it with others as long as you credit the authors, but you can't change the article in any way or use it commercially. More information and the full terms of the licence here: <https://creativecommons.org/licenses/>

Takedown

If you consider content in White Rose Research Online to be in breach of UK law, please notify us by emailing eprints@whiterose.ac.uk including the URL of the record and the reason for the withdrawal request.



eprints@whiterose.ac.uk
<https://eprints.whiterose.ac.uk/>

Periodontal disease affects oral cancer progression in a surrogate animal model for tobacco exposure

TOBIAS R. SPULDARO¹, VIVIAN P. WAGNER^{2,3}, FELIPE NÖR^{2,4},
EDUARDO J. GAIO¹, CRISTIANE H. SQUARIZE^{4,6}, VINICIUS C. CARRARD^{2,7},
CASSIANO K. RÖSING¹ and ROGERIO M. CASTILHO^{4,6}

Departments of ¹Periodontology and ²Oral Pathology, Federal University of Rio Grande do Sul, Porto Alegre, RS 90010-150, Brazil; ³Academic Unit of Oral and Maxillofacial Medicine and Pathology, Department of Clinical Dentistry, University of Sheffield, Sheffield S10 2TN, UK; ⁴Department of Periodontics and Oral Medicine, University of Michigan, Ann Arbor, MI 48109-1078; ⁵Laboratory of Epithelial Biology, University of Michigan School of Dentistry, Ann Arbor, MI 48109-1078; ⁶Rogel Cancer Center, University of Michigan, Ann Arbor, MI 48109-0944, USA; ⁷Department of Oral Medicine, Otorhinolaryngology Service, Porto Alegre General Hospital, Port Alegre, RS 90035-903, Brazil

Received February 11, 2022; Accepted April 12, 2022

DOI: 10.3892/ijo.2022.5367

Abstract. For decades, the link between poor oral hygiene and the increased prevalence of oral cancer has been suggested. Most recently, emerging evidence has suggested that chronic inflammatory diseases from the oral cavity (e.g., periodontal disease), to some extent, play a role in the development of oral squamous cell carcinoma (OSCC). The present study aimed to explore the direct impact of biofilm-induced periodontitis in the carcinogenesis process using a tobacco surrogate animal model for oral cancer. A total of 42 Wistar rats were distributed into four experimental groups: Control group, periodontitis (Perio) group, 4-nitroquinoline 1-oxide (4-NQO) group and 4NQO/Perio group. Periodontitis was stimulated by placing a ligature subgingivally, while oral carcinogenesis was induced by systemic administration of 4NQO in the drinking water for 20 weeks. It was observed that the Perio, 4NQO and 4NQO/Perio groups presented with significantly higher alveolar bone loss compared with that in the control group. Furthermore, all groups receiving 4NQO developed lesions on the dorsal surface of the tongue; however, the 4NQO/Perio group presented larger lesions compared with the 4NQO group. There was also a modest overall increase in the number of epithelial dysplasia and OSCC lesions in the 4NQO/Perio group. Notably, abnormal focal activation

of cellular differentiation (cytokeratin 10-positive cells) that extended near the basal cell layer of the mucosa was observed in rats receiving 4NQO alone, but was absent in rats receiving 4NQO and presenting with periodontal disease. Altogether, the presence of periodontitis combined with 4NQO administration augmented tumor size in the current rat model and tampered with the protective mechanisms of the cellular differentiation of epithelial cells.

Introduction

Oral cancer is a major public health problem, with >500,000 new cases per year worldwide (1). Squamous cell carcinoma from the oral cavity and surrounding anatomical areas is the most common malignancy from the head and neck area, accounting for 90% of all tumors (2). Overall survival rates remain low at 50% after 5 years from the initial diagnosis and have not improved significantly in the last three decades (3,4). Oral squamous cell carcinoma (OSCC) has a multifactorial origin with several risk factors that act individually or in combination (5). The predominant etiological factors for OSCC involve tobacco and alcohol consumption, with an estimated 5-fold increase risk for cancer development in heavy smokers (2,6,7).

Emerging evidence indicates that periodontitis may be an associated risk factor for OSCC (2,5,8,9). In fact, the presence of periodontal disease has been associated with an elevated risk of lung and colorectal cancer in a population study of >7,000 participants (10). Periodontitis represents an infection-induced chronic inflammatory disease that leads to irreversible loss of the supporting structures of the teeth. The heavy burden of periodontitis is directly associated with its high prevalence. Severe periodontitis is estimated to represent the 6th most prevalent disease, affecting around 743 million people worldwide (11). The biological mechanism by which periodontitis could act as a predisposing factor to oral cancer

Correspondence to: Dr Rogerio M. Castilho, Department of Periodontics and Oral Medicine, University of Michigan, 1011 N. University Ave., Room - 3150 Commons, Ann Arbor, MI 48109-1078, USA
E-mail: rcastilh@umich.edu

Key words: head and neck cancer, 4-nitroquinoline-1-oxide, periodontitis, ligature, cell differentiation

initiation and development is hypothesized in two theories: i) The direct involvement of the periodontopathogens; and ii) indirectly by inducing a persistent chronic inflammatory state (8,9). The constant polymicrobial infection present in periodontitis and the associated release of pro-inflammatory mediators are likely to play an important role in the initiation and/or progression of oral cancer, or at least increase its susceptibility (2).

Epidemiological studies present several confounding factors that can affect the establishment of an accurate correlation between periodontitis and oral cancer, such as smoking and alcohol consumption. The majority of experimental studies trying to establish a direct link between periodontal disease and OSCC were performed with cell lines and focused on the carcinogenic potential of *Porphyromonas gingivalis* (*P. gingivalis*), a major pathogen of periodontal disease (12). *in vivo*, experimental studies are still scarce and focus on *P. gingivalis* (13). The results indicate an association between *P. gingivalis* infection and OSCC development (13,14). Despite emerging evidence, to the best of our knowledge, the *in vivo* evaluation of biofilm-induced periodontitis in oral carcinogenesis and tumor progression has not been explored. Therefore, the present study aimed to analyze the effect of ligature-induced periodontitis on the development of 4-nitroquinoline 1-oxide (4NQO)-induced OSCC in Wistar rats.

Materials and methods

Animals and experimental procedures. The present study was performed in accordance with Brazilian Federal Law No. 11.794/2008 for the scientific use of animals. The study protocol was submitted to and approved by the Animal Use Ethics Committee, Porto Alegre General Hospital (Porto Alegre, Brazil; approval no. 150475). Each sample size calculation for the experimental groups was performed based on previous studies with a similar methodology. The control group and the group with induced periodontitis (Perio) were comprised of 8 animals each, while the groups receiving 4-nitroquinoline 1-oxide (4NQO) were composed of 13 animals to account for the expected mortality rate of ~30% due to 4NQO-related side effects during the 20 weeks of carcinogen administration (Fig. 1A) (15-17).

A total of 42 60-day-old male Wistar rats were used in the study. Rats were shipped weighing ~250 g, and after the acclimation period, rats gained an additional 100 g, therefore weighing 350 g at the start date of the experiments (Fig. 1B). The rats were provided by the Center for Reproduction and Experimentation in Laboratory Animals (Federal University of Rio Grande do Sul, Porto Alegre, Brazil) and acclimated for 2 weeks at the Animal Experimentation Unit of the Porto Alegre General Hospital. Animals were kept under standard temperature conditions at 22±2°C, using a light/dark cycle of 12 h, with a relative humidity of 50-70% and free access to sterilized rodent laboratory chow (Nuvilab CR1; Quimtia S.A.).

Animals were randomly distributed throughout the four groups according to bodyweight: Control (n=8), Perio (n=8), 4NQO (n=13) and 4NQO/Perio (n=13). Periodontitis was induced by placing a 4-0 silk ligature subgingivally (Ethicon, Inc.; Johnson & Johnson). Ligatures were placed around the right maxilla second molar under isoflurane anesthesia

(5% of isoflurane for induction and 2% for maintenance) 2 weeks before 4NQO administration. Subgingival ligatures were kept in place during the experiment (22 weeks) (18,19). 4NQO solution was used to induce oral carcinogenesis according to a previously published protocol (20,21). Fresh solutions were prepared every 2 days, and rats were exposed to 25 ppm of the 4NQO carcinogen solution (Sigma-Aldrich; Merck KGaA; catalog no. N8141) diluted in drinking water for 20 weeks (15). Cage water consumption was measured each time the solution was replaced (Fig. 1C). Animal weight and health status were monitored every other day by the researcher and constantly monitored by the vivarium staff and veterinarian during the experimental period. There was no evidence of ligature-induced disruption of food intake. In total, 2 animals from the 4NQO group required early euthanasia using 5% isoflurane followed by exsanguination during the experimental period due to bodyweight loss of 20% as an adverse effect advent from 4NQO administration. Death was verified by the lack of vital signs, including the absence of respiration and heartbeat. Other endpoints considered during the experiment included oral tumor burden presenting as disrupted eating and drinking behaviors associated with bodyweight loss of 20%. Animals from the Control, Perio, 4NQO and 4NQO/Perio groups were anesthetized by inhalation of isoflurane (5%), followed by euthanasia by decapitation. After euthanasia, the tongues and maxillae from the rats were removed and stored in 10% formalin for 24-72 h at room temperature.

Determination of lesion surface area. Tumor development was assessed on the dorsal area of the tongues. Images were captured of each tongue specimen, and the number and the size of the lesions were determined (Fig. 1D). Total lesion area was measured using ImageJ 1.46r software (National Institutes of Health). The area was calculated in pixels and converted to mm² using a scale reference. Briefly, the scale was set using the straight-line tool from the ImageJ toolbar over a known scale (i.e., ruler image next to an open image). Under Analyze>Set Scale, the known scale was added to the 'known distance' field and 'Unit of length' was set in millimeters. Next, all images to be analyzed were transformed into 8-bit images (Image>Type>8-bit). Lesions were delineated using the 'Freehand selections' tool from the ImageJ toolbar. Lesion area was calculated using the analysis tool under the menu bar Analyze>Measure. Sequential measurements of all lesions were recorded. Additional information on ImageJ tools can be found at <https://imagej.nih.gov/ij/docs/>.

Morphometrical analysis. All maxillae were defleshed using 9% sodium hypochlorite for 4 h at room temperature, and soft tissue was removed carefully. Maxillae were stained for 1 min in methylene blue (1%) to outline the cemento-enamel junction (CEJ). Standardized pictures were captured of the buccal and palatal sides of the maxillae and measured using ImageJ 1.46r software (National Institutes of Health) (Fig. 1E). Five linear points were recorded, and the mean of the values considering the distance between the CEJ and the alveolar bone crest was considered for bone loss. To ensure that the examiner was blinded to the groupings, pictures were randomized by a computer program, coded and renamed by an external examiner. Approximately 10% of the maxillae were randomly

selected and twice measured in terms of alveolar bone loss, and compared using the intraclass correlation coefficient, which showed excellent results (0.96).

Histological and immunostaining analysis. Tongues were embedded in paraffin blocks and longitudinally thin-sectioned (4 μ m). The sections were stained with hematoxylin for 4 min and eosin for 2 min, at room temperature (Merck KGaA) and graded as normal, epithelial dysplasia and carcinoma (Fig. 1F and G) by two blinded expert oral pathologists (differences in grading were discussed and agreement was achieved). Hematoxylin and eosin-stained slides were scanned using an Aperion ScanScope slide scanner (Leica Biosystems).

Immunofluorescence was performed using double staining with anti-cytokeratin 10 (CK10) (clone Poly19054; cat. no. 905404; 1:500; BioLegend, Inc.) as the primary antibody for 1 h at room temperature, followed by use of Alexa Fluor[®] 568 (cat. no. A11036; 1:200; Invitrogen; Thermo Fisher Scientific, Inc.) as the secondary antibody for 45 min at room temperature. DNA was stained using Hoechst 33342 (cat. no. H1399; 1:5,000; Invitrogen; Thermo Fisher Scientific, Inc.) for 5 min at room temperature. Bovine serum albumin (cat. no. 9048-46-8; MilliporeSigma) diluted to 3% in PBS was used as a blocking solution prior to the incubation of primary antibody for 45 min at room temperature. Images of the entire tongue of different groups were captured at x200 magnification using a QImaging-ExiAqua monochrome digital camera attached to an epi-fluorescence Nikon microscope (Nikon Corporation) and visualized with QCapturePro 7 software (QImaging; Teledyne Photometrics). The Control and Perio groups had 1 sample per group, and the 4NQO and 4NQO/Perio groups had 6 samples per group (2 samples diagnosed with OSCC and 4 samples diagnosed with dysplasia). The 4NQO and 4NQO/Perio groups had a total of 398 fields captured each. Images were randomized by a computer program, and coded and renamed by an external examiner. A blinded examiner analyzed the images by evaluating the presence of CK10 positivity in the basal cell layer within each field. The percentage of positive fields per experimental group was calculated and used for statistical analysis.

Statistical analysis. The variables of this study were tested for normality. Data were analyzed using the statistical package GraphPad Prism 7 (GraphPad Software, Inc.). Findings were reported as the mean \pm SEM. One-way ANOVA followed by Tukey's multiple comparison test was used on the alveolar bone analysis and weight gain data. Solution consumption data were analyzed using one-way ANOVA followed by Dunnett's multiple comparisons test. Unpaired student's t-test was used for tumor size and CK10⁺ field data analysis. The incidence of OSCC was compared using the χ^2 test, and the odds ratio and the 95% confidence interval were computed using binary logistic regression. $P < 0.05$ was used to indicate a statistically significant difference.

Results

Weight and solution consumption analysis. Fig. 1A shows a flowchart of the study design. All animals gained weight during the study (Fig. 1B). Animals exposed to 4NQO consistently

gained weight during the first 16 weeks of drug administration. The modest weight gain during the first 4 weeks of 4NQO administration is commonly observed throughout different animal models as part of the adaptation process to 4NQO intake. A decline in animal weight after 16 weeks of drug administration was observed in both groups receiving 4NQO.

During the entire 20-weeks of 4NQO administration significant weight loss was only observed in the 4NQO and 4NQO/Perio groups compared with the Perio group at week 20 (mean difference, 93.2 and 99.4; $P = 0.0042$ and $P = 0.0022$, respectively). When compared with the Control group, the 4NQO and 4NQO/Perio groups showed no significant difference throughout the experiment. A parallel may be drawn regarding solution consumption. The 4NQO group consistently drank less than the control group throughout the experiment (Fig. 1C). Significantly lower solution consumption was observed during weeks 1, 4, 12, 16 and 20 of exposure to the carcinogen in the 4NQO group (mean difference, 362.0, 293.6, 305.4, 307.9, and 396.3; $P = 0.0156$, $P = 0.0472$, $P = 0.0272$, $P = 0.00081$ and $P = 0.0154$, respectively), and in the first week of exposure in the 4NQO/Perio group (mean difference, 357.0; $P = 0.0168$) compared with that in the Control group.

Alveolar bone loss analysis. Alveolar bone loss was measured in the second maxillary molar on the right side, in which periodontitis was induced using ligatures. The mean level of bone loss in the Perio, 4NQO and 4NQO/Perio groups (0.57 ± 0.02 , 0.57 ± 0.06 and 0.66 ± 0.02 mm, respectively) was significantly higher compared with that in the Control group (0.38 ± 0.02 mm) (Fig. 2A and B). Unexpectedly, it was observed that the administration of 4NQO alone resulted in alveolar bone loss similar to that in the Perio group.

Lesion size and histopathological analysis. All groups that received 4NQO developed lesions on the dorsal surface of the tongue. Images of dissected tongues were captured, and the total area of the lesions was identified by an expert pathologist and digitally identified and marked with a red 'mask' using ImageJ to determine the lesion surface area. The mean lesion surface area for the 4NQO/Perio group (62.75 ± 9.72 mm²) was significantly higher than that observed for the 4NQO-treated group (44.25 ± 6.69 mm²) (Fig. 3A and B). Histological analysis revealed that the incidence of epithelial dysplasia and invasive squamous cell carcinoma was similar among the 4NQO and 4NQO/Perio-treated animals, with a slight increase in the number of lesions found in 4NQO/Perio rodents (Fig. 4A). Also, both groups developed large tumors characterized by the infiltration of the muscle tissue of the tongue and focal poorly differentiated tumor areas (Fig. 4B).

Cell differentiation analysis. During the process of the histological analysis of tissues from the 4NQO and 4NQO/Perio groups, abnormal morphological changes were observed in the epithelial layer of the dorsal tongue mucosa receiving 4NQO alone. The observed alterations were suggestive of focal activation of cellular differentiation that extended near to the basal cell layer of the mucosa (Fig. 4C). In order to further explore these findings, the expression of CK10, a known marker of epithelial cell differentiation, was assessed in the rats receiving 4NQO and 4NQO/Perio. CK10 is normally

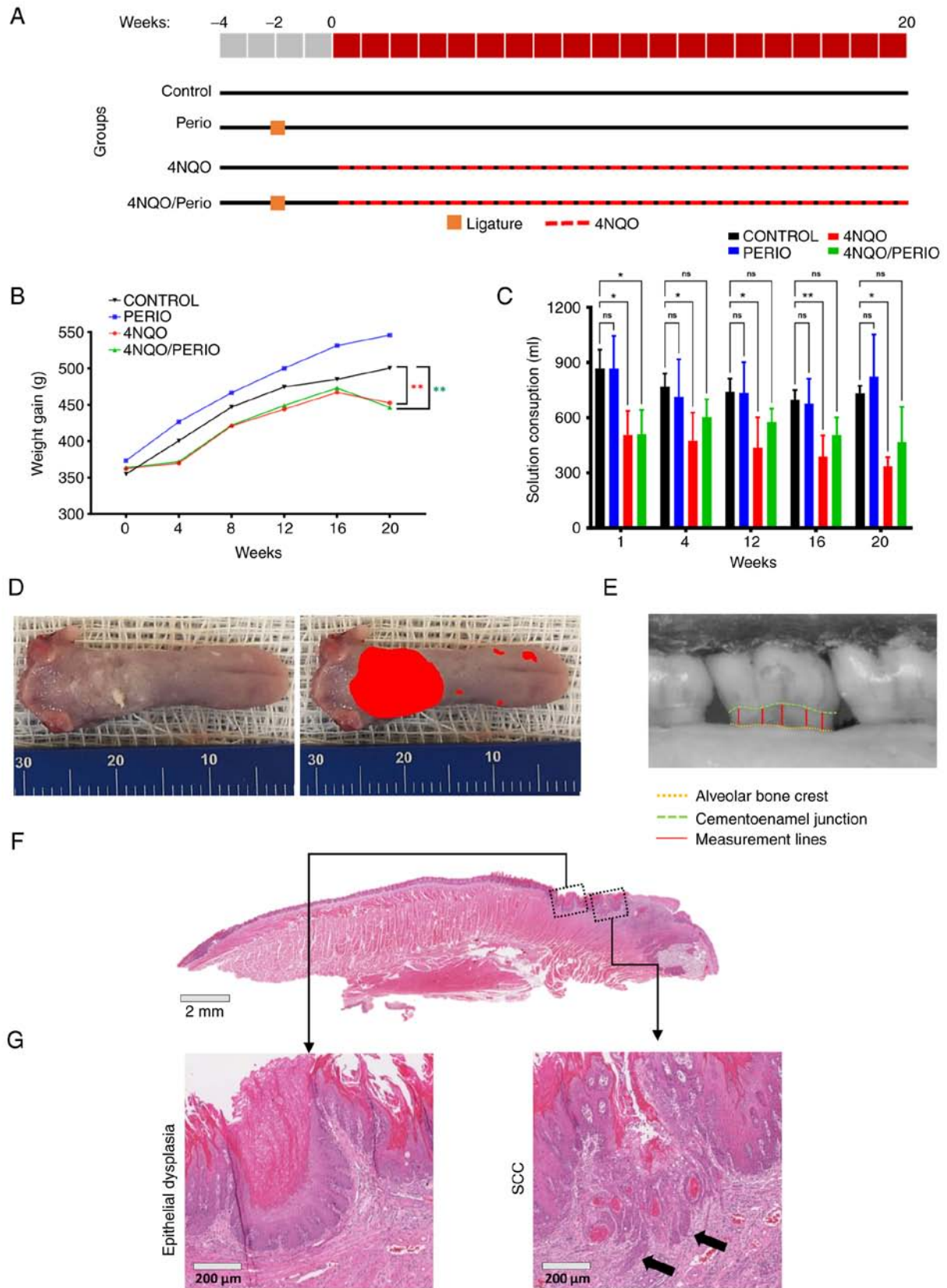


Figure 1. Study methodological aspects. (A) Study flowchart according to experimental groups. All groups were acclimated for 2 weeks. Periodontitis was induced by ligature in the Perio and 4NQO/Perio groups 2 weeks before 4NQO exposure. The 4NQO and 4NQO/Perio groups were exposed to 4NQO carcinogen in the drinking water for 20 weeks. (B) Weight of rats in experimental groups every 4 weeks during the 20 weeks of 4NQO exposure (** $P < 0.01$). (C) Solution consumption of rats in different groups every 4 weeks during the 20 weeks of 4NQO exposure. Data are presented as the mean \pm SEM (* $P < 0.05$ and ** $P < 0.01$). (D) Representative images of lesion size determination through software analysis of altered areas in the tongues of the rats (scale bar in millimeters). (E) Representative images of morphometric evaluation of bone loss. The distance between the cemento-enamel junction and the alveolar bone crest was computed at 5 points in the second upper molar. (F) Representative histological section from a tongue receiving 4NQO stained with hematoxylin and eosin. (G) Representative images of epithelial dysplasia and invasive carcinoma from tongue. Cases presenting basal membrane invasion (indicated by arrows) were considered carcinomas. Perio, periodontitis; 4NQO, 4-nitroquinoline 1-oxide; SCC, squamous cell carcinoma.

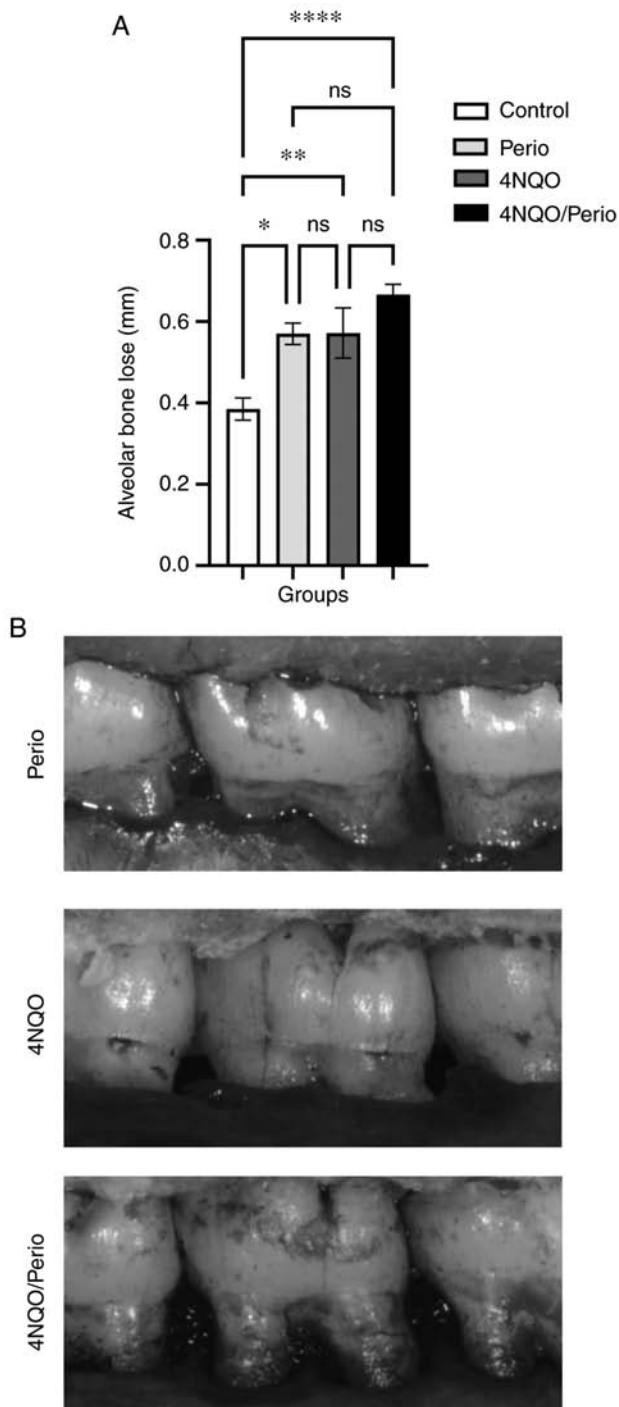


Figure 2. Morphometric alveolar bone loss evaluation. (A) Mean \pm SEM level of alveolar bone loss in the ligature-induced periodontitis sites in each experimental group (* $P < 0.05$, ** $P < 0.01$ and **** $P < 0.0001$). (B) Representative images of alveolar bone loss in the Perio, 4NQO, and 4NQO/Perio groups. The 4NQO/Perio group exhibited the largest distance between the cemento-enamel junction and the alveolar bone crest. Perio, periodontitis; 4NQO, 4-nitroquinoline 1-oxide.

expressed in the differentiation-committed spinous layer of the oral mucosa, while basal cells do not express CK10 (22). Immunofluorescence staining for CK10 was performed, and positive basal cells were quantified. All histological fields presenting with abnormal basal cells expressing CK10 were computed as positive. A total of 398 fields were assessed in which 25.3% (4NQO) and 11.5% (4NQO/Perio) of the

fields shown showed CK10 expression at the basal cells (Fig. 5A and B). These findings demonstrated increased abnormal activation of cellular differentiation of basal cells in 4NQO-treated animals compared with that in the 4NQO/Perio group.

Summary. Taken together, the present results suggest that periodontitis can influence the course of tumor development by reducing the differentiation of epithelial cells upon exposure to carcinogens. Differences in the rate of tumor transformation upon the presence of periodontitis were not conclusive in the present cohort of animals. Nonetheless, the development of periodontitis and exposure to 4NQO resulted in the increased size of oral lesions (Fig. 6).

Discussion

The role of periodontitis and its potential contributions as a risk factor/indicator in the development and/or progression of oral cancer by direct and indirect mechanisms have been the subject of interest and investigation in recent years (5,9). The majority of studies investigating the biological mechanisms of the association between periodontal disease and oral cancer mainly focus on *P. gingivalis*, a major etiological agent in the development of chronic periodontitis, yet not the only one (5,12,23-27). To the best of our knowledge, no previous study has evaluated the impact of the dental biofilm on oral carcinogenesis and tumor progression. The present study used a ligature-induced periodontitis animal model, as it shares similarities with the etiopathogenesis of periodontal biofilm accumulation following the alveolar bone loss observed in humans (28,29). This pioneering study indicated that biofilm-induced periodontitis statistically contributes to the development of larger lesions in 4NQO-induced oral carcinogenesis. Furthermore, periodontitis associated with 4NQO administration showed a tendency to develop more epithelial dysplasia and oral carcinomas than animals receiving 4NQO alone (Fig. 4A and B); however, this latest finding was not statistically significant.

In the present study, the body weight of all rodents was assessed as a proxy for their systemic health. All animals exhibited increased weight during the experiment compared with the baseline. Notably, the average weight of the Perio group increased week on week over the whole experiment; however, there was no difference compared with the Control group, which is in accordance with the results of other studies (18,19). Regarding the groups exposed to 4NQO, there was ~10% less weight gain from baseline to the final week compared with that in the control groups, with a particular slight drop in the final four weeks, which is also in line with the results of other studies (15,30-32). Significant differences were observed in the last weeks between the Perio group and the groups exposed to 4NQO. A parallel may be drawn regarding water consumption, with groups exposed to 4NQO showing significantly lower water intake at various time points over 20 weeks compared with the control groups. Those differences in body weight and solution consumption observed between control and 4NQO groups are likely to occur due to the unusual taste of the 4NQO diluted in the drinking water during the first weeks of induced carcinogenesis, as proposed in the literature (15).

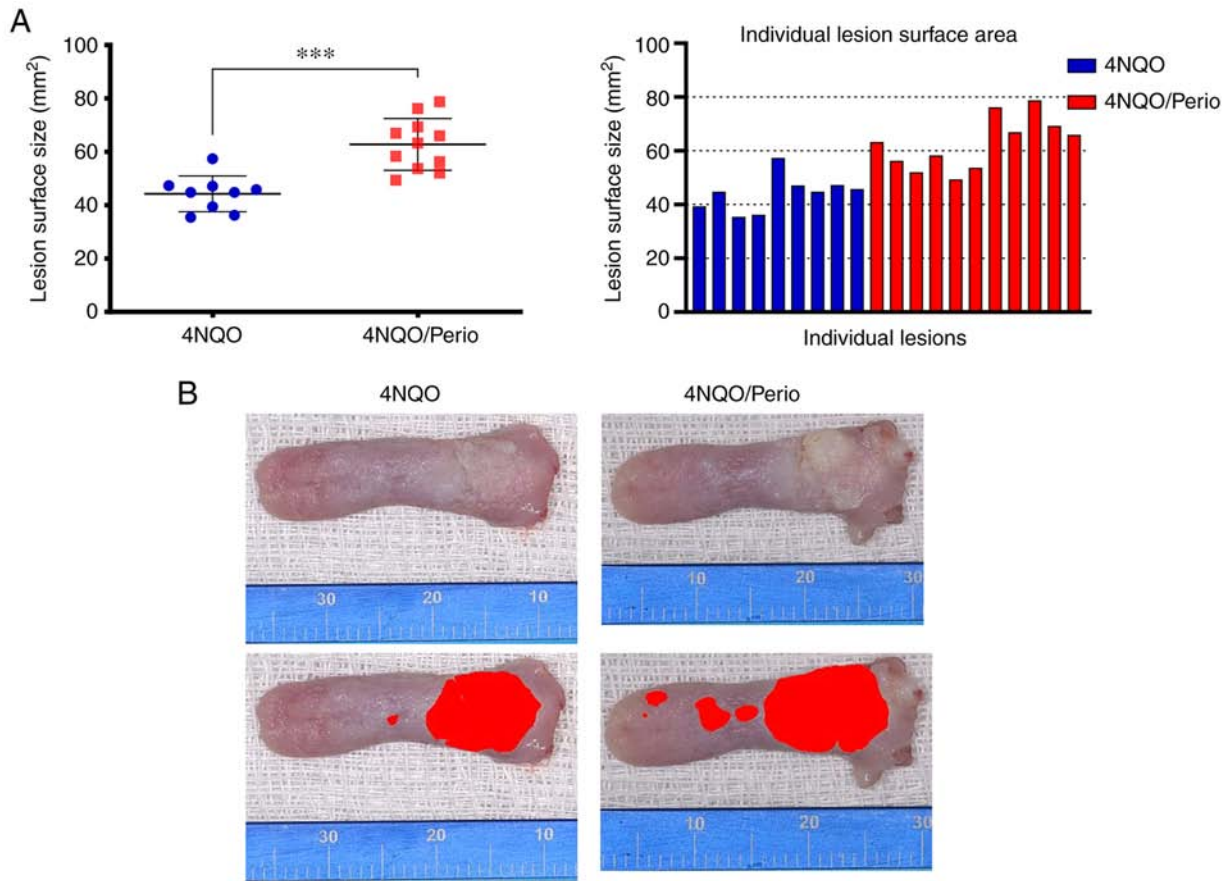


Figure 3. Analysis of lesion size in 4NQO-treated groups. (A) Mean \pm SEM level of lesion surface area in each experimental group ($^{***}P < 0.001$), and individual tumor surface area in the 4NQO and 4NQO/Perio groups. (B) Representative images of tongue lesions and digital quantification in the 4NQO and 4NQO/Perio groups. The 4NQO/Perio exhibited the largest area. Moreover, a more heterogeneous lesion was observed, with large exophytic and verrucous regions, while the 4NQO group showed a more flat and homogeneous lesion (scale bar in millimeters). Perio, periodontitis; 4NQO, 4-nitroquinoline 1-oxide.

The challenge of establishing periodontal etiopathogenesis mediated by ligatures and producing alveolar bone loss was successfully achieved (18,19). Exposure to 4NQO alone was sufficient to induce alveolar bone loss to similar levels as that found in the Perio and 4NQO/Perio groups. This result is in accordance with our previous study in which spontaneous alveolar bone loss was also observed in animals receiving 4NQO, and enhanced when OSCC was present (21). Changes in the oxidative stress balance are among the possible mechanisms to support this association (33). 4NQO is capable of inducing oxidative DNA damage (34). In parallel, reactive oxygen species are capable of triggering periodontal tissue damage (35,36). Further studies may be necessary to elucidate whether the effect of 4NQO in periodontal tissue is a local response associated with the direct exposure of the oral mucosa and periodontium to 4NQO-diluted water or if this is a systemic effect.

To investigate the direct associations between periodontitis and oral carcinogenesis without confounding factors, the present study used a well-defined rodent animal model for inducible periodontitis in conjunction with the 4NQO chemical carcinogenesis protocol (15,37,38). Administration of 4NQO results in the formation of DNA adducts resulting in DNA damage and TP53 mutation, along with other hallmarks of tobacco-driven oral carcinogenesis commonly observed in humans. In the present study, all animals exposed to 25 ppm 4NQO showed alterations in the epithelium of the tongue

during the 20-week treatment period. Periodontal disease was induced using ligatures kept in place for the entire experimental period mimicking the biofilm-induced periodontal disease found in humans (18,19). To the best of our knowledge, this is the first time that a ligature-induced periodontal disease animal model and a 4NQO-induced oral cancer model were implemented concomitantly to explore the potential correlation between periodontal disease and tumor progression.

We hypothesized that the presence of periodontitis would increase the incidence of oral cancer, as suggested in previous epidemiological and biological studies (5,9,13,39). The present study found a higher incidence of OSCC and dysplasia lesions in rats with periodontitis (4NQO/Perio) when compared with the 4NQO group. Although notable, statistical significance was not demonstrated in these findings. However, statistical significance was identified when comparing the tumor size of rats receiving ligatures and 4NQO (overall larger lesions) and rats receiving 4NQO alone. This finding is similar to the recent study that showed that chronically infected mice with *P. gingivalis*/*F. nucleatum* exposed to 4NQO in the drinking water presented with larger tumors and more lesions than animals without the pathogens (13,40). Also, it has been recently demonstrated that germ-free mice exposed to 4NQO and colonized with different oral microbiomes have an increased number and size of lesions compared with animals that receive 4NQO alone while remaining germ-free (41).

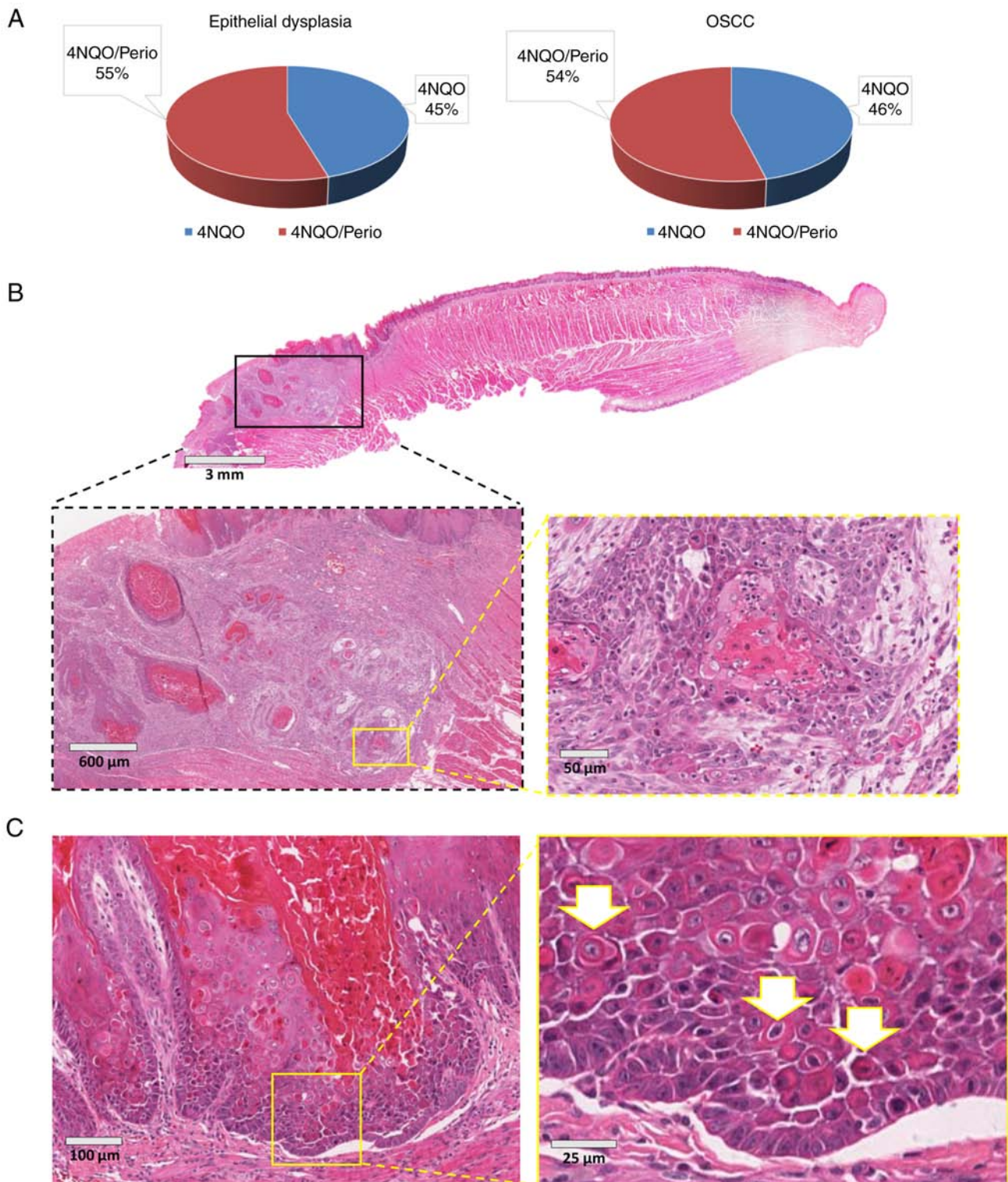


Figure 4. Histopathological analysis. (A) Percentage of cases diagnosed as epithelial dysplasia and carcinoma according in each experimental group. (B) Representative case showing microscopic findings in the 4NQO group. A carcinoma was present at the posterior portion of the tongue. Note the invasive characteristics of the dorsal carcinoma along local tissue destruction depicted by hematoxylin and eosin staining (inserts). (C) Representative example of 4NQO-treated rats depicting focal activation of cellular differentiation within the dorsal tongue mucosa. Epithelial cells exhibiting enhanced eosinophilic cytoplasm were present next to the basal layer of the mucosa (arrows). Perio, periodontitis; 4NQO, 4-nitroquinoline 1-oxide; OSCC, oral squamous cell carcinoma.

During the analysis of the animal data in the present study, it became evident that tumors from the 4NQO group presented as focal alterations on the spinous layer of the dorsal epithelium of the tongue. Such alterations resembled the

premature activation of cellular differentiation only observed on the uppermost layer of the mucosa, a phenomenon histologically described as dyskeratosis. The process of cellular differentiation is commonly found to be altered or lost during

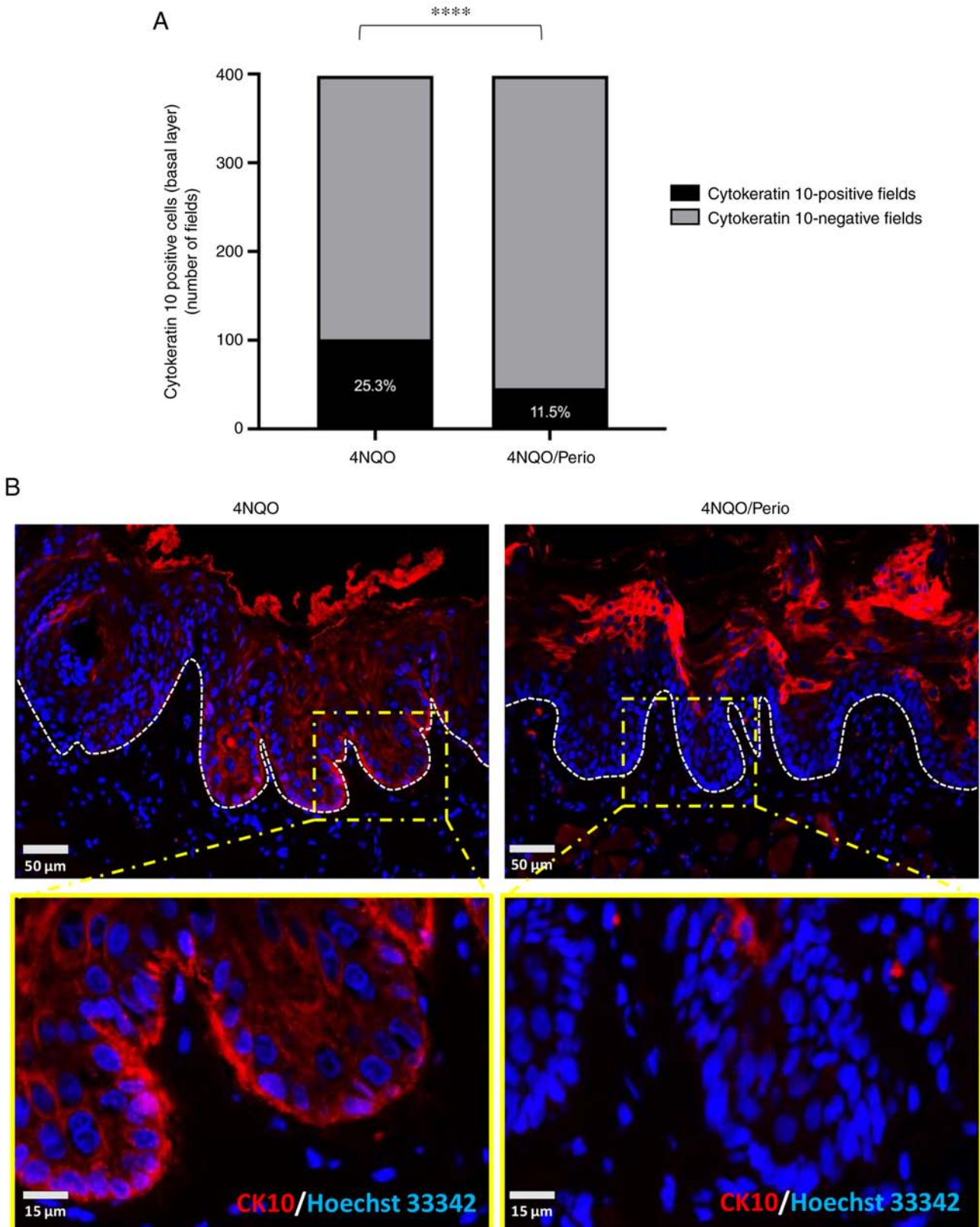


Figure 5. Cell differentiation analysis. (A) CK10 basal layer expression by fields in each experimental group ($****P < 0.0001$). (B) Representative images of CK10 immunostaining (red) merged with Hoechst 33342 (blue) in the 4NQO and 4NQO/Perio groups. The 4NQO group contains CK10-positive cells within the basal cells layer (white dotted line). By contrast, the 4NQO/Perio group lacks the expression of CK10 in the basal epithelial layers and just expresses CK10 on the upper layers of the epithelial layer of the mucosa. Perio, periodontitis; 4NQO, 4-nitroquinoline 1-oxide; CK10, cytokeratin 10.

carcinogenesis, potentially exerting an important role in tumor behavior. Mechanistically, activation of cellular differentiation involves the regulation of cell polarity. Emerging

findings show that several tumor suppressor genes are, in fact, controllers of cellular polarity, and loss of function of tumor suppressor genes directly impacts the maintenance of tissue

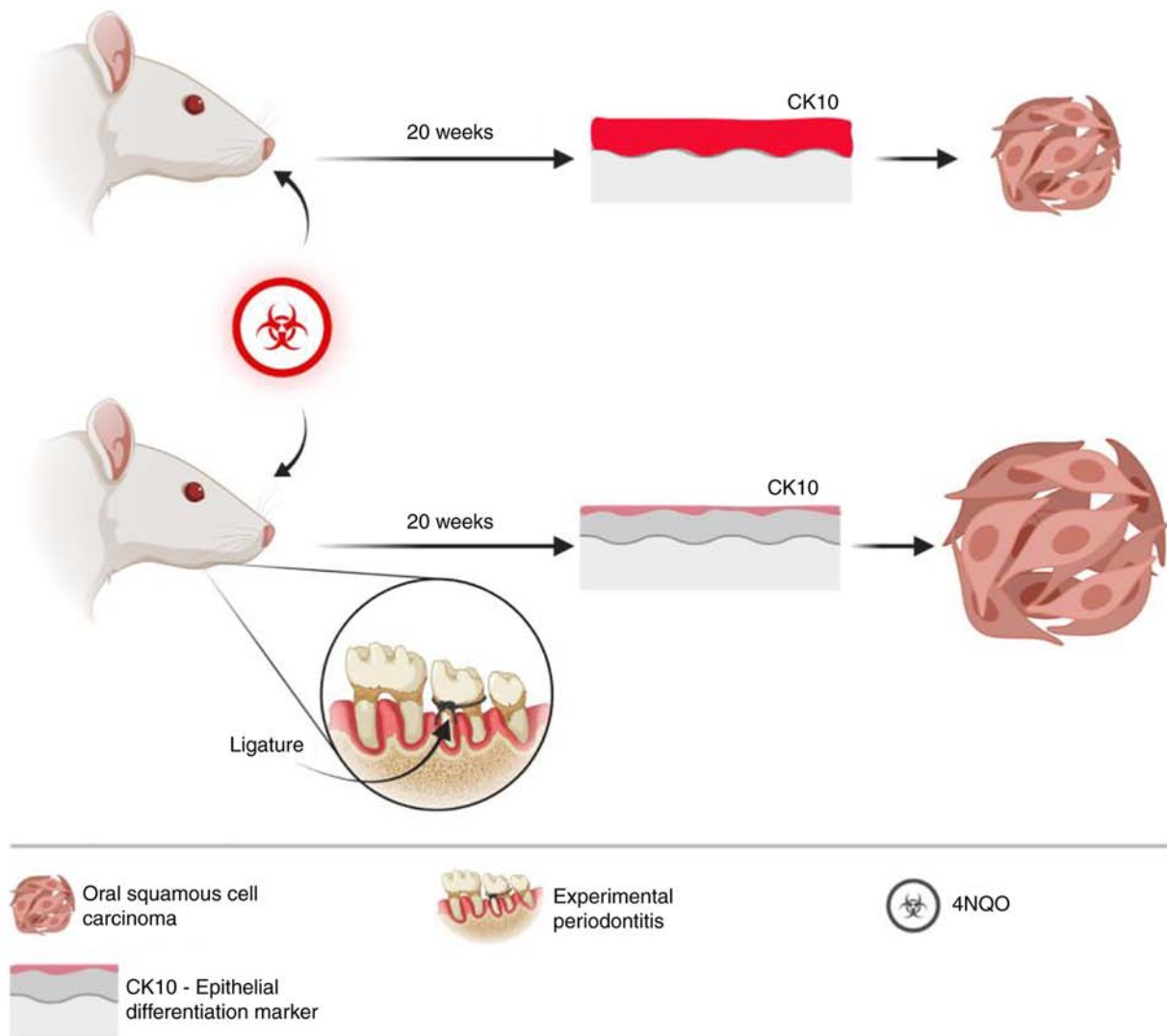


Figure 6. Diagram depicting increased cellular differentiation on the oral mucosa exposed to 4NQO and the presence of a smaller tumor area on the tongue of the rats. The presence of periodontal disease associated with the administration of 4NQO resulted in reduced cellular differentiation of the oral mucosa and the presence of larger tumor areas in the tongue of rats. Fig. 6 was created with BioRender.com. 4NQO, 4-nitroquinoline 1-oxide; CK10, cytokeratin 10.

homeostasis by disrupting symmetrical and asymmetrical cellular division (42,43). In order to investigate the effects of early carcinogenesis and the potential role of periodontitis in influencing tumor formation and progression, early changes in cellular differentiation on the dorsal mucosa of the tongue were investigated in the present study. Immunofluorescence analysis was performed for CK10, a major keratin and a marker of keratinocyte differentiation and keratinization commonly present on differentiating postmitotic keratinocytes (44,45). As this keratin is associated with epithelial differentiation, its expression is not expected in the proliferative basal cells of the mucosa. A recent study pointed out that the downregulation of CK10 expression in oral dysplastic areas can indicate malignant transformation (46). The present study found that rats receiving 4NQO presented with patches of basal epithelial cells with aberrant expression of CK10. CK10 was also expressed to a significantly higher level in basal cells from the 4NQO group (25.3% of fields) compared with that in the 4NQO/Perio (11.5% of fields). This result indicated that the presence of periodontitis reduces early activation of cellular differentiation, as

evidenced by the downregulation of CK10 in this group, therefore suggesting increased transformation potential. In fact, this result aligns with the observed increased size of lesions found in the 4NQO/Perio group compared with the group treated with 4NQO alone. Previous *in vitro* and *in vivo* studies suggested that CK10 may delay and decrease tumor formation, and that its presence in the basal layer inhibits cell proliferation and prevents skin tumorigenesis (47-50). Combined, these findings support the impact of biofilm-driven periodontitis as an associated risk factor for OSCC progression, as it reduces the activation of the terminal differentiation process upon exposure to carcinogens. Although noteworthy, the study fell short of being able to define the role of periodontitis in the carcinogenesis process and increased cancer incidence. Despite efforts to recapitulate the process of carcinogenesis in humans using the tobacco surrogate 4NQO, faster tumor development was observed in the rats, limiting the study to 20 weeks. The fast growth of tumors in rats contrasts with the lengthy accumulation of mutations and cellular transformation driven by tobacco consumption in humans. Such a fast and

aggressive carcinogenesis process may have masked differences in the tumor initiation process between the 4NQO and 4NQO/Perio groups. Another limitation of the present study is the quantification of the tumor volume. 4NQO-induced tumors are highly infiltrative and difficult to properly dissect. Following previously published 4NQO studies, in the present study, the tumor superficial extension was measured rather than attempting to calculate the tumor volume, in order to avoid the introduction of bias (20,51).

Nonetheless, even with the aforementioned limitations, a direct connection was established between the presence of periodontal disease with larger oral lesions and a dysfunctional cellular differentiation of surrounding mucosa. The clinical implications of these findings suggest careful follow-up is required for patients with periodontal disease who smoke. Although the influences of periodontitis on cellular transformation and cancer initiation remain unclear, the present data suggest that periodontitis plays a role in the progression of tumors. Nevertheless, future studies need to be performed to better understand chronic inflammatory diseases from the oral cavity and their role in oral cancer development and progression.

Acknowledgements

The authors would like to thank Ms. Flavia Rejane Giusti (Porto Alegre General Hospital, Port Alegre, Brazil) for providing technical support.

Funding

This study was funded by the Postgraduate Research Group of Clinics Hospital of Porto Alegre (grant nos. 15-0475 and 16-0541). This study was partially conducted during a visiting scholar period at the University of Michigan, sponsored by the Capes Foundation within the Ministry of Education, Brazil (grant no. BEX/88881.133691/2016-01). Cassiano Kuchenbecker Rösing is a research fellow funded by the Brazilian National Council for Scientific and Technological Development.

Availability of data and materials

The datasets used and/or analyzed during the current study are available from the corresponding author on reasonable request.

Authors' contributions

TRS, EJG, VPW and CKR contributed to the conception and design of the study. TRS, FN, VPW, EJG, CHS, VCC, CKR and RMC contributed to the data acquisition, analysis and interpretation. TRS, VPW, CHS, and RMC contributed to manuscript drafting. All authors contributed to the critical revisions of the intellectual content and have approved the final manuscript version to be published. All authors agree to be accountable for all aspects of the work so that any questions relating to research integrity or scientific accuracy in any part of the study are appropriately investigated and resolved. TRS, VPW, VCC and RMC confirm the authenticity of all the raw data.

Ethics approval and consent to participate

The study protocol was submitted to and approved by the Animal Use Ethics Committee, Porto Alegre General Hospital (Port Alegre, Brazil; approval no. 150475).

Patient consent for publication

Not applicable.

Competing interests

The authors declare that they have no competing interests.

References

1. Siegel R, Naishadham D and Jemal A: Cancer statistics, 2013. *CA Cancer J Clin* 63: 11-30, 2013.
2. Sahingur SE and Yeudall WA: Chemokine function in periodontal disease and oral cavity cancer. *Front Immunol* 6: 214, 2015.
3. Leemans CR, Braakhuis BJ and Brakenhoff RH: The molecular biology of head and neck cancer. *Nat Rev Cancer* 11: 9-22, 2011.
4. Warnakulasuriya S: Global epidemiology of oral and oropharyngeal cancer. *Oral Oncol* 45: 309-316, 2009.
5. Perera M, Al-Hebshi NN, Speicher DJ, Perera I and Johnson NW: Emerging role of bacteria in oral carcinogenesis: A review with special reference to perio-pathogenic bacteria. *J Oral Microbiol* 8: 32762, 2016.
6. Choclatewala N, Chaturvedi P and Desale R: The role of bacteria in oral cancer. *Indian J Med Paediatr Oncol* 31: 126-131, 2010.
7. Bravi F, Lee YA, Hashibe M, Boffetta P, Conway DI, Ferraroni M, La Vecchia C and Edefonti V; INHANCE Consortium investigators: Lessons learned from the INHANCE consortium: An overview of recent results on head and neck cancer. *Oral Dis* 27: 73-93, 2021.
8. Tezal M, Grossi SG and Genco RJ: Is periodontitis associated with oral neoplasms? *J Periodontol* 76: 406-410, 2005.
9. Gondivkar SM, Gondivkar RS, Gadgil AR, Chole R, Mankar M and Yuwanati M: Chronic periodontitis and the risk of head and neck squamous cell carcinoma: Facts and figures. *Exp Oncol* 35: 163-167, 2013.
10. Michaud DS, Lu J, Peacock-Villada AY, Barber JR, Joshu CE, Prizment AE, Beck JD, Offenbacher S and Platz EA: Periodontal disease assessed using clinical dental measurements and cancer risk in the ARIC study. *J Natl Cancer Inst* 110: 843-854, 2018.
11. Tonetti MS, Jepsen S, Jin L and Otomo-Corgel J: Impact of the global burden of periodontal diseases on health, nutrition and wellbeing of mankind: A call for global action. *J Clin Periodontol* 44: 456-462, 2017.
12. Nagy KN, Sonkodi I, Szöke I, Nagy E and Newman HN: The microflora associated with human oral carcinomas. *Oral Oncol* 34: 304-308, 1998.
13. Binder Gallimidi A, Fischman S, Revach B, Bulvik R, Maliutina A, Rubinstein AM, Nussbaum G and Elkin M: Periodontal pathogens *Porphyromonas gingivalis* and *Fusobacterium nucleatum* promote tumor progression in an oral-specific chemical carcinogenesis model. *Oncotarget* 6: 22613-22623, 2015.
14. Wu JS, Zheng M, Zhang M, Pang X, Li L, Wang SS, Yang X, Wu JB, Tang YJ, Tang YL and Liang XH: *Porphyromonas gingivalis* Promotes 4-nitroquinoline-1-oxide-induced oral carcinogenesis with an alteration of fatty acid metabolism. *Front Microbiol* 9: 2081, 2018.
15. Ribeiro DA and Salvadori DM: Gingival changes in wistar rats after oral treatment with 4-nitroquinoline 1-oxide. *Eur J Dent* 1: 152-157, 2007.
16. Ribeiro DA, Fracalossi AC, Uatari SA, Oshima CT and Salvadori DM: Imbalance of tumor suppression genes expression following rat tongue carcinogenesis induced by 4-nitroquinoline 1-oxide. *In Vivo* 23: 937-942, 2009.
17. Dayan D, Hirshberg A, Kaplan I, Rotem N and Bodner L: Experimental tongue cancer in desalivated rats. *Oral Oncol* 33: 105-109, 1997.

18. Cavagni J, de Macedo IC, Gaio EJ, Souza A, de Molon RS, Cirelli JA, Hoefel AL, Kucharski LC, Torres IL and Rösing CK: Obesity and hyperlipidemia modulate alveolar bone loss in Wistar rats. *J Periodontol* 87: e9-e17, 2016.
19. Verzeletti GN, Gaio EJ, Linhares DS and Rösing CK: Effect of obesity on alveolar bone loss in experimental periodontitis in Wistar rats. *J Appl Oral Sci* 20: 218-221, 2012.
20. Squarize CH, Castilho RM, Abrahao AC, Molinolo A, Lingen MW and Gutkind JS: PTEN deficiency contributes to the development and progression of head and neck cancer. *Neoplasia* 15: 461-471, 2013.
21. Oballe HJR, Muniz FWMG, Bueno CC, Klein IP, Carrard VC, Rösing CK and Gaio EJ: Spontaneous alveolar bone loss after 4NQO exposure in Wistar rats. *Arch Oral Biol* 89: 44-48, 2018.
22. Dale BA, Salonen J and Jones AH: New approaches and concepts in the study of differentiation of oral epithelia. *Crit Rev Oral Biol Med* 1: 167-190, 1990.
23. Atanasova KR and Yilmaz O: Looking in the Porphyromonas gingivalis cabinet of curiosities: The microbiome, the host and cancer association. *Mol Oral Microbiol* 29: 55-66, 2014.
24. Ahn J, Segers S and Hayes RB: Periodontal disease, Porphyromonas gingivalis serum antibody levels and orodigestive cancer mortality. *Carcinogenesis* 33: 1055-1058, 2012.
25. Katz J, Onate MD, Pauley KM, Bhattacharyya I and Cha S: Presence of Porphyromonas gingivalis in gingival squamous cell carcinoma. *Int J Oral Sci* 3: 209-215, 2011.
26. Groeger S, Domann E, Gonzales JR, Chakraborty T and Meyle J: B7-H1 and B7-DC receptors of oral squamous carcinoma cells are upregulated by Porphyromonas gingivalis. *Immunobiology* 216: 1302-1310, 2011.
27. Meyer MS, Joshipura K, Giovannucci E and Michaud DS: A review of the relationship between tooth loss, periodontal disease, and cancer. *Cancer Causes Control* 19: 895-907, 2008.
28. Graves DT, Fine D, Teng YT, Van Dyke TE and Hajishengallis G: The use of rodent models to investigate host-bacteria interactions related to periodontal diseases. *J Clin Periodontol* 35: 89-105, 2008.
29. Duarte PM, Tezolin KR, Figueiredo LC, Feres M and Bastos MF: Microbial profile of ligature-induced periodontitis in rats. *Arch Oral Biol* 55: 142-147, 2010.
30. Al-Koshab M, Alabsi AM, Mohd Bakri M, Ali-Saeed R and Selvi Naicker M: Antitumor activity of ficus deltoidea extract on oral cancer: An in vivo study. *J Oncol* 2020: 5490468, 2020.
31. Yanaida Y, Kohno H, Yoshida K, Hirose Y, Yamada Y, Mori H and Tanaka T: Dietary silymarin suppresses 4-nitroquinoline 1-oxide-induced tongue carcinogenesis in male F344 rats. *Carcinogenesis* 23: 787-794, 2002.
32. Al-Afifi N, Alabsi A, Kaid F, Bakri M and Ramanathan A: Prevention of oral carcinogenesis in rats by Dracaena cinnabari resin extracts. *Clin Oral Investig* 23: 2287-2301, 2019.
33. Araújo AA, Pereira ASBF, Medeiros CACX, Brito GAC, Leitão RFC, Araújo LS, Guedes PMM, Hiyari S, Pirih FQ and Araújo Júnior RF: Effects of metformin on inflammation, oxidative stress, and bone loss in a rat model of periodontitis. *PLoS One* 12: e0183506, 2017.
34. Miranda SR, Noguti J, Carvalho JG, Oshima CT and Ribeiro DA: Oxidative DNA damage is a preliminary step during rat tongue carcinogenesis induced by 4-nitroquinoline 1-oxide. *J Mol Histol* 42: 181-186, 2011.
35. Canakçi CF, Çiçek Y and Canakçi V: Reactive oxygen species and human inflammatory periodontal diseases. *Biochemistry (Mosc)* 70: 619-628, 2005.
36. Takane M, Sugano N, Iwasaki H, Iwano Y, Shimizu N and Ito K: New biomarker evidence of oxidative DNA damage in whole saliva from clinically healthy and periodontally diseased individuals. *J Periodontol* 73: 551-554, 2002.
37. Kanojia D and Vaidya MM: 4-nitroquinoline-1-oxide induced experimental oral carcinogenesis. *Oral Oncol* 42: 655-667, 2006.
38. El-Rouby DH: Histological and immunohistochemical evaluation of the chemopreventive role of lycopene in tongue carcinogenesis induced by 4-nitroquinoline-1-oxide. *Arch Oral Biol* 56: 664-671, 2011.
39. Yao QW, Zhou DS, Peng HJ, Ji P and Liu DS: Association of periodontal disease with oral cancer: A meta-analysis. *Tumour Biol* 35: 7073-7077, 2014.
40. Harrandah AM, Chukkappalli SS, Bhattacharyya I, Progulske-Fox A and Chan EKL: Fusobacteria modulate oral carcinogenesis and promote cancer progression. *J Oral Microbiol* 13: 1849493, 2020.
41. Stashenko P, Yost S, Choi Y, Danciu T, Chen T, Yoganathan S, Kressirer C, Ruiz-Tourrella M, Das B, Kokaras A and Frias-Lopez J: The oral mouse microbiome promotes tumorigenesis in oral squamous cell carcinoma. *mSystems* 4: e00323-19, 2019.
42. Royer C and Lu X: Epithelial cell polarity: A major gatekeeper against cancer? *Cell Death Differ* 18: 1470-1477, 2011.
43. Martin-Belmonte F and Perez-Moreno M: Epithelial cell polarity, stem cells and cancer. *Nat Rev Cancer* 12: 23-38, 2011.
44. Moll R, Divo M and Langbein L: The human keratins: Biology and pathology. *Histochem Cell Biol* 129: 705-733, 2008.
45. Paramio JM, Santos M and Jorcano JL: The ends of a conundrum? *J Cell Sci* 120: 1145-1148, 2007.
46. Garcia NG, Oliveira DT, Lauris JR, Domingues MA, Minicucci EM and Soares CT: Loss of cytokeratin 10 indicates malignant transformation in actinic cheilitis. *Clin Oral Investig* 20: 745-752, 2016.
47. Reichelt J, Furstenberger G and Magin TM: Loss of keratin 10 leads to mitogen-activated protein kinase (MAPK) activation, increased keratinocyte turnover, and decreased tumor formation in mice. *J Invest Dermatol* 123: 973-981, 2004.
48. Paramio JM, Casanova ML, Segrelles C, Mittnacht S, Lane EB and Jorcano JL: Modulation of cell proliferation by cytokeratins K10 and K16. *Mol Cell Biol* 19: 3086-3094, 1999.
49. Santos M, Paramio JM, Bravo A, Ramirez A and Jorcano JL: The expression of keratin k10 in the basal layer of the epidermis inhibits cell proliferation and prevents skin tumorigenesis. *J Biol Chem* 277: 19122-19130, 2002.
50. Santos M, Perez P, Segrelles C, Ruiz S, Jorcano JL and Paramio JM: Impaired NF-kappa B activation and increased production of tumor necrosis factor alpha in transgenic mice expressing keratin K10 in the basal layer of the epidermis. *J Biol Chem* 278: 13422-13430, 2003.
51. Czerninski R, Amornphimoltham P, Patel V, Molinolo AA and Gutkind JS: Targeting mammalian target of rapamycin by rapamycin prevents tumor progression in an oral-specific chemical carcinogenesis model. *Cancer Prev Res (Phila)* 2: 27-36, 2009.



This work is licensed under a Creative Commons Attribution-NonCommercial-NoDerivatives 4.0 International (CC BY-NC-ND 4.0) License.