



This is a repository copy of *Clinical image—postpartum clitoral epidermoid cyst*.

White Rose Research Online URL for this paper:

<https://eprints.whiterose.ac.uk/185850/>

Version: Published Version

Article:

Oluwaferanmi, E. and Jha, S. orcid.org/0000-0002-4519-6903 (2022) *Clinical image—postpartum clitoral epidermoid cyst*. *International Urogynecology Journal*, 33 (9). pp. 2589-2590. ISSN 0937-3462

<https://doi.org/10.1007/s00192-022-05177-7>

Reuse

This article is distributed under the terms of the Creative Commons Attribution (CC BY) licence. This licence allows you to distribute, remix, tweak, and build upon the work, even commercially, as long as you credit the authors for the original work. More information and the full terms of the licence here:

<https://creativecommons.org/licenses/>

Takedown

If you consider content in White Rose Research Online to be in breach of UK law, please notify us by emailing eprints@whiterose.ac.uk including the URL of the record and the reason for the withdrawal request.



eprints@whiterose.ac.uk
<https://eprints.whiterose.ac.uk/>



Clinical image—postpartum clitoral epidermoid cyst

Ebunoluwa Oluwaferanmi¹ · Swati Jha¹

Received: 27 January 2022 / Accepted: 24 March 2022
© The Author(s) 2022

Keywords Clitoral cyst · Epidermoid cyst · Postpartum · Excisional biopsy

Introduction

Clitoral epidermal cysts are benign lesions that can be excised surgically and carry good prognosis after treatment. They are usually slowly growing tumors that arise due to invagination of epidermis into dermis either spontaneously or following trauma. The differential diagnosis of clitoral cysts depends on the age of presentation. When these cysts present in children, they mimic clitoromegaly and can be confused with virilization due to hyperandrogenic states. Non-hormonal differential diagnosis includes neurofibromatosis (NF) and nevus lipomatous cutaneous superficialis.

We present images of a female who developed this cyst post-partum.

Case report

A 31-year-old woman presented to our team 18 months post-caesarean section after her first child, with a slowly but progressively enlarging clitoral lump first noticed about a month postpartum. The caesarean was uneventful and not associated with any trauma. She had not undergone any form of trauma

to the clitoral area such as female genital mutilation (FGM) previously.

Perineal examination was normal except for an 8 cm, soft and fluctuant, mildly tender clitoral swelling with no evidence of involvement or obstruction to the urethral and vaginal openings. Magnetic resonance imaging (MRI) pelvis (Figs. 1 and 2) confirmed an isolated clitoral cyst with no connection to the pelvis or surrounding organs. The cyst was excised under general anesthesia while avoiding the areas of innervation of the clitoris and surgical reconstruction done for cosmesis. The patient developed a secondary infection on the 2nd postoperative day, which was treated with antibiotics.

Histology showed a thin-walled, lobulated tense cyst containing beige creamy material, measuring 65 × 28 × 32 mm, confirmed to be epidermal cyst (Fig. 3). Postoperative outcome demonstrated a normal appearance of the clitoris.

Clitoral epidermal cysts are very rare with only a few cases reported in literature [1, 2] including one report described in a pregnant female [3]. Concerns with removal include the impact on sexual function and cosmesis, and patients should be forewarned of these risks.

✉ Swati Jha
swati.jha1@nhs.net

¹ Department of Urogynaecology, Sheffield Teaching Hospitals, Level 4 Jessop Wing, Tree Root Walk, Sheffield S10 2SF, UK

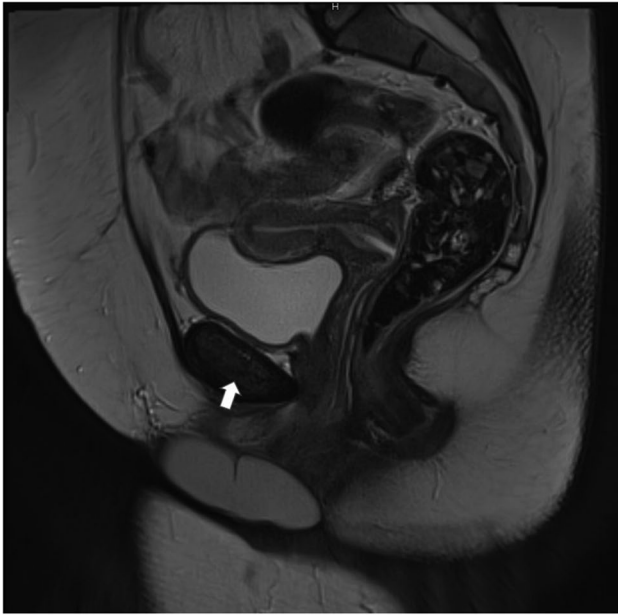

Fig. 1 MRI sagittal view of clitoral cyst

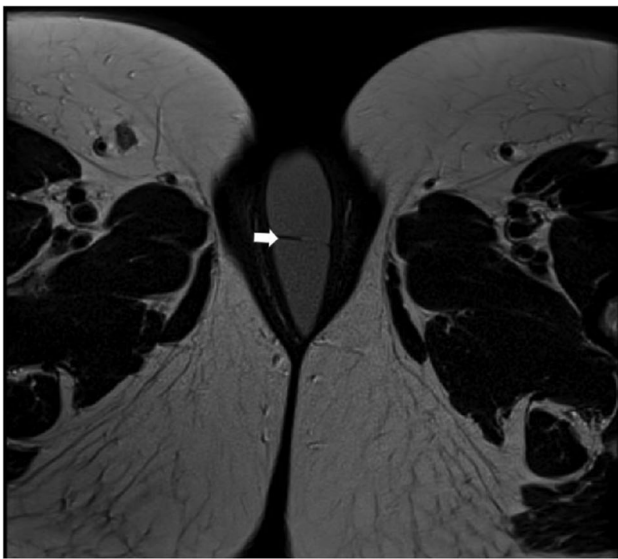


Fig. 2 MRI transverse view of clitoral cyst

Author contributions EO; SJ: wrote the manuscript
SJ: performed the surgery.

Declarations

Conflict of interest None.

Open Access This article is licensed under a Creative Commons Attribution 4.0 International License, which permits use, sharing, adaptation, distribution and reproduction in any medium or format, as long as you give appropriate credit to the original author(s) and the source, provide a link to the Creative Commons licence, and indicate if changes were made. The images or other third party material in this article are

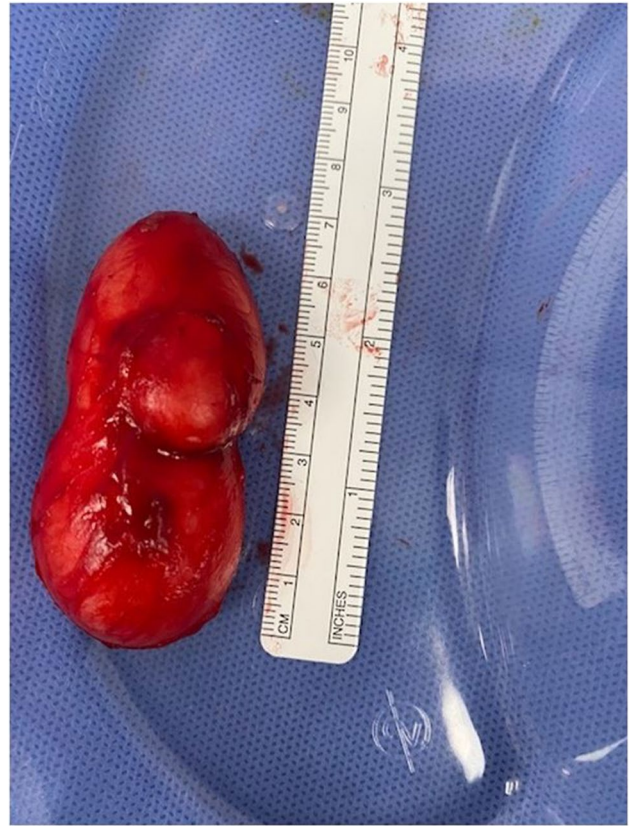

Fig. 3 Excised clitoral cyst sent for histology

included in the article's Creative Commons licence, unless indicated otherwise in a credit line to the material. If material is not included in the article's Creative Commons licence and your intended use is not permitted by statutory regulation or exceeds the permitted use, you will need to obtain permission directly from the copyright holder. To view a copy of this licence, visit <http://creativecommons.org/licenses/by/4.0/>.

References

1. Huda T, Suttrave T, Pandya B. Clitoral inclusion cyst in an adult: a rare presentation. *Int J Reproduction, Contraception, Obstet Gynecol.* 2019;8(8):3375.
2. Pehlivan M, Özbay PÖ, Temur M, Yılmaz Ö, Gümüş Z, Güzel A. Epidermal cyst in an unusual site: A case report. *Int J Surg Case Reports.* 2015;8:114–6.
3. Hughes JW, Guess MK, Hittelman A, Yip S, Astle J, Pal L, Inzucchi SE, Dulay AT. Clitoral epidermoid cyst presenting as pseudoclitoromegaly of pregnancy. *Am J Perinatol Reports.* 2013;3:057–62.

Consent Written informed consent was obtained from the patient for publication of this Images in Urogynaecology and any accompanying images.

Publisher's note Springer Nature remains neutral with regard to jurisdictional claims in published maps and institutional affiliations.