











OPEN ACCESS

## CLINICAL SCIENCE

# Dactylitis is an indicator of a more severe phenotype independently associated with greater SJC, CRP, ultrasound synovitis and erosive damage in DMARD-naive early psoriatic arthritis

Sayam Dubash <sup>1,2</sup> Oras A Alabas <sup>2,3</sup> Xabier Michelena <sup>2,4</sup>  
 Leticia Garcia-Montoya <sup>1,2</sup> Richard J Wakefield <sup>1,2</sup> Philip S Helliwell <sup>2</sup>  
 Paul Emery <sup>1,2</sup> Dennis G McGonagle <sup>1,2</sup> Ai Lyn Tan <sup>1,2</sup>  
 Helena Marzo-Ortega <sup>1,2</sup>

**Handling editor** Josef S Smolen

► Additional supplemental material is published online only. To view, please visit the journal online (<http://dx.doi.org/10.1136/annrheumdis-2021-220964>).

<sup>1</sup>NIHR Leeds Musculoskeletal Biomedical Research Centre, Leeds Teaching Hospitals NHS Trust, Leeds, UK

<sup>2</sup>Leeds Institute of Rheumatic and Musculoskeletal Medicine, University of Leeds, Leeds, UK

<sup>3</sup>Faculty of Biology, Medicine and Health, The University of Manchester, Manchester, UK

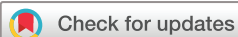<sup>4</sup>Rheumatology, Vall d'Hebron Hospital Universitari, Barcelona, Spain

**Correspondence to**

Dr Helena Marzo-Ortega, Rheumatology, 2nd Floor, NIHR Leeds Musculoskeletal Biomedical Research Centre, Leeds, LS7 4SA, UK; [h.marzo-ortega@leeds.ac.uk](mailto:h.marzo-ortega@leeds.ac.uk)

Received 14 June 2021

Accepted 14 October 2021



© Author(s) (or their employer(s)) 2021. Re-use permitted under CC BY-NC. No commercial re-use. See rights and permissions. Published by BMJ.

**To cite:** Dubash S, Alabas OA, Michelena X, et al. *Ann Rheum Dis* Epub ahead of print: [please include Day Month Year]. doi:10.1136/annrheumdis-2021-220964

**ABSTRACT**

**Objective** To characterise the impact of dactylitis in disease-modifying antirheumatic drug (DMARD)-naive early psoriatic arthritis (PsA).

**Methods** Patients with early PsA meeting the classification criteria for PsA (CASPAR) were recruited. Clinical outcomes were recorded, and ultrasonography was conducted to assess grey scale (GS) and power Doppler (PD) synovitis, periarticular cortical bone erosions and enthesitis. The cohort was dichotomised by the presence or absence of dactylitis.

**Results** Of 177 patients with PsA, those with dactylitis (dactylitic PsA (81/177, 46%)) had higher tender joint count ( $p<0.01$ ), swollen joint count (SJC) ( $p<0.001$ ) and C reactive protein (CRP) ( $p<0.01$ ) than non-dactylitic PsA. Dactylitis was more prevalent in toes (146/214 (68.2%)) than fingers (68/214 (31.8%)); 'hot' dactylitis was more prevalent than 'cold' (83.6% vs 16.4%). Ultrasound (US) synovitis and erosions were significantly more prevalent in dactylitic PsA ( $p<0.001$  and  $p<0.001$ , respectively). Exclusion of dactylitis in dactylitic PsA confirmed significantly greater SJC (3 vs 1,  $p=0.002$ ), US synovitis (GS  $\geq 2$ : 20.6% vs 16.1%,  $p<0.001$ , or PD  $\geq 1$ : 5.1% vs 3.3%,  $p<0.001$ ) and erosions (1.1% vs 0.5% joints,  $p=0.008$ ; 26.1% vs 12.8% patients,  $p=0.035$ ) than non-dactylitic PsA. Synovitis (GS  $\geq 2$  and/or PD  $\geq 1$ ) occurred in 53.7% of dactylitis. No substantial differences were observed for US enthesitis.

**Conclusion** Dactylitis signifies a more severe disease phenotype independently associated with an increased disease burden with greater SJC, CRP, US-detected synovitis and bone erosions in DMARD-naive early PsA and may be a useful discriminator for early risk stratification.

**INTRODUCTION**

Dactylitis is defined as diffuse swelling of a finger or toe and represents a specific lesion typically associated with psoriatic arthritis (PsA). The prevalence of dactylitis in PsA has been estimated at 33%–55%, with approximately 70% occurring at presentation.<sup>1</sup> Dactylitis is the epitome of PsA pathophysiology, encompassing multiple underlying pathologies including inflammation to joints (synovitis) and tendons/ligaments (enthesitis).

**Key messages****What is already known about this subject?**

- Dactylitis is a typical lesion in psoriatic arthritis (PsA) and is associated with radiographic progression in chronic disease.
- In early PsA, dactylitis is a common finding, but the associated impact of this lesion on the disease burden is unknown.

**What does this study add?**

- This study demonstrates that disease-modifying antirheumatic drug (DMARD)-naive patients with early PsA with dactylitis (dactylitic PsA) have a greater burden of disease than patients with PsA without dactylitis (non-dactylitic PsA), which was confirmed independently (ie, when dactylitis was excluded) demonstrating greater swollen joint count, C reactive protein, ultrasound (US) synovitis and US erosions.
- Our data confirm that dactylitis is a clinical marker of a more severe phenotype in DMARD-naive early PsA.

**How might this impact on clinical practice or future developments?**

- In patients with early PsA, the presence of dactylitis identifies a more severe disease phenotype and may be an important discriminator for risk stratification in early arthritis clinics and clinical research trials.

Flexor tenosynovitis, surrounding diffuse peritendinous inflammation and soft tissue oedema, are typically responsible for the 'sausage digit' appearance.<sup>2</sup> Importantly, synovitis and bone erosion can develop, adding to further structural and functional impairments.<sup>3</sup> Bone marrow oedema and ligamentous enthesitis have also been demonstrated using high-resolution MRI.<sup>4</sup> At the bedside, the accuracy of ultrasound (US) for detecting inflammatory arthritis in PsA is regarded as comparable to MRI, with studies suggesting US may be superior for the assessment of synovitis.<sup>5</sup>

The presence or history of dactylitis adds high sensitivity and specificity towards classifying PsA (CASPAR criteria).<sup>6</sup> Further, dactylitis is associated with greater radiographic damage in chronic established PsA.<sup>7</sup> However, to our knowledge, direct evaluation of the impact of dactylitis on overall disease phenotype and severity in early, untreated PsA has not been characterised. The objective of this study was to determine the impact of dactylitis on clinical phenotype, US synovitis and erosion in disease-modifying antirheumatic drug (DMARD)-naive early PsA.

## METHODS

### Patients, clinical details and examination

In total, 177 DMARD-naive patients with early PsA meeting CASPAR criteria were recruited into the Leeds Spondyloarthritis Register for Research and Observation for baseline cross-sectional analysis.<sup>6</sup> Clinical examination included tender joint count (TJC) (78) and swollen joint count (SJC) (76). The early PsA cohort was dichotomised by the presence or absence of dactylitis at baseline (PsA with dactylitis (dactylitic PsA) or PsA without dactylitis (non-dactylitic PsA)). Dactylitis was recorded per digit via the dichotomous (Clegg *et al*) method including tender ('hot') or non-tender ('cold') status.<sup>8,9</sup> Clinical enthesitis was measured by the Maastricht Ankylosing Spondylitis Enthesitis Score (MASES) to include peripheral and axial entheses.

### US examination

Experienced ultrasonographers blinded to clinical details (four operators with over 5 years' experience) scanned 50 joints per patient using the GE Logiq E9 machine with matrix linear (ML) 15–6 MHz or small-footprint linear array 18–8 MHz transducer and had regular training and calibration on the US examination protocol and quality of sonographic assessment throughout the study period, conducted every 6 months to maintain high consistency for US assessment, image interpretation and scoring.

### Synovitis

Synovitis was graded by semiquantitative scores (0–3) and defined as grey scale (GS)  $\geq 2$  or abnormal power Doppler (PD) signal (PD  $\geq 1$ ), and GS of  $\leq 1$  was determined as non-significant as it occurs frequently in healthy individuals.<sup>10</sup>

Wrists (radiocarpal, intercarpal and ulnar carpal recesses), metacarpophalangeal (MCP) joints 1–5, proximal interphalangeal (PIP) joints 1–5, distal interphalangeal joints 2–5, elbows, knees (suprapatellar, medial parapatellar and lateral parapatellar recesses), ankles (tibiotalar joint), subtalar joints, talonavicular joints and metatarsophalangeal (MTP) joints 1–5 were scanned in longitudinal and transverse planes (online supplemental table S1A).

### Erosions

Erosions were determined by periarticular cortical bone discontinuity present in two perpendicular planes (longitudinal and transverse), with MTP1 excluded as it is a frequent site of osteoarthritis.

### Enthesitis

Enthesitis was determined by the Outcome MEasures in Rheumatology (OMERACT)-defined elementary lesions and modified Glasgow Ultrasound Enthesitis Severity Score (GUESS), calculated per patient based on all the enthesitis sites and domains (except bursitis at the quadriceps tendon insertion—not

recorded in the study protocol).<sup>11,12</sup> The US data recorded for entheses are shown in online supplemental table S1 (B).

## Statistical analysis

Statistical tests were two-tailed, statistical significance prespecified at 5% ( $p < 0.05$ ) with 95% CIs. Differences between mean, medians and proportions were calculated using Student's t-test, quantile regression (continuous variables),  $\chi^2$  test (binary variables) and Kruskal-Wallis (categorical variables) via Stata V.16.1.

## RESULTS

### Clinical characteristics

#### Dactylitic PsA versus non-dactylitic PsA

Dactylitic PsA occurred in 81/177 (46%) patients vs non-dactylitic PsA in 96/177 (54%) patients. Mean ages were similar; 43.7 and 44.4 years, respectively. More patients in the dactylitic group had a symptom duration of  $< 24$  months (68/81 (84%) vs 64/96 (66.7%),  $p = 0.008$ ). The median TJCs and SJC were significantly greater in patients with dactylitic PsA compared with patients without dactylitic PsA (TJC: 9 vs 4,  $p < 0.01$ ; SJC 7 vs 1,  $p < 0.001$ ), with polyarthritis being the predominant phenotype in dactylitic PsA (65.4%,  $p < 0.01$ ), while oligoarthritis was dominant in non-dactylitic PsA (86.5%,  $p < 0.001$ ). Excluding dactylitis affected digits, dactylitic PsA remained predominantly polyarticular (51/81 patients, 62.9%), and the SJC (but not the TJC) still significantly greater (total SJC: 326 joints (81 patients) vs 209 joints (96 patients), median 3 vs 1,  $p = 0.002$ ).

Clinical enthesitis was more prevalent in patients with dactylitic PsA (42/81 (51.9%) vs 34/96 (35.4%);  $p = 0.027$ ), with greater median MASES (1.0 (0.0–2.0) vs 0.0 (0.0–2.0);  $p < 0.01$ ). The prevalence of nail dystrophy did not differ between groups, however the median modified nail psoriasis severity index (mNAPSI) was greater in non-dactylitic PsA (2.0 (0.0–7.5) vs 0.0 (0.0–8.0);  $p < 0.05$ ).

Elevated C reactive protein (CRP  $> 10$  mg/L) occurred more frequently in dactylitic versus non-dactylitic patients (44% vs 25% ( $p = 0.006$ )) including with a greater median CRP and erythrocyte sedimentation rate (ESR; mm/hr) (CRP: 8.1 vs 5.0 ( $p < 0.01$ ), ESR: 16.5 vs 11 ( $p < 0.05$ )). Disease Activity in Psoriatic Arthritis (DAPSA) scores were greater in dactylitic PsA but not significant (median 24.4 vs 20.8,  $p = 0.07$ ). No significant differences were observed in PsAQoL, HAQ, and DLQI. Comparison of patient characteristics between groups are shown in table 1.

### Characteristics of dactylitis

Of 81/177 (45.8%) patients with dactylitic PsA, dactylitis affected 214 digits, predominantly with multiple digit involvement ( $> 1$ ) in 51/81 (63%) patients (median digits: 2 (IQR 1–3)) and was distributed asymmetrically (52/81 (64%) patients). Hands were affected in 23/81 (28.4%) patients, feet in 40/81 (49.4%), and both in 18/81 (22.2%). Dactylitis was more prevalent in toes (146/214, 68.2%) than fingers (68/214, 31.8%) with the majority of digits classified as hot dactylitis (179/214 digits, 83.6%) (cold dactylitis (35/214, 16.4%)). The second finger (23/179, 12.8%) and fourth toe (40/179; 22.3%) were most frequently affected by hot dactylitis, and the third finger (2/35; 5.7%) and fourth toe (10/35; 28.6%) by cold dactylitis (online supplemental figure S1A).

### US synovitis

In total, 155/177 (87.5%) patients with PsA underwent ultrasonography (6143 joints): 69/155 (44.5%) patients with dactylitic PsA and 86/155 (55.5%) without dactylitic PsA

**Table 1** Characteristics of the early PsA cohort dichotomised by the presence or absence of dactylitis

Characteristics and outcomes	Non-dactylitic PsA (96/177 (54.2%))	Dactylitic PsA (81/177 (45.8%))	Difference/p value
<b>Clinical</b>			
Age (years), mean (SD)	44.4 (12.8)	43.7 (13.3)	0.7 (−3.2 to 4.5)
Male	38 (39.6%)	42 (51.9%)	p=0.10
Symptom duration (months), median (IQR)	18.0 (10.5–36.0)	12.0 (6.0–24.0)	−6.0 (−13.1 to 1.1)
Duration from diagnosis (months), median (IQR)	1.1 (0–2.7)	1.2 (0.3–4.6)	0.03 (−0.9 to 1.0)
Symptoms <24 months, patients (%)	64/96 (66.7)	68/81 (84.0)	p=0.008
Early morning stiffness (min), median (IQR)	50.0 (15.0–90.0)	60.0 (15.0–180.0)	0 (−24.1 to 24.1)
TJC (78), median (IQR)	4.0 (1.0–10)	9.0 (5.0–19.0)	5.0 (2.0 to 8.0)**
SJC (76), median (IQR)	1.0 (0.0–3.0)	7.0 (4.0–13.0)	6.0 (4.3 to 7.6)***
TJC (78) median (IQR) (excluding dactylitis)	4.0 (1.0–10.0)	5.0 (2.0–11.0)	1.0 (−1.4 to 3.4)
SJC (76) median (IQR) (excluding dactylitis)	1.0 (0.0–3.0)	3.0 (1.0–6.0)	2.0 (0.8 to 3.3)**
Current psoriasis	96/96 (100.0%)	74/81 (91.4%)	p=0.003**
Family history of psoriasis	52/94 (55.3%)	49/78 (62.8%)	p=0.32
PASI, median (IQR)	2.9 (0.8–4.9)	1.9 (0.4–4.2)	−1.2 (−2.4 to 0.0)
Psoriatic nail dystrophy	49/96 (51.0%)	44/81 (54.3%)	p=0.66
mNAPSI, median (IQR)	2.0 (0.0–7.5)	0.0 (0.0–8.0)	−2.0 (−3.7 to −27.9)*
Clinical Enthesitis	34/96 (35.4%)	42/81 (51.9%)	p=0.027*
MASES score, median (IQR)	0.0 (0.0–2.0)	1.0 (0.0–2.0)	1.0 (0.4 to 1.6)**
BMI, median (IQR)	28.2 (24.0–32.1)	28.6 (25.0–31.5)	0.3 (−1.7 to 2.4)
Smoking (current)	19 (19.8%)	9 (11.1%)	p=0.11
<b>Disease phenotype</b>			
Oligoarthritis (defined by SJC <5)	83/96 (86.5%)	28/81 (34.6%)	p<0.001***
Oligoarthritis (defined by TJC and/or SJC <5)	48/96 (50%)	29/81 (35.8%)	p=0.058
DIP joint disease	7/93 (7.5%)	13/77 (16.9%)	p=0.058
Axial disease	17/94 (18.1%)	9/78 (11.5%)	p=0.23
Arthritis mutilans	0	0	0
<b>Laboratory markers</b>			
CRP (mg/L), median (IQR)	5.0 (5.0–9.3)	8.1 (5.0–18.4)	3.1 (0.9–5.3)**
Elevated CRP (>10 mg/L)	24/96 (25.0%)	36/81 (44.4%)	p=0.006**
ESR, median (IQR)	11.0 (5.0–25.0)	16.5 (7.0–27.0)	7.0 (0.4–13.6)*
<b>Composite outcomes</b>			
DAPSA score, median (IQR)	20.8 (12.6, 30.5)	24.4 (14.9, 36.5)	p=0.07
<b>Patient-reported outcomes (PROs)</b>			
PsAQoL, median (IQR)	6.0 (0.0–13.0)	6.0 (2.0–12.0)	0.0 (−4.1 to 4.1)
DLQI, median (IQR)	3.0 (1.0–9.0)	2.0 (1.0–6.0)	−1.0 (−3.3 to 1.3)
HAQ, median (IQR)	0.75 (0.25–1.50)	0.75 (0.38–1.38)	0.125 (−0.23 to 0.48)

\*p&lt;0.05, \*\*p&lt;0.01, \*\*\*p&lt;0.001.

BMI, body mass index; CRP, C reactive protein; DAPSA, Disease Activity in Psoriatic Arthritis; DIP, distal interphalangeal; DLQI, Dermatology Quality of Life Index; ESR, erythrocyte sedimentation rate; HAQ, Health Assessment Questionnaire Disability Index; MASES, Maastricht Ankylosing Spondylitis Enthesitis Score; mNAPSI, Modified Nail Psoriasis Severity Index; PASI, Psoriasis Area Severity Index; ; PsA, psoriatic arthritis; PsAQoL, PsA quality of life; SJC, swollen joint count; TJC, tender joint count.

(online supplemental figure S1B). US synovitis was significantly more prevalent in dactylitic PsA (GS  $\geq 2$ : 23.6% vs 16.1% joints (p<0.001); PD  $\geq 1$ : 7.3% vs 3.3% joints (p<0.001); GS  $\geq 2$ +PD  $\geq 1$ : 6.3% vs 2.6% joints (p<0.001)) as outlined in table 2A. GS  $\geq 2$  synovitis was most frequently observed at MCP 2–5, PIP1–3, MTP2–5, and PD  $\geq 1$  synovitis at MCP 2 and MTP 4–5. On exclusion of digits affected by dactylitis, US synovitis remained significantly more prevalent in patients with dactylitic PsA (GS  $\geq 2$ : 21.3% vs 16.1% joints (p<0.001); PD  $\geq 1$ : 5% vs 3.3% joints (p<0.001); GS  $\geq 2$ +PD  $\geq 1$ : 4.1% vs 2.6% joints (p<0.003); table 2B). Further subgroup analyses stratified for phenotype (defined by SJC  $\geq 5$  as polyarticular) confirmed greater GS  $\geq 2$  and PD  $\geq 1$  synovitis, respectively, for polyarticular subsets in dactylitic PsA (p<0.001), including greater GS  $\geq 2$  synovitis when dactylitis was excluded (p=0.01) (online supplemental table S2). Application of the second definition inclusive of tender joints (tender and/or swollen joints<5 as oligoarticular

indicated significantly greater GS of  $\geq 2$  and PD of  $\geq 1$  synovitis, respectively, independent of phenotype in dactylitic PsA. Exclusion of dactylitis from dactylitic PsA also confirmed greater GS of  $\geq 2$  synovitis in oligoarticular and polyarticular subsets independent of dactylitis affected joints (online supplemental table S3).

### US erosions

Periarticular cortical bone erosions were identified in a significantly greater proportion of patients with dactylitic PsA, compared with those without dactylitis (20/69 (29.0%) vs 11/86 (12.8%), p=0.012). There was also a significant difference in the total number of erosions detected in dactylitic versus patients without dactylitic PsA (33/2557 joints vs 15/3206 joints, p<0.001; table 2A). The anatomical sites for joints most prone to erosive damage were MCP2 (9/33 (27.3%)) and MTP5 (11/33 (33.3%)).



**Table 2** Ultrasound synovitis and bone erosions in non-dactylitic versus dactylitic PsA: (A) including dactylitis affected digits and (B) excluding dactylitis affected digits

(A) US synovitis and erosions	Non-dactylitic PsA (86/155 (55.5%) patients)	Dactylitic PsA (69/155 (44.5%) patients)	Difference
Total GS $\geq 2$ (joints)	551/3422 (16.1%)	642/2721 (23.6%)	p<0.001
Total PD $\geq 1$ (joints)	114/3422 (3.3%)	198/2721 (7.3%)	p<0.001
Total GS $\geq 2$ +PD $>1$ (joints)	89/3422 (2.6%)	171/2721 (6.3%)	p<0.001
Total US erosions (joints)	15/3206 (0.5%)	33/2557 (1.3%)	p<0.001
Total erosion score (patient level)	Mean 0.28 (SD 0.87), median 0 (0–0)	Mean 0.72 (SD 1.63), median 0 (0–1)	p=0.016
Total US erosive patients	11/86 (12.8%)	20/69 (29.0%)	p=0.012
(B) US synovitis and erosions	Non-dactylitic PsA (86/155 (55.5%)) (same as A)	Dactylitic PsA (69/155 (44.5%)) (dactylitis excluded)	Difference
Total GS $\geq 2$ (joints)	551/3422 (16.1%)	507/2466 (20.6%)	p<0.001
Total PD $\geq 1$ (joints)	114/3422 (3.3%)	126/2466 (5.1%)	p<0.001
Total GS $\geq 2$ +PD $>1$ (joints)	89/3422 (2.6%)	101/2466 (4.1%)	p=0.003
Total US erosions (joints)	15/3206 (0.5%)	24/2315 (1.1%)	p=0.008
Total erosion score (patient level)	Mean 0.28 (SD 0.87), median 0 (0–0)	Mean 0.58 (SD 1.52), median 0 (0–1)	p=0.048
Total US erosive patients	11/86 (12.8%)	18/69 (26.1%)	p=0.035

GS, grey scale; PD, power Doppler; PsA, psoriatic arthritis.

On exclusion of dactylitic digits, US erosions were more frequent in dactylitic PsA than non-dactylitic PsA (24/2315 (1.1%) vs 15/3206 (0.5%) joints, p=0.008). The proportion of patients with US erosions (US erosion-positive patients) was greater for dactylitic PsA (18/69 (26.1%) vs 11/86 (12.8%) patients, p=0.035). Total erosion scores at the patient level were also higher in dactylitic PsA (p=0.016), including when dactylitis was excluded (p=0.048), as shown in [table 2B](#). Subgroup analyses confirmed greater total US-detected erosions in polyarticular stratified subsets regardless of the phenotype definition applied and on excluding dactylitis affected joints (online supplemental table S2 and S3). The US appearances of erosions detected in the dactylitic PsA group are illustrated in [figure 1B,D](#).

### US in dactylitis

In digits affected by dactylitis, US synovitis (GS  $\geq 2$ ) was prevalent in 137/255 (53.7%) joints. A higher prevalence of US synovitis was observed in joints affected by hot dactylitis versus those with the cold type (129/227 (56.8%) vs 8/28 (28.6%) joints, p=0.0047). US PD synovitis (PD  $\geq 1$  regardless of GS grade) was present in 72/255 (28.2%) of the total joints clinically affected by dactylitis and was more prevalent in hot type (hot: 69/227 (30.4%) and cold: 3/28 (10.7%) joints, p=0.0289). In hot dactylitis, erosions occurred in 9/227 (2.6%) of affected joints (4/69 (6%) patients) and none in cold dactylitis (0/28) (p=0.388). [Figure 1](#) illustrates synovitis at MTP5 ([figure 1A](#)) and shows soft tissue oedema and flexor tenosynovitis ([figure 1E](#)).

### US enthesitis

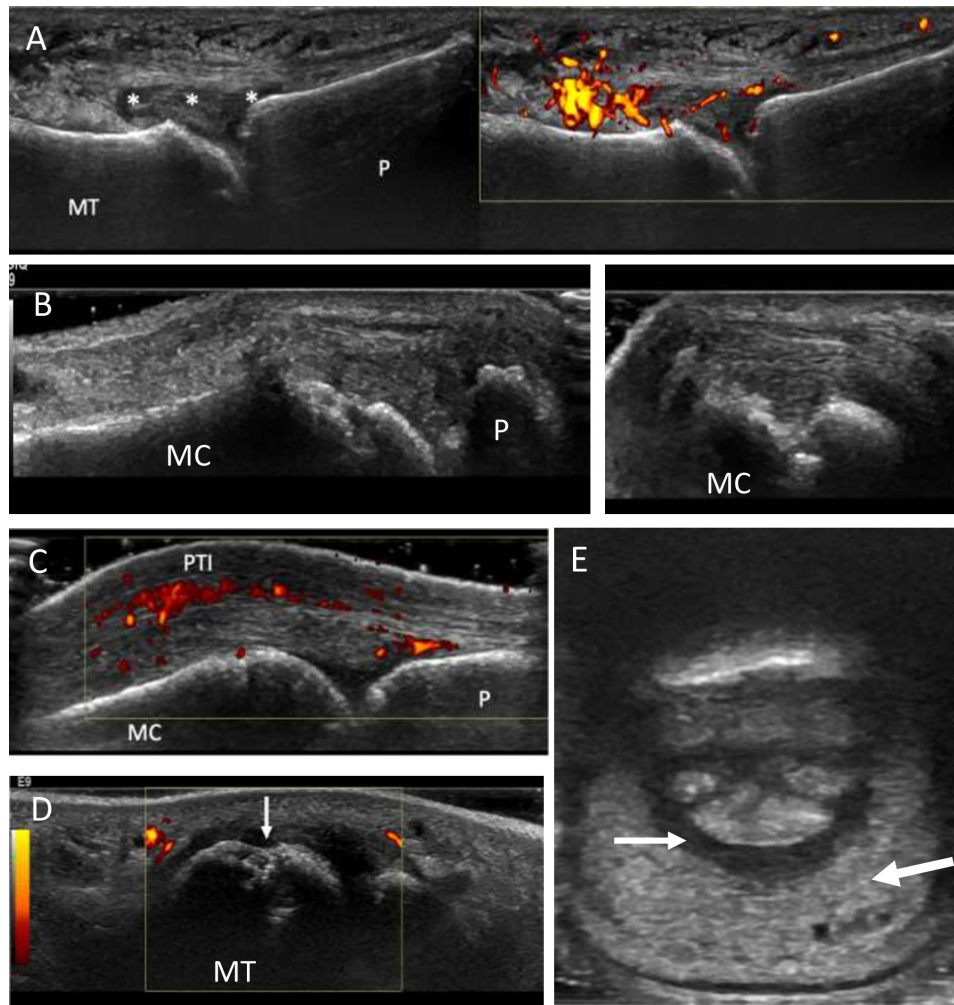
Of 1534 entheses examined by US, modified GUESS scores indicated no significant differences between patients with dactylitic PsA and patients without dactylitic PsA (median 3 (IQR 2–6) vs median 4 (IQR 1–6), p=0.91). There were no relevant differences between groups on analysis of OMERACT elementary lesions.

### DISCUSSION

This is the first study, to our knowledge, to evaluate the overall clinical and US disease burden in a DMARD-naive early PsA cohort based on the presence/absence of dactylitis. These study results confirmed a greater burden of disease in PsA with

dactylitis. Moreover, patients with dactylitic PsA had greater SJC, CRP, prevalence of US synovitis and erosive damage independently (ie, on exclusion of digits affected by dactylitis) compared with non-dactylitic PsA. These results therefore provide an insight into the significance of dactylitis in early PsA, demonstrating that it is an indicator of a more severe phenotype. Indeed, more aggressive disease accounted for an earlier diagnosis of patients with dactylitic PsA who presented with shorter disease duration. Further analyses to include history of dactylitis and exclude patients with a symptom duration of  $>24$  months, respectively, did not change results confirming the increased burden of disease in the dactylitic group (online supplemental table S4 and S5).

Previous studies in established PsA have shown that digits affected by dactylitis are associated with significant pathological findings. Brockbank *et al* first reported that radiographic damage occurred frequently in hot dactylitis with an average PsA cohort disease duration of 8 years.<sup>7</sup> Healy *et al* reported a high prevalence of synovitis in hot dactylitis present on MRI in 69%, closely matching the prevalence of US detected synovitis in our study (56.8%), confirming that synovitis is present in the majority of dactylitis in early PsA.<sup>13</sup> Moreover, in our early PsA study, the greater prevalence of US synovitis and erosions in patients with dactylitic PsA (vs non-dactylitic PsA), even when excluding the dactylitis digits, has to our knowledge not previously been shown and reflects an increased burden of disease. Further, this was reflected by CRP, also a marker of disease activity which was elevated ( $>10$  mg/L) more often in patients with dactylitic PsA (44.4% vs 25%, p=0.006) and with higher median values. This is a relevant observation, since elevated baseline CRP is associated with poor radiographic outcomes.<sup>14</sup> Additionally, radiographic joint destruction is reportedly predicted by the development of dactylitis in men from longitudinal PsA cohort data.<sup>15</sup> Despite the differences found for clinical enthesitis, a possible limitation of our study was the inability to show meaningful differences in US enthesopathy possibly related to the outcomes used or the known clinical and US mismatch shown in other studies.<sup>16</sup> However, our results do provide new data, including for US synovitis and erosion, showing that there is a difference in the burden of disease between patients with early PsA with and without dactylitis.



**Figure 1** Characteristic ultrasound pathologies in early dactylitic patients with PsA. (A) Longitudinal view through the fifth metatarsophalangeal joint illustrating synovitis within a dactylitic toe. There is grey scale synovitis (grade 3) with effusion (\*) and abnormal power Doppler signal (grade 2, right image) consistent with 'active' synovitis. (B) Periarticular cortical bone irregularity at the second MCP joint confirmed in the longitudinal (left) and transverse planes, respectively (right), confirming erosion. A common site of erosion in PsA and in dactylitis. (C) Longitudinal view at the MCP joint displaying power Doppler signal above the extensor tendon (PTI). (D) Image in the transverse plane showing the fifth metatarsal head, the most frequent site of erosion in feet, demonstrating periarticular bone irregularity (arrow). Bone irregularity was confirmed further in the longitudinal plane to signify erosion. There is also surrounding grey scale synovial hypertrophy (grade 2). (E) Transverse view of volar aspect of dactylitic third toe showing diffuse soft tissue oedema (large arrow) and flexor tenosynovitis (small arrow). MCP, metacarpophalangeal; MC, metacarpal head; MT, metatarsal head; P, phalanx; PsA, psoriatic arthritis; PTI, peritendon inflammation.

Tailoring therapy specific to PsA phenotypes is increasingly pertinent to avoid biologic disease-modifying antirheumatic drug (bDMARD) failure, especially given the diverse mode of action therapies available. Moreover, superior treatment responses have been shown for dactylitis with bDMARDs over conventional synthetic DMARDs, including first-line combination therapy.<sup>17 18</sup> Our study findings can facilitate early risk stratification to optimise treatment outcomes, coherent with the European Alliance of Associations for Rheumatology (EULAR) recommendations that regard dactylitis as a poor prognostic factor in early PsA and advocate rapid initiation of DMARDs.<sup>19</sup> Overall, these data may further inform management strategies, including clinical trials for targeted therapy to understand differential responses within PsA phenotypes.

## CONCLUSIONS

The presence of dactylitis is independently associated with an increased burden of disease with greater SJC, CRP, US-detected synovitis and erosive bone damage in DMARD-naïve

early PsA. Dactylitis should therefore be considered a clinical marker for a more severe phenotype in early PsA and may be an important discriminator for risk stratification in early intervention strategies.

**Twitter** Sayam Dubash @DrSayamDubash, Xabier Michelena @xabiermich, Leticia Garcia-Montoya @LeedsBRC, Richard J Wakefield @CAHTriTeam1, Philip S Helliwell @UniversityLeeds, Paul Emery @LeedsHospitals, Dennis G McGonagle @LeedsTeamSpA and Ai Lyn Tan @DrAiLynTan

**Acknowledgements** The authors thank the study sonographers, particularly Kate Smith and Borsha Sarkar. This report presents independent research supported by the National Institute for Health Research Leeds Biomedical Research Centre.

**Contributors** SD conducted the study, analysis and the writing of the manuscript. OA and XM conducted statistical methods and tests. XM and LG-M contributed to the clinical assessment of patients. RJW contributed to ultrasound scan procedure and protocol. PE and ALT conducted clinical supervision of patients and writing of the manuscript. HM-O, DGM and PH contributed to writing of the manuscript. HM-O designed the study protocol and oversaw its conduct as principal investigator and guarantor.

**Funding** This study was supported by the NIHR Leeds Biomedical Research Centre. SD was supported by the Leeds Cares charity.

**Disclaimer** The views expressed are those of the authors and not necessarily those of the National Institute for Health Research or the Department of Health and Social Care.

**Competing interests** None declared.

**Patient consent for publication** Consent obtained directly from patient(s).

**Ethics approval** Ethics approval was granted by the Leeds West Research Ethics Committee (ref: LG03/028) and written informed consent was received from all participants.

**Provenance and peer review** Not commissioned; externally peer reviewed.

**Data availability statement** Data are available upon reasonable request. All data relevant to the study are included in the article or uploaded as supplementary information.

**Supplemental material** This content has been supplied by the author(s). It has not been vetted by BMJ Publishing Group Limited (BMJ) and may not have been peer-reviewed. Any opinions or recommendations discussed are solely those of the author(s) and are not endorsed by BMJ. BMJ disclaims all liability and responsibility arising from any reliance placed on the content. Where the content includes any translated material, BMJ does not warrant the accuracy and reliability of the translations (including but not limited to local regulations, clinical guidelines, terminology, drug names and drug dosages), and is not responsible for any error and/or omissions arising from translation and adaptation or otherwise.

**Open access** This is an open access article distributed in accordance with the Creative Commons Attribution Non Commercial (CC BY-NC 4.0) license, which permits others to distribute, remix, adapt, build upon this work non-commercially, and license their derivative works on different terms, provided the original work is properly cited, appropriate credit is given, any changes made indicated, and the use is non-commercial. See: <http://creativecommons.org/licenses/by-nc/4.0/>.

#### ORCID iDs

Sayam Dubash <http://orcid.org/0000-0002-9303-7122>  
 Oras A Alabas <http://orcid.org/0000-0003-2002-0781>  
 Xabier Michelena <http://orcid.org/0000-0002-5352-919X>  
 Leticia Garcia-Montoya <http://orcid.org/0000-0002-1806-7532>  
 Richard J Wakefield <http://orcid.org/0000-0001-5352-8683>  
 Philip S Helliwell <http://orcid.org/0000-0002-4155-9105>  
 Paul Emery <http://orcid.org/0000-0002-7429-8482>  
 Dennis G McGonagle <http://orcid.org/0000-0001-7428-0146>  
 Ai Lyn Tan <http://orcid.org/0000-0002-9158-7243>  
 Helena Marzo-Ortega <http://orcid.org/0000-0002-9683-3407>

#### REFERENCES

- 1 McGonagle D, Tan AL, Watad A, *et al.* Pathophysiology, assessment and treatment of psoriatic dactylitis. *Nat Rev Rheumatol* 2019;15:113–22.

- 2 Olivieri I, Barozzi L, Favaro L, *et al.* Dactylitis in patients with seronegative spondylarthropathy. assessment by ultrasonography and magnetic resonance imaging. *Arthritis Rheum* 1996;39:1524–8.
- 3 Kane D, Greaney T, Bresnihan B. Ultrasonography in the diagnosis and management of psoriatic dactylitis. *J Rheumatol* 1751;1 1999:1746.
- 4 Tan AL, Fukuba E, Halliday NA, *et al.* High-Resolution MRI assessment of dactylitis in psoriatic arthritis shows flexor tendon pulley and sheath-related enthesitis. *Ann Rheum Dis* 2015;74:185–9.
- 5 Backhaus M, Kamradt T, Sandrock D, *et al.* Arthritis of the finger joints: a comprehensive approach comparing conventional radiography, scintigraphy, ultrasound, and contrast-enhanced magnetic resonance imaging. *Arthritis Rheum* 1999;42:1232–45.
- 6 Taylor W, Gladman D, Helliwell P, *et al.* Classification criteria for psoriatic arthritis: development of new criteria from a large international study. *Arthritis Rheum* 2006;54:2665–73.
- 7 Brockbank JE, Stein M, Schentag CT, *et al.* Dactylitis in psoriatic arthritis: a marker for disease severity? *Ann Rheum Dis* 2005;64:188–90.
- 8 Clegg DO, Reda DJ, Mejias E. Comparison of sulfasalazine and placebo in the treatment of psoriatic arthritis. *Arthritis Rheum* 1996;39:2013–20.
- 9 Kaeley GS, Eder L, Aydin SZ, *et al.* Dactylitis: a hallmark of psoriatic arthritis. *Semin Arthritis Rheum* 2018;48:263–73.
- 10 Padovano I, Costantino F, Breban M, *et al.* Prevalence of ultrasound synovial inflammatory findings in healthy subjects. *Ann Rheum Dis* 2016;75:1819–23.
- 11 Terslev L, Naredo E, Iagnocco A, *et al.* Defining enthesitis in spondyloarthritis by ultrasound: results of a Delphi process and of a reliability reading exercise. *Arthritis Care Res* 2014;66:741–8.
- 12 Balint PV, Terslev L, Aegerter P, *et al.* Reliability of a consensus-based ultrasound definition and scoring for enthesitis in spondyloarthritis and psoriatic arthritis: an OMERACT us initiative. *Ann Rheum Dis* 2018;77:1730–5.
- 13 Healy PJ, Groves C, Chandramohan M, *et al.* MRI changes in psoriatic dactylitis—extent of pathology, relationship to tenderness and correlation with clinical indices. *Rheumatology* 2008;47:92–5.
- 14 van der Heijde D, Gladman DD, FitzGerald O, *et al.* Radiographic progression according to baseline C-reactive protein levels and other risk factors in psoriatic arthritis treated with tofacitinib or adalimumab. *J Rheumatol* 2019;46:1089–96.
- 15 Geijer M, Lindqvist U, Husmark T, *et al.* The Swedish early psoriatic arthritis registry 5-year followup: substantial radiographic progression mainly in men with high disease activity and development of Dactylitis. *J Rheumatol* 2015;42:2110–7.
- 16 Husic R, Gretler J, Felber A, *et al.* Disparity between ultrasound and clinical findings in psoriatic arthritis. *Ann Rheum Dis* 2014;73:1529–36.
- 17 Gladman DD, Ziouzina O, Thavaneswaran A, *et al.* Dactylitis in psoriatic arthritis: prevalence and response to therapy in the biologic era. *J Rheumatol* 2013;40:1357–9.
- 18 Vieira-Sousa E, Alves P, Rodrigues AM, *et al.* GO-DACT: a phase 3B randomised, double-blind, placebo-controlled trial of golimumab plus methotrexate (MTX) versus placebo plus MTX in improving DACTylitis in MTX-naive patients with psoriatic arthritis. *Ann Rheum Dis* 2020;79:490–8.
- 19 Gossec L, Baraliakos X, Kerschbaumer A, *et al.* EULAR recommendations for the management of psoriatic arthritis with pharmacological therapies: 2019 update. *Ann Rheum Dis* 2020;79:700.1–12.