



**UNIVERSITY OF LEEDS**

This is a repository copy of *Causes of subcutaneous emphysema following dental procedures: a systematic review of cases 1993-2020*.

White Rose Research Online URL for this paper:  
<https://eprints.whiterose.ac.uk/171424/>

Version: Supplemental Material

---

**Article:**

Jones, A, Stagnell, S, Renton, T et al. (2 more authors) (2021) Causes of subcutaneous emphysema following dental procedures: a systematic review of cases 1993-2020. *British Dental Journal*, 231. pp. 493-500. ISSN 0007-0610

<https://doi.org/10.1038/s41415-021-3564-0>

---

**Reuse**

Items deposited in White Rose Research Online are protected by copyright, with all rights reserved unless indicated otherwise. They may be downloaded and/or printed for private study, or other acts as permitted by national copyright laws. The publisher or other rights holders may allow further reproduction and re-use of the full text version. This is indicated by the licence information on the White Rose Research Online record for the item.

**Takedown**

If you consider content in White Rose Research Online to be in breach of UK law, please notify us by emailing [eprints@whiterose.ac.uk](mailto:eprints@whiterose.ac.uk) including the URL of the record and the reason for the withdrawal request.



[eprints@whiterose.ac.uk](mailto:eprints@whiterose.ac.uk)  
<https://eprints.whiterose.ac.uk/>

### SE DISTRIBUTION BY MANDIBULAR OR MAXILLARY TOOTH TREATED

■ Maxillary ■ Mandibular ■ Both ■ Not relevant

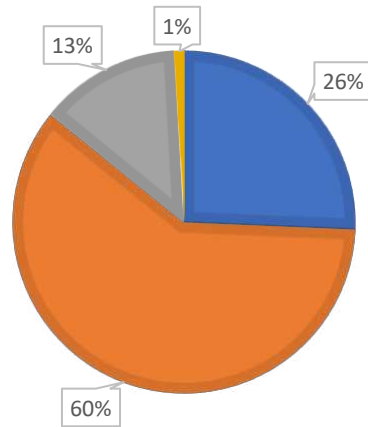


Figure 4. When treatment of a specific tooth was reported (113 cases) the majority of cases of SE resulted following treatment of at least one lower tooth (73%)( $p < 0.01$ ).