



This is a repository copy of *Placental microbial–metabolite profiles and inflammatory mechanisms associated with preterm birth.*

White Rose Research Online URL for this paper:  
<https://eprints.whiterose.ac.uk/164688/>

Version: Accepted Version

---

**Article:**

Parris, K.M. [orcid.org/0000-0002-1382-5146](https://orcid.org/0000-0002-1382-5146), Amabebe, E. [orcid.org/0000-0002-3924-5270](https://orcid.org/0000-0002-3924-5270), Cohen, M.C. et al. (1 more author) (2020) Placental microbial–metabolite profiles and inflammatory mechanisms associated with preterm birth. *Journal of Clinical Pathology*, 74 (1). pp. 10-18. ISSN 0021-9746

<https://doi.org/10.1136/jclinpath-2020-206536>

---

This article has been accepted for publication in the *Journal of Clinical Pathology*, 2020 following peer review, and the Version of Record can be accessed online at <http://dx.doi.org/10.1136/jclinpath-2020-206536> © Authors (or their employer(s), 2020. Reuse of this manuscript version (excluding any databases, tables, diagrams, photographs and other images or illustrative material included where a another copyright owner is identified) is permitted strictly pursuant to the terms of the Creative Commons Attribution-Non Commercial 4.0 International (CC-BY-NC 4.0) <https://creativecommons.org/licenses/by-nc/4.0/>

**Reuse**

This article is distributed under the terms of the Creative Commons Attribution-NonCommercial (CC BY-NC) licence. This licence allows you to remix, tweak, and build upon this work non-commercially, and any new works must also acknowledge the authors and be non-commercial. You don't have to license any derivative works on the same terms. More information and the full terms of the licence here: <https://creativecommons.org/licenses/>

**Takedown**

If you consider content in White Rose Research Online to be in breach of UK law, please notify us by emailing [eprints@whiterose.ac.uk](mailto:eprints@whiterose.ac.uk) including the URL of the record and the reason for the withdrawal request.



[eprints@whiterose.ac.uk](mailto:eprints@whiterose.ac.uk)  
<https://eprints.whiterose.ac.uk/>

# Placental Microbial-Metabolite Profiles and Inflammatory Mechanisms Associated with Preterm Birth

Kerry M. Parris,<sup>1+</sup> Emmanuel Amabebe,<sup>1+</sup> Marta C. Cohen,<sup>1,2</sup> Dilly O. Anumba<sup>1\*</sup>  
<sup>1</sup>Department of Oncology and Metabolism, University of Sheffield, UK; <sup>2</sup>Department of Histopathology, Sheffield Children's NHS Foundation Trust, UK.

+Joint First author

**\*Corresponding author:**

Prof. Dilly O. Anumba MD, Department of Oncology and Metabolism, University of Sheffield, 4th Floor, Jessop Wing, Tree Root Walk, Sheffield S10 2SF, UK. +44 114 2159707/2268148, [d.o.c.anumba@sheffield.ac.uk](mailto:d.o.c.anumba@sheffield.ac.uk)

## Abstract

There is growing emphasis on the potential significance of the placental microbiome and microbiome-metabolite interactions in immune responses and subsequent pregnancy outcome, especially in relation to preterm birth (PTB). This review discusses in detail the pathomechanisms of placental inflammatory responses and the resultant maternal-fetal allograft rejection in both microbial-induced and sterile conditions. It also highlights some potential placental-associated predictive markers of PTB for future investigation. The existence of a placental microbiome remains debatable. Therefore, an overview of our current understanding of the state and role of the placental microbiome (if it exists) and metabolome in human pregnancy is also provided. We critically evaluate the evidence for a placental microbiome, discuss its functional capacity through the elaborated metabolic products and also describe the consequent and more established feto-maternal inflammatory responses that stimulate the pathway to preterm premature rupture of membranes (PPROM), preterm labour (PTL) and spontaneous PTB.

**Keywords:** Preterm Birth, Placenta, Microbiome, Metabolite, Inflammation

## Introduction

This review provides an overview of our current understanding of the state and role of the not-yet proven placental microbiome and metabolome in human pregnancy. The human microbiome has existed as a complex, symbiotic ecosystem of microorganisms inhabiting human mucosal tissues and skin, yet its importance in health and disease has only been reported in recent years.<sup>(1)</sup> Growing evidence suggests a vital role for the human microbiome in immunity, metabolism and cancer but clarity remains required regarding whether microbiome dysregulation is the cause or consequence of these processes and conditions.<sup>(2-5)</sup> Dysbiosis of the gut microbiome has been implicated in influencing tumorigenesis and cancer progression in gastrointestinal and systemic cancers <sup>(6)</sup> as well as in the development of polycystic ovary syndrome (PCOS), <sup>(7)</sup> Type 2 Diabetes (T2D) <sup>(8)</sup> and even mental health disorders such as anxiety and depression.<sup>(9)</sup> Research suggests a possible contribution from a deranged maternal gut microbiota in the development of atopy, the genetic tendency to develop allergic diseases such as rhinitis and asthma and autoimmune phenotypes in the

neonate(4), along with an increased risk of necrotising enterocolitis and sepsis.(10) Furthermore, emerging evidence of the interactions between placental and fetal gut and lung microbiomes highlights that dysregulation of these fetal microbiomes related to placental dysbiosis may influence short- and long-term neonatal complications such as bronchopulmonary dysplasia and necrotising enterocolitis amongst other morbidities.(10) Nonetheless, whether the maternal gut microbiota, and the subsequent impact on metabolic, hormonal and immunological factors during gestation, exerts any influence on the pregnancy itself remains unclear.(11)

However, there is consensus on the role of the vaginal microbiome in health with a dominance of protective *Lactobacillus* species, which make up >70% of resident bacteria, found in the vagina of healthy, reproductive-age women.(11-14) Lowered disease risk and increased protection from opportunistic pathogens is considered to be the benefits of this dominance and the low pH of 4.5 observed in humans. Additionally, decreased relative abundance of *Lactobacillus* species in the vagina is strongly linked to bacterial vaginosis (BV) resulting in increased anaerobic bacterial respiration, pH values  $\geq 4.7$  and increased risks of infertility, maternal infection (particularly sexually transmitted infections, STI), preterm premature rupture of membranes (PPROM) and preterm labour (PTL) through microbial ascent to the uterus.(12-15)

The two-part Human Microbiome Project (HMP), spanning almost fifteen years, has sought to answer questions surrounding the uniqueness of the microbiome between humans and throughout different life stages, as well as how diversity contributes to function and dysfunction.(15, 16) The first part of the HMP revealed a microbiome distinctly different within each individual's niche in addition to a 'personalised' microbiome with discrete variants. The second part determined how changes to the host-microbiome interactions affect the stressors for three conditions - prediabetes, inflammatory bowel diseases and pregnancy including preterm birth (PTB). *Lactobacillus* dominance of the vaginal microbiome positively correlated to term birth. A 'signature' microbiome was described for a high risk of PTB. However, pregnancy-related microbiomes for other tissues such as the placenta, uterus, breast milk or blood were not explored.(15)

Despite this apparent oversight, evidence showed support for the translocation of maternal gut bacteria to breast milk and other extra-intestinal sites during pregnancy.(4) They also showed that the maternal gut microbiome exerts an influence on neonatal immunity most notably through colonisation of the neonatal gut during vaginal delivery.(4, 17, 18) Contrastingly, reports of hematogenous and *in utero* transmission of bacteria to identifiable placental and amniotic fluid microbiomes challenge the decades-old 'sterile womb' paradigm.(19-23)

Given the above raging controversy, this review discusses in detail the pathomechanism of placental inflammatory responses and the plausibly resultant maternal-fetal allograft rejection in both microbial-induced and sterile conditions. We also highlight some potential placental-associated predictive markers of PTB for future investigation. The evidence for and against a placental microbiome is described and how this may interact with the placental metabolome during human pregnancy is also provided in the context of the more established fetomaternal

inflammatory responses that stimulate the pathway to preterm premature rupture of membranes (PPROM), preterm labour (PTL) and spontaneous PTB.

## **Placental inflammatory response**

### **Histologic Features**

Spontaneous preterm birth (sPTB) is often associated with ascending intrauterine infection that triggers both maternal and fetal inflammatory responses, collectively referred to as the placental inflammatory response (PIR). Placental inflammatory response is associated with poor neonatal outcomes including low birth weight, sepsis, intraventricular haemorrhage, cerebral palsy, bronchopulmonary dysplasia, and neonatal mortality.(24, 25) The inflammatory responses of the placenta reflect the maternal and fetal inflammatory responses. PIR begins as a maternal inflammatory response with subsequent fetal inflammatory responses elicited if acute chorioamnionitis persists and increases in severity (24).

The inflammatory response of the placenta that extends into the chorion, amnion or decidua is referred to as maternal inflammatory response. The hallmark of this response is histologic chorioamnionitis (HCA). On the other hand, inflammation that infiltrates the chorionic plate, umbilical cord (funisitis), and fetal blood vessels (vasculitis) is regarded as fetal inflammatory response (FIR), which is defined clinically as a fetal cord blood plasma IL-6 concentration >11 pg/ml (24), and frequently associated with microbial invasion of the amniotic cavity.(24, 26)

The fetus' capacity to respond to bacterial colonisation develops after 20 – 21 week's gestation and manifests as inflammation of the umbilical cord (funisitis). This fetal response begins in the umbilical vein (phlebitis) before progressing to one or both umbilical arteries (arteritis) and into the Wharton's jelly, with this progression being a good pathologic indicator of the stage and severity of the fetal inflammatory response.(27, 28) Some researchers regard both funisitis and chorioamnionitis as hallmarks of fetal inflammatory response syndrome (FIRS), however, the fetal inflammatory response indicates an increased severity and advancement of acute chorioamnionitis.(26, 29) Both maternal and fetal inflammatory responses are associated with PPROM but FIR in the placenta is usually more severe than MIR and more frequently associated with poor neonatal outcome.(25, 30) Preterm parturition is usually associated with HCA and infants born in such situation are at greater risk of sepsis and poor neurological, cardiorespiratory, gastrointestinal (including necrotising enterocolitis) and renal outcomes.(24, 25, 31, 32)

There is often chorioamnionitis (inflammation in the chorion and amnion) at placental examination with associated high concentration of cytokines in the amniotic fluid.(33) However, signs of intra-amniotic inflammation have been observed without elevated amniotic fluid cytokine levels.(33) Early detection has resulted in the identification of several inflammatory markers associated with PIR.

Spontaneous PTB between 24-32 weeks are less common (<2% of all births) than late preterm births but are associated with greater risk of morbidity and mortality and evidence of

intrauterine infection and/or inflammation.(34) Histologic chorioamnionitis (HCA) is defined by inflammation of the chorion, amnion and placenta.(31) It is a frequent observation (~70%) in PTBs between 20-24 weeks gestation, but rare (16%) in deliveries after 34 weeks.(26) HCA is observed in 10% of term births, 30% of PTL with intact membranes and 50% of PPRM, with highest frequency of 80–90% in miscarriages at 20-24 weeks.(35) Despite the classic observation of HCA and high amniotic fluid concentrations of chemocytokines or matrix degrading enzymes in intrauterine infection and/or inflammation, only a few of such pregnancies (5-12% at term; and 20% preterm with PROM)(36) exhibit clinical signs of chorioamnionitis.(34) HCA is about 3 times more common than clinical chorioamnionitis, which is characterised by maternal fever, tachycardia, uterine tenderness, leucocytosis and preterm rupture of membranes (PROM);(31) and diagnosed by positive amniotic fluid culture of bacteria such as genital mycoplasmas.(37) Intrauterine infection may also occur through haematogenous spread, by invasive medical procedures, or by retrograde passage from the peritoneal cavity through the fallopian tubes, but most commonly by ascent from the vagina associated with a dysbiotic microbiota.(34, 37)

### **Immune Profile**

The placental microenvironment in healthy pregnancies is biased toward a T-helper (Th)2 (predominantly anti-inflammatory e.g. IL-4 and IL-10) cytokine milieu,(38) and reversal to Th1 cytokine (e.g. TNF- $\alpha$ , IFN- $\gamma$ , IL-2 and IL-1 $\beta$ ) dominance is associated with labour.(39) The balance between Th1 (cell mediated and pro-inflammatory) and Th2 cytokines is considered a measure of the immune environment.(40) Alteration in this cytokine balance can lead to a breakdown of the maternal-fetal tolerance and rejection of the semi-allogenic fetus.(41) Increased expression of pro-inflammatory cytokines in the placenta, cord blood, maternal blood and cervicovaginal fluid is associated with poor pregnancy outcomes including placental dysfunction, intrauterine growth restriction (IUGR), preeclampsia and PTB.(38, 40, 42, 43) Placentas from women with PPRM and PTB indicate a bias towards Th1 cytokines IFN- $\gamma$ , IL-2 and IL-12 compared to term placentas that show higher IL-4 and IL-10 (Th2) levels.(39) Elevated levels of IL-6 (produced by Th2 cells) and IL-8 (a chemokine produced by macrophages and monocytes) are also observed in preterm compared to term placentas. IL-6 is a highly sensitive and specific indicator of infection-induced PTL, while up to a 1000-fold increase in IL-8 expression have been observed in PTL with evidence of chorioamnionitis.(39)

Choriodecidual colonisation by bacteria with release of pathogen associated molecular patterns (PAMPs, endo- and exotoxins) activate pattern recognition receptors (PRRs) such as toll-like receptors (TLRs) and nod-like receptors (NLRs) that are expressed by amnion epithelial cells, intermediate trophoblasts in the chorion, decidual cells, macrophages, and neutrophils.(44) These PRRs activate the pleiotropic transcription factor nuclear factor- $\kappa$ B (NF- $\kappa$ B) signal transduction pathway. NF- $\kappa$ B regulates the expression of pro-inflammatory cytokines, chemokines and antimicrobial peptides (e.g. defensins).(34, 37, 45) HCA in the setting of PTB is associated with significantly increased chorionic expression of TLR-1 and -2 compared to PTB without HCA.(35) Regardless of membrane status (intact or ruptured) and gestational age (term or preterm), HCA is associated with increased expression of TLR-2 and TLR-4 on chorioamniotic membranes.(45) TLR-2 recognizes microbial products of

gram-positive bacteria (peptidoglycan, lipoteichoic acid), genital mycoplasmas, and fungi; while TLR-4 recognizes bacterial endotoxin (Lipopolysaccharide, LPS).(45) TLR-4 signalling pathway activates NF- $\kappa$ B through the recruitment of adapter proteins (MyD88, IRAK1/4 and TRAF6) and activation of intermediate kinases (RIP1, TAB2/3, TAK1 and IKK $\alpha/\beta$ ) (Fig. 1).(34) Other signalling pathways (p38MAP kinase/CREB) and modulators (histone deacetylase) that interact unselectively with NF- $\kappa$ B signalling are also involved.(34, 46) Key regulators of allogenic tolerance are decidual macrophages, specifically of the M2 anti-inflammatory phenotype, and regulatory T cells (T<sub>regs</sub>), which exhibit immunosuppressive properties. The placenta is capable of inducing these homeostatic macrophages and regulatory T cells to establish and maintain pregnancy with accumulation of T<sub>regs</sub> having been observed in the decidua.(47)

### **Cytokine Profile**

The downstream effect of NF- $\kappa$ B activation is the release of pro-inflammatory chemocytokines, which induce neutrophil activity, synthesis and release of PG, contractile associated proteins, and matrix metalloproteinases (MMPs) in the placental tissues and fetal membranes. The ultimate effect is increased myometrial contractility, cervical remodelling, membrane rupture, and PTB (Fig. 1).(37, 46), which can occur due to premature or pathological activation of NF- $\kappa$ B.(48)

On the other hand, IL-10 inhibits the activity of NF- $\kappa$ B,(49) and downregulates Th1-associated cytokines and PGE<sub>2</sub> expression.(50) IL-10 expression is stimulated by bacterial colonisation of the fetal membranes and amniotic cavity; and inflammation-associated intracellular signalling pathways e.g. MyD88, p38MAP kinase, CREB, and STAT.(46) Levels of IL-10 and IL-4 are elevated in placentas of women who delivered at term,(51) while placental IL-10 expression is reduced in pregnancies complicated by chorioamnionitis and PTL.(52) Similarly, low levels of IL-10 have been observed in umbilical cord blood of preterm neonates. However, high plasma levels of IL-10 have been reported in women who experienced PTB.(53)

Another anti-inflammatory cytokine, transforming growth factor- $\beta$ 2 (TGF- $\beta$ 2) is also secreted by the placenta.(51) Low cord blood levels of TGF- $\beta$  but elevated IL-10 have been found in women with placental inflammation.(54) High levels of TGF- $\beta$  and IL-4 in maternal plasma have also been associated with high risk of PTB <35 weeks with HCA.(40) In a recent case-control study, low serum levels of IL-10 or TGF- $\beta$  or both simultaneously between 22-25 weeks' gestation were associated with high risk of PTB independent of the presence of bacterial vaginosis (BV)(55). These regulatory cytokines(55) prevent inflammation-mediated damage to the fetus.(51)

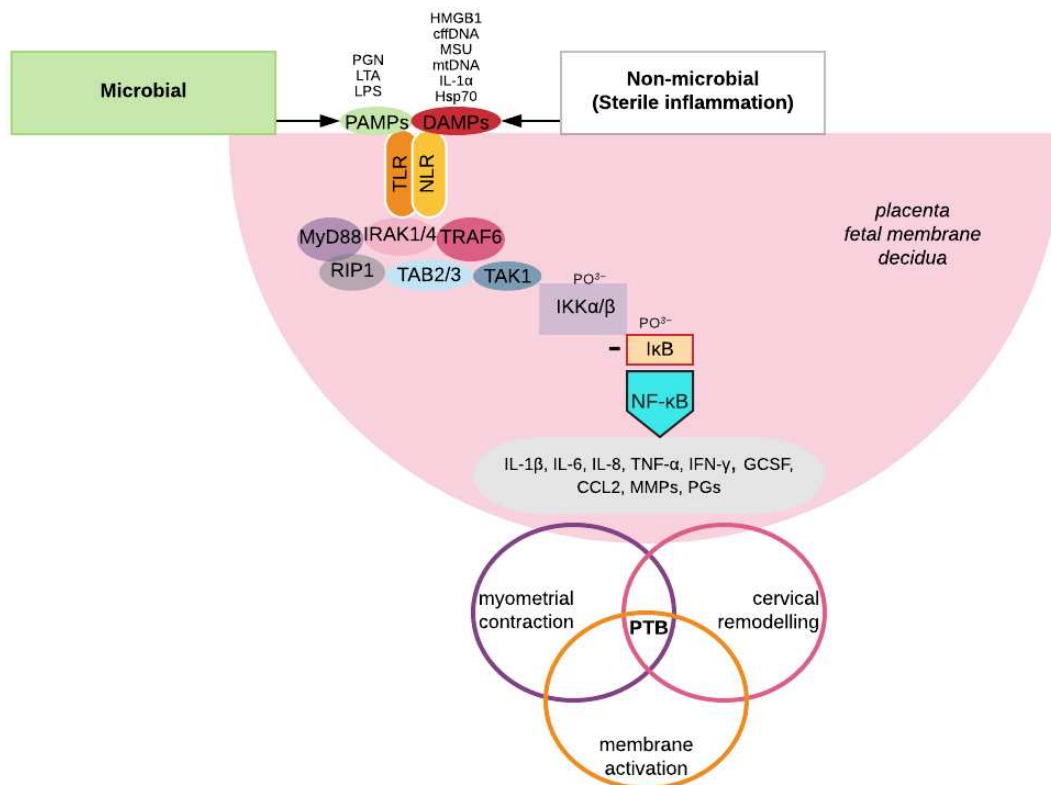
Another endogenous protein associated with immune reactivity and homeostasis in pregnancy is anti-secretory factor (AF). AF is present in the placenta and other human tissues and body fluid. It is also expressed by macrophages and dendritic cells with potent anti-inflammatory effects. It usually exists in an inactive form and becomes activated in response to exposure to bacterial toxins as part of the innate immune response. Placenta levels of active AF are inversely related to inflammation and decrease in PTB. It has been suggested that AF regulates placental inflammation during gestation by converting complement factor 3 to its inactive form and stimulating the activity of proteasomes. (56)

Bacterial colonisation of the placenta in the latter half of pregnancy elicits the so-called fetal inflammatory response syndrome (FIRS), through the stimulation of the fetal hypothalamic pituitary axis and the production of corticotropin-releasing hormone (CRH) from the placenta. Subsequently, there is increased fetal cortisol biosynthesis and decreased maternal cortisol metabolism. Cortisol stimulates PG synthesis and through a positive feedback loop induces placental CRH production. PG production is enhanced by concomitant downregulation of prostaglandin dehydrogenase (PGDH) within the chorion and the production of PTGS-2. Both CRH and PGs stimulate MMP production and infiltration of inflammatory mediators (37, 44).

### **Sterile inflammation**

Some women with signs of intra-amniotic inflammation e.g. elevated amniotic fluid cytokines do not demonstrate clinical intra-amniotic infection.(33) For instance, in the absence of positive amniotic fluid bacterial cultures, elevated amniotic fluid IL-6, IL-1 $\alpha$ , IL-1 $\beta$  levels have been shown to correlate with PTB before 34 weeks.(57) Elevated placental (58, 59) and cervical (50) cytokine levels have been described in women who delivered preterm without histologically confirmed intrauterine infection. Spontaneous PTB without infection is more common than PTL associated with infection. (60) (46) However, some pregnancies without microbial invasion of the amniotic cavity but with bacteria localised to the fetal membranes may be misclassified as 'sterile'. More so, because antibiotics are generally ineffective in preventing PTL and birth in women with infection, such PTBs may be the result of inflammation rather than infection.(34) Amongst other factors, the degree of immune response mounted by the host against the infectious agent is crucial to the ultimate reproductive outcome. This is because a significant proportion of women with inflammation of the gestational tissues who deliver prematurely do not have infection.(46, 61) Hence, for more effective prevention/treatment of PTB, co-administration of antibiotics and anti-inflammatory agents has been recommended.(34)

Sterile inflammation may be induced by cellular stress, tissue damage, and danger signals and is mediated by damage-associated molecular patterns (DAMPs) or alarmins, which activate PRRs. The non-microbial molecular drivers of sterile inflammation are usually associated with cell damage or death and are either intracellular – high-mobility group box 1 (HMGB1), cell-free DNA, uric acid, heat shock proteins (e.g. Hsp70), IL-1 $\alpha$  and mitochondrial components (DNA, ATP, N-formylated peptides); or extracellular – extracellular matrix proteins (fibronectin, hyaluronan), oxidised phospholipids, fatty acids, advanced glycosylation end-products (AGEs), lipid oxidation products and oxysterols. These alarmins are released by the placenta and fetal membranes and provoke inflammation by activating PRRs on gestational tissues resulting in activation of NF- $\kappa$ B and p38MAP kinase signalling pathways which stimulate transcription of inflammatory genes. The ultimate outcomes include placental dysfunction, IUGR, preeclampsia and PTB (Fig 1).(42, 46) A detailed review of the role of cytokines in PTL is provided by Farina and Winkelman.(50)



**Figure 1.** Microbial and sterile inflammatory signalling pathways associated with preterm labour and birth. Both pathogen (PAMPs) and damage (DAMPs) associated molecular patterns activate NF- $\kappa$ B by interacting with pattern recognition receptors (TLR and NLR) on immune cells and gestational tissues. The pleiotropic NF- $\kappa$ B regulates the expression of pro-inflammatory mediators that activate the tripartite common pathway of labour and if before 37 completed weeks of gestation, preterm birth (PTB).

*cffDNA*: cell-free fetal DNA, *CCL2*: chemokine (C-C motif) ligand, *DAMP*: damage-associated molecular patterns, *GCSF*: granulocyte colony-stimulating factor, *HMGB1*: high-mobility group box 1, *Hsp70*: heat shock protein 70, *IFN- $\gamma$* : interferon-gamma, *IKK $\alpha$ / $\beta$* : inhibitor of nuclear factor kappa B kinase subunit alpha/beta, *I $\kappa$ B*: inhibitor of nuclear factor of kappa B, *IL-1 $\alpha$* : interleukin-1-alpha, *IL-1 $\beta$* : interleukin-1-beta, *IL-6*: interleukin-6, *IL-8*: interleukin-8, *IRAK1/4*: Interleukin-1 receptor-associated kinase 1/4, *LPS*: lipopolysaccharide, *LTA*: lipoteichoic acids, *MMP*: matrix metalloproteinases, *MSU*: monosodium urate, *mtDNA*: mitochondrial DNA, *MyD88*: myeloid differentiation primary response 88, *NF- $\kappa$ B*: nuclear factor kappa B, *NLR*: nod-like receptor, *PAMP*: pathogen associated molecular patterns, *PG*: prostaglandins, *PGN*: peptidoglycans, *PTB*: preterm birth, *RIP1*: receptor interacting protein 1, *TAB2/3*: transforming growth factor beta-activated kinase 1-binding protein 2/3, *TAK1*: transforming growth factor beta-activated kinase 1, *TLR*: toll-like receptor, *TRAF6*: tumour necrosis factor receptor associated factor.

### Chronic versus acute placental inflammation

Placental infections affect different histologic components of this complex organ and are termed chorioamnionitis, intervillitis, villitis and deciduitis. Depending on the pathologic features expressed, placentitis could be acute or chronic. Both acute and chronic infectious villitis result from direct haematogenous spread of pathogens to the placenta, though whether the inflammatory cell types are neutrophils or macrophages and lymphocytes defines an acute or chronic villitis respectively (29, 62). Where cultures, PCR or additional methods fail to demonstrate an infection, a diagnosis of villitis of unknown aetiology (VUE) is made, a condition speculated to be related to dysregulation of the maternal immune system (63). The prevalence of VUE varies between studies with a range identified between 2% and 33.8% of all placentas having a positive diagnosis; it has been suggested that differences in diagnostic



criteria and sampling protocols may account for this broad range. VUE is mainly associated with term placentas and is often regarded as being a benign placental inflammatory lesion despite the more severe grades being associated with adverse neonatal outcomes (29, 63).

An infiltration of neutrophils characterises acute infections, either chorioamnionitis or villitis, whereas the hallmark of chronic chorioamnionitis (CCA) is an infiltration of lymphocytes to the chorionic plate and chorionic membranes. Acute chorioamnionitis presents with a thickened amniotic membrane which can be easily separated from the amnion due to adhesions between the layers (62, 64), a feature which distinguishes it from the rarely observed condition, chronic chorioamnionitis (62, 64). VUE is diagnosed where there is no evidence to support an infectious aetiology and an infiltration of Hofbauer cells (fetal macrophages) and maternal T-lymphocytes are demonstrated with histologic staining techniques. Uniquely, the inflammatory processes in VUE involves immune cells from two different hosts and shows maternal cells damaging fetal tissue and a response resembling allograft rejection (29, 63, 65).

Due to the controversy of terminologies used in describing placental lesions and diagnostic criteria, a group consensus has been developed to reduce definition and sampling differences between laboratories and to standardise grading and staging of inflammation, as detailed in Table 1.(30)

**Table 1.** Amsterdam placental workshop group consensus on staging and grading of maternal and fetal inflammatory responses.

		Inflammatory Response	
		Maternal	Fetal
<b>Stage</b>	1 Early	Acute subchorionitis or chorionitis	Chorionic vasculitis <i>or</i> umbilical phlebitis
	2 Intermediate	Acute chorioamnionitis	Umbilical vasculitis (one or both arteries with or without vein) <i>or</i> umbilical panvasculitis (all three vessels)
	3 Advanced	Necrotising chorioamnionitis	Necrotising funisitis <i>or</i> concentric umbilical perivasculitis
<b>Grade</b>	1 Mild-Moderate	No specific terminology/not severe	No specific terminology/not severe
	2 Severe	Acute chorioamnionitis, subchorionic abscesses	Intense chorionic/umbilical vasculitis
	Other	Chronic or subacute chorioamnionitis	Associated fetal thrombi Peripheral funisitis Acute villitis Acute intervillitis with intervillous abscesses Decidual plasma cells

Adapted from: Redline *et al.*,(66) and Khong *et al.*(30)

Acute inflammatory response to ascending infection is more common than chronic inflammatory lesions during gestation. Acute inflammatory response is characterised clinically and pathologically as feto-maternal neutrophilic infiltrates (Table 2). Neutrophilic migration to the chorioamnion is induced by elevated concentrations of intra-amniotic neutrophil chemokines such as IL-8.(29) Increase in histologic severity in both maternal and fetal acute inflammatory response usually correlates with time of onset of ascending infection during gestation. Usually maternal response precedes the fetal response.(67)

On the other hand, the less well understood chronic inflammatory response could be focal or multifocal but without obvious relationship between aetiology or clinical outcome and severity of inflammation. Due to the expansive collection of placental locations at which chronic inflammatory cells can be observed, characterising chronic inflammatory lesions is often challenging. Chronic chorioamnionitis features in about 39% and 34% of cases of PPRM and PTB respectively.(29) It is especially common in late PTB which constitute up to 70% of premature deliveries. Additionally, chronic chorioamnionitis and elevated intra-amniotic CXCL10 (T-cell chemokine) have been demonstrated in up to 60% of cases of fetal death suggesting a role of maternal anti-fetal rejection in certain cases of idiopathic fetal death.(29) Where chronic chorioamnionitis is observed histologically, a concomitant chronic deciduitis or VUE is commonly diagnosed. Similarly to VUE, chronic chorioamnionitis is regarded as being immunological in origin, though it is associated mainly with preterm births rather than term deliveries.(64)

Chronic inflammatory response is characterised by incidental microscopic identification of chronic inflammatory cells including lymphocytes, plasma cells, histiocytes (tissue macrophages) and eosinophilic infiltrates, most commonly observed in the choriodecidual border of the chorion laeve (Table 3).(64) The degree and severity of T-lymphocyte infiltration is usually not up to the neutrophilic infiltration observed in acute chorioamnionitis. A ratio of neutrophil to lymphocyte shows useful predictive accuracy for PIR with 71.4% sensitivity, 77.9% specificity, 80.7% positive predictive value, and 67.8% negative predictive value.(24)

It is proposed that the migration of CXCR3+ T cells from the maternal (decidua) to fetal tissue (chorioamniotic membranes) (amniotropism) is induced by high concentration of amniotic fluid CXCL10 and overexpression of CXCL9, -10, and -11 in the chorioamnion (Fig 2).(29) This is supported by the observation of elevated amniotic fluid CXCR3 and its ligands CXCL9 and -10 in women who experience PTL and PTB, and lesions of maternal anti-fetal rejection (e.g. chronic chorioamnionitis, chronic histiocytic intervillitis, villitis of unknown aetiology (VUE) and chronic deciduitis with plasma cells) compared to those without such lesions even though they deliver preterm. CXCR3, CXCL9 and CXCL10 are also higher in women with sPTL and PTB compared to those with labour at term. In addition, irrespective of the presence or absence of placental lesions, elevated CXCR3 is associated with PTL compared with labour at term. Interaction of CXCR3 and its IFN- $\gamma$ -inducible ligands (CXCL9, -10, and -11) stimulates migration of maternal CD8+ cytotoxic T-cells from peripheral circulation to the decidua and chorioamnion, increase production of Th1 and reduce synthesis of Th2 cytokines (Fig. 2). However, this phenotype is not observed in physiologic labour at term.(68) The blockage of CXCR3 could attenuate the chronic

inflammatory response associated with PTL and this could be beneficial in preventing maternal anti-fetal rejection and prematurity.

Loss of allogenic tolerance is another potential mechanism for PTB. This occurs via an imbalance in T<sub>regs</sub>, inflammatory Th17 cells and/or decidual macrophages. T<sub>regs</sub> are essential for controlling excessive immune responses and tolerance and are influenced by resident microbiota in tissues other than the placenta, such as the gut, oral mucosa and the vagina. Induction and maintenance of T<sub>regs</sub> relies on the local microbiota and changes to the T<sub>regs</sub>/Th17 balance or microbial dysbiosis are linked to infections, increased neutrophil infiltration and a breakdown in commensal tolerance in mucosa. It is therefore not unrealistic for the placenta to exhibit a similar response whereby dysbiotic microbiota results in maternal anti-fetal rejection. (47, 69)

Chronic chorioamnionitis, chronic histiocytic intervillitis, VUE and chronic deciduitis each present individual inflammatory features, however, they are rarely observed in isolation. Most commonly two or more of these conditions are seen and are termed overlap chronic placental inflammation (oCPI), which presents with unique inflammatory features separate to those noted individually.

There is also the hypothesis that overlap chronic placental inflammation (oCPI) i.e. the presence of chronic chorioamnionitis, chronic histiocytic intervillitis, VUE and chronic deciduitis together in a tissue, could show unique inflammatory features compared to those seen in the rare cases when these conditions occur individually. For example, oCPI may represent an IgA-mediated immunological response characterised by elevated expression of CXCL13,(70) which is selectively chemotactic for B cells through its interaction with CXCR5.(71, 72) This hypothesis is derived from the inclusion of IgA positive plasma cells by oCPI-associated chronic deciduitis compared to isolated chronic deciduitis.(70)

The eosinophils contribute to the fetal inflammatory infiltrate in both acute chronic vasculitis and eosinophilic/T-cell chronic vasculitis (ETCV) (Table 3).(67) Many cases of idiopathic chronic placental inflammation e.g. chronic chorioamnionitis or VUE are reflective of fetal allograft rejection characterised by infiltration of maternal cytotoxic lymphocytes (CD8+ T cells) and presence of fetal human leukocyte antigen (HLA)-specific antibodies in maternal serum.(29, 56)

Furthermore, amniotic fluid concentration of glycodelin-A, which is associated with the maintenance of maternal tolerance against the semi-allogenic placenta/fetus is decreased in chronic chorioamnionitis. This is in addition to 31 differentially expressed proteins in cases of chronic chorioamnionitis compared to cases of acute chorioamnionitis or controls without inflammatory lesions.(29)

The clinical presentation of PTB (especially <34 weeks' gestation) is associated with placental pathologic features (Fig. 3). Ascending intrauterine infection/amniotic fluid infection has been shown to be associated with maternal vascular malperfusion (MVM) and common in cases of PPRM. Women with preeclampsia show changes associated with severe MVM. Irrespective of the presence of intrauterine/amniotic infection, lymphocyte inflammation (chronic chorioamnionitis and VUE) was identified in all clinical presentations of PTB implicating maternal anti-fetal immunologic rejection. Chronic chorioamnionitis and basal villitis are also associated with cases of placental abruption showing laminar decidual necrosis and acute retroplacental haemorrhage.(73)

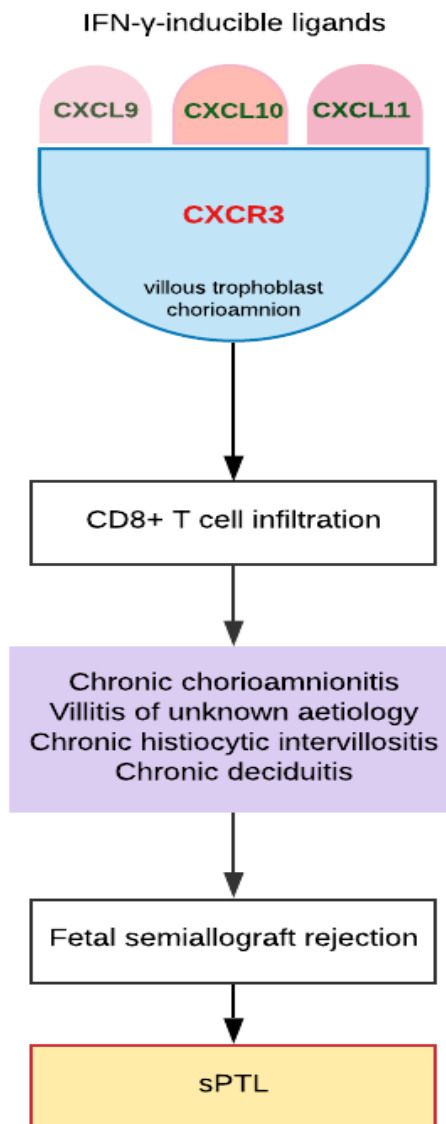
**Table 2.** Characteristics of acute placental inflammatory responses (Amsterdam criteria(30))

<b>Acute inflammatory response</b>	
<b>Maternal response</b>	<b>Fetal response</b>
Acute deciduitis	Acute umbilical phlebitis and/ or arteritis
Acute subchorionitis	Chorionic vasculitis
Acute chorioamnionitis	Acute chorionitis
Acute severe/necrotizing chorioamnionitis	Acute funisitis (Wharton’s jelly)
Neutrophilic infiltration	

**Table 3.** Characteristics of chronic placental inflammatory responses (Amsterdam criteria(30))

<b>Chronic inflammatory response</b>	<b>Cellular infiltration</b>
Chronic deciduitis	Lymphocytes (CD8+ T-cells) Plasma cells Histiocytes Eosinophils
Basal chronic villitis	
Chronic villitis	
Chronic intervillitis	
Chronic chorioamnionitis	
Eosinophilic/T-cell chronic vasculitis	

Placental inflammatory response could be predicted by maternal serum neutrophil-lymphocyte ratio.(24)



**Figure 2.** Disruption of maternal-fetal tolerance during pregnancy. Chronic inflammatory lesions of the placenta are associated with overexpression of CXCR3 (a transmembrane G-protein coupled receptor) by the villous cytotrophoblasts and syncytiotrophoblasts, chorioamnion and decidua. Binding of CXCR3 to its IFN- $\gamma$ -inducible chemokine ligands (CXCL9, -10, and -11) generates a T-cell chemokine gradient from the amniotic fluid and increases CD8+ cytotoxic T cell infiltration of the decidua and fetal membranes. This stimulates cell- and antibody mediated immune responses that lead to chronic chorioamnionitis, villitis of unknown aetiology, and chronic deciduitis with plasma cells that are placental lesions associated with maternal anti-fetal rejection, fetal growth restriction and spontaneous preterm labour (sPTL).(29, 68)

## **‘Placental microbiome’**

A successful pregnancy largely depends on an optimal immune response to the fetal allograft and microbial and other stimuli.(20, 74-76) Interruption of the tolerogenic state associated with a healthy pregnancy results in maternal anti-fetal rejection, placental damage, and pregnancy complications including fetal growth restriction and spontaneous miscarriage or PTL (sPTL). This allograft rejection is either cellular (T-cell) or antibody (humoral) mediated; an extreme form of such rejection is fetal death similar to graft failure in organ transplantation(29). It is hypothesised that villitis of unknown aetiology (VUE), an under-recognised yet significant diagnosis, which is discussed in more detail within this review, results in a distinct fetal systemic inflammatory response akin to allograft rejection or graft versus host disease (GvHD) despite the absence of identifiable pathogens (29, 63).

### **Evidence in favour of a placental microbiome**

Detection of urogenital microbes in the uterus or bacterial colonisation of the placenta and/or amniotic membranes has traditionally been speculated to result in subclinical infection, such as chorioamnionitis, and a concomitant initiation of labour.(20, 77-79) Microbes ascending from the vagina, including group B *Streptococcus*, and *Ureaplasma* and *Mycoplasma* species, have been associated with chorioamnionitis, placental and membrane colonisation and PTB. Interestingly, non-urogenital bacterial species, such as *Streptococcus* and *Fusobacterium* spp., which are normally found in the oral cavity, have also been linked to placental and fetal colonisation and chorioamnionitis, further supporting the hypothesis of hematogenous transfer of microbial organisms to contribute to a placental microbiome.(76, 80, 81) Placentas delivered by sterile Caesarean section following term pregnancy with an absence of infection were found to harbour bacteria, as did amniotic fluid from women who had intact membranes.(5) Doyle *et al.*, (2017) used 16S ribosomal RNA gene sequencing to analyse placental and fetal membrane microbial communities in a rural Malawi cohort reported a placental microbiome at delivery distinct from the vaginal and oral microbiomes. An increased bacterial load of *Fusobacterium nucleatum*, *Ureaplasma* spp. and *Gemella asaccharolytica* was identified in the fetal membranes and this was shown to correlate with shorter gestation and PTB.(82) A placental microbiome resembling that of the oral cavity, specifically the tongue and tonsils, was identified in a study of 320 women. Whilst of a low abundance, bacteria of the species *Firmicutes*, *Tenericutes*, *Proteobacteria*, *Bacteroidetes*, and *Fusobacteria* were found to be present in placentas following 16S rRNA sequencing (20) challenging previous constructs that the placenta has no microbiome.(20, 74-76)

### **Evidence against a placental microbiome**

Conversely, many sequencing-based studies have failed to identify a placental microbiome (75, 83-86), suggesting instead that contamination by reagents used in 16S gene sequencing is the cause of microbial identification and reported placental microbiomes, a recognised vulnerability of sequencing studies, especially when studying tissue with a low bacterial abundance such as the placenta.(87) Alternative sources of contamination which may be

misinterpreted as suggesting a placental microbiome have been attributed to environmental sources, either during or after delivery or from maternal faeces.(20, 85-87) The lack of a placental microbiome has garnered further support following a DNA-sequencing approach study of villous tissue samples from 537 women including negative controls of samples free of biological material. This research found no evidence of a functional placental microbiome and demonstrated that bacterial DNA contamination was from laboratory reagents or acquisition during labour or delivery (75).

### **Placental microbial metabolite profile**

By combining the application of 16S ribosomal DNA-based and whole-genome shotgun (WGS) metagenomic sequencing analyses with multiplex bead-based immunoassay, researchers have observed that changes in placental microbiota that influence delivery outcome are accompanied by variations in microbiota-induced metabolic pathways.(20, 74, 76) These alterations appear not to be influenced by whether the placentas were delivered vaginally or through caesarean section.(20)

The placentas of women who deliver at term without chorioamnionitis show significant positive correlation between *Acinetobacter* spp. and *Streptococcus thermophilus*, and functional pathways involving metabolism of cofactors and vitamins such as riboflavin, nicotinate and nicotinamide, vitamin B6, pantothenate and CoA. These pathways were similarly related to *L. crispatus*, *Acinetobacter* spp, *Streptococcus* spp., *Fusobacterium* spp. and *Enterobacter* spp. in preterm women without chorioamnionitis.(76) However, women with chorioamnionitis irrespective of birth outcome showed alterations in biosynthesis of secondary metabolites (e.g. phenylpropanoid, stilbenoid, diarylheptanoid and gingerol) and lipid (glycerolipid, glycerophospholipid, arachidonic acid and unsaturated fatty acids) metabolism associated with increased abundance of oral commensal bacteria - *S. thermophilus* and *Fusobacterium* spp. Furthermore, in the term women, those with chorioamnionitis had significantly lower butanoate and riboflavin metabolism compared to those without chorioamnionitis. Butyrate from butanoate metabolism inhibits inflammation in the gut,(74) while decreased riboflavin metabolism is associated with inflammation. This altered secondary metabolite biosynthesis is most likely associated with the observed histologic inflammatory responses in term placentas with chorioamnionitis.(76)

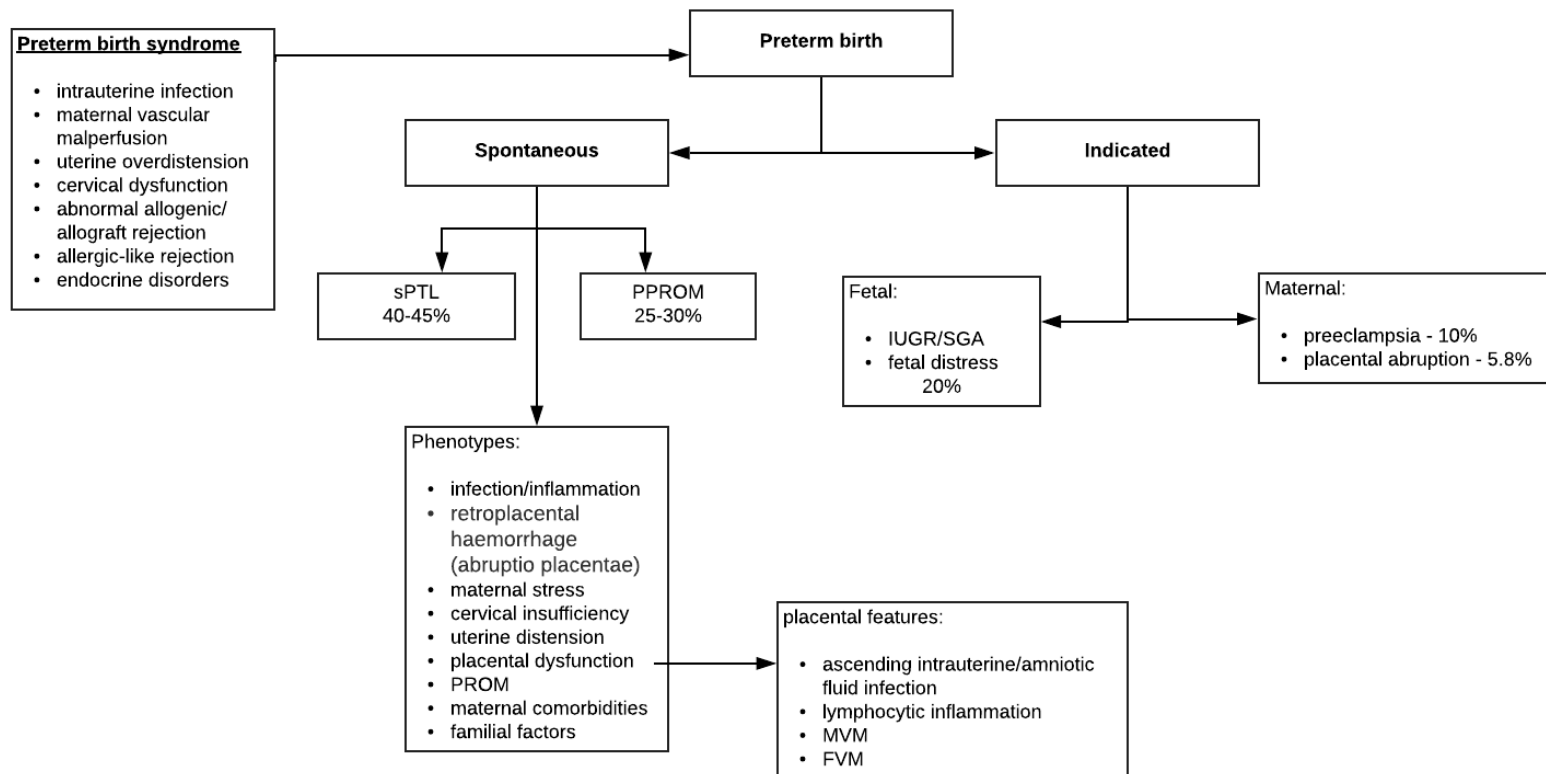
On the other hand, the preterm women with chorioamnionitis showed significantly increased pentose phosphate pathway (PPP), glycerophospholipid metabolism and biosynthesis of siderophores compared to those without chorioamnionitis. The increased PPP is considered to be related to the reduced amniotic fluid glucose observed in chorioamnionitis and PTB as glucose feeds into the PPP.(88) Glycerophospholipids are metabolised to arachidonic acid, which promotes inflammation and prostaglandin (PG) synthesis, both required for initiation of labour.(76) Siderophores are iron-chelating molecules released by aerobic and facultative anaerobic bacteria that require iron for proliferation.(89, 90) Some of such bacteria (e.g. *Gardnerella vaginalis*) have been associated with dysbiosis and adverse reproductive outcomes,(90) compared to lactic acid-producing *Lactobacilli* that do not require iron for growth and proliferation.(90) Increased siderophores in preterm placenta is also possibly related to iron deficiency anaemia. It may also be a causative factor that triggers PTB as response to aggravated iron status.(74)

Elevated amounts of folic acid has also been observed in the placenta of preterm women without excess gestational weight gain.(74) This observation is one of several mixed and contradictory reports present in the literature.(74) For instance, one study suggested that folic acid supplementation initiated beyond the first and second trimester is associated with increased risk of PTB but this was reported without accounting for confounding factors that may affect this association.(91) This observation conflicts with the slight reduction in PTB risk observed in other studies,(92), highlighting the need for further studies to confirm the role of folic acid supplementation before and/or during pregnancy.(91, 92)

### **Conclusion and Future directions**

There is a growing emphasis on the potential significance of the placental microbiome and microbiome-metabolite interactions in immune responses and subsequent pregnancy outcome, especially in relation to preterm birth, however the existence of a placental microbiome remains open for debate. Whilst studies have shown the presence of commensal bacteria in the placenta, many others have found this to be due to contamination from the environment and/or gene sequencing reagents or methods. It has been suggested that poor pregnancy outcomes result from an inflammatory response originating from the mother, fetus and/or placenta. Dysbiosis of the vaginal, gut or placental microbiome and subsequent alterations to secondary metabolite biosynthesis are important in the development of infection, inflammation and pathogenesis of preterm labour. Aberrant placental, maternal and fetal inflammatory responses are implicated in premature activation of the pathways involved in labour. However, early determination of placental pathological pathways associated with PTB remains challenging. There is a dearth of functional placental experimental models necessitating further investigation to elucidate the role of the placenta in the molecular pathways involved in gestation-specific initiation of parturition. A comprehensive investigation involving the omics techniques including genomics, transcriptomics, proteomics, metabolomics and lipidomics across different races and ethnic groups is necessary to determine the phenotypes and functions of the placental microbiome and physicochemical signature and the consequent feto-maternal inflammatory (immune) reactions that may lead to maternal anti-fetal rejection and prematurity. Novel predictive markers of preterm birth may become available based on the understanding of the placenta's contribution to the timing of delivery.





**Figure 3.** Association of clinical presentation of preterm birth and placental pathologic features. Lymphocytic inflammation manifests as chronic chorioamnionitis, villitis of unknown aetiology and chronic deciduitis related to preeclampsia and essential hypertension, all of which are placental inflammatory lesions observed in maternal fetal allograft rejection. Histologically, maternal vascular malperfusion (MVM) correlates with uterine ischemia.(73) *FVM*, fetal vascular malperfusion; *IUGR*, intrauterine growth restriction; *PPROM*, preterm premature rupture of membrane; *SGA*, small for gestational age; *sPTL*, spontaneous preterm labour.(93-95)

## **Funding**

This review was supported by funding from the National Institute for Health Research (NIHR, 17/63/26).

## **Acknowledgement**

NIHR Global Health Research Group on Preterm birth prevention and management (PRIME) at The University of Sheffield, UK; University of Cape Town, South Africa; University of Pretoria, South Africa; and The International Centre for Diarrhoeal Disease Research (icddr,b), Bangladesh. <https://www.primeglobalhealth.co.uk>

A portion of this work was presented at the Sheffield Global Health Symposium as a short oral presentation in January 2020.

## **Competing Interest**

None declared.

## **Licence for Publication**

The Corresponding Author has the right to grant on behalf of all authors and does grant on behalf of all authors, an exclusive licence (or non-exclusive for government employees) on a worldwide basis to the BMJ Publishing Group Ltd to permit this article (if accepted) to be published in JCP and any other BMJPG products and sublicences such use and exploit all subsidiary rights, as set out in our licence (<http://group.bmj.com/products/journals/instructions-for-authors/licence-forms>).

## **Author Contribution**

The review idea was conceptualised by KP, EA, MC and DA. EA and KP performed the literature search and produced the initial draft. All authors contributed to the subsequent drafts and critical revision of the manuscript with KP and EA leading the process. All authors read and approved the final draft before submission for publication.

## **References**

1. Dominguez-Bello MG, Godoy-Vitorino F, Knight R, Blaser MJ. Role of the microbiome in human development. *Gut*. 2019;68(6):1108-14.
2. Wheeler KM, Liss MA. The Microbiome and Prostate Cancer Risk. *Current Urology Reports*. 2019;20(10).
3. Picardo SL, Coburn B, Hansen AR. The microbiome and cancer for clinicians. *Critical Reviews in Oncology Hematology*. 2019;141:1-12.
4. Nyangahu DD, Jaspán HB. Influence of maternal microbiota during pregnancy on infant immunity. *Clin Exp Immunol*. 2019;198(1):47-56.
5. D'Argenio V. The Prenatal Microbiome: A New Player for Human Health. *High Throughput*. 2018;7(4).
6. Zitvogel L, Galluzzi L, Viaud S, Vétizou M, Daillere R, Merad M, et al. Cancer and the gut microbiota: An unexpected link. *Science Translational Medicine*. 2015;7(271).
7. Yurtdas G, Akdevelioglu Y. A New Approach to Polycystic Ovary Syndrome: The Gut Microbiota. *Journal of the American College of Nutrition*.

8. Zhong HZ, Ren HH, Lu Y, Fang C, Hou GX, Yang ZY, et al. Distinct gut metagenomics and metaproteomics signatures in prediabetics and treatment-naive type 2 diabetics. *Ebiomedicine*. 2019;47:373-83.
9. Peirce JM, Alvina K. The role of inflammation and the gut microbiome in depression and anxiety. *J Neurosci Res*. 2019;97(10):1223-41.
10. Piersigilli F, Van Grambezen B, Hocq C, Danhaive O. Nutrients and Microbiota in Lung Diseases of Prematurity: The Placenta-Gut-Lung Triangle. *Nutrients*. 2020;12(2).
11. Taddei CR, Cortez RV, Mattar R, Torloni MR, Daher S. Microbiome in normal and pathological pregnancies: A literature overview. *Am J Reprod Immunol*. 2018;80(2):9.
12. Witkin SS. The vaginal microbiome, vaginal anti-microbial defence mechanisms and the clinical challenge of reducing infection-related preterm birth. *Bjog-Int J Obstet Gy*. 2015;122(2):213-8.
13. Amabebe E, Anumba DOC. The Vaginal Microenvironment: The Physiologic Role of. *Front Med (Lausanne)*. 2018;5:181.
14. Miller EA, Beasley DE, Dunn RR, Archie EA. Lactobacilli Dominance and Vaginal pH: Why Is the Human Vaginal Microbiome Unique? *Front Microbiol*. 2016;7.
15. Proctor LM, Creasy HH, Fettweis JM, Lloyd-Price J, Mahurkar A, Zhou WY, et al. The Integrative Human Microbiome Project. *Nature*. 2019;569(7758):641-8.
16. Turnbaugh PJ, Ley RE, Hamady M, Fraser-Liggett CM, Knight R, Gordon JI. The Human Microbiome Project. *Nature*. 2007;449(7164):804-10.
17. Schoenmakers S, Steegers-Theunissen R, Faas M. The matter of the reproductive microbiome. *Obstet Med*. 2019;12(3):107-15.
18. Williams JE, Carrothers JM, Lackey KA, Beatty NF, Brooker SL, Peterson HK, et al. Strong Multivariate Relations Exist Among Milk, Oral, and Fecal Microbiomes in Mother-Infant Dyads During the First Six Months Postpartum. *J Nutr*. 2019;149(6):902-14.
19. Perez-Muñoz ME, Arrieta MC, Ramer-Tait AE, Walter J. A critical assessment of the "sterile womb" and "in utero colonization" hypotheses: implications for research on the pioneer infant microbiome. *Microbiome*. 2017;5(1):48.
20. Aagaard K, Ma J, Antony KM, Ganu R, Petrosino J, Versalovic J. The Placenta Harbors a Unique Microbiome. *Sci Transl Med*. 2014;6(237).
21. Carmen Collado M, Rautava S, Aakko J, Isolauri E, Salminen S. Human gut colonisation may be initiated in utero by distinct microbial communities in the placenta and amniotic fluid. *Scientific Reports*. 2016;6.
22. Funkhouser LJ, Bordenstein SR. Mom Knows Best: The Universality of Maternal Microbial Transmission. *Plos Biol*. 2013;11(8).
23. Cao B, Stout MJ, Lee I, Mysorekar IU. Placental Microbiome and Its Role in Preterm Birth. *Neoreviews*. 2014;15(12):e537-e45.
24. Kim M-A, Lee YS, Seo K. Assessment of Predictive Markers for Placental Inflammatory Response in Preterm Births. *PLOS ONE*. 2014;9(10):e107880.
25. Liu Z, Tang Z, Li J, Yang Y. Effects of Placental Inflammation on Neonatal Outcome in Preterm Infants. *Pediatrics & Neonatology*. 2014;55(1):35-40.
26. Kemp MW. Preterm Birth, Intrauterine Infection, and Fetal Inflammation. *Frontiers in Immunology*. 2014;5(574).
27. Kim CJ, Yoon BH, Romero R, Bin Moon J, Kim M, Park SS, et al. Umbilical arteritis and phlebitis mark different stages of the fetal inflammatory response. *Am J Obstet Gynecol*. 2001;185(2):496-500.
28. Kim CJ, Romero R, Chaemsaitong P, Chaiyasit N, Yoon BH, Kim YM. Acute chorioamnionitis and funisitis: definition, pathologic features, and clinical significance. *Am J Obstet Gynecol*. 2015;213(4):S29-S52.
29. Kim CJ, Romero R, Chaemsaitong P, Kim J-S. Chronic inflammation of the placenta: definition, classification, pathogenesis, and clinical significance. *American Journal of Obstetrics & Gynecology*. 2015;213(4):S53-S69.

30. Khong TY, Mooney EE, Ariel I, Balmus NCM, Boyd TK, Brundler M-A, et al. Sampling and Definitions of Placental Lesions Amsterdam Placental Workshop Group Consensus Statement. *Archives of Pathology & Laboratory Medicine*. 2016;140(7):698-713.
31. Galinsky R, Polglase GR, Hooper SB, Black MJ, Moss TJM. The consequences of chorioamnionitis: preterm birth and effects on development. *J Pregnancy*. 2013;2013:412831-.
32. Ducey J, Owen A, Coombs R, Cohen M. Vasculitis as part of the fetal response to acute chorioamnionitis likely plays a role in the development of necrotizing enterocolitis and spontaneous intestinal perforation in premature neonates. *Eur J Pediatr Surg*. 2015;25(3):284-91.
33. Jacobsson B, Mattsby-Baltzer I, Hagberg H. Interleukin-6 and interleukin-8 in cervical and amniotic fluid: relationship to microbial invasion of the chorioamniotic membranes. 2005;112(6):719-24.
34. Keelan JA. Pharmacological inhibition of inflammatory pathways for the prevention of preterm birth. *Journal of Reproductive Immunology*. 2011;88(2):176-84.
35. Waring GJ, Robson SC, Bulmer JN, Tyson-Capper AJ. Inflammatory Signalling in Fetal Membranes: Increased Expression Levels of TLR 1 in the Presence of Preterm Histological Chorioamnionitis. *PLOS ONE*. 2015;10(5):e0124298.
36. Romero R, Miranda J, Kusanovic JP, Chaiworapongsa T, Chaemsaitong P, Martinez A, et al. Clinical chorioamnionitis at term I: microbiology of the amniotic cavity using cultivation and molecular techniques. *J Perinat Med*. 2015;43(1):19-36.
37. Nadeau HCG, Subramaniam A, Andrews WW. Infection and preterm birth. *Seminars in Fetal and Neonatal Medicine*. 2016;21(2):100-5.
38. Abioye AI, McDonald EA, Park S, Joshi A, Kurtis JD, Wu H, et al. Maternal, placental and cord blood cytokines and the risk of adverse birth outcomes among pregnant women infected with *Schistosoma japonicum* in the Philippines. *PLOS Neglected Tropical Diseases*. 2019;13(6):e0007371.
39. Sykes L, MacIntyre DA, Yap XJ, Teoh TG, Bennett PR. The Th1:Th2 Dichotomy of Pregnancy and Preterm Labour. *Mediators of Inflammation*. 2012;2012:12.
40. Gargano JW, Holzman C, Senagore P, Thorsen P, Skogstrand K, Hougaard DM, et al. Mid-pregnancy circulating cytokine levels, histologic chorioamnionitis and spontaneous preterm birth. *Journal of reproductive immunology*. 2008;79(1):100-10.
41. Cappelletti M, Della Bella S, Ferrazzi E, Mavilio D, Divanovic S. Inflammation and preterm birth. *Journal of Leukocyte Biology*. 2016;99(1):67-78.
42. Mathieu N-V, Dima O, Julia P, Marie-Ève B, Cyntia D, Sylvain C, et al. Sterile inflammation and pregnancy complications: a review. *Reproduction*. 2016;152(6):R277-R92.
43. Vogel I, Goepfert AR, Thorsen P, Skogstrand K, Hougaard DM, Curry AH, et al. Early second-trimester inflammatory markers and short cervical length and the risk of recurrent preterm birth. *J Reprod Immunol*. 2007;75(2):133-40.
44. Sweeney EL, Dando SJ, Kallapur SG, Knox CL. The Human *Ureaplasma* Species as Causative Agents of Chorioamnionitis. *Clin Microbiol Rev*. 2016;30(1):349-79.
45. Kim YM, Romero R, Chaiworapongsa T, Kim GJ, Kim MR, Kuivaniemi H, et al. Toll-like receptor-2 and -4 in the chorioamniotic membranes in spontaneous labor at term and in preterm parturition that are associated with chorioamnionitis. *American Journal of Obstetrics and Gynecology*. 2004;191(4):1346-55.
46. Keelan JA. Intrauterine inflammatory activation, functional progesterone withdrawal, and the timing of term and preterm birth. *Journal of Reproductive Immunology*. 2018;125:89-99.
47. Svensson-Arvelund J, Mehta RB, Lindau R, Mirrasekhian E, Rodriguez-Martinez H, Berg G, et al. The human fetal placenta promotes tolerance against the semiallogeneic fetus by inducing regulatory T cells and homeostatic M2 macrophages. *J Immunol*. 2015;194(4):1534-44.
48. Boyle AK, Rinaldi SF, Norman JE, Stock SJ. Preterm birth: Inflammation, fetal injury and treatment strategies. *Journal of Reproductive Immunology*. 2017;119:62-6.
49. Iyer SS, Cheng G. Role of interleukin 10 transcriptional regulation in inflammation and autoimmune disease. *Crit Rev Immunol*. 2012;32(1):23-63.

50. Farina L, Winkelman C. A Review of the Role of Proinflammatory Cytokines in Labor and Noninfectious Preterm Labor. *Biological Research For Nursing*. 2005;6(3):230-8.
51. El-Shazly S, Makhseed Ma, Azizieh F, Raghupathy R. Increased Expression of Pro-Inflammatory Cytokines in Placentas of Women Undergoing Spontaneous Preterm Delivery or Premature Rupture of Membranes. *American Journal of Reproductive Immunology*. 2004;52(1):45-52.
52. Romero R, Espinoza J, Gonçalves LF, Kusanovic JP, Friel L, Hassan S. The Role of Inflammation and Infection in Preterm Birth. *Semin Reprod Med*. 2007;25(01):021-39.
53. Tsiartas P, Holst RM, Wennerholm UB, Hagberg H, Hougaard DM, Skogstrand K, et al. Prediction of spontaneous preterm delivery in women with threatened preterm labour: a prospective cohort study of multiple proteins in maternal serum. *BJOG*. 2012;119(7):866-73.
54. Kumar P, Venners SA, Fu L, Pearson C, Ortiz K, Wang X. Association of antenatal steroid use with cord blood immune biomarkers in preterm births. *Early Hum Dev*. 2011;87(8):559-64.
55. Pereira TB, Thomaz EB, Nascimento FR, Santos AP, Batista RL, Bettiol H, et al. Regulatory Cytokine Expression and Preterm Birth: Case-Control Study Nested in a Cohort. *PLoS One*. 2016;11(8):e0158380.
56. Gustafsson AM, Fransson E, Dubicke A, Hjelmstedt AK, Ekman-Ordeberg G, Silfverdal S-A, et al. Low levels of anti-secretory factor in placenta are associated with preterm birth and inflammation. *Acta Obstetrica et Gynecologica Scandinavica*. 2018;97(3):349-56.
57. Hillier SL, Witkin SS, Krohn MA, Watts DH, Kiviat NB, Eschenbach DA. The relationship of amniotic fluid cytokines and preterm delivery, amniotic fluid infection, histologic chorioamnionitis, and chorioamnion infection. *Obstet Gynecol*. 1993;81(6):941-8.
58. Steinborn A, Günes H, Röddiger S, Halberstadt E. Elevated placental cytokine release, a process associated with preterm labor in the absence of intrauterine infection. *Obstetrics & Gynecology*. 1996;88(4, Part 1):534-9.
59. Steinborn A, Niederhut A, Solbach C, Hildenbrand R, Sohn C, Kaufmann M. Cytokine release from placental endothelial cells, a process associated with preterm labour in the absence of intrauterine infection. *Cytokine*. 1999;11(1):66-73.
60. Romero R, Gómez R, Chaiworapongsa T, Conoscenti G, Cheol Kim J, Mee Kim Y. The role of infection in preterm labour and delivery. *Paediatric and Perinatal Epidemiology*. 2001;15(s2):41-56.
61. Srinivasan U, Misra D, Marazita ML, Foxman B. Vaginal and oral microbes, host genotype and preterm birth. *Med Hypotheses*. 2009;73(6):963-75.
62. Nakayama M. Significance of pathological examination of the placenta, with a focus on intrauterine infection and fetal growth restriction. *Journal of Obstetrics and Gynaecology Research*. 2017;43(10):1522-35.
63. Tamblin JA, Lissauer DM, Powell R, Cox P, Kilby MD. The immunological basis of villitis of unknown etiology - Review. *Placenta*. 2013;34(10):846-55.
64. Kim CJ, Romero R, Kusanovic JP, Yoo W, Dong Z, Topping V, et al. The frequency, clinical significance, and pathological features of chronic chorioamnionitis: a lesion associated with spontaneous preterm birth. *Modern Pathology*. 2010;23(7):1000-11.
65. Ito Y, Matsuoka K, Uesato T, Sago H, Okamoto A, Nakazawa A, et al. Increased expression of perforin, granzyme B, and C5b-9 in villitis of unknown etiology. *Placenta*. 2015;36(5):531-7.
66. Redline RW, Faye-Petersen O, Heller D, Qureshi F, Savell V, Vogler C, et al. Amniotic infection syndrome: Nosology and reproducibility of placental reaction patterns. *Pediatric and Developmental Pathology*. 2003;6(5):435-48.
67. Katzman PJ. Chronic Inflammatory Lesions of the Placenta and Preterm Birth. *NeoReviews*. 2016;17(2):e80-e6.
68. Maymon E, Romero R, Bhatti G, Chaemsaitong P, Gomez-Lopez N, Panaitescu B, et al. Chronic inflammatory lesions of the placenta are associated with an up-regulation of amniotic fluid CXCR3: A marker of allograft rejection. *J Perinat Med*. 2018;46(2):123-37.

69. Pandiyan P, Bhaskaran N, Zou M, Schneider E, Jayaraman S, Huehn J. Microbiome Dependent Regulation of T<sub>regs</sub> and Th17 Cells in Mucosa. *Front Immunol.* 2019;10:426.
70. Raman K, Wang H, Troncone MJ, Khan WI, Pare G, Terry J. Overlap Chronic Placental Inflammation Is Associated with a Unique Gene Expression Pattern. *PLoS one.* 2015;10(7):e0133738-e.
71. Ansel KM, Harris RBS, Cyster JG. CXCL13 Is Required for B1 Cell Homing, Natural Antibody Production, and Body Cavity Immunity. *Immunity.* 2002;16(1):67-76.
72. Legler DF, Loetscher M, Roos RS, Clark-Lewis I, Baggiolini M, Moser B. B Cell-attracting Chemokine 1, a Human CXC Chemokine Expressed in Lymphoid Tissues, Selectively Attracts B Lymphocytes via BLR1/CXCR5. *The Journal of Experimental Medicine.* 1998;187(4):655-60.
73. Chisholm KM, Norton ME, Penn AA, Heerema-McKenney A. Classification of Preterm Birth With Placental Correlates. *Pediatric and Developmental Pathology.* 2018;21(6):548-60.
74. Antony KM, Ma J, Mitchell KB, Racusin DA, Versalovic J, Aagaard K. The preterm placental microbiome varies in association with excess maternal gestational weight gain. *American Journal of Obstetrics and Gynecology.* 2015;212(5):653.e1-.e16.
75. de Goffau MC, Lager S, Sovio U, Gaccioli F, Cook E, Peacock SJ, et al. Human placenta has no microbiome but can contain potential pathogens. *Nature.* 2019;572(7769):329-+.
76. Prince AL, Ma J, Kannan PS, Alvarez M, Gisslen T, Harris RA, et al. The placental membrane microbiome is altered among subjects with spontaneous preterm birth with and without chorioamnionitis. *Am J Obstet Gynecol.* 2016;214(5):627 e1- e16.
77. Steel JH, Malatos S, Kennea N, Edwards AD, Miles L, Duggan P, et al. Bacteria and inflammatory cells in fetal membranes do not always cause preterm labor. *Pediatr Res.* 2005;57(3):404-11.
78. Stout MJ, Conlon B, Landeau M, Lee I, Bower C, Zhao Q, et al. Identification of intracellular bacteria in the basal plate of the human placenta in term and preterm gestations. *Am J Obstet Gynecol.* 2013;208(3):226.e1-7.
79. Doyle RM, Alber DG, Jones HE, Harris K, Fitzgerald F, Peebles D, et al. Term and preterm labour are associated with distinct microbial community structures in placental membranes which are independent of mode of delivery. *Placenta.* 2014;35(12):1099-101.
80. Han YW. Oral Health and Adverse Pregnancy Outcomes - What's Next? *Journal of Dental Research.* 2011;90(3):289-93.
81. Vander Haar EL, So J, Gyamfi-Bannerman C, Han YW. *Fusobacterium nucleatum* and adverse pregnancy outcomes: Epidemiological and mechanistic evidence. *Anaerobe.* 2018;50:55-9.
82. Doyle RM, Harris K, Kamiza S, Harjunmaa U, Ashorn U, Nkhoma M, et al. Bacterial communities found in placental tissues are associated with severe chorioamnionitis and adverse birth outcomes. *PLoS One.* 2017;12(7):23.
83. Theis KR, Romero R, Winters AD, Greenberg JM, Gomez-Lopez N, Alhousseini A, et al. Does the human placenta delivered at term have a microbiota? Results of cultivation, quantitative real-time PCR, 16S rRNA gene sequencing, and metagenomics. *American Journal of Obstetrics and Gynecology.* 2019;220(3):267.e1-.e39.
84. Leon LJ, Doyle R, Diez-Benavente E, Clark TG, Klein N, Stanier P, et al. Enrichment of Clinically Relevant Organisms in Spontaneous Preterm-Delivered Placentas and Reagent Contamination across All Clinical Groups in a Large Pregnancy Cohort in the United Kingdom. *Applied and Environmental Microbiology.* 2018;84(14):e00483-18.
85. Leiby JS, McCormick K, Sherrill-Mix S, Clarke EL, Kessler LR, Taylor LJ, et al. Lack of detection of a human placenta microbiome in samples from preterm and term deliveries. *Microbiome.* 2018;6.
86. Lauder AP, Roche AM, Sherrill-Mix S, Bailey A, Laughlin AL, Bittinger K, et al. Comparison of placenta samples with contamination controls does not provide evidence for a distinct placenta microbiota. *Microbiome.* 2016;4.

87. Salter SJ, Cox MJ, Turek EM, Calus ST, Cookson WO, Moffatt MF, et al. Reagent and laboratory contamination can critically impact sequence-based microbiome analyses. *BMC Biol.* 2014;12:87.
88. Buhimschi CS, Dulay AT, Abdel-Razeq S, Zhao G, Lee S, Hodgson EJ, et al. Fetal inflammatory response in women with proteomic biomarkers characteristic of intra-amniotic inflammation and preterm birth. *BJOG : an international journal of obstetrics and gynaecology.* 2009;116(2):257-67.
89. Neilands JB. Siderophores: Structure and Function of Microbial Iron Transport Compounds. *Journal of Biological Chemistry.* 1995;270(45):26723-6.
90. Witkin S, Linhares I. Why do lactobacilli dominate the human vaginal microbiota? *BJOG: An International Journal of Obstetrics & Gynaecology.* 2017;124(4):606-11.
91. Alwan NA, Greenwood DC, Simpson NAB, McArdle HJ, Cade JE. The relationship between dietary supplement use in late pregnancy and birth outcomes: a cohort study in British women. *BJOG : an international journal of obstetrics and gynaecology.* 2010;117(7):821-9.
92. Mantovani E, Filippini F, Bortolus R, Franchi M. Folic acid supplementation and preterm birth: results from observational studies. *Biomed Res Int.* 2014;2014:481914-.
93. Goldenberg RL, Culhane JF, Iams JD, Romero R. Epidemiology and causes of preterm birth. *The Lancet.* 2008;371(9606):75-84.
94. Ananth CV, Vintzileos AM. Maternal-fetal conditions necessitating a medical intervention resulting in preterm birth. *American Journal of Obstetrics and Gynecology.* 2006;195(6):1557-63.
95. Manuck TA, Esplin MS, Biggio J, Bukowski R, Parry S, Zhang H, et al. The phenotype of spontaneous preterm birth: application of a clinical phenotyping tool. *American Journal of Obstetrics and Gynecology.* 2015;212(4):487.e1-.e11.