



Deposited via The University of Sheffield.

White Rose Research Online URL for this paper:

<https://eprints.whiterose.ac.uk/id/eprint/160251/>

Version: Accepted Version

Article:

Semeraro, A., Kemp, E.H., Pardi, E. et al. (2020) Late-onset postsurgical hypoparathyroidism following parathyroidectomy for recurrent primary hyperparathyroidism : a case report and literature review. *Endocrine*, 69 (2). pp. 402-409. ISSN: 1355-008X

<https://doi.org/10.1007/s12020-020-02344-y>

This is a post-peer-review, pre-copyedit version of an article published in *Endocrine*. The final authenticated version is available online at: <https://doi.org/10.1007/s12020-020-02344-y>

Reuse

Items deposited in White Rose Research Online are protected by copyright, with all rights reserved unless indicated otherwise. They may be downloaded and/or printed for private study, or other acts as permitted by national copyright laws. The publisher or other rights holders may allow further reproduction and re-use of the full text version. This is indicated by the licence information on the White Rose Research Online record for the item.

Takedown

If you consider content in White Rose Research Online to be in breach of UK law, please notify us by emailing eprints@whiterose.ac.uk including the URL of the record and the reason for the withdrawal request.

[Click here to view linked References](#)

1 1 **Late-onset postsurgical hypoparathyroidism following parathyroidectomy**
2
3
4 2 **for recurrent primary hyperparathyroidism: a case report and literature**
5
6 3 **review**
7
8
9

10 4

11
12
13 5 Antonella Semeraro¹, Elizabeth Helen Kemp, ² Elena Pardi¹, Agostino Di Certo¹, Claudio
14
15 6 Marcocci¹, Filomena Cetani³
16
17

18
19 7 ¹Department of Clinical and Experimental Medicine, University of Pisa, Pisa, Italy
20
21

22 8 ²Department of Oncology and Metabolism, University of Sheffield, Sheffield, UK
23
24

25 9 ³University Hospital of Pisa, Endocrine Unit 2, Pisa, Italy
26
27
28

29 10

30
31
32 11 **Concise title: Late-onset postsurgical hypoparathyroidism**
33
34

35
36 12

37
38
39 13 **Keywords:** hyperparathyroidism-jaw tumor syndrome, CDC73, parafibromin,
40
41 14 parathyroidectomy
42
43

44
45 15 **Corresponding author:**
46
47

48 16 Dr Filomena Cetani, MD, PhD, University Hospital of Pisa, Endocrine Unit 2, Via Paradisa 2,
49
50 17 56124 Pisa, Italy.
51
52

53
54 18 Phone: +39050995040; Fax: +39050996551; E-mail: cetani@endoc.med.unipi.it
55
56
57
58
59
60
61

19 **Abstract**

20 **Purpose** Previously in 1987, a 21-year-old-male was diagnosed with primary
21 hyperparathyroidism (PHPT) when a right inferior parathyroid adenoma was removed. PHPT
22 recurred after three and six years and on both occasions was cured by resection of parathyroid
23 adenomas. At 52-years-of-age, the patient developed a late-onset hypoparathyroidism (HP),
24 even though postsurgical HP typically occurs as a transient or permanent form soon after neck
25 surgery. The purpose of this work was to report the follow-up of the patient and to review prior
26 cases of late-onset postsurgical HP.

27 **Methods** Prior cases of late-onset postsurgical HP were searched and reviewed focusing on
28 clinical and biochemical features.

29 **Results** The patient's asymptomatic hypocalcemia with total serum calcium at 8.2 mg/dL was
30 initially documented in September 2018; PTH was inappropriately low at 15 ng/mL. In
31 February 2020, a mild hypocalcemia was confirmed with low-normal PTH at 15 ng/mL.
32 Autoimmune and familial causes of HP were ruled out including the presence of stimulating
33 autoantibodies against calcium-sensing receptor. Instead, a progressive damage or atrophy of
34 the parathyroid gland(s) ensuing years after surgery is believed to have led to the patient's
35 hypocalcemia. All 19 previously reported cases of late-onset postsurgical HP occurred after
36 thyroid surgery, with no examples of the condition being found following parathyroidectomy.

37 **Conclusions** The case highlights the rare occurrence of late-onset postsurgical HP in a patient
38 who had had multiple parathyroidectomies for PHPT. Thus, monitoring serum calcium,
39 phosphate and PTH during follow-up of such patients is recommended.

40

1
2
3
4
5
6
7
8
9
10
11
12
13
14
15
16
17
18
19
20
21
22
23
24
25
26
27
28
29
30
31
32
33
34
35
36
37
38
39
40
41
42
43
44
45
46
47
48
49
50
51
52
53
54
55
56
57
58
59
60
61
62
63
64
65

41 Introduction

42 Postsurgical hypoparathyroidism (HP) may occur after total thyroidectomy or radical neck
43 dissection and is caused by inadvertent removal of parathyroid glands and/or the irreversible
44 damage of their blood supply [1, 2]. The resulting reduced or absent production of PTH leads
45 to hypocalcemia either because of the lack of mobilization of calcium and phosphate from the
46 skeleton or synthesis of calcitriol due to impaired or absent renal hydroxylation of serum 25-
47 hydroxyvitamin D [1]. In addition, reduced PTH lowers reabsorption of calcium and secretion
48 of phosphate in renal tubular cells. Postsurgical HP may occur transiently when hypocalcemia
49 persists for less than six months or permanently when hypocalcemia persists for more than six
50 and upto 12 months after surgery in the presence of low or inappropriately normal PTH levels
51 [1, 2].

52 Transient hypocalcemia is not uncommon in the post-operative period after parathyroidectomy
53 in patients with primary hyperparathyroidism (PHPT) caused by the delayed functional
54 recovery of the remaining parathyroid glands and the inhibition of PTH secretion by prior
55 hypercalcemia [2, 3]. The biochemical signature is also characterized by high or elevated serum
56 phosph~~ate~~ and low or undetectable PTH. Another form of hypocalcemia, the so-called hungry
57 bone syndrome, may follow parathyroidectomy, mainly in patients with severe PHPT and
58 preoperative high bone turnover, **due to rapid remineralization of bone** [4].
59 Parathyroidectomy usually rapidly decreases bone **resorption**. However, in hungry bone
60 syndrome, the rate of bone formation remains elevated for several weeks, with increased
61 calcium influx in bone and the development of persistent hypocalcemia that requires treatment
62 with calcium and **active** vitamin D [4]. In these patients, the biochemical signature is also
63 characterized by elevated serum PTH associated with hypophosphatemia and hypomagnesemia.

1
2
3
4
5
6
7
8
9
10
11
12
13
14
15
16
17
18
19
20
21
22
23
24
25
26
27
28
29
30
31
32
33
34
35
36
37
38
39
40
41
42
43
44
45
46
47
48
49
50
51
52
53
54
55
56
57
58
59
60
61
62
63
64
65

64 Late-onset postsurgical HP is a rare condition which has been shown to develop several years
65 after thyroid surgery [3, 5–18]. Symptoms of hypocalcemia may be latent and mild and very
66 rarely sever [3, 5, 11–13]. The underlying mechanism of the late-onset postsurgical HP is
67 unclear and may be due to progressive damage or atrophy of the parathyroid glands leading to
68 their insufficiency years after surgery. To our knowledge, no case of late-onset postsurgical HP
69 has been described so far in patients with PHPT after parathyroidectomy.

70 Herein, the follow-up is described of a patient with apparently sporadic recurrent PHPT
71 carrying a germline mutation of the *CDC73* gene who had undergone **three subsequent**
72 **parathyroidectomies** with resection of four parathyroid adenomas [19]. Over time, the patient
73 gradually developed a late-onset postsurgical HP. Prior cases of late-onset postsurgical HP,
74 with particular focus on the clinical and biochemical features of this rare condition, are also
75 summarised.

76 **Materials and Methods**

77 **Patient history**

78 The detailed medical history of the patient has been reported in a prior publication [19]. The
79 relevant clinical details are briefly reported here. The patient was first diagnosed with PHPT in
80 1987 at the age of 21 years with a total serum calcium of 17.3 mg/dL (normal range, 8.6-10.2
81 mg/dL) and a C-PTH level of 3.17 ng/mL (normal, <0.88 ng/mL). In the same year, the patient
82 underwent right inferior parathyroidectomy. In 1990, a relapse of PHPT was diagnosed and
83 successfully cured in 1993 by right superior parathyroidectomy. The patient was referred to
84 our outpatient clinic in 1998 for recurrent PHPT. His total serum calcium and PTH were mildly
85 elevated at 10.6 mg/dL and 72 ng/L (normal range, 10–65 ng/L), respectively. In March 2004,
86 a further relapse of PHPT was evident. The patient’s total and ionized serum calcium were 12.2
87 mg/dL and 1.75 mmol/L (normal range, 1.12-1.32 mmol/L), respectively, and a PTH level of
88 260 ng/L. The patient underwent surgical neck exploration and subsequent superior and inferior
89 left parathyroidectomy. Histological examination of the excised parathyroids showed chief cell
90 adenomas. Subsequent genetic analysis identified a germline mutation of the *CDC73* gene
91 (encodes the tumor suppressor parafibromin) in exon 3 (R91P), and the loss of parafibromin
92 expression was implicated in the development of the benign parathyroid tumors. **Following**
93 **the identification of the *CDC73* gene mutation which are responsible for**
94 **hyperparathyroidism-jaw tumor syndrome, a re-evaluation of all parathyroid**
95 **histological sections was carried out by our pathologist in order to exclude atypical or**
96 **malignant features that can be present in this setting [20]. However, histology did not**
97 **reveal the presence of atypical features (i.e solid growth pattern, fibrous bands and**
98 **cellular atypia) and histologic features suggestive of potential malignancy.**

1
2
3
4
5
6
7
8
9
10
11
12
13
14
15
16
17
18
19
20
21
22
23
24
25
26
27
28
29
30
31
32
33
34
35
36
37
38
39
40
41
42
43
44
45
46
47
48
49
50
51
52
53
54
55
56
57
58
59
60
61
62
63
64
65

99 **Furthermore, since patients carrying *CDC73* mutations might develop**
100 **mandibular/maxillary fibrous tumors and kidney tumors, a radiologic** evaluation of the
101 jaw and an abdomen ultrasound were undertaken, but these excluded the presence of tumor
102 lesions. Following the final parathyroidectomy, the patient had a transient hypocalcemia after
103 which ionized serum calcium remained within the normal range until March 2006 (Table 1).
104 PTH also remained within the normal range except for a slight elevation to 68 ng/L in March
105 2005 (Table 1).

106 **Calcium-sensing receptor (CaSR) immunoprecipitation assays**

107 Immunoprecipitation assays used to detect CaSR antibodies were undertaken as detailed
108 elsewhere [21]. Briefly, HEK293 cells were transiently transfected with pcCaSR-FLAG.
109 GammaBind[®] Sepharose beads (50- μ l samples) (GE Healthcare, Little Chalfont, UK) were
110 mixed with sera at a 1:100 dilution and incubated at 4°C for 1 h. The beads and IgG complexes
111 were collected and incubated with cell extract containing CaSR-FLAG protein for 16 h at 4°C,
112 then collected and subjected to SDS-PAGE and immunoblotting using anti-FLAG[®] M2-
113 Peroxidase Conjugate (Sigma-Aldrich, Poole, UK) and an ECL[™] Western Blotting Analysis
114 System (GE Healthcare). The densitometry of bands was performed in a Bio-Rad GS 690
115 Scanning Densitometer with Multi-Analyst Software (Bio-Rad Laboratories Ltd., Hemel
116 Hempstead, UK). A CaSR antibody index for each serum sample was calculated as the
117 densitometry value of the tested serum/mean densitometry value of 10 control sera. The upper
118 normal limit for the assay was calculated using the mean CaSR antibody index + 3 SD of 10
119 controls and was a value of 2.78.

120 121 **Systematic review of late-onset postsurgical HP cases**

122 A systematic Pubmed search focused on late-onset postsurgical HP was undertaken. The
1
2 following keywords were used for the search: “late-onset hypoparathyroidism”, “late-onset
3
4 hypocalcemia”, “post surgical hypoparathyroidism”, “post surgical hypocalcemia”, “delayed
5
6 hypoparathyroidism”, “post thyroidectomy hypoparathyroidism”, “post parathyroidectomy
7
8 hypocalcemia”, “iatrogenic hypoparathyroidism”, and “post thyroidectomy basal ganglia
9
10
11
12
13
14
15
16
17
18
19
20
21
22
23
24
25
26
27
28
29
30
31
32
33
34
35
36
37
38
39
40
41
42
43
44
45
46
47
48
49
50
51
52
53
54
55
56
57
58
59
60
61
62
63
64
65

129

130

131 **Results**

132 **Case follow-up**

133 Since *CDC73* mutation carriers are at risk for recurrence of PHPT or parathyroid cancer,
134 regular follow-up was mandatory in this patient. Frequent surveillance may allow an early
135 detection and cure of PHPT, before a possible development of malignancy [19].

136 Between March 2006 and July 2008, a relapse of the patient's PHPT was suspected because of
137 the finding that at yearly evaluation there was a slightly elevated ionized serum calcium
138 associated with PTH levels at the upper limit of the normal range (Table 1). No kidney stones
139 or nephrocalcinosis were present. Bone mineral density confirmed a reduced bone mass at one-
140 third distal radius which was comparable with that found in 2004. Neck ultrasound and a
141 sestamibi scan were negative. In May 2009, the patient was further evaluated, and at this time
142 total and ionized serum calcium and PTH, as well as 24-h urinary calcium (normal range, 100-
143 300 mg/24-h), were within the normal ranges. The subsequent follow-ups were notable for the
144 progressive reduction, although still in the normal range, of total and ionized serum calcium
145 and PTH levels (Table 1).

146 In September 2018, the patient was in good health and asymptomatic. The patient's recent
147 medical history was notable for the presence of arterial hypertension for which he was taking
148 zofenopril. The patient was also taking cholecalciferol (25,000 IU monthly). Physical
149 examination was negative except the presence of neck scars. Chvostek and Trousseau signs
150 were negative. Total serum and ionized calcium were low at 8.2 mg/dL and 1.07 mmol/L,
151 respectively (Figure 1). PTH was inappropriately low-normal at 15 ng/L (Figure 1). Serum
152 phosphate at 2.9 mg/dL (normal range, 2.5-4.5 mg/dL), magnesium at 2.1 mg/dL (normal
153 range, 1.7-2.2 mg/dL), creatinine at 1.11 mg/dL (normal range, 0.5 to 1.2 mg/dL), and urinary
154 calcium at 144 mg/24-h were normal. Serum 25-hydroxyvitamin D level was elevated at 57.4

155 ng/mL (normal range, 20-50 ng/mL). Alkaline phosphatase and liver function tests were
156 normal. Neck and abdomen ultrasounds did not reveal any tumor lesions. No autoimmune
157 disorders were present. Given that there was no evidence of any other disease contributing to
158 the patient's hypocalcemia, and no family history of HP, a diagnosis of postsurgical HP was
159 made. Since symptoms and signs of hypocalcemia were absent, no treatment was advised.

160 In February 2020, laboratory tests confirmed a mild hypocalcemia. Total serum and ionized
161 calcium were low at 7.9 mg/dL and 0.98 mmol/L, respectively (Figure 1). PTH levels were
162 inappropriately low-normal at 15 ng/L (Figure 1). Serum phosphate and magnesium were
163 normal at 3.8 mg/dL and 2.0 mg/dL, respectively. Urinary calcium was normal 102 mg/24-h.
164 Renal function was also normal. Serum 25-hydroxyvitamin D was normal at 39 ng/mL while
165 receiving cholecalciferol (25,000 IU monthly). Electrocardiogram (ECG) did not show
166 prolongation of QT interval. Abdomen ultrasound was negative for kidney stones and
167 nephrocalcinosis. Chest x-ray was normal. No hyperparathyroidism-jaw tumor syndrome-
168 related tumors were present. The patient was in good health and had no symptoms or signs of
169 hypocalcemia, thus, no specific treatment was advised.

170 **CaSR autoantibody analysis**

171 Normally, the CaSR controls serum calcium levels via PTH secretion from the parathyroid
172 keeping the calcium concentration within a very tight range. In rare cases autoantibodies
173 against the receptor can cause primary hypoparathyroidism [21]. In such cases, CaSR
174 autoantibodies stimulate the receptor so that even at lower than optimum calcium levels PTH
175 secretion from the parathyroid glands is reduced. However, the patient was negative for CaSR
176 autoantibodies with an antibody index of 0.98.

178 **Review of the literature for postsurgical HP**

179 A total of 19 relevant articles were retrieved for systematic review. Four were excluded due to
180 the lack of a full-text article, so that 15 studies were included and reviewed [3, 5–18]. The
181 results are in Table 2. All cases of late-onset postsurgical HP occurred after thyroid surgery,
182 with no examples of the condition being found following parathyroidectomy.

183

184 **Discussion**

1
2
3 185 Acquired HP is usually caused by inadvertent removal of the parathyroid glands or damage of
4
5 186 their blood supply during thyroid surgery. Indeed, postsurgical HP is the most common
6
7
8 187 complication of total or near-total thyroidectomy [2]. More rarely, it can be caused by the
9
10 188 excision of too much parathyroid tissue during surgery for PHPT. Other rare causes include
11
12
13 189 hemochromatosis, sarcoidosis, hemosiderosis, Wilson's disease, and metastatic infiltration of
14
15 190 the parathyroid gland [1].
16
17

18
19 191 Given the clinical history of the patient who carried a germline mutation of the *CDC73* gene
20
21 192 leading to recurrent PHPT [19], we unexpectedly observed a late-onset postsurgical HP rather
22
23
24 193 than a possible and foreseeable recurrence of PHPT. Of note, three years after the last
25
26 194 parathyroidectomy, **leading to completion of (sub)total parathyroidectomy**, a slight increase
27
28 195 of ionized serum calcium and inappropriately normal PTH levels were observed in the absence
29
30
31 196 of enlarged parathyroid gland(s) at neck imaging. This biochemical picture raised the suspicion
32
33 197 for a further recurrence of PHPT supporting the concept that, in this setting, all parathyroid
34
35
36 198 tissue may continue to proliferate overtime [1, 19]. However, a subsequent normocalcemia was
37
38 199 evident. **The former and latter findings were consistent with the presence of a**
39
40
41 200 **supernumerary parathyroid gland. Otherwise, it could be speculated that the patient**
42
43 201 **might have a small amount of malignant parathyroid tissue in the site of the first surgery**
44
45 202 **which was carried-out elsewhere and not-re-explored at the last surgery able to maintain**
46
47
48 203 **normocalcemia. However, the revision of all histological sections of the right-side tumors**
49
50 204 **by our pathologist showed no histological features of malignancy [19]. Thus, we can**
51
52
53 205 **speculate that the function of the supernumerary parathyroid gland remained almost**
54
55 206 **normal for a given period of time and then progressively decreased due to its damage or**
56
57
58 207 **atrophy. The question of whether other factors (i.e. environmental) might have**
59
60 208 **contributed to this condition remains unclear.**
61
62
63
64
65

1
2
3
4
5
6
7
8
9
10
11
12
13
14
15
16
17
18
19
20
21
22
23
24
25
26
27
28
29
30
31
32
33
34
35
36
37
38
39
40
41
42
43
44
45
46
47
48
49
50
51
52
53
54
55
56
57
58
59
60
61
62
63
64
65

209 However, during follow-up, serum calcium slowly decreased over the years until a mild
210 asymptomatic hypocalcemia with inappropriately low-normal PTH levels was evident.

211 Potential causes of hypocalcemia **including hypomagnesemia** were ruled out; the patient did
212 not have autoimmune disorders or a family history of autoimmunity [22], family members did
213 not have a history of hypocalcemia ruling out a genetic cause [23], and the patient was negative
214 for autoantibodies to the CaSR [21, 22], a molecule that controls serum calcium levels via PTH
215 secretion from the parathyroid gland. When HP gradually develops, as in non-surgical acquired
216 forms, patients are usually asymptomatic, reflecting a sort of adaptation to a progressive decline
217 of serum calcium [2, 18]. In line with this, our patient did not experience symptoms or signs of
218 hypocalcemia over the years, so we suggest that the residual parathyroid gland, which kept the
219 patient normocalcemic for 14 years, underwent progressive damage until HP developed.

220 To date, 19 cases of late-onset postsurgical HP have been reported and all occurred after thyroid
221 surgery [3, 5–18]. The first case was described in 1962 by Blanchard et al. who described a 59-
222 year-old male patient presenting with hypocalcemia 33 years after thyroidectomy [5]. This
223 patient was admitted to the University Hospital because of “jerking of his right arm and leg”
224 and a recent history of seizures. Laboratory tests showed a severe hypocalcemia and
225 hyperphosphatemia. ECG showed QT-interval prolongation. At the time of hospital admission
226 focal seizures occurred every 15 minutes and they disappeared after one day of intravenously
227 calcium therapy.

228 Eighteen patients with late-onset postsurgical HP have since been reported. Four occurred after
229 subtotal thyroidectomy and 15 after total thyroidectomy (Table 2). The age at diagnosis varied
230 considerably from nine months to 41 years with a higher prevalence in females than males (15
231 vs 4), an expected figure considering that thyroid disease is more prevalent in the former. In
232 nine patients, the diagnosis was made more than 20 years after surgery with a mean time of

1
2
3 234 HP was evident within 20 years of surgery with a mean time of 10.1 ± 7.44 years (range, nine
4
5 235 months-19 years) [3, 9, 11, 12, 14, 16, 17]. The mean age at diagnosis was 54.5 ± 13.8 years
6
7
8 236 (range, 24-76 years). In female patients, this was 54.5 ± 14.62 years (range, 24-76 years) and,
9
10 237 in males, 54.2 ± 12.14 years (range, 42-69 years).

11
12
13
14 238 Ten of 19 (52.6%) patients experienced severe symptoms of hypocalcemia that required
15
16 239 hospitalization. The medical history of these patients was characterized by seizures which were
17
18
19 240 evident for many years or just a few months [11–14, 17, 18]. Conversely, four of the 19 (21.1%)
20
21 241 patients had a history of cramps or tingling in the limbs. In the remaining cases, the medical
22
23 242 history was not available. Finally, in six cases (31.6%), computed tomography (CT) scans
24
25
26 243 showed the presence of bilateral and extended brain calcifications, that in HP are located most
27
28 244 often in basal ganglia. Patients with brain calcifications usually had a late diagnosis after
29
30
31 245 surgery (range, 10-41 years).

32
33
34 246 In conclusion, this case highlights the rare occurrence of late-onset postsurgical HP in a patient
35
36 247 who had had multiple parathyroidectomies for PHPT as well as in patients with previous
37
38
39 248 thyroidectomy, particularly if total. Although hypocalcemia typically occurs in the immediate
40
41 249 postoperative period, progressive damage or atrophy of the parathyroid gland(s) may ensue
42
43
44 250 years after surgery leading to blood calcium and PTH insufficiency. Thus, serum calcium,
45
46 251 phosphate and PTH should be monitored during follow-up in patients who have had previous
47
48
49 252 neck surgery to identify and eventually treat such patients.

50
51
52 253

53
54
55 254 **Acknowledgments** The authors wish to thank the patient involved in the study who graciously
56
57
58 255 agreed to collaborate in the study. We also thank Mrs Laura Macrì for her help in searching for
59
60 256 the articles for the review of the literature.

257 **Author contributions** A.S. and F.C. planned the study. E.H.K. performed the search for
258 calcium-sensing receptor antibodies and revised the manuscript. E.P. and A.D.C. collected the
259 clinical data. C.M. revised the manuscript. A.S and F.C. wrote the manuscript. All authors
260 discussed the results.

261 **Compliance with Ethical Standards**

262 **Conflict of interest** The authors declare that there is no conflict of interest.

263 **Informed consent** Informed consent was obtained from the patient for publication of this case.

264

265

266 **References**

- 267 1. Bilezikian, J.P., Marcus, R., Levine, M.A.: *The Parathyroids: Basic and Clinical*
268 *Concepts: Third Edition.* (2014). <https://doi.org/10.1016/C2011-0-07346-5>.
- 269 2. Kakava, K., Tournis, S., Papadakis, G., Karelas, I., Stampouloglou, P., Kassi, E.,
270 Triantafillopoulos, I., Villiotou, V., Karatzas, T.: Postsurgical Hypoparathyroidism: A
271 Systematic Review. *In Vivo.* 30, 171–179 (2016).
- 272 3. Simões, C.A., Costa, M.K., Comerlato, L.B., Ogusco, A.A., Araújo Filho, V.,
273 Dedivitis, R.A., Cernea, C.R.: A Case of “Late” Postsurgical Hypoparathyroidism.
274 *Case Rep. Endocrinol.* (2017). <https://doi.org/10.1155/2017/3962951>.
- 275 4. Witteveen, J.E., van Thiel, S., Romijn, J.A., Hamdy, N.A.: Hungry bone syndrome:
276 still a challenge in the post-operative management of primary hyperparathyroidism: a
277 systematic review of the literature. *Eur. J. Endocrinol.* 168, 45–53 (2013).
278 <https://doi.org/10.1530/EJE-12-0528>.

1
2
3
4
5
6
7
8
9
10
11
12
13
14
15
16
17
18
19
20
21
22
23
24
25
26
27
28
29
30
31
32
33
34
35
36
37
38
39
40
41
42
43
44
45
46
47
48
49
50
51
52
53
54
55
56
57
58
59
60
61
62
63
64
65

279 5. Blanchard BM: Focal hypocalcemic seizures 33 years after thyroidectomy. Arch Intern
280 Med. (1962).

281 6. Petch CP: Hypoparathyroidism presenting with convulsions twenty-seven years after
282 thyroidectomy. Lancet. (1963).

283 7. Bull, D.M., Dillihunt, R.C.: Hypoparathyroidism Presenting With Convulsions 28
284 Years After Thyroidectomy. JAMA J. Am. Med. Assoc. 193, 308–309 (1965).
285 <https://doi.org/10.1001/jama.1965.03090040052020>.

286 8. Jorens, P.G., Appel, B.J., Hilte, F.A., Mahler, C., De Deyn, P.P.: Basal ganglia
287 calcifications in postoperative hypoparathyroidism: a case with unusual characteristics.
288 Acta Neurol. Scand. 83, 137–140 (1991). <https://doi.org/10.1111/j.1600-0404.1991.tb04663.x>.

290 9. GARG, M., MOHAPATRA, A., SINGH, A., SAINI, J.: Delayed Onset of
291 Postthyroidectomy Hypoparathyroidism. Med. J. Armed Forces India. 55, 157–158
292 (1999). [https://doi.org/10.1016/s0377-1237\(17\)30277-0](https://doi.org/10.1016/s0377-1237(17)30277-0).

293 10. Lang, C., Huk, W., Pichl, J.: Comparison of extensive brain calcification in
294 postoperative hypoparathyroidism on CT and NMR scan. Neuroradiology. 31, 29–32
295 (1989). <https://doi.org/10.1007/BF00342026>.

296 11. Cox, R.E.: Hypoparathyroidism: An unusual cause of seizures. Ann. Emerg. Med. 12,
297 314–315 (1983). [https://doi.org/10.1016/S0196-0644\(83\)80517-4](https://doi.org/10.1016/S0196-0644(83)80517-4).

298 12. Halperin, I., Nubiola, A., Vendrell, J., Vilardell, E.: Late-onset hypocalcemia
299 appearing years after thyroid surgery. J. Endocrinol. Invest. 12, 419–420 (1989).
300 <https://doi.org/10.1007/BF03350718>.

301 13. Bellamy, R.J., Kendall-Taylor, P.: Unrecognized hypocalcaemia diagnosed 36 years
 1
 2 302 after thyroidectomy. *J. R. Soc. Med.* 88, 690–691 (1995).
 3
 4
 5 303 <https://doi.org/10.1177/014107689508801210>.
 6
 7
 8 304 14. Mrowka, M., Knake, S., Klinge, H., Odin, P., Rosenow, F.: Hypocalcemic generalised
 9
 10 305 seizures as a manifestation of iatrogenic hypoparathyroidism months to years after
 11
 12 306 thyroid surgery. *Epileptic Disord.* 6, 85–87 (2004).
 13
 14
 15
 16 307 15. Adorni, A., Lussignoli, G., Geroldi, C., Zanetti, O.: Extensive brain calcification and
 17
 18 308 dementia in postsurgical hypoparathyroidism. *Neurology.* 65, 1501 (2005).
 19
 20
 21 309 <https://doi.org/10.1212/01.wnl.0000182293.34015.a9>.
 22
 23
 24 310 16. Zisimopoulou, V., Siatouni, A., Tsoukalos, G., Tavernarakis, A., Gatzonis, S.:
 25
 26 311 Extensive bilateral intracranial calcifications: A case of iatrogenic
 27
 28 312 hypoparathyroidism. *Case Rep. Med.* 2013, 8–11 (2013).
 29
 30 313 <https://doi.org/10.1155/2013/932184>.
 31
 32
 33
 34 314 17. Agarwal, R., Lahiri, D., Biswas, A., Mukhopadhyay, J., Maity, P., Roy, M.K.: A rare
 35
 36 315 cause of seizures, Parkinsonian, And cerebellar signs: Brain calcinosis secondary to
 37
 38 316 thyroidectomy. *N. Am. J. Med. Sci.* 6, 540–542 (2014). [https://doi.org/10.4103/1947-](https://doi.org/10.4103/1947-2714.143287)
 39
 40
 41 317 [2714.143287](https://doi.org/10.4103/1947-2714.143287).
 42
 43
 44
 45 318 18. Kamath, S.D., Rao, B.S.: Delayed post-surgical hypoparathyroidism: The forgotten
 46
 47 319 chameleon! *J. Clin. Diagnostic Res.* 11, OD07–OD09 (2017).
 48
 49 320 <https://doi.org/10.7860/JCDR/2017/23609.9260>.
 50
 51
 52
 53 321 19. Cetani, F., Pardi, E., Ambrogini, E., Viacava, P., Borsari, S., Lemmi, M., Cianferotti,
 54
 55 322 L., Miccoli, P., Pinchera, A., Arnold, A., Marcocci, C.: Different somatic alterations of
 56
 57 323 the HRPT2 gene in a patient with recurrent sporadic primary hyperparathyroidism
 58
 59
 60
 61
 62
 63
 64
 65

- 324 carrying an HRPT2 germline mutation. *Endocr. Relat. Cancer.* 14, 493–499 (2007).
1
2
3 325 <https://doi.org/10.1677/ERC-06-0092>.
4
5
6 326 20. Cetani, F., Marcocci, C., Torregrossa, L., Pardi, E.: Atypical parathyroid adenomas:
7
8 327 Challenging lesions in the differential diagnosis of endocrine tumors. *Endocr. Relat.*
9
10 328 *Cancer.* 26, R441–R464 (2019). <https://doi.org/10.1530/ERC-19-0135>.
11
12
13
14 329 21. Gavalas, N.G., Kemp, E.H., Krohn, K.J.E., Brown, E.M., Watson, P.F., Weetman,
15
16 330 A.P.: The calcium-sensing receptor is a target of autoantibodies in patients with
17
18 331 autoimmune polyendocrine syndrome type 1. *J. Clin. Endocrinol. Metab.* 92, 2107–
19
20
21 332 2114 (2007). <https://doi.org/10.1210/jc.2006-2466>.
22
23
24 333 22. Kifor, O., Mcelduff, A., Leboff, M.S., Moore, F.D., Butters, R., Gao, P., Cantor, T.L.,
25
26
27 334 Kifor, I., Brown, E.M.: Activating Antibodies to the Calcium-Sensing Receptor in
28
29 335 Two Patients with Autoimmune Hypoparathyroidism. *J. Clin. Endocrinol. Metab.* 89,
30
31
32 336 548–556 (2004). <https://doi.org/10.1210/jc.2003-031054>.
33
34
35 337 23. Bilezikian, J.P., Khan, A., Potts, J.T., Brandi, M.L., Clarke, B.L., Shoback, D.,
36
37 338 Jüppner, H., D’Amour, P., Fox, J., Rejnmark, L., Mosekilde, L., Rubin, M.R.,
38
39
40 339 Dempster, D., Gafni, R., Collins, M.T., Sliney, J., Sanders, J.: Hypoparathyroidism in
41
42 340 the adult: Epidemiology, diagnosis, pathophysiology, target-organ involvement,
43
44
45 341 treatment, and challenges for future research. *J. Bone Miner. Res.* 26, 2317–2337
46
47 342 (2011). <https://doi.org/10.1002/jbmr.483>.
48
49
50
51 343

344 **Figure legend**

1
2
3 345 **Fig. 1** Time-course of serum calcium and PTH concentrations in the patient. The normal range
4
5 of serum calcium is 8.6-10.2 mg/dL. The normal range of PTH (2nd generation assay) is 10-65
6 346
7
8 347 ng/L from 2012 to 2014, and 8-40 ng/L (3rd generation assay) thereafter.
9

10
11 348

12
13 349

14
15 350

16
17 351

18
19 352

20
21 353

22
23 354

24
25 355

26
27 356

28
29 357

30
31 358

32
33 359

34
35 360

36
37 361

38
39 362

40
41 363

42
43 364

44
45 365

46
47 366

48
49 367

50
51 368

52
53 369

54
55 370

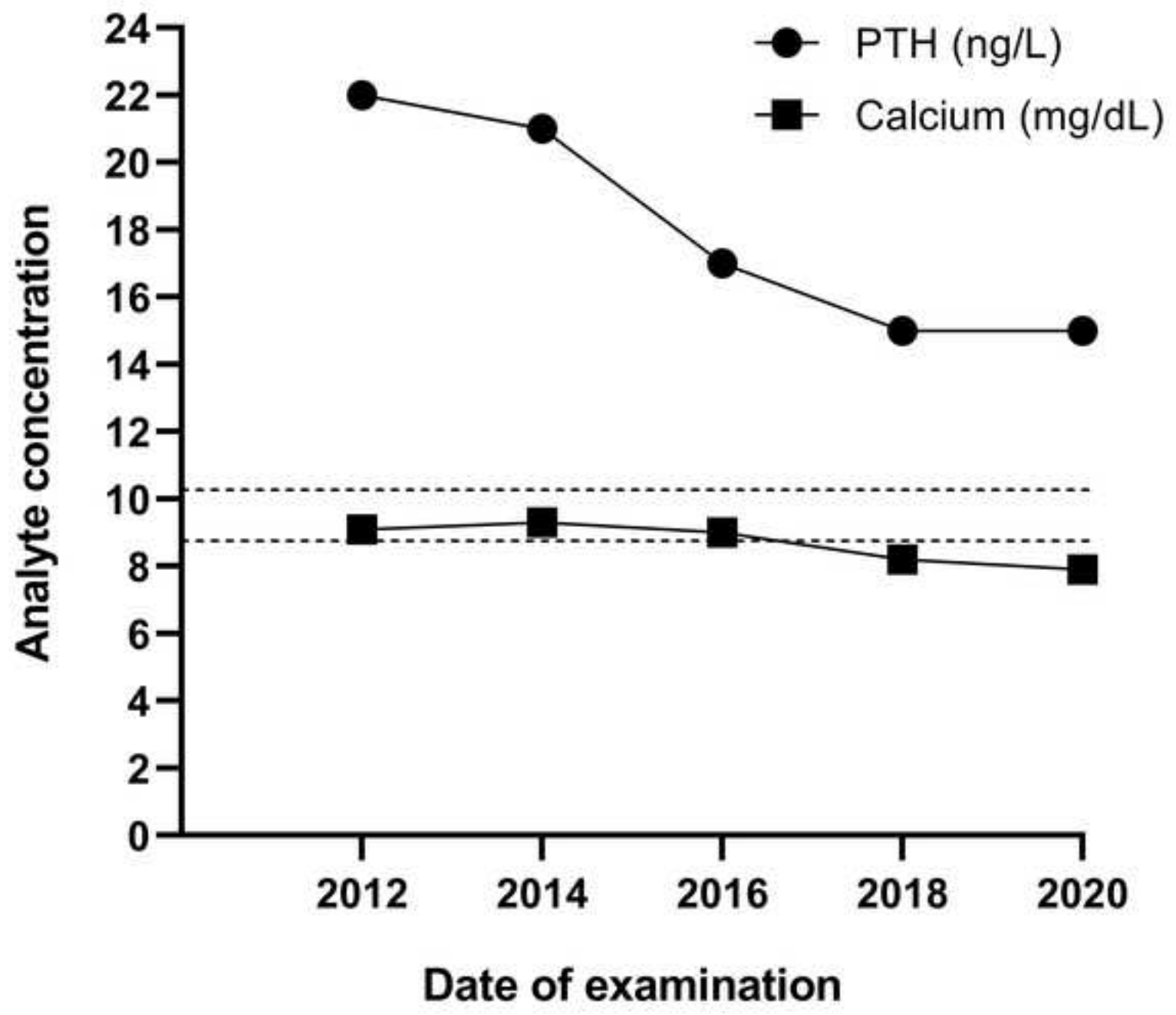


Table 1. Biochemical findings of the patient.

Date	Ionized serum calcium (mmol/L) ^{1,6}	Total serum calcium (mg/dL) ^{2,6}	Serum phosphorus (mg/dL) ^{3,6}	Plasma PTH (ng/L) ⁴	Serum 25-hydroxyvitamin D (ng/mL) ⁵
June 2004	1.23	na	na	46	27.6
March 2005	1.29	na	na	68	21.3
March 2006	1.34	na	na	41	23.3
July 2008	1.38	na	na	65	31.9
April 2009	na	9.6	2.2	46	20.6
December 2009	1.22	na	na	49	11.1
December 2010	1.30	na	na	47	22.4
June 2012	1.18	9.1	2.8	22	25.1
December 2014	1.19	9.3	3.0	21	43.3
September 2016	1.17	9.0	3.5	17	47.6

¹Ionized serum calcium normal range: 1.12-1.32 mmol/L

²Total serum calcium normal range: 8.6-10.2 mg/dL

³Serum phosphorus normal range: 2.5-4.5 mg/dL

⁴Plasma PTH normal range: 10-65 ng/L (2nd generation assay from June 2004 to October 2014); 8-40 ng/L (3rd generation assay from December 2014 to September 2016)

⁵Serum 25-hydroxyvitamin D normal range: 20-50 ng/mL

⁶na, not available

Table 2. Clinical and biochemical features of reported cases of late-onset postsurgical hypoparathyroidism.

Reference	Neck surgery ¹	Clinical presentation	Serum calcium (mg/dL) ²	Serum phosphorus (mg/dL) ²	PTH (pg/mL) ²	Time (years) since surgery
Blanchard et al. (5)	Tx	<ul style="list-style-type: none"> • Jerking of right arm and leg • Seizures (clonic movements of the right hand that progressed to involve the entire right arm, trunk, and lower extremity) • Pursing and "smacking" of the lips • Tetany: not observed • Chvostek's and Trousseau's signs could not be elicited • Mental obtundation was severe 	3.9 (normal range, na)	5.8 (normal range, na)	na	33
Bull et al. (15)	Subtotal Tx	<ul style="list-style-type: none"> • Generalized seizures (tonic and clonic movements, eye rolling, tongue biting, and unconsciousness) • Frequent headaches and lassitude for years • Chvostek's and Trousseau's signs could not be elicited 	6.0 (normal range, na)	5.3 (normal range, na)	na	28
Petch et al. (14)	Tx (two operations)	<ul style="list-style-type: none"> • Increasing forgetfulness • Loss of interest in her surroundings for several months • Fits • Trousseau's sign was positive 	4.5 (normal range, na)	5.4 (normal range, na)	na	27
Cox et al. (6)	Tx	<ul style="list-style-type: none"> • Episode of unconsciousness • Generalized seizure • Tetany: not observed • Chvostek: negative • Trousseau: another generalized seizure occurred during test 	5.8 (normal range, 9-11)	4.1 (normal range, 3-4.8)	162 pgEq/ml (C-terminal; normal range, <150-375)	19
Halperin et al. (7)	Tx	<ul style="list-style-type: none"> • Case 1: severe paresthesia and muscular spasm • Case 2: paresthesia and muscular spasm • Case 3: generalized seizures • Case 4: paresthesia and psychopathy 	6.48 7.08 7.00 8.20	5.26 5.88 6.04 5.60	6 (normal range, 10-60) na 16 pg/mL (N-terminal; normal range, 11-24) 5.3	17 23 5 7

			(normal range, 8.4-10.4)	(normal range, 2.35-4.02)	(normal range, 10-60)	
Lang et al. (18)	Tx	<ul style="list-style-type: none"> • Tetany • Moderately demented • Bilateral symmetrical calcifications in both cerebellar hemispheres, mid-pons, white matter of the frontal, temporal, parietal and occipital lobes 	na	na	na	7 (only tetany) 30
Jorens et al (16)	Subtotal Tx	<ul style="list-style-type: none"> • History of generalized tonic-clonic seizures • Chvostek's and Trousseau's signs could not be elicited • Bilateral calcifications in the basal ganglia, thalami, frontal periventricular white matter, cerebellar hemispheres and brainstem 	4.6 (normal range, 8.01-10.4)	8.01 (normal range, 3.2-5.6)	5 (normal range, 10-55)	35
Bellamy et al. (8)	Tx	<ul style="list-style-type: none"> • Four-year history of fatigue and musculoskeletal limb pains • History of seizures • Marked bilateral basal ganglia calcification • Increasing pain and stiffness in the neck, shoulders, back, arms and legs • Chvostek's and Trousseau's signs negative 	6.16 (normal range, 8.6-9.84)	5.48 (normal range, 2.48-4.46)	< 5 (normal range, 10-65)	36
Garg et al. (17)	Tx	<ul style="list-style-type: none"> • Generalized tonic-clonic seizure • Chvostek's and Trousseau's sign strongly positive • Extensive intracranial calcification of basal ganglia, cerebellum and cerebral white matter 	5.2 (normal range, 9-11)	6.1 (normal range, 2.5-4.5)	1.0 (normal range, 12-72)	19
Mrowka et al. (9)	Subtotal Tx	<ul style="list-style-type: none"> • Case 1: generalized tonic-clonic seizure • Case 2: generalized tonic-clonic seizure; Chvostek's sign positive 	6.0 (normal range, na) 4.0 (normal range, 8.8-10.4)	na na	3 (normal range, na) 5.5 (normal range, 15-70)	9 months 2
Adorni et al. (10)	Tx	<ul style="list-style-type: none"> • Progressive dementia • Psychosis, agitation and insomnia • Symmetric bilateral brain calcifications. 	7.69 (normal range, na)	5.14 (normal range, na)	< 1.0 (normal range, na)	41
Zisimopoulou et al. (11)	Tx	<ul style="list-style-type: none"> • Loss of consciousness lasting a few seconds • Mild extrapyramidal signs • Extensive bilateral symmetrical brain calcifications in the frontal lobes, basal ganglia, subcortical and periventricular white matter, and cerebellar hemispheres 	5.3 (normal range, 8.5-10.5)	5.4 (normal range, 2.5-5)	undetectable	18
Agarwal et al. (12)	Tx	<ul style="list-style-type: none"> • Generalized tonic-clonic convulsions 				

		<ul style="list-style-type: none"> • Tongue bite • Urinary incontinence • Trousseau and Chvostek signs positive • Truncal ataxia, dysdiadochokinesia, dysynergia, past pointing. Hypotonic limbs; diminished tendon reflexes • Extensive intracranial calcifications 	6.1 (normal range, na)	na	na	10
Kamath et al. (13)	Tx	<ul style="list-style-type: none"> • History of recurrent calf muscle cramps and aches in the legs • History of progressive forgetfulness, jitteriness, difficulty in walking, getting up from squatting position and rising from the chair, tingling and numbness in the hands, toes and around the mouth • Different episodes of generalized tonic-clonic seizures • Trousseau's sign and Chovstek's sign positive • Multiple calcifications in basal ganglia 	4.5 (normal range, 9-11)	8.5 (normal range, na)	3.3 (normal range, 9.5-75)	25
Simões et al. (3)	Tx	<ul style="list-style-type: none"> • Crises of cramps in the upper limbs 	3.0 (normal range, 8.6-10.2)	na	3.1 (normal range, 15-65)	3.5
Present study	PTx	<ul style="list-style-type: none"> • Asymptomatic 	7.9 (normal range, 8.6-10.2)	3.8 (normal range, 2.5-4.5)	15 (normal range, 8-40)	14

¹Tx, total thyroidectomy; PTx, parathyroidectomy

²na, not available