

# Cardiac resynchronization therapy following Carillon<sup>®</sup> annuloplasty device for symptomatic heart failure and functional mitral regurgitation: a case report

Haqel A. Jamil <sup>1</sup>, Steven L. Goldberg<sup>2,3</sup>, and Klaus K. Witte <sup>1\*</sup>

<sup>1</sup>Division of Cardiovascular and Diabetes Research, Leeds Institute of Cardiovascular and Metabolic Medicine, University of Leeds, LIGHT Building, Clarendon Way, Leeds LS2 9JT, UK; <sup>2</sup>Tyler Heart Institute of Community Hospital of the Monterey Peninsula, 23625 Holman Hwy, Monterey, CA 93940, USA; and <sup>3</sup>Cardiac Dimensions Inc, 5540 Lake Washington Blvd NE, Kirkland, WA 98033, USA

Received 9 July 2019; first decision 28 August 2019; accepted 21 November 2019; online publish-ahead-of-print 10 December 2019

## Background

Symptomatic patients with significant left ventricular systolic dysfunction (LVSD) require a tailored treatment approach. Both functional mitral regurgitation (FMR) and left bundle branch block (LBBB) can develop, contributing to clinical deterioration, and worse prognosis despite optimal medical therapy (OMT).

## Case summary

We report the case of a symptomatic 60-year-old man on OMT with LVSD and significant FMR. His symptoms and FMR initially improved following transvenous mitral annuloplasty using the Carillon<sup>®</sup> Mitral Contour System<sup>®</sup> annuloplasty device. However, he subsequently developed LBBB with associated reduction in exercise capacity, for which he underwent cardiac resynchronization therapy, and ensuing symptom improvement and stabilization.

## Discussion

Our case describes how targeted device interventions can be combined synergistically to optimize patient symptoms.

## Keywords

Cardiac resynchronization therapy • Heart failure • Mitral annuloplasty • Carillon • Functional mitral regurgitation • Case report

## Learning points

- Functional mitral regurgitation and left bundle branch block are frequently present in patients with symptomatic severe left ventricular systolic dysfunction despite guideline-based optimal medical therapy, and pathways of care should be responsive to changing clinical circumstances.
- Cardiac resynchronization therapy (CRT) in accordance with current heart failure/CRT guidelines remains technically achievable in the presence of a Carillon<sup>®</sup> Mitral Contour System<sup>®</sup> annuloplasty device and can be accomplished as a day-case under local anaesthetic using standard techniques and equipment.

\* Corresponding author. Tel: +44-113-3926108, Email: [k.k.witte@leeds.ac.uk](mailto:k.k.witte@leeds.ac.uk)

Handling Editor: Nikolaos Bonaros

Peer-reviewers: Georg Goliash and Habib Khan

Compliance Editor: Max Sayers

Supplementary Material Editor: Ross Thomson

© The Author(s) 2019. Published by Oxford University Press on behalf of the European Society of Cardiology.

This is an Open Access article distributed under the terms of the Creative Commons Attribution Non-Commercial License (<http://creativecommons.org/licenses/by-nc/4.0/>), which permits non-commercial re-use, distribution, and reproduction in any medium, provided the original work is properly cited. For commercial re-use, please contact [journals.permissions@oup.com](mailto:journals.permissions@oup.com)

## Introduction

Functional mitral regurgitation (FMR) is a common finding in cardiomyopathy patients with both ischaemic and non-ischaemic left ventricular systolic dysfunction (LVSD),<sup>1</sup> being associated with worse symptoms and higher morbidity and mortality. The mitral valve is usually structurally normal, but ventricular (or atrial) dilatation or associated regional wall motion abnormalities can result in lateral displacement and mitral leaflet mal-coaptation leading to secondary (functional) mitral regurgitation (MR). The development of left bundle branch block (LBBB) can cause additional detriment, with cardiac resynchronization therapy (CRT) being a well-established recommended treatment, improving both symptoms and prognosis.<sup>2</sup>

with worsening symptoms of shortness of breath, new orthopnoea, and marked reduction in exercise tolerance [symptoms graded as Class 3 of the New York Heart Association Functional Classification of Heart Failure (NYHA III)], despite being on optimal guideline-based pharmacological therapy<sup>2</sup> at the highest tolerated doses, consisting of Bisoprolol 5 mg b.i.d., Sacubitril/Valsartan 200 mg b.i.d., Spironolactone 25 mg o.d., and Bumetanide 5 mg o.d. Other regular medications consisted of Aspirin 75 mg o.d., Atorvastatin 40 mg o.d., and Metformin 1 g b.i.d. Additionally, a recent increase in loop diuretic dosage had exacerbated his gout symptoms. Physical examination revealed new pulmonary and peripheral oedema, with increased jugular venous pressure. Radial pulse was regular at 60 b.p.m., with a blood pressure of 100/70.

## Timeline

Date	Events
June 2013	Diagnosed with dilated cardiomyopathy. Symptoms stable on Bisoprolol 10 mg o.d., Ramipril 10 mg o.d., Spironolactone 25 mg o.d.
May 2017	Presented acutely with chest pain and shortness of breath. Diagnosed as non-ST elevation myocardial infarction and heart failure exacerbation. Coronary angiogram: moderate diffuse coronary artery disease Transthoracic echocardiogram: mild-moderate eccentric mitral regurgitation (MR), severe left ventricular (LV) dilatation, and severe global left ventricular systolic dysfunction (LVSD) Managed medically
November 2017	Seen in Heart Failure Clinic. Symptoms stable on optimized medical therapy (Bisoprolol 10 mg o.d., Sacubitril/Valsartan 200 mg b.i.d., Spironolactone 25 mg o.d., Ivabradine 5 mg b.i.d., Furosemide 80 mg o.d.). New York Heart Association (NYHA) Class II
July 2018	Seen in Heart Failure Clinic. Worsening shortness of breath and orthopnoea, NYHA III/IV. Furosemide switched to Bumetanide 5 mg o.d. Transthoracic echocardiogram: moderate eccentric MR, severe LV dilatation, and severe global LVSD. 12-lead electrocardiogram (ECG): sinus rhythm, heart rate 65 b.p.m., QRS 110 ms Transoesophageal echocardiogram: severe eccentric MR
August 2018	Community heart failure nurse review. Remains symptomatic with significant orthopnoea, paroxysmal nocturnal dyspnoea, and peripheral oedema. Increased diuretics caused worsening of gout symptoms. Remains NYHA III/IV
September 2018	Carillon <sup>®</sup> Mitral Contour System <sup>®</sup> annuloplasty device implant as part of REDUCE-FMR trial
October 2018	Seen in Heart Failure Clinic. Improvement in symptoms and NYHA II. Clinically euvolaemic
January 2019	Seen in Heart Failure Clinic with worsening symptoms, peripheral and pulmonary oedema, and NYHA III/IV 12-lead ECG: sinus rhythm, left bundle branch block (LBBB), and QRS 142 ms
February 2019	Echocardiogram: mild MR, severe LV dilatation, and severe global LVSD
March 2019	Remains symptomatic with reduced exercise tolerance, NYHA III 12-lead ECG: sinus rhythm, PR interval 178 ms, LBBB, and QRS 148 ms
April 2019	Cardiac resynchronization therapy with primary prevention defibrillator implanted
June 2019	Symptomatic improvement, clinically euvolaemic, and NYHA II

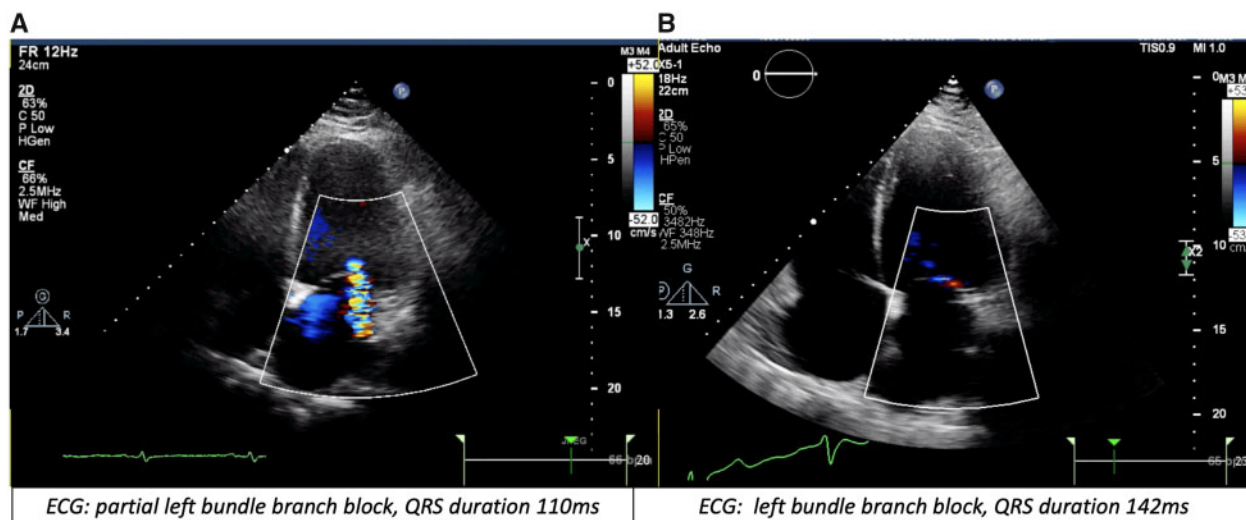
## Case presentation

### Chief complaint

A 60-year-old man with known heart failure with reduced ejection fraction (HFrEF) presented to Heart Failure Clinic in January 2019

### Past medical history

Past medical history included dilated cardiomyopathy, non-ST-elevation myocardial infarction (diagnosed following presentation with troponin-positive chest pain and an angiogram revealing moderate diffuse coronary artery disease), Type 2 diabetes mellitus, obesity



**Figure 1** (A and B) Echocardiogram colour Doppler demonstrating the degree of mitral regurgitation prior to Carillon<sup>®</sup> Mitral Contour System<sup>®</sup> implant (A) and on repeat study in 2019 when symptoms deteriorated (B).

(body mass index 39), gout, and Carillon<sup>®</sup> Mitral Contour System<sup>®</sup> annuloplasty device implantation as part of the REDUCE-FMR trial<sup>3</sup> in September 2018.

## Investigations

Echocardiogram (February 2019, *Figure 1B*) showing severe LVSD and mild MR (previously moderate-severe on transthoracic and transoesophageal echocardiograms in July 2018, prior to Carillon<sup>®</sup> device implant, *Figure 1A*; *Supplementary material online, Video S1*), known moderate diffuse coronary artery disease on coronary angiogram (2017), sinus rhythm with new LBBB on electrocardiogram (QRS duration 142 ms in January 2019, previously 110 ms in 2018).

## Differential diagnosis

His current deterioration in symptoms was deemed to be the result of developing LBBB with severe LVSD, despite initial symptomatic improvement following Carillon<sup>®</sup> device implant and optimal medical therapy (OMT).

## Management

A decision was made to implant a CRT with primary prevention defibrillator (CRT-D) device, in accordance with the ESC guidelines on Cardiac Pacing and CRT.<sup>4</sup>

## Procedure

The patient attended for CRT-D implantation in April 2019. The procedure was carried out under local anaesthetic and aseptic technique using a standard left infraclavicular incision and subclavian venous access. Using routine lead-placement procedures, a Medtronic 6947M internal cardioverter defibrillator dual-coil lead was positioned at the right ventricular apex and a Medtronic 5076 active lead was positioned in the right atrial wall with good variables.

The coronary sinus (CS) was cannulated using a standard pre-shaped CS guiding catheter (Attain system, Medtronic Inc., Minneapolis, MN, USA) with a standard MultiPurpose catheter. Retrograde contrast fluoroscopy revealed a large lateral vein (*Figure 2A, Supplementary material online, Video S2*). A 4798-78 cm Medtronic left ventricular (LV) quadripolar lead was positioned in a stable mid-lateral position (*Figure 2B*).

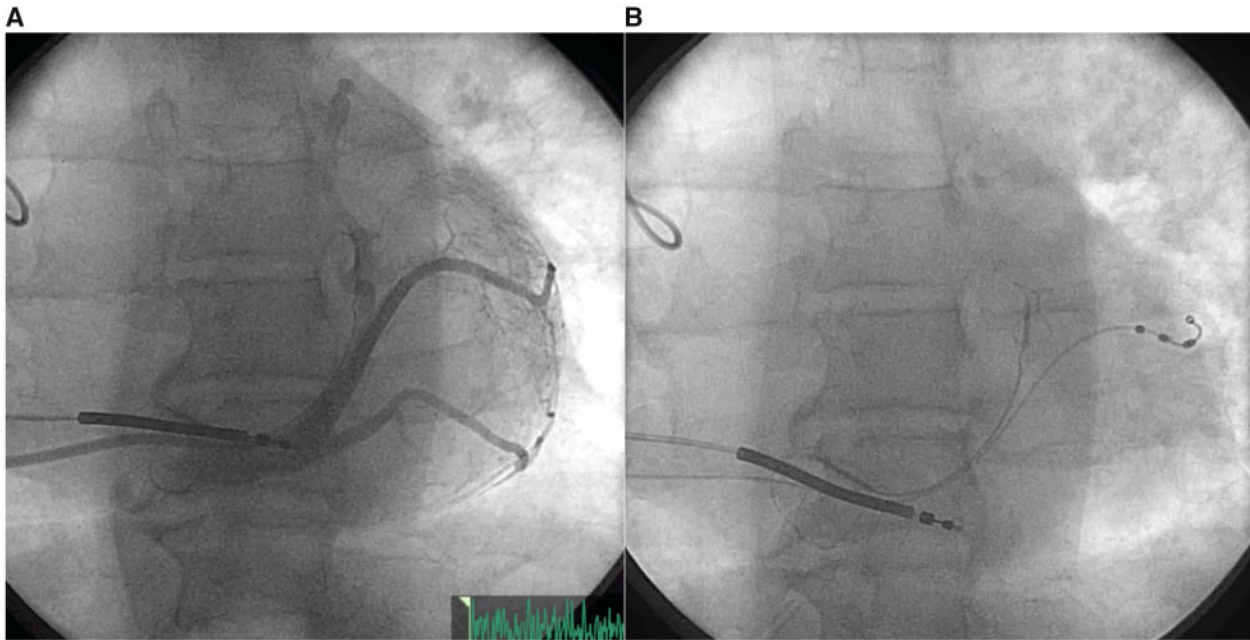
## Follow-up

The patient was discharged the same day uneventfully and was reviewed one week later in the pacing clinic for pacemaker parameter interrogation and incision area evaluation, with no issues identified. He has also reported a reduction in shortness of breath and resolution of orthopnoea symptoms on telephone consultation review with the HF specialist nursing team at 2 weeks; and was deemed to have a symptom burden of NYHA Class II when reviewed in the Heart Failure Clinic in June 2019 (see *Timeline*).

## Discussion

Guideline-based OMT can improve LV systolic function, reduce MR severity, and increase exercise capacity.<sup>1</sup> In those with conduction delay, CRT is a well-established recommended treatment, improving FMR, symptoms, and prognosis.<sup>3,5</sup> For patients without a traditional CRT indication, surgical correction of FMR is not associated with improved outcomes.<sup>6</sup> This has led to an increasing drive to find percutaneous techniques to reduce the FMR, with low peri-procedural risk.<sup>7</sup> Recent trials have heightened anticipation that such percutaneous approaches might improve both symptoms and outcomes.<sup>2,8</sup>

Percutaneous mitral annuloplasty using the Carillon<sup>®</sup> device is a fully transvenous approach utilizing the anatomical proximity of the



**Figure 2** (A and B) Retrograde venography demonstrating potential tributaries of the coronary sinus and the Carillon<sup>®</sup> Mitral Contour System<sup>®</sup> (A) and the final position of the left ventricular lead (B).

CS to the mitral ring, that can lead to clinically relevant reductions in FMR.<sup>3</sup> The device consists of distal and proximal anchors linked by a flexible nitinol bridge which, when deployed within the CS, can reduce FMR by externally restricting the mitral annulus diameter.<sup>3,9</sup>

However, HF<sub>r</sub>EF is a progressive disease process, one feature of which is the development of new conduction abnormalities.<sup>10</sup> Observational studies have described an incidence of new-onset LBBB of up to 10% at 1 year even in ostensibly stable patients.<sup>11</sup> New intraventricular conduction delay and QRS prolongation are associated with increased symptoms, worsening LV function, accelerated remodelling, increased risk of ventricular arrhythmias and sudden death and are an independent risk factor for all-cause mortality.<sup>12,13</sup> The presence of LBBB also predicts lower rates of reverse remodelling,<sup>14</sup> and intraventricular conduction delay, especially LBBB is associated with worse FMR by lengthening LV isovolumetric contraction and relaxation. There is no evidence from observational studies or trials suggesting that device-based treatments for FMR are associated with the development of intraventricular delay or conduction abnormalities. Thus, our interpretation was that the development of new LBBB reported, in this case, is in keeping with the observed natural history of the underlying disease process.

There have been very few cases of CRT implantation in the presence of a Carillon<sup>®</sup> Mitral Contour System<sup>®</sup> annuloplasty device.<sup>15–18</sup> The first reported case series by Hoppe *et al.* demonstrated the feasibility of successful CRT after percutaneous mitral annuloplasty, while in the other reported cases, the patients had pre-existing LBBB and ongoing symptoms following Carillon<sup>®</sup> device implant.

Several concerns arise when contemplating LV lead implantation through the Carillon<sup>®</sup> device, particularly around CS cannulation due to altered geometry and increased tortuosity or angulation. Other potential questions around lead positioning and stability and the risks of CS dissection have been raised.<sup>6</sup> In practice, as can be seen from our image (Figure 1), the Carillon<sup>®</sup> device provides easy visualization of the CS anatomy and orientation, facilitating direct access. Furthermore, tension from the device also reduces any tortuosity or angulation at the ostia of tributaries, potentially increasing the ease of LV lead placement. The conceivable risk of dislodgement of the Carillon system can be disregarded since intravascular-ultrasound data have demonstrated complete endothelialization of the anchors of the Carillon device within 6 months of implant.<sup>10</sup>

Placing a Carillon<sup>®</sup> Mitral Contour System<sup>®</sup> over an existing transvenous CRT lead is currently not recommended, although a series of animal experiments demonstrated the feasibility and stability of the Carillon<sup>®</sup> Mitral Contour System<sup>®</sup> implanted in the presence of LV leads, and also that these leads could be extracted without migration of the Carillon<sup>®</sup> device and without acute or long-term vascular complications.<sup>19</sup>

## Conclusion

This case highlights the complexity of caring for a patient with symptomatic HF<sub>r</sub>EF, and that pathways of care should be responsive to changing clinical circumstances. We have demonstrated that a transvenous quadripolar LV lead can be safely implanted in the presence of a Carillon<sup>®</sup> Mitral Contour System<sup>®</sup> using



standard implanting techniques under local anaesthetic as a day-case procedure.

## Lead author biography



Klaus Witte is a Senior Lecturer and a Consultant Cardiologist in the Leeds Institute of Cardiovascular and Metabolic Medicine at the University of Leeds. His research interests include vitamin D in CHF, heart rate, and exercise capacity in heart failure (*JACC* 2016) and the force-frequency relationship (*JACC-HF* 2018). He is principle investigator of VINDICATE (*JACC* 2016), principal investigator of OPT-Pace (*EHRA* late-breaking clinical trials 2019), co-investigator of REM-HF study (*Eur Heart J*), a co-investigator of REDUCE-FMR (*JACC-HF*), and the only UK cardiologist to have held an NIHR (UK) clinician scientist award.

ical trials 2019), co-investigator of REM-HF study (*Eur Heart J*), a co-investigator of REDUCE-FMR (*JACC-HF*), and the only UK cardiologist to have held an NIHR (UK) clinician scientist award.

## Supplementary material

Supplementary material is available at *European Heart Journal - Case Reports* online.

**Slide sets:** A fully edited slide set detailing this case and suitable for local presentation is available online as [Supplementary data](#).

**Consent:** The author/s confirm that written consent for submission and publication of this case report including image(s) and associated text has been obtained from the patient in line with COPE guidance.

**Conflicts of interest:** H.A.J. has received honoraria from Bayer. S.L.G. is a stock-holder and consultant to Cardiac Dimensions, during the conduct of the study; he has received honoraria from Abbott, outside the submitted work. K.K.W. has held an NIHR (UK) Clinician Scientist Award, has received speaker fees and honoraria from Medtronic, Cardiac Dimensions, Novartis, Abbott, BMS, Pfizer, and Bayer and has received unconditional research grants from Medtronic.

## References

- Bursi F, Enriquez-Sarano M, Nkomo VT, Jacobsen SJ, Weston SA, Meverden RA, Roger VL. Heart failure and death after myocardial infarction in the community: the emerging role of mitral regurgitation. *Circulation* 2005;**111**:295–301.
- Ponikowski P, Voors AA, Anker SD, Bueno H, Cleland JGF, Coats AJS, Falk V, González-Juanatey JR, Harjola VP, Jankowska EA, Jessup M, Linde C, Nihoyannopoulos P, Parissis JT, Pieske B, Riley JP, Rosano GMC, Riuolo LM, Ruschitzka F, Rutten FH, van der Meer P; ESC Scientific Document Group. 2016 ESC Guidelines for the diagnosis and treatment of acute and chronic heart failure: The Task Force for the diagnosis and treatment of acute and chronic heart failure of the European Society of Cardiology (ESC). Developed with the special contribution of the Heart Failure Association (HFA) of the ESC. *Eur Heart J* 2016;**37**:2129–2200.
- Witte KK, Lipiecki J, Siminiak T, Meredith IT, Malkin CJ, Goldberg SL, Stark MA, von Bardeleben RS, Cremer PC, Jaber WA, Celermajer DS, Kaye DM, Sievert H, REDUCE FMR: a randomized sham controlled study of percutaneous mitral annuloplasty in functional mitral regurgitation. *JACC Heart Fail* 2019;**7**:945–955.
- Brignole M, Auricchio A, Baron-Esquivias G, Bordachar P, Boriani G, Breithardt OA, Cleland J, Deharo JC, Delgado V, Elliott PM, Gorenek B, Israel CW, Leclercq C, Linde C, Mont L, Padeletti L, Sutton R, Vardas PE; ESC Committee for Practice Guidelines (CPG), Zamorano JL, Achenbach S, Baumgartner H, Bax JJ, Bueno H, Dean V, Deaton C, Erol C, Fagard R, Ferrari R, Hasdai D, Hoes AW, Kirchhof P, Knuuti J, Kolh P, Lancellotti P, Linhart A, Nihoyannopoulos P, Piepoli MF, Ponikowski P, Sirnes PA, Tamargo JL, Tendera M, Torbicki A, Wijns W, Windecker S; Document Reviewers, Kirchhof P, Blomstrom-Lundqvist C, Badano LP, Aliyev F, Bänsch D, Baumgartner H, Bsata W, Buser P, Charron P, Daubert JC, Dobreanu D, Faerstrand S, Hasdai D, Hoes AW, Le Heuzey JY, Mavrakis H, McDonagh T, Merino JL, Nawar MM, Nielsen JC, Pieske B, Poposka L, Ruschitzka F, Tendera M, Van Gelder IC, Wilson CM. 2013 ESC Guidelines on cardiac pacing and cardiac resynchronization therapy: the task force on cardiac pacing and resynchronization therapy of the European Society of Cardiology (ESC). Developed in collaboration with the European Heart Rhythm Association (EHRA). *Eur Heart J* 2013;**34**:2281–2329.
- Witte KK, Sasson Z, Persaud JA, Jolliffe R, Wald RW, Parker JD. Biventricular pacing: impact on exercise-induced increases in mitral insufficiency in patients with chronic heart failure. *Can J Cardiol* 2008;**24**:379–384.
- Andalib A, Chetrit M, Eberg M, Filion KB, Thériault-Lauzier P, Lange R, Buithieu J, Martucci G, Eisenberg M, Bolling SF, Piazza N. A systematic review and meta-analysis of outcomes following mitral valve surgery in patients with significant functional mitral regurgitation and left ventricular dysfunction. *J Heart Valve Dis* 2016;**25**:696–707.
- Lowry JE, Fichtlscherer S, Witte KK. Therapeutic options for functional mitral regurgitation in chronic heart failure. *Expert Rev Med Devices* 2018;**15**: 357–365.
- Grayburn PA, Sannino A, Packer M. Proportionate and disproportionate functional mitral regurgitation: a new conceptual framework that reconciles the results of the MITRA-FR and COAPT trials. *JACC Cardiovasc Imaging* 2019;**12**: 353–362.
- Schofer J, Siminiak T, Haude M, Herrman JP, Vainer J, Wu JC, Levy WC, Mauri L, Feldman T, Kwong RY, Kaye DM, Duffy SJ, Tübler T, Degen H, Brandt MC, Van Bibber R, Goldberg S, Reuter DG, Hoppe UC. Percutaneous mitral annuloplasty for functional mitral regurgitation: results of the CARILLON Mitral Annuloplasty Device European Union Study. *Circulation* 2009;**120**:326–333.
- Depuey EG, Guertler-Krawczynska E, Robbins WL. Thallium-201 SPECT in coronary artery disease patients with left bundle branch block. *J Nucl Med* 1988;**29**: 1479–1485.
- Clark AL, Goode K, Cleland JG. The prevalence and incidence of left bundle branch block in ambulant patients with chronic heart failure. *Eur J Heart Fail* 2008;**10**:696–702.
- Aleksova A, Carriere C, Zecchin M, Barbati G, Vitrella G, Lenarda AD, Sinagra G. New-onset left bundle branch block independently predicts long-term mortality in patients with idiopathic dilated cardiomyopathy: data from the Trieste Heart Muscle Disease Registry. *Europace* 2014;**16**:1450–1459.
- Lund LH, Jurga J, Edner M, Benson L, Dahlström U, Linde C, Alehagen U. Prevalence, correlates, and prognostic significance of QRS prolongation in heart failure with reduced and preserved ejection fraction. *Eur Heart J* 2013;**34**: 529–539.
- Sze E, Samad Z, Dunning A, Campbell KB, Loring Z, Atwater BA, Chiswell K, Kisslo JA, Velazquez EJ, Daubert JP. Impaired recovery of left ventricular function in patients with cardiomyopathy and left bundle branch block. *J Am Coll Cardiol* 2018;**71**:306–317.
- Hoppe UC, Brandt MC, Degen H, Dodos F, Schneider T, Stoepel C, Kroener A, Haude M. Percutaneous mitral annuloplasty device leaves free access to cardiac veins for resynchronization therapy. *Catheter Cardiovasc Interv* 2009;**74**:506–511.
- El Said AM, Chase D, Al Rawahy NZ. Percutaneous Carillon Mitral Contour System deployment followed by CRT-D implantation: first case report from Oman. *Oman Med J* 2018;**33**:531–534.
- Cimen T, Efe TH, Sunman H, Asarcikli LD, Yeter E. Cardiac resynchronization therapy after percutaneous valve repair in functional mitral regurgitation management. *Kosuyolu Heart J* 2018;**21**:75–76.
- Siminiak T, Jerzykowska O, Kalmucki P, Link R, Baszko A. Cardiac resynchronization therapy after percutaneous trans-coronary-venous mitral annuloplasty. *Kardiologia* 2013;**71**:1293–1294.
- Wengenmayer T, Reinöhl J, Steinfurt J, Mittag A, Bode C, Biermann J. Implantation of CARILLON® Mitral Contour System with transvenous left ventricular lead in place. *Clin Res Cardiol* 2017;**106**:796–801.