



Deposited via The University of Sheffield.

White Rose Research Online URL for this paper:

<https://eprints.whiterose.ac.uk/id/eprint/150419/>

Version: Accepted Version

Article:

Pilborough, A.E., Lambert, D.W. and Khurram, S.A. (2019) Extranodal extension in oral cancer : a role for the nodal microenvironment? *Journal of Oral Pathology & Medicine*, 48 (10). pp. 863-870. ISSN: 0904-2512

<https://doi.org/10.1111/jop.12870>

This is the peer reviewed version of the following article: Pilborough, AE, Lambert, DW, Khurram, SA. Extranodal extension in oral cancer: A role for the nodal microenvironment? *J Oral Pathol Med*. 2019; 00: 1– 8, which has been published in final form at <https://doi.org/10.1111/jop.12870>. This article may be used for non-commercial purposes in accordance with Wiley Terms and Conditions for Use of Self-Archived Versions.

Reuse

Items deposited in White Rose Research Online are protected by copyright, with all rights reserved unless indicated otherwise. They may be downloaded and/or printed for private study, or other acts as permitted by national copyright laws. The publisher or other rights holders may allow further reproduction and re-use of the full text version. This is indicated by the licence information on the White Rose Research Online record for the item.

Takedown

If you consider content in White Rose Research Online to be in breach of UK law, please notify us by emailing eprints@whiterose.ac.uk including the URL of the record and the reason for the withdrawal request.



Extranodal extension in oral cancer: a role for the nodal microenvironment?

Journal:	<i>Journal of Oral Pathology and Medicine</i>
Manuscript ID	JOPM-05-19-RE-5442
Manuscript Type:	Review
Date Submitted by the Author:	03-May-2019
Complete List of Authors:	Pilborough, Alice; The University of Sheffield, School of Clinical Dentistry Lambert, Daniel; University of Sheffield, Khurram, Syed; University of Sheffield, School of Clinical Dentistry
Methods:	
Keywords:	Oral cancer, Extranodal extension, Extracapsular spread, Lymph node metastasis, Tumour microenvironment
Abstract:	<p>Oral squamous cell carcinoma (OSCC) is a significant cause of morbidity and mortality worldwide, and accounts for the majority of head and neck cancers. Metastasis of primary tumours, primarily to cervical lymph nodes in the neck, is associated with worsening prognosis. Furthermore, the prognosis of patients with extranodal extension of metastatic tumour from the lymph nodes into the neck tissues is particularly poor. The factors affecting this process are poorly understood and detection is difficult pre-surgery.</p> <p>Mounting evidence shows that components of the tumour microenvironment including cancer-associated fibroblasts, vascular and lymphatic endothelial cells, the extracellular matrix and inflammatory immune cells, are important modulators of tumour behaviour in primary OSCC and other cancers. However, little is known about the lymph node microenvironment, its response to tumour presence and role in extranodal extension. In addition, there are many lymph node-specific cell types and structures, such as fibroblast reticular cells and high endothelial venules, making the lymph node microenvironment distinct from that found at primary tumour sites, and which contribute to the nodal response to tumour presence.</p> <p>This review details the current knowledge regarding the lymph node tumour microenvironment in OSCC and its role in lymph node metastasis and extranodal extension, and relates this to features of the primary tumour. Understanding the role that the lymph node microenvironment plays in promoting tumour development and extranodal extension may aid the identification of novel biomarkers and alternative treatment strategies to improve the prognosis of patients with advanced OSCC.</p>

1
2
3
4
5
6
7
8
9
10
11
12
13
14
15
16
17
18
19
20
21
22
23
24
25
26
27
28
29
30
31
32
33
34
35
36
37
38
39
40
41
42
43
44
45
46
47
48
49
50
51
52
53
54
55
56
57
58
59
60



Extranodal extension in oral cancer: a role for the nodal microenvironment?

Running title: The oral cancer nodal microenvironment

Pilborough, A. E., Lambert, D.W., and Khurram, S.A*

Affiliations: Unit of Oral and Maxillofacial Pathology, School of Clinical Dentistry, University of Sheffield, S10 2TA, UK.

* Corresponding author: Dr S.A. Khurram: s.a.khurram@sheffield.ac.uk

Acknowledgements

All authors declare that they have no conflicts of interest to disclose.

Abstract

Oral squamous cell carcinoma (OSCC) is a significant cause of morbidity and mortality worldwide, and accounts for the majority of head and neck cancers. Metastasis of primary tumours, primarily to cervical lymph nodes in the neck, is associated with worsening prognosis. Furthermore, the prognosis of patients with extranodal extension of metastatic tumour from the lymph nodes into the neck tissues is particularly poor. The factors affecting this process are poorly understood and detection is difficult pre-surgery.

Mounting evidence shows that components of the tumour microenvironment including cancer-associated fibroblasts, vascular and lymphatic endothelial cells, the extracellular matrix and inflammatory immune cells, are important modulators of tumour behaviour in primary OSCC and other cancers. However, little is known about the lymph node microenvironment, its response to tumour presence and role in extranodal extension. In addition, there are many lymph node-specific cell types and structures, such as fibroblast reticular cells and high endothelial venules, making the lymph node microenvironment distinct from that found at primary tumour sites, and which contribute to the nodal response to tumour presence.

This review details the current knowledge regarding the lymph node tumour microenvironment in OSCC and its role in lymph node metastasis and extranodal extension, and relates this to features of the primary tumour. Understanding the role that the lymph node microenvironment plays in promoting tumour development and extranodal extension may aid the identification of novel biomarkers and alternative treatment strategies to improve the prognosis of patients with advanced OSCC.

Introduction

Oral cancer is the 13th most common cause of cancer mortality in the world¹; survival rates remain static at 50% and mortality rates are projected to increase due to rising incidence².

Oral squamous cell carcinoma (OSCC), which originates from the squamous epithelial cells of the oral cavity, is the most common form of oral cancer. However, in comparison to other common cancers, the molecular landscape of OSCC is poorly understood, hampering the development of novel treatments and prognosticators informing treatment options. In particular, successful treatment of OSCC is impeded by its propensity to metastasise to locoregional sites such as the cervical lymph nodes and the development of extranodal extension (ENE).

1. Lymph node metastasis

Metastasis of OSCC, usually to the cervical lymph nodes, worsens prognosis^{3,4}. In some instances, the metastatic tumour can grow and infiltrate beyond the lymph node capsule and invade into the surrounding adipose tissue and muscle. This phenomenon, previously referred to as extracapsular spread (ECS), but now renamed extranodal extension (ENE) and results in a further significant reduction in prognosis (section 2.1).

OSCC is most commonly treated by surgery with or without radiotherapy or chemotherapy⁵.

Owing to the high mortality rate associated with lymph node metastasis, identification of patients with node involvement is essential to guide treatment strategies. Currently, fine needle aspiration, core biopsies, ultrasound or magnetic resonance imaging (MRI) scanning and sentinel node biopsies are used to identify patients with lymph node involvement.

However, evidence suggests these methods are not sufficiently sensitive^{6,7} and the risks associated with false negative reporting result in a large number of patients undergoing elective neck dissections despite being classified as negative for metastatic tumour clinically.

Only approximately 30% of node-negative patients undergoing elective neck dissection are

1
2
3 found to have lymph node involvement⁸. Although identification and removal of positive
4 nodes confers a survival benefit⁸, a large number of neck dissections - and resulting
5 profound morbidity - are unnecessary. Neck dissection may result in neck stiffness and
6
7 constriction, pain, numbness and damage to the spinal accessory nerve which can impair
8
9 shoulder function⁹.
10
11
12
13
14
15
16

17 **1.1. Lymph node structure**

18
19
20 The lymph node structure and constituent cells play a key role in the colonisation, growth
21 and local invasion of OSCC tumours. The highly organised lymph node structure (Figure 1)
22 facilitates interactions between cells of the immune system and foreign antigens. In normal
23 function, lymph fluid drained from surrounding tissues enters the lymph node via the afferent
24 lymph vessels along with circulating antigen presenting cells (APCs). Here the subcapsular
25 sinus forms a barrier to fluid entering the lymph node but APCs are able to actively cross it
26 along with their antigen cargo¹⁰. Fluid containing small antigens and chemokines are
27 transported around the lymph node via collagen conduits formed and covered by fibroblast
28 reticular cells (FRCs)¹¹. A fibrocollagenous capsule surrounds the entire lymph node and
29 supports its structure.
30
31
32
33
34
35
36
37
38
39
40

41 Lymphocytes are organised into distinct compartments in the cortical areas due to
42 homeostatic chemokine expression by FRCs. B lymphocytes are localised to B cell follicles
43 in the outer cortex, whereas T lymphocytes are located in the inner paracortical areas. Naïve
44 lymphocytes enter from blood vessels via the high endothelial venules and lymph fluid and
45 lymphocytes are drained from the lymph node via the efferent lymph vessels¹⁰.
46
47
48
49
50

51
52 The complexity of the lymph node stroma was highlighted in a recent comprehensive paper
53 which identified nine distinct subsets of non-endothelial stromal cells based on single cell
54 RNA-seq data from mouse lymph nodes¹². This included several subsets of FRCs and
55
56
57
58
59
60

1
2
3 emphasizes the importance of considering the lymph node as a distinct tumour
4
5 microenvironment compared to that found in the oral cavity.
6
7
8
9

10 **1.2. Metastatic lymph node tumour development**

11
12
13 The routes of lymph node entry used by immune cells are also exploited by tumour cells.
14
15 This is particularly key in OSCC as oral structures (in particular lateral tongue, a common
16
17 site for OSCC) have abundant superficial lymphatic vessels. Tumour cells invading
18
19 lymphatic vessels follow the path of natural lymph drainage, entering the lymph node via the
20
21 afferent lymph vessels and collecting at the subcapsular sinus¹³ (Figure 1). Complementary
22
23 chemokine expression by tumour cells and the lymphatic endothelial cells lining the
24
25 subcapsular sinus may facilitate tumour migration into the cortex¹⁴. Once within the cortex,
26
27 tumour cells proliferate, develop a blood vessel network and, in some cases, generate a
28
29 supportive stroma. Cancer cells can migrate and invade through lymph node tissue and
30
31 break out of the capsule surrounding the lymph node in a process termed ENE (Figure 2).
32
33
34
35
36
37

38 **2. Extranodal Extension (ENE)**

39 **2.1. Prognostic value of ENE**

40
41
42 ENE (or ECS) is a key indicator of poor survival, increased recurrence and increased rate of
43
44 distant metastasis^{4,15-17}. Shaw et al. (2010)⁴ reported 5-year survival rates of 65%, 52% and
45
46 23% in node negative, node-positive ENE-negative and node-positive ENE-positive patients,
47
48 respectively. Additionally, a recent study showed that when ENE was categorised based on
49
50 the level of invasion out of the lymph node, patients with the highest level of invasion had a
51
52 significantly poorer survival and higher recurrence rate¹⁸. Although by using retrospective
53
54 data these studies do not represent the impact of current treatment strategies, they do
55
56 provide evidence that ENE is a crucial prognostic indicator. This is further highlighted by the
57
58
59
60

1
2
3 recent update to TNM classification, which recommends taking ENE into consideration for
4 the tumour to be up-staged.
5
6
7
8
9

10 **2.2. ENE detection**

11
12
13 Currently, the presence of ENE is confirmed histologically (Figure 2) following lymph node
14 removal through a selective (or in some cases radical) neck dissection. Preoperative
15 scanning techniques such as computed tomography (CT) and MRI are also used for ENE
16 diagnosis. However, a recent meta-analysis revealed that the mean sensitivity and specificity
17 of these methods is below 0.85, meaning that a significant proportion of patients are still
18 being misdiagnosed¹⁹. This false negative reporting could delay identification of patients
19 requiring more aggressive treatment. There have been reports of primary tumour gene
20 expression signatures that can predict ENE²⁰⁻²²; which would aid treatment decisions but
21 larger studies are needed before translation to the clinic can be considered.
22
23
24
25
26
27
28
29
30
31
32

33 In order to develop more effective diagnostic and therapeutic tools, the mechanisms of ENE
34 need to be better understood, both within the tumour and its surrounding environment.
35
36
37
38
39
40
41
42
43
44
45

46 **3. The tumour microenvironment in ENE**

47 The behaviour of cancer cells is heavily influenced by the multitudinous cell types present in
48 the tumour microenvironment (TME, Figure 3). Fibroblasts, lymphatic and vascular
49 endothelial cells, and inflammatory immune cells are all key components of the TME and are
50 able to influence cancer development through multiple intercellular signalling pathways and
51 their influence on the extracellular matrix (ECM). There has been increased focus on the
52 OSCC TME in recent years and it has been proposed that it may be a key driver of lymph
53 node metastasis and ENE.
54
55
56
57
58
59
60

3.1. Cancer-associated fibroblasts

Cancer-associated fibroblasts (CAF) are often found surrounding epithelial tumour islands and contribute to cancer progression through the secretion of a range of growth factors, proteases and cytokines, as well as contributing to the development of a tumour-permissive ECM. The myofibroblast marker α -smooth muscle actin (α SMA) is often used as a CAF marker, but evidence suggest that the CAF population is very heterogeneous and other CAF phenotypes, such as senescent CAF, are also important²³. Single-cell transcriptome analysis of a set of matched primary and lymph node OSCC tumours identified several subsets of CAF which were present at both sites, but in varying proportions and with differential expression of certain ligands and receptors at each site²⁴. This may indicate that CAF populations are maintained following metastasis but that the lymph node signalling environment alters their composition. Many alternative CAF sources including recruited mesenchymal stem cells, resident fibroblasts and differentiated epithelial cancer cells have been suggested²⁵ but the exact origins and mechanisms by which CAF are generated in the lymph node are yet to be fully elucidated .

In OSCC, the presence of α SMA-positive CAF in the tumour stroma has been linked to poor survival, increased recurrence, lymph node metastasis and increased ENE^{26–28}. α SMA-positive fibroblasts are also present in lymph node tumours and unpublished data from our lab has shown that they are more abundant in nodes with ENE as well as their matched primary tumours and the presence of a more desmoplastic stroma in ENE-positive nodes (Figure 4).

CAF have been linked to the promotion of migration, invasion and metastasis in primary tumour OSCC both *in vitro* and *ex vivo*. However, their influence on ENE is less well understood. The development of a mesenchymal phenotype in cancer cells through a process called epithelial-mesenchymal transition (EMT) is a key route through which cancer cells gain the ability to migrate and invade and this has been proposed as a possible mechanism behind ENE. Puram et al. (2017) identified a partial-EMT expression signature

1
2
3 which localised to the leading edge of tumour islands in both primary and lymph node
4
5 OSCC²⁴. These islands were also surrounded by CAF which were enriched for EMT-
6
7 promoting ligands. Lee et al. (2014) investigated EMT marker expression in lymph nodes
8
9 with and without ENE²⁹. They found that EMT was a better predictor of poor survival than
10
11 ENE alone as ENE-positive patients with a high percentage of tumour cells expressing
12
13 mesenchymal markers had a five times worse survival rate compared to ENE-negative
14
15 patients.
16

17
18 Together, these studies provide evidence that CAF might be important in ENE development
19
20 but further work is needed to elucidate the mechanisms by which they influence tumour
21
22 development.
23
24

25 26 27 28 **3.2. Fibroblast reticular cells**

29
30 Fibroblast reticular cells (FRCs) are a specialised sub-type of fibroblasts found within the
31
32 lymph node (Figure 1). FRCs produce complex networks of collagen conduits ensheathed in
33
34 a basement membrane which provide structure and support to the lymph node. These
35
36 conduits transport fluid containing chemokines and small antigens through the lymph node to
37
38 the high endothelial venules¹¹.
39

40
41
42 Despite their critical role in nodal function, very few studies have investigated the FRC
43
44 response to metastatic cancer. Riedel et al. (2016)³⁰ investigated FRC responses in the
45
46 tumour draining lymph nodes (TDLN) of a mouse melanoma model. They observed an
47
48 enlargement of pre-metastatic TDLNs which was partly attributed to an expansion of FRCs.
49
50 Whole genome transcriptome analysis comparing non-draining lymph nodes, early and late
51
52 stage TDLNs revealed many alterations in gene expression including an increase in FRC
53
54 activation markers. Most significantly they observed a dysregulation in cytokine and
55
56 chemokine signalling in the late stage nodes which resulted in a disorganised tissue
57
58 architecture and alteration to immune cell composition. Alterations to transporter function,
59
60

1
2
3 remodelling of collagen fibres and changes to cell junction proteins were also found in late
4 stage nodes where conduits were widened. The authors suggested this loss of conduit
5 integrity may aid the delivery of tumour-derived factors, debris and antigens deep into the
6 lymph node to aid subsequent lymph node metastasis.
7
8
9

10
11
12 However, the impact of FRCs on tumour cells and their development once they reach the
13 lymph node is unknown. In addition, multiple subtypes of FRC have now been identified
14 within the lymph node localised to specific areas within the cortex or subcapsular synapse¹²,
15 suggesting that more detailed analysis of FRC subset responses may be needed to
16 understand their role in the different stages of lymph node metastases development.
17
18
19
20
21
22
23
24
25

26 **3.3. Extracellular matrix**

27
28
29 The extracellular matrix (ECM) provides a supportive structure to all tissues. It is formed of
30 fibrous proteins, such as collagen and fibronectin, and glycosaminoglycans, predominantly
31 secreted by fibroblasts³¹. Fibroblasts also secrete enzymes such as matrix
32 metalloproteinases which cleave ECM proteins, allowing for structural remodelling or the
33 release of bound signalling molecules³¹. The ECM plays an important role in cancer
34 development, particularly as cancer cells must migrate along and invade through the ECM if
35 they are to metastasise to other sites. In lymph nodes FRCs are the key secretors of the
36 ECM, which is primarily made up of collagen conduits (section 3.2).
37
38
39
40
41
42
43
44
45

46 Although altered ECM composition has been reported in OSCC³¹, data is scarce regarding
47 the response of the lymph node ECM to cancer presence. Rizwan et al. (2015)³²
48 investigated collagen density using a mouse model of metastatic breast cancer and found
49 that lymph nodes containing metastatic deposits had a higher collagen I density compared to
50 mice with non-metastatic breast cancer or no tumour. They also examined human breast
51 cancer lymph nodes with metastasis and saw an up-regulation of collagen and fibronectin
52
53
54
55
56
57
58
59
60

1
2
3 compared to tumour-free lymph nodes. The contribution of ECM alterations, both in terms of
4 composition and physical properties, to ENE remains to be determined.
5
6
7
8
9

10 11 12 **3.4. Lymphatic and vascular endothelial cells**

13
14
15
16 Endothelial cells line blood and lymphatic vessels, both of which are important in facilitating
17 tumour growth as well as providing a route of metastasis. In OSCC, increased vascular and
18 lymphatic invasion has been linked to increased nodal metastasis and ENE^{33,34}. Increased
19 vessel density and elevated expression of pro-angiogenic factors have been observed in
20 primary OSCC and correlated with increased lymph node metastasis^{35,36}, decreased
21 survival^{36,37}, and elevated levels of α SMA-positive CAF³⁸. However, few studies focus on the
22 role of endothelial cells within the lymph node.
23
24
25
26
27
28
29

30
31 A study using an OSCC mouse model found that blood vessel density was elevated in
32 tumour-draining lymph nodes when metastatic, but not non-metastatic, tumour cells were
33 implanted into the tongue, suggesting the lymph node TME is altered prior to colonisation³⁹.
34
35 Furthermore, in a mouse model of squamous cell carcinoma, metastasising tumour cells
36 were observed accumulating around blood vessels in the lymph node cortex and moving
37 inside the vessel lumen⁴⁰. This study therefore proposed that blood vessels may be an
38 important route of further metastasis from the lymph node.
39
40
41
42
43
44
45

46
47 In lymph nodes, specialised blood vessels called high endothelial venules (HEV) are found
48 in the paracortex, formed of cuboidal endothelial cells surrounded by FRCs (Figure 1). In
49 OSCC lymph nodes with metastatic deposits, an increased density of HEVs has been
50 observed and correlated to poor prognosis⁴¹. However, HEV density has also been found to
51 be elevated during lymph node enlargement prior to metastatic colonisation⁴² and in sentinel
52 lymph nodes (SLN) regardless of metastatic status compared to non-SLNs⁴³. Furthermore,
53
54
55
56
57
58
59
60

1
2
3 tumour deposits have been observed adjacent to HEVs suggesting this may be an
4
5 alternative route for metastasis⁴².
6

7
8 The response of lymphatic vessels to tumour presence in the lymph node is not clear. Chung
9
10 et al. (2012) reported an increase in lymphatic vessel density in SLNs regardless of
11
12 metastasis status compared to non-SLN⁴³, whereas Wakisaka et al. (2015) found that the
13
14 density was significantly higher in SLN with metastatic deposits compared to tumour-free
15
16 SLN⁴⁴.
17

18
19 Research so far has focussed on the angiogenic response of the lymph node prior and
20
21 immediately following colonisation; further work is needed to elucidate the role of endothelial
22
23 cells in ENE.
24
25

26 27 28 **3.5. Inflammation and tumour-associated macrophages** 29

30
31
32 The generation of an inflammatory microenvironment is now known to be a crucial driver of
33
34 tumour progression. The innate immune cells crucial to this inflammatory response, including
35
36 macrophages and neutrophils, have multitudinal effects on the tumour and its
37
38 microenvironment through their secretion of cytokines, chemokines, prostaglandins and
39
40 other factors⁴⁵. The response of both native and recruited immune cells to tumour presence
41
42 in the lymph node is an important consideration and may impact on ECS development.
43
44

45
46 Macrophages are recruited to the tumour in response to a variety of signals secreted by
47
48 tumour and stromal cells. Aberrant chemokine signalling in FRCs in response to the cancer
49
50 presence has been shown to increase macrophage presence in lymph nodes in a mouse
51
52 model of metastatic melanoma³⁰. Macrophages can display diverse behaviours, with some
53
54 contributing to an active inflammatory immune response while others, often labelled M2
55
56 macrophage, are anti-inflammatory and promote tissue remodelling and repair in healthy
57
58 tissues⁴⁶. Tumour-associated macrophages (TAMs), which display M2 phenotype behaviour,
59
60

1
2
3 are able to aid tumour progression through the stimulation of proliferation, angiogenesis, and
4
5 ECM remodelling and the suppression of anti-tumour immunity⁴⁶.
6
7

8 In primary OSCC, high macrophage numbers have been linked to poor prognosis and
9
10 increased lymph node metastasis⁴⁷⁻⁴⁹. However, there is some disagreement as to whether
11
12 macrophage densities in the tumour, invasive edge or stroma are significant and whether
13
14 this association is only found when staining for M2 macrophage markers. Only one study, to
15
16 our knowledge, has investigated macrophage in metastatic lymph nodes of OSCC⁵⁰.
17
18 However, this focussed on whether macrophage numbers or polarisation in the lymph node
19
20 sinus could predict primary tumour invasion and grading parameters, with results varying
21
22 depending on the macrophage marker ratio used.
23
24
25
26
27
28

29 **4. Perspectives and clinical impact**

30
31
32 This review provides an overview of current knowledge regarding the development and
33
34 treatment of lymph node metastasis and ENE in OSCC, and the role of the TME in these
35
36 processes. There is mounting evidence that the TME has the ability to induce the invasion
37
38 and metastasis of primary tumour OSCC and evidence is beginning to emerge to link the
39
40 TME to lymph node tumour development. However, direct evidence and specific
41
42 mechanisms of action are lacking and many questions remain unanswered including the
43
44 origin of lymph node-associated CAFs and the response of the many resident immune cells
45
46 to the presence of metastatic deposits. Advances in *in vitro* cell culture techniques, such as
47
48 3D modelling of lymph nodes, combined with *in vivo* and *ex vivo* data may help reveal the
49
50 molecular and cellular mechanisms underlying ENE.
51
52
53

54 Given their importance, it is not surprising that therapeutic targeting of many of the
55
56 TME cell types and ENE is seen as a promising approach. The greater genetic stability and
57
58 influence CAFs, TAMs, FRCs and endothelial cells have on the ECM, which is often a barrier
59
60

1
2
3 for the delivery of drugs to solid tumours, makes them even more attractive. Given the
4
5 difficulties faced in the detection of ENE pre-surgery, the huge quality of life impact on
6
7 patients and economic cost of unnecessary neck dissections, the TME also represents a
8
9 promising area for the identification of novel prognostic biomarkers for use either in primary
10
11 tumour samples or lymph node biopsies. Understanding the ENE process and the
12
13 mechanisms underpinning it could have a significant impact on prognostic and therapeutic
14
15 tools available to clinicians treating OSCC patients.
16
17
18
19
20
21
22
23
24
25
26
27
28
29
30
31
32
33
34
35
36
37
38
39
40
41
42
43
44
45
46
47
48
49
50
51
52
53
54
55
56
57
58
59
60

For Review Only

References

1. Ferlay J, Soerjomataram I, Ervik M, et al. *GLOBOCAN 2012 v1.0, Cancer Incidence and Mortality Worldwide: IARC CancerBase No. 11*. Lyon, France; 2013.
2. Olsen A, Parkin D, Saseini P. Cancer mortality in the United Kingdom: projections to the year 2025. *Br J Cancer*. 2008;99(1):1549-1554.
3. Myers JN, Greenberg JS, Mo V, Roberts D. Extracapsular Spread: A Significant Predictor of Treatment Failure in Patients with Squamous Cell Carcinoma of the Tongue. *Cancer*. 2001;92(12):3030-3036.
4. Shaw RJ, Lowe D, Woolgar JA, et al. Extracapsular spread in oral squamous cell carcinoma. *Head Neck*. 2010;32(6):714-722.
5. Sapp JP, Eversole LR, Wysocki GP. *Contemporary Oral and Maxillofacial Pathology*. 2nd Ed. (Rudolph P, Alvis K, eds.). St. Louis: Elsevier; 2004.
6. Tandon S, Shahab R, Benton JI, Ghosh SK, Sheard J, Jones TM. Fine-needle aspiration cytology in a regional head and neck cancer center: Comparison with a systematic review and meta-analysis. *Head Neck*. 2008;30(9):1246-1252.
7. Govers TM, Hannink G, Merks MAW, Takes RP, Rovers MM. Sentinel node biopsy for squamous cell carcinoma of the oral cavity and oropharynx: A diagnostic meta-analysis. *Oral Oncol*. 2013;49(8):726-732.
8. D'Cruz AK, Vaish R, Kapre N, et al. Elective versus Therapeutic Neck Dissection in Node-Negative Oral Cancer. *N Engl J Med*. 2015;373(6):521-529.
9. Inoue H, Nibu KI, Saito M, et al. Quality of life after neck dissection. *Arch Otolaryngol - Head Neck Surg*. 2006;132(6):662-666.
10. Chang JE, Turley SJ. Stromal infrastructure of the lymph node and coordination of immunity. *Trends Immunol*. 2015;36(1):30-39.
11. Roozendaal R, Mebius RE, Kraal G. The conduit system of the lymph node. *Int Immunol*. 2008;20(12):1483-1487.
12. Rodda LB, Lu E, Bennett ML, et al. Single-Cell RNA Sequencing of Lymph Node Stromal Cells Reveals Niche-Associated Heterogeneity. *Immunity*. 2018;48(5):1014-1028.e6.
13. Nathanson SD, Shah R, Rosso K. Sentinel lymph node metastases in cancer: Causes, detection and their role in disease progression. *Semin Cell Dev Biol*. 2015;38(1):106-116.
14. Podgrabinska S, Skobe M. Role of lymphatic vasculature in regional and distant metastases. *Microvasc Res*. 2014;95(1):46-52.
15. Liao C-T, Wang H-M, Chang JT-C, et al. Analysis of risk factors for distant metastases in squamous cell carcinoma of the oral cavity. *Cancer*. 2007;110(7):1501-1508.
16. Shibuya Y, Ohtsuki Y, Hirai C, et al. Oral squamous cell carcinoma with microscopic extracapsular spread in the cervical lymph nodes. *Int J Oral Maxillofac Surg*. 2014;43(4):387-92.
17. Suton P, Salaric I, Granic M, Mueller D, Luksic I. Prognostic significance of extracapsular spread of lymph node metastasis from oral squamous cell carcinoma in the clinically negative neck. *Int J Oral Maxillofac Surg*. 2017.
18. Yamada S, Yanamoto S, Otani S, et al. Evaluation of the level of progression of extracapsular spread for cervical lymph node metastasis in oral squamous cell

- 1
2
3 carcinoma. *Int J Oral Maxillofac Surg*. 2016;45(2):141-146.
- 4 19. Su Z, Duan Z, Pan W, et al. Predicting extracapsular spread of head and neck
5 cancers using different imaging techniques: A systematic review and meta-
6 analysis. *Int J Oral Maxillofac Surg*. 2016;45(4):413-421.
- 7 20. Zhou X, Temam S, Oh M, et al. Global expression-based classification of lymph
8 node metastasis and extracapsular spread of oral tongue squamous cell
9 carcinoma. *Neoplasia*. 2006;8(11):925-32.
- 10 21. Michikawa C, Uzawa N, Sato H, Ohyama Y, Okada N, Amagasa T. Epidermal
11 growth factor receptor gene copy number aberration at the primary tumour is
12 significantly associated with extracapsular spread in oral cancer. *Br J Cancer*.
13 2011;104(5):850-855.
- 14 22. Wang W, Lim WK, Leong HS, et al. An eleven gene molecular signature for
15 extra-capsular spread in oral squamous cell carcinoma serves as a
16 prognosticator of outcome in patients without nodal metastases. *Oral Oncol*.
17 2015;51(4):355-362.
- 18 23. Cirri P, Chiarugi P. Cancer-associated-fibroblasts and tumour cells: a diabolic
19 liaison driving cancer progression. *Cancer Metastasis Rev*. 2012;31(1):195-
20 208.
- 21 24. Puram S V., Tirosh I, Parikh AS, et al. Single-Cell Transcriptomic Analysis of
22 Primary and Metastatic Tumor Ecosystems in Head and Neck Cancer. *Cell*.
23 2017;171(7):1611-1624.e24.
- 24 25. Madar S, Goldstein I, Rotter V. "Cancer associated fibroblasts" - more than
25 meets the eye. *Trends Mol Med*. 2013;19(8):447-453.
- 26 26. Kellermann MG, Sobral LM, da Silva SD, et al. Myofibroblasts in the stroma of
27 oral squamous cell carcinoma are associated with poor prognosis.
28 *Histopathology*. 2007;51(6):849-53.
- 29 27. Marsh D, Suchak K, Moutasim K a., et al. Stromal features are predictive of
30 disease mortality in oral cancer patients. *J Pathol*. 2011;223(4):470-481.
- 31 28. Dhanda J, Triantafyllou A, Liloglou T, et al. SERPINE1 and SMA expression at
32 the invasive front predict extracapsular spread and survival in oral squamous
33 cell carcinoma. *Br J Cancer*. 2014;111(11):2114-21.
- 34 29. Lee W-Y, Shin D-Y, Kim HJ, Ko Y-H, Kim S, Jeong H-S. Prognostic
35 significance of epithelial-mesenchymal transition of extracapsular spread
36 tumors in lymph node metastases of head and neck cancer. *Ann Surg Oncol*.
37 2014;21(1):1904-11.
- 38 30. Riedel A, Shorthouse D, Haas L, Hall BA, Shields J. Tumor-induced stromal
39 reprogramming drives lymph node transformation. *Nat Immunol*. 2016;17(9).
- 40 31. Ziober AF, Falls EM, Ziober BL. The extracellular matrix in oral squamous cell
41 carcinoma: friend or foe? *Head Neck*. 2006;28(8):740-749.
- 42 32. Rizwan A, Bulte C, Kalaichelvan A, et al. Metastatic breast cancer cells in
43 lymph nodes increase nodal collagen density. *Sci Rep*. 2015;5(1):10002.
- 44 33. Jones HB, Sykes A, Bayman N, et al. The impact of lymphovascular invasion
45 on survival in oral carcinoma. *Oral Oncol*. 2009;45(1):10-5.
- 46 34. Adel M, Kao H-K, Hsu C-L, et al. Evaluation of Lymphatic and Vascular
47 Invasion in Relation to Clinicopathological Factors and Treatment Outcome in
48 Oral Cavity Squamous Cell Carcinoma. *Medicine (Baltimore)*.
49 2015;94(43):e1510.
- 50 35. Jung S, Sielker S, Purcz N, Sproll C, Acil Y, Kleinheinz J. Analysis of

- angiogenic markers in oral squamous cell carcinoma-gene and protein expression. *Head Face Med.* 2015;11(1):19.
36. Miyahara M, Tanuma J, Sugihara K, Semba I. Tumor lymphangiogenesis correlates with lymph node metastasis and clinicopathologic parameters in oral squamous cell carcinoma. *Cancer.* 2007;110(6):1287-1294.
37. Zhao D, Pan J, Li XQ, Wang XY, Tang C, Xuan M. Intratumoral lymphangiogenesis in oral squamous cell carcinoma and its clinicopathological significance. *J Oral Pathol Med.* 2008;37(10):616-25.
38. Lin NN, Wang P, Zhao D, Zhang FJ, Yang K, Chen R. Significance of oral cancer-associated fibroblasts in angiogenesis, lymphangiogenesis, and tumor invasion in oral squamous cell carcinoma. *J Oral Pathol Med.* 2017;46(1):21-30.
39. Mayorca-Guiliani AE, Yano H, Nakashiro KI, Hamakawa H, Tanaka J. Premetastatic vasculogenesis in oral squamous cell carcinoma xenograft-draining lymph nodes. *Oral Oncol.* 2012;48(8):663-670.
40. Pereira ER, Kedrin D, Seano G, et al. Lymph node metastases can invade local blood vessels, exit the node, and colonize distant organs in mice. *Science (80-)*. 2018;359(6382):1403-1407.
41. Lee SY, Chao-Nan Q, Seng OA, et al. Changes in specialized blood vessels in lymph nodes and their role in cancer metastasis. *J Transl Med.* 2012;10(1):206.
42. Shen H, Wang X, Shao Z, et al. Alterations of high endothelial venules in primary and metastatic tumors are correlated with lymph node metastasis of oral and pharyngeal carcinoma. *Cancer Biol Ther.* 2014;15(3):342-349.
43. Chung MK, Do I-G, Jung E, Son Y-I, Jeong H-S, Baek C-H. Lymphatic Vessels and High Endothelial Venules are Increased in the Sentinel Lymph Nodes of Patients with Oral Squamous Cell Carcinoma Before the Arrival of Tumor Cells. *Ann Surg Oncol.* 2012;19(5):1595-1601.
44. Wakisaka N, Hasegawa Y, Yoshimoto S, et al. Primary tumor-secreted lymphangiogenic factors induce pre-metastatic lymphovascular niche formation at sentinel lymph nodes in oral squamous cell carcinoma. *PLoS One.* 2015;10(12):1-14.
45. Grivennikov SI, Greten FR, Karin M. Immunity, Inflammation, and Cancer. *Cell.* 2010;140(6):883-899.
46. Takeya M, Komohara Y. Role of tumor-associated macrophages in human malignancies: friend or foe? *Pathol Int.* 2016;66(9):491-505.
47. Weber M, Büttner-Herold M, Hyckel P, et al. Small oral squamous cell carcinomas with nodal lymphogenic metastasis show increased infiltration of M2 polarized macrophages - An immunohistochemical analysis. *J Cranio-Maxillofacial Surg.* 2014;42(7):1087-1094.
48. Ni Y-H, Ding L, Huang X-F, Dong Y, Hu Q-G, Hou Y-Y. Microlocalization of CD68+ tumor-associated macrophages in tumor stroma correlated with poor clinical outcomes in oral squamous cell carcinoma patients. *Tumour Biol.* 2015;36(7):5291-8.
49. Yamagata Y, Tomioka H, Sakamoto K, et al. CD163-Positive Macrophages Within the Tumor Stroma Are Associated With Lymphangiogenesis and Lymph Node Metastasis in Oral Squamous Cell Carcinoma. *J Oral Maxillofac Surg.* 2017;75(10):2144-2153.
50. Wehrhan F, Büttner-Herold M, Hyckel P, et al. Increased malignancy of oral

1
2
3 squamous cell carcinomas (oscc) is associated with macrophage polarization in
4 regional lymph nodes – an immunohistochemical study. *BMC Cancer*.
5 2014;14(1):522.
6
7
8
9
10
11
12
13
14
15
16
17
18
19
20
21
22
23
24
25
26
27
28
29
30
31
32
33
34
35
36
37
38
39
40
41
42
43
44
45
46
47
48
49
50
51
52
53
54
55
56
57
58
59
60

For Review Only

Figure legends

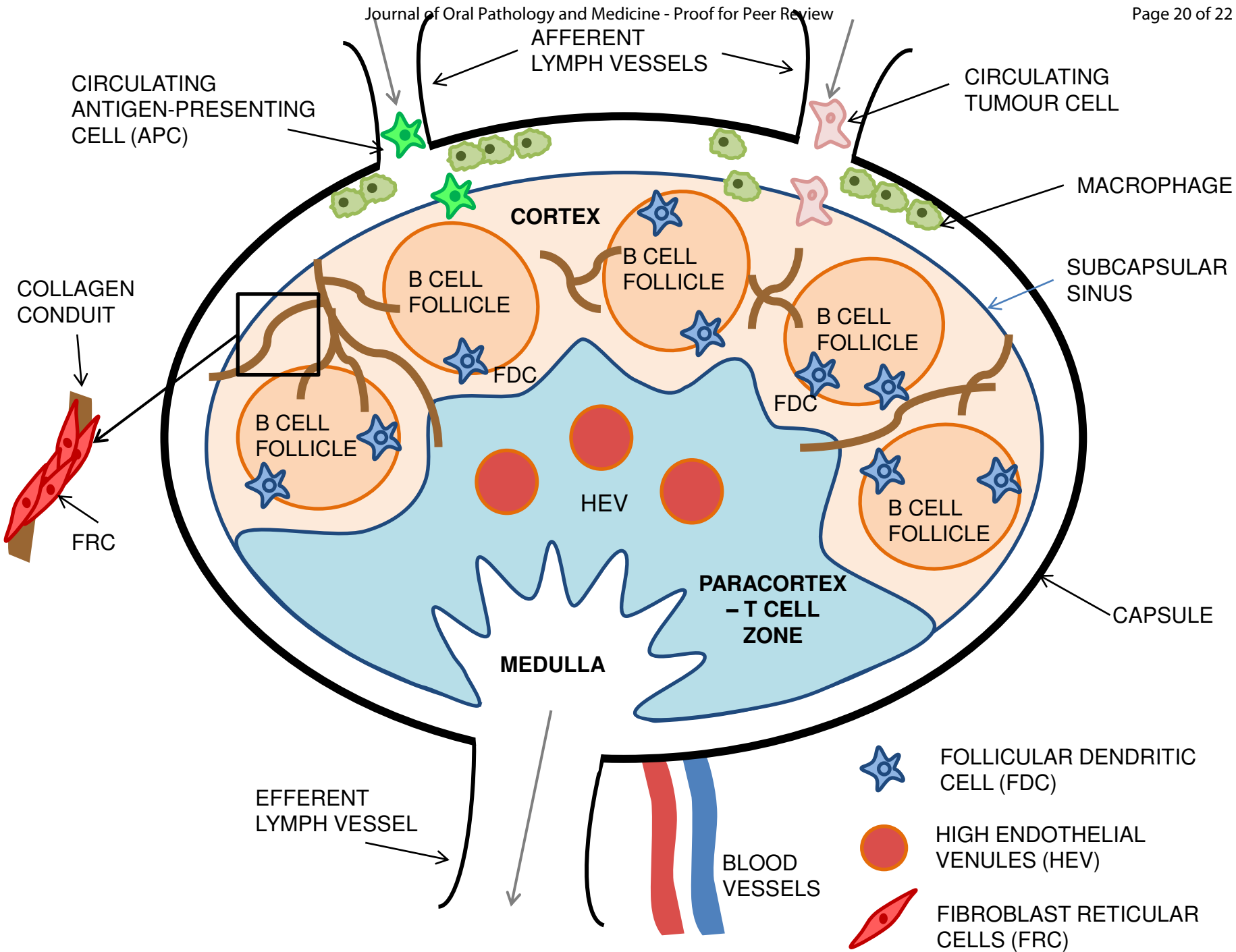
Figure 1: Structure of the lymph node and infiltration by tumour cells. Cancer cells enter the lymph node via afferent lymph vessels along with antigen presenting cells. The subcapsular sinus prevents fluid from entering the cortical areas but allows active cellular transport, including that of cancer cells. Macrophages in the subcapsular sinus are capable of sampling large antigens for presentation to B cells. B cell zones are found in the cortex along with follicular dendritic cells (FDC) which form a supportive network, and secrete a wide range of immune cell modulators with T cells contained with the paracortex. Collagen conduits formed by fibroblastic reticular cells (FRC) carry fluid around the lymph node and blood vessels carrying naïve lymphocytes enter via the high endothelial venules (HEV) in the paracortex. Lymph fluid is drained from the node via the efferent lymph vessels.




Figure 2: Histological images of lymph node metastasis and extranodal extension. Lymph node OSCC tumour specimens stained with haematoxylin and eosin (H&E) showing metastatic deposits without (top) and with (bottom) extranodal extension.

Figure 3: Cells and components of the tumour microenvironment (TME). Malignant epithelial cancer cells are supported by a number of stromal cells that make up the TME. Cancer associated fibroblasts (CAFs) promote tumour development through the secretion of a range of growth factors, proteases and cytokines as well as secreting and remodelling the extracellular matrix (ECM). Blood and lymphatic vessels are important structures in the TME and represent key routes of metastasis. Tumour cells, alongside CAFs, recruit inflammatory innate immune cells to the tumour site, such as tumour-associated macrophage (TAMs). TAMs themselves are able to promote tumour growth, vessel formation and ECM modulation as well as inhibiting anti-tumour immune responses.

Figure 4: Immunohistochemical staining of α -smooth muscle actin (α SMA) in ENE-positive patient tissue specimens. Immunohistochemical staining of α SMA in primary tumour (left) and lymph node tumour (right) ENE-positive OSCC patient tissue specimens showing α SMA-positive stroma surrounding tumour islands. x10 magnification, scale bars 200 μ m.

1
2
3
4
5
6
7
8
9
10
11
12
13
14
15
16
17
18
19
20
21
22
23
24
25
26
27
28
29
30
31
32
33
34
35
36
37
38
39
40
41



-  FOLLICULAR DENDRITIC CELL (FDC)
-  HIGH ENDOTHELIAL VENULES (HEV)
-  FIBROBLAST RETICULAR CELLS (FRC)

1
2
3
4
5
6
7
8
9
10
11
12
13
14
15
16
17
18
19
20
21
22
23
24
25
26
27
28
29
30
31
32
33
34
35
36
37
38
39
40
41
42
43
44
45
46
47
48
49
50
51
52
53
54
55
56
57
58
59
60

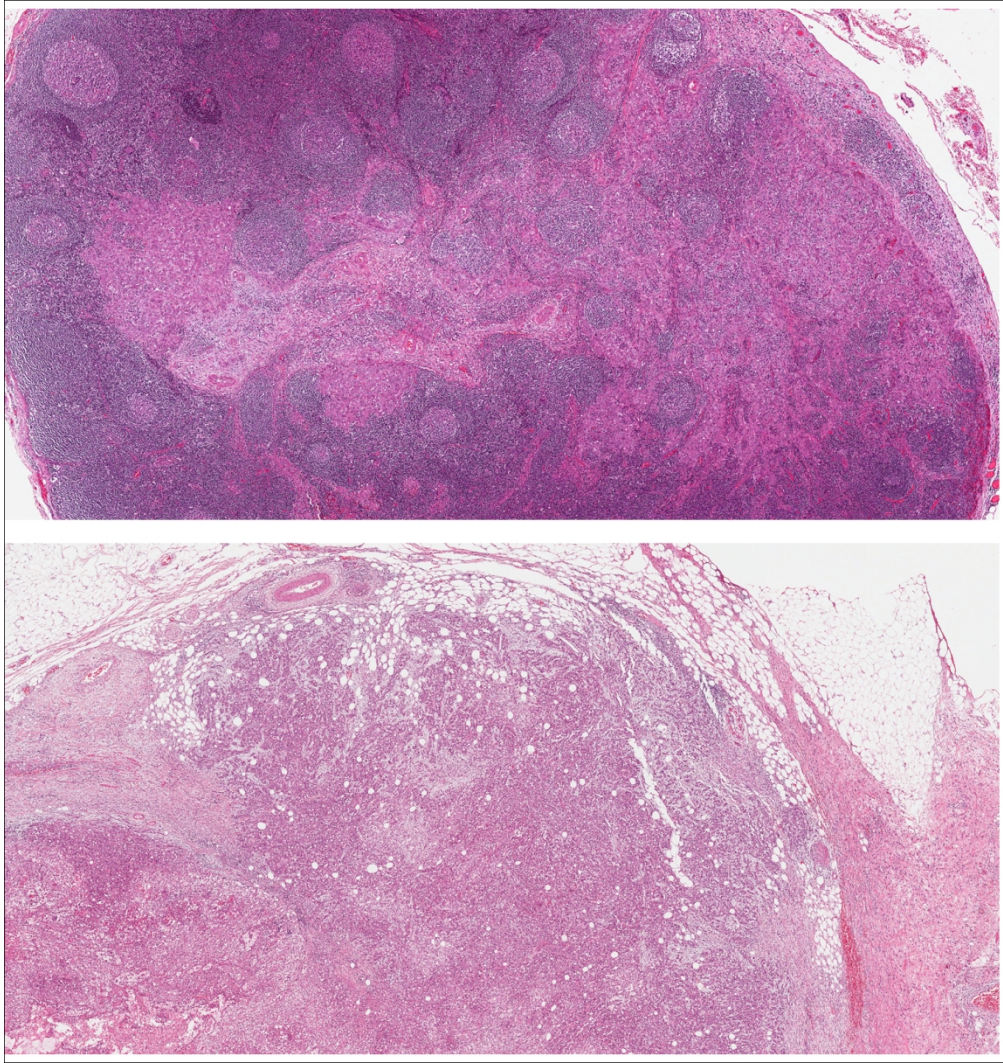
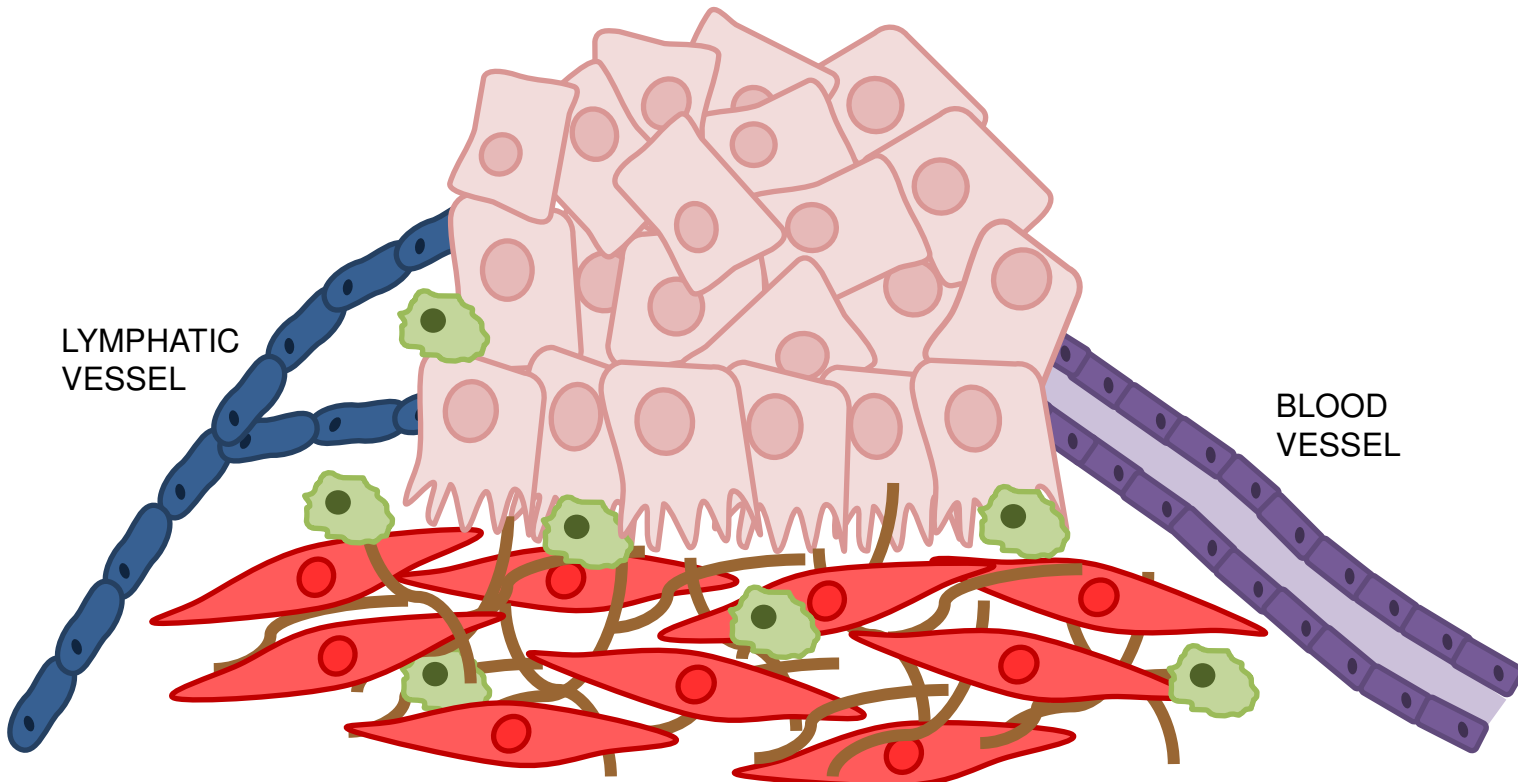


Figure 2: Histological images of lymph node metastasis and extranodal extension. Lymph node OSCC tumour specimens stained with haemotoxylin and eosin (H&E) showing metastatic deposits without (top) and with (bottom) extranodal extension.

254x270mm (150 x 150 DPI)



LYMPHATIC
VESSEL

BLOOD
VESSEL



CANCER CELL



LYMPHATIC
ENDOTHELIAL
CELL



EXTRACELLULAR
MATRIX (ECM)



CANCER-
ASSOCIATED
FIBROBLAST (CAF)



MICROVASCULAR
ENDOTHELIAL
CELL



TUMOUR-ASSOCIATED
MACROPHAGE (TAM)

1
2
3
4
5
6
7
8
9
10
11
12
13
14
15
16
17
18
19
20
21
22
23
24
25
26
27
28
29
30
31
32
33
34
35
36
37
38
39
40
41

1
2
3
4
5
6
7
8
9
10
11
12
13
14
15
16
17
18
19
20
21
22
23
24
25
26
27
28
29
30
31
32
33
34
35
36
37
38
39
40
41
42
43
44
45
46
47
48
49
50
51
52
53
54
55
56
57
58
59
60

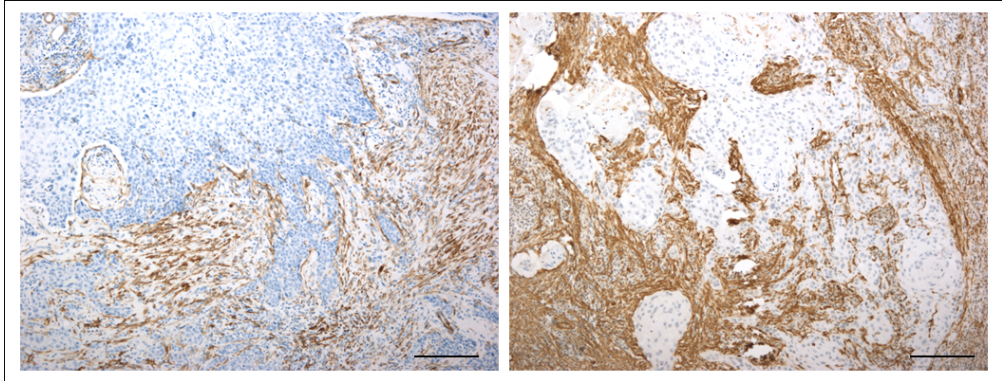


Figure 4: Immunohistochemical staining of α -smooth muscle actin (α SMA) in ENE-positive patient tissue specimens. Immunohistochemical staining of α SMA in primary tumour (left) and lymph node tumour (right) ENE-positive OSCC patient tissue specimens showing α SMA-positive stroma surrounding tumour islands. x10 magnification, scale bars 200 μ m.

178x68mm (150 x 150 DPI)