



This is a repository copy of *Cardiac auscultation: normal and abnormal*.

White Rose Research Online URL for this paper:
<http://eprints.whiterose.ac.uk/145443/>

Version: Accepted Version

Article:

Warriner, D., Michaels, J. and Morris, P.D. orcid.org/0000-0002-3965-121X (2019) Cardiac auscultation: normal and abnormal. *British Journal of Hospital Medicine*, 80 (2). C28-C31. ISSN 1750-8460

[10.12968/hmed.2019.80.2.C28](https://doi.org/10.12968/hmed.2019.80.2.C28)

This document is the Accepted Manuscript version of a Published Work that appeared in final form in *British Journal of Hospital Medicine*, copyright © MA Healthcare, after peer review and technical editing by the publisher. To access the final edited and published work see <https://doi.org/10.12968/hmed.2019.80.2.C28>

Reuse

Items deposited in White Rose Research Online are protected by copyright, with all rights reserved unless indicated otherwise. They may be downloaded and/or printed for private study, or other acts as permitted by national copyright laws. The publisher or other rights holders may allow further reproduction and re-use of the full text version. This is indicated by the licence information on the White Rose Research Online record for the item.

Takedown

If you consider content in White Rose Research Online to be in breach of UK law, please notify us by emailing eprints@whiterose.ac.uk including the URL of the record and the reason for the withdrawal request.



eprints@whiterose.ac.uk
<https://eprints.whiterose.ac.uk/>

Cardiac Auscultation: normal and abnormal

Dr David Warriner¹, Dr Joshua Michaels², Dr Paul D Morris^{3,4}

Dr Warriner is a senior cardiology registrar (St7), Dr Michaels is a Foundation Year 2 (FY2) doctor and Dr Morris is NIHR Clinical Lecturer and BCIS Fellow.

- 1) Department of Adult Congenital Heart Disease, Leeds General Infirmary, Great George St, Leeds, United Kingdom, LS1 3EX
- 2) Department of General Medicine Harrogate District General Hospital, Lancaster Park Road, Harrogate, United Kingdom, HG2 7SX,
- 3) Department of Interventional Cardiology, Victoria Heart Institute Foundation, Royal Jubilee Hospital, Victoria, British Columbia, Canada.
- 4) Department of Infection, Immunity and Cardiovascular Disease, University of Sheffield, Sheffield, UK

Abstract

Hippocrates first documented the pivotal role that cardiac auscultation plays in facilitating clinical diagnosis in 400 BC and despite the increasing availability of investigations such as echocardiography, such tests must be considered in the context of the history and the examination, which remain central to reaching an accurate diagnosis. Cardiac auscultation is often examined in post-graduate qualifications; it requires a structured approach and the use of manoeuvres to augment subtle differences in the characteristics of murmurs and added sounds. All doctors, regardless of speciality, are required to be proficient in performing and interpreting cardiac auscultation.

Short Title

Hippocrates first documented the pivotal role that cardiac auscultation plays in facilitating clinical diagnosis in 400 BC and despite the increasing availability of investigations such as echocardiography, mastering cardiac auscultation remains gatekeeper to these tests.

Conflicts of Interest: None to declare.

Key Words:

Heart sounds

Murmurs

Cardiac auscultation

Background

The pivotal role that cardiac auscultation plays in facilitating clinical diagnosis was documented first by Hippocrates (460 to 370 BC). Point of care ultrasound (POCUS) is increasingly being utilised to provide highly detailed images, such that the work of the ears is being bypassed for that of the eyes, yet clinical assessment remains gatekeeper to these tests. The importance of cardiac auscultation is still reflected in postgraduate medical and surgical examinations, which necessarily demand a high level of skill.

The Heart Sounds

Heart sounds are the normal audible reverberations generated during the closure of the cardiac valves, the character of which is governed by chamber architecture, blood pressure, valvular orifice size and electrical propagation.

The first heart sound, S_1 ("lub"), is the sound of both atrioventricular (AV) valves closing which occurs when ventricular pressures exceeds atrial pressure at the start of ventricular systole.

The mitral component occurs first (M_1), quickly followed by the tricuspid component (T_1). The second heart sound, S_2 ("dub"), is the sound of both semilunar valves closing. This occurs when the pressure in the pulmonary artery and aorta exceed ventricular pressure at the start of ventricular diastole. The aortic component occurs first (A_2), quickly followed by the pulmonary component (P_2). The first two heart sounds are physiologically normal and the components of S_1 and S_2 are not usually well differentiated because they occur almost simultaneously.

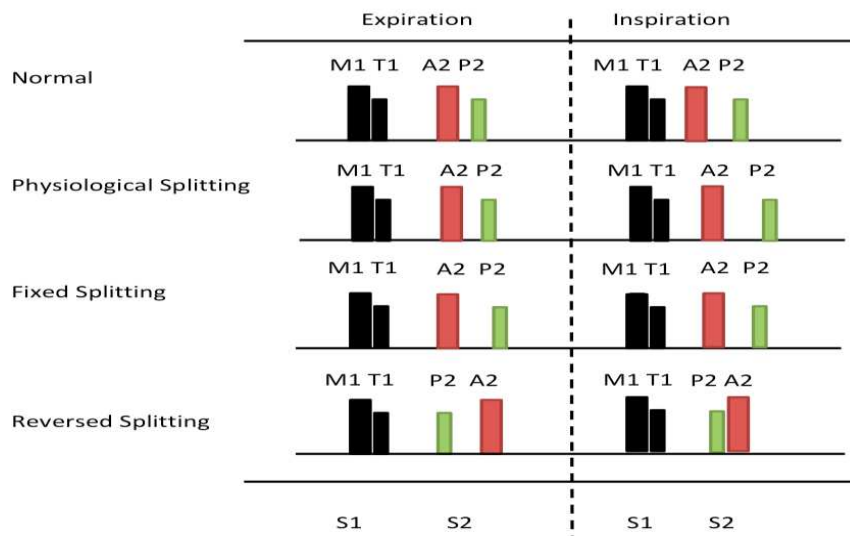
Less commonly heard are third and fourth heart sounds. A third heart sound S_3 (lub-de-dub) may be heard. S_3 reflects rapid ventricular filling during early diastole, immediately after S_2 . It can be normal in isolation in the young or athletes, but is pathological in association with a fourth heart sound. A fourth heart sound S_4 (le-lub-dub) is always pathological, occurring in late diastole immediately before S_1 , as a result of atrial contraction forcing blood into abnormally stiff ventricle. Common causes of an S_4 include cardiomyopathies or increased cardiac afterload. The presence of all 4 heart sounds is known as a gallop rhythm (le-lub-de-dub), rather like the hooves of a trotting horse and is a feature of acute heart failure.

Heart sound intensity

The intensity of S_1 is dependent upon body habitus, PR interval, AV valvular mobility and LV contraction velocity. Thus, S_1 is commonly quieter in the presence of obesity, a long PR interval or hypodynamic LV. The intensity of S_2 is dependent upon ventriculo-arterial valvular mobility and so the A_2 component can be quiet or even absent in severe aortic stenosis (AS).

Splitting of the second heart sounds: physiological, paradoxical, variable and fixed (see figure 1).

Figure 1: Splitting of the second heart sound



Physiological splitting of S₂ refers to A₂ occurring before P₂ during inspiration, so that both are individually audible. Inspiration increases right heart venous return, thus prolonging right ventricular (RV) systole, relative to the LV, and so the pulmonary valve (PV) closes after the aortic valve (AoV). This disappears during expiration.

Reversed (or paradoxical) splitting refers to when the split is heard during expiration, not inspiration. Any process that prolongs LV systole and /or AoV closure can cause this. Examples include AS, hypertrophic cardiomyopathy (HCM) or left bundle branch block (LBBB). So the P₂ component is heard first, then A₂.

Persistent splitting of S₂ refers to when A₂ and P₂ are audible separately throughout the respiratory cycle, but the interval prolongs with inspiration. It occurs secondary to processes which prolong RV systole and/or PV closure e.g. right bundle branch block (RBBB), pulmonary hypertension (PH) or pulmonary stenosis (PS) or processes which hastens LV systole and/or AoV closure e.g. mitral regurgitation (MR) or a ventriculoseptal defect (VSD).

Fixed splitting refers to splitting with a constant closure interval without respiratory variation. This is usually due to the presence of an atrial septal defect (ASD), which abnormally loads the RV (left to right shunt), meaning the RV volume continually exceeds the LV, thus RV systole and PV opening are prolonged.

Extra Heart Sounds: clicks, snaps, knocks and plops.

Extra heart sounds tend to be named onomatopoeically, for example, a tumour 'plop' is an early diastolic low pitched sound just after S_2 . This rare but characteristic sound occurs in atrial myxoma, if the tumour is large enough and its stalk long enough to allow it to move through the AV valve (typically the MV). A mammary 'soufflé' is a rarely heard vascular bruit (systolic and diastolic components) with a blowing quality heard during pregnancy and until the end of lactation, radiating from the vascular breast tissue. Rarely, A early systolic ejection 'click' is caused by thickened AoV leaflets in AS as opposed to an opening 'snap' is caused by thickened valve leaflets, typically in mitral stenosis (MS), early in diastole. A pericardial knock is heard during early diastole in constrictive pericarditis, a variant of S_3 , due to rapid ventricular filling abruptly halted by the taut pericardium, preventing full diastole. Finally, in acute pericarditis, a friction rub is commonly audible which is said to resemble a crunch, like treading in fresh snow.

Flow murmur

Flow murmurs are also known as functional, physiological or benign murmurs. They arise as a result of increased flow across the cardiac valves, due to high output states, tachycardia, increased venous return or reduced systemic vascular resistance. Examples include pyrexia, anaemia, pregnancy or hyperthyroidism. They are typically soft, systolic, position dependent and without an accompanying thrill, in the absence of structural heart disease.

What are Heart Murmurs?

Normal blood flow is laminar and therefore inaudible. Blood flow becomes audible when laminar flow breaks down into disturbed or turbulent flow. This may occur for one of two reasons: increased flow across a normal valve or structure i.e. a flow murmur, or normal flow across an abnormal structure. These two states may co-exist. Whilst murmurs are important clinical signs, they should be interpreted in the context of the remainder of the clinical examination. In an undergraduate assessment, it is usually sufficient to detect a murmur and to formulate a list of likely differential diagnoses but in postgraduate assessment, one will be expected to look for evidence of aetiological factors, markers of severity, complications and decompensation.

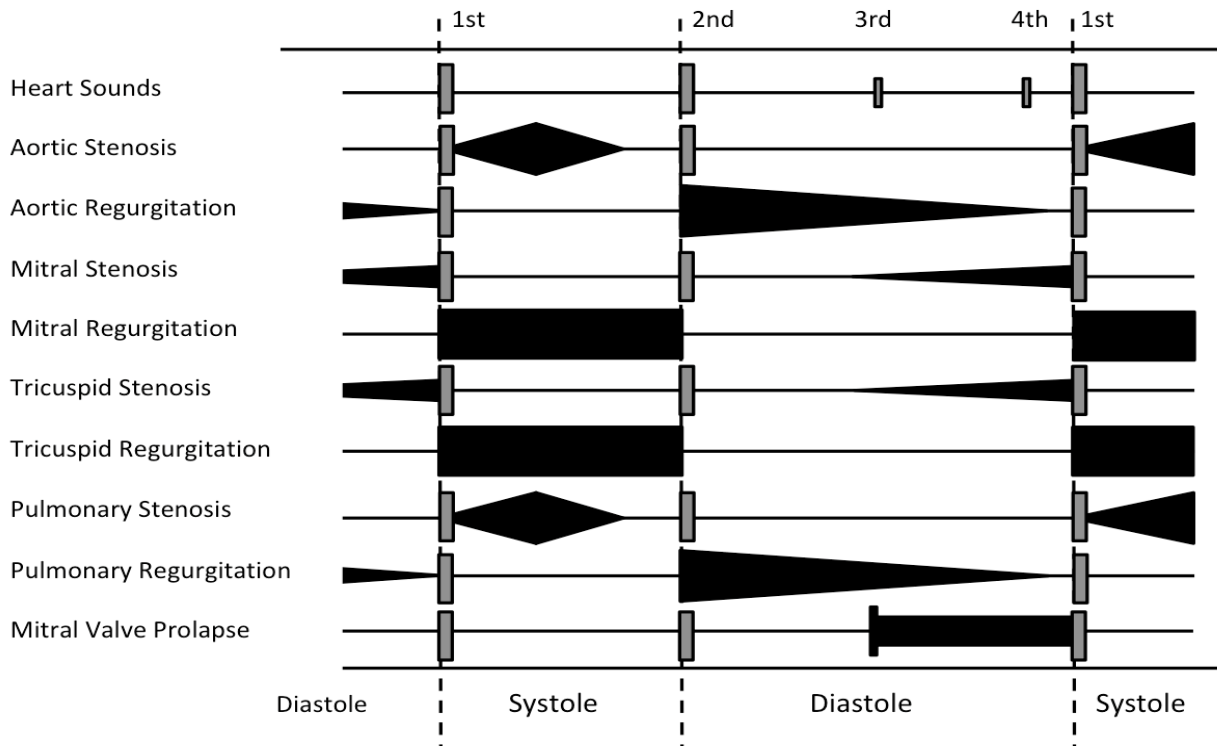
Classification

When a murmur is detected, it should be systematically classified according to timing in the cardiac cycle, phonology, location, radiation, intensity, respiratory variation and tonal quality (see figure 2).

Timing: This is best measured relative to the carotid or subclavian pulse, which should be palpated whilst auscultation is being performed. Note whether the murmur occurs during systole or diastole, whether it occurs early, late or fills the whole of the phase.

Phonological shape: This refers to the intensity of the murmur over time; crescendo (increasing), decrescendo (decreasing) or crescendo-decrescendo (increasing then decreasing).

Figure 2: The phonology of heart sounds and associated murmurs



Location and radiation: Which valve area is the murmur heard loudest and which direction does it propagate? Murmurs radiate in the direction of the blood flow. For example, AS radiates towards the carotids and MR towards the axilla.

Intensity: This refers to the amplitude of the murmur. It is graded according to the Levine scale (see **Table 1**). Amplitude often correlates with the echocardiographic severity of valve disease but this is not always the case. In end-stage AS, with left ventricular failure, reduced trans valvular flow causes a reduction in murmur volume, despite worsening valve disease.

Respiration: Does the murmur intensity vary ventilation? Right heart flow increases on inspiration and through the left heart on expiration. Murmur amplitude rises and falls accordingly. This can be used to deduce if the murmur arises from the left or the right heart.

Quality: Additional, defining components should be noted. Does the murmur sound harsh, high- or low-pitched, rumbling, squeaky, or blowing.

Table 1. Levine Scale of murmur intensity (Levine SA et al, 1933).

1	The murmur is only audible upon considered, lengthy auscultation.
2	The murmur is immediately audible upon auscultation, but faint.
3	The murmur is loud upon auscultation, no palpable thrill.
4	A loud murmur with a palpable thrill (palpable vibration on the chest wall).
5	A loud murmur audible with only superficial auscultation necessary, strong thrill.
6	A loud murmur audible without auscultation with the stethoscope, strong thrill.

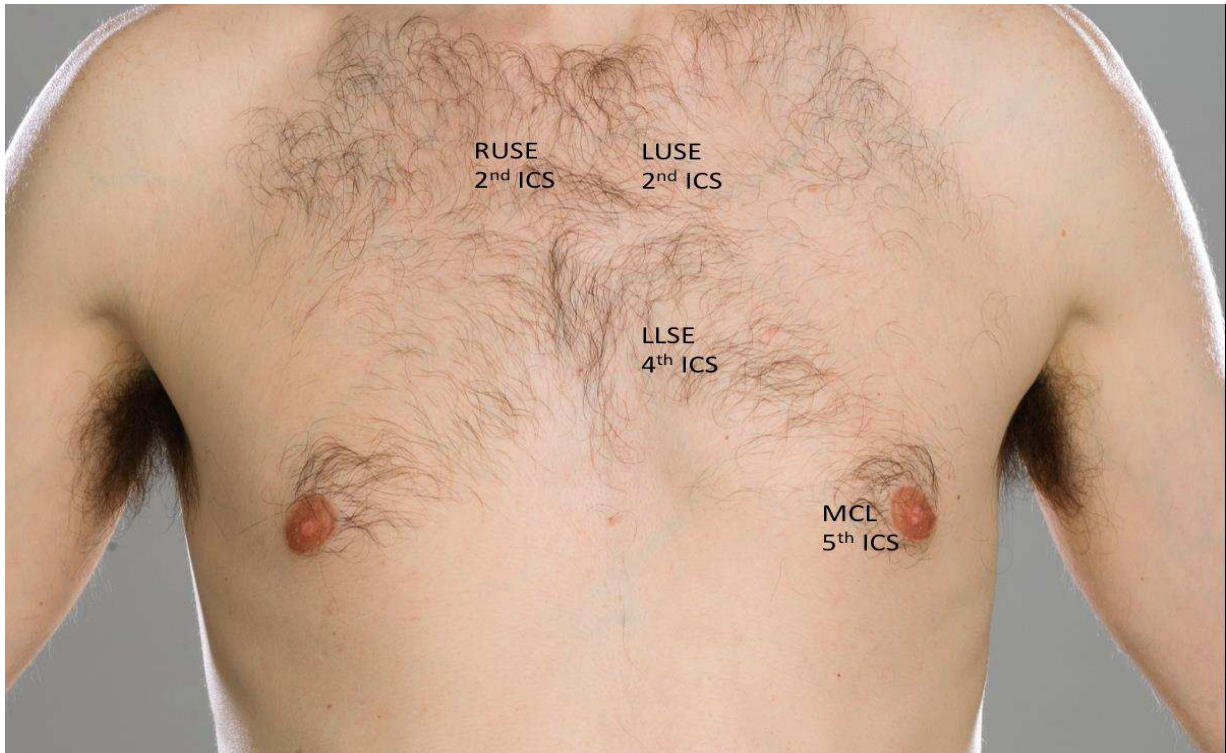
How to auscultate the heart sounds?

Like all components of cardiovascular examination, auscultation should be interpreted within the wider clinical context of the patient's presentation. The examining doctor should be able to tailor their approach according to their findings. Undergraduates must first learn the physical steps of examination which, after practice, becomes second nature. At this point, the examining doctor focuses less about what to do and more on what signs they are eliciting. With more experience, the mind begins to interpret the signs and synthesise a list of possible and likely diagnoses. The following is one way of approaching cardiac auscultation, with practice and experience; doctors develop their own format and style.

Auscultate each valve area (see figure 3) with the stethoscope's diaphragm: mitral, tricuspid, aortic and then pulmonary. Listen during passive inspiration and expiration. By this point you should already have a good idea what the diagnosis might be. Next, do a second 'lap', this time using manoeuvres to amplify murmurs and to either consolidate or discount your working diagnosis e.g.

- 1) Mitral region (5th left intercostal space, mid-clavicular line): Roll the patient on to their left side and listen on full expiration with the diaphragm and bell (for the low pitched mitral stenosis murmur)
- 2) Tricuspid region (lower left sternal edge): listen with patient sat forwards on expiration with the diaphragm.
- 3) Aortic region (right upper sternal edge, 2nd intercostal space): Listen with diaphragm on expiration. If a murmur is heard, does it radiate towards the mitral region or into the carotids?
- 4) Pulmonic region (left upper sternal edge, 2nd intercostal space).
- 5) Also listen to the point half way between the mitral and aortic regions (mid left sternal edge) with patient leaning forward on expiration (a common point at which AR can be heard).

Figure 3. Picture of the praecordium with cardiac auscultation areas.



Key: ICS = intercostal space, LLSE = left lower sternal edge, LUSE = left upper sternal edge, LUSE = right upper sternal edge, MCL = mid-clavicular line.

Systolic murmurs

Aortic stenosis (AS): An ejection systolic murmur loudest at the right upper sternal border, loudest when the patient leans forward and fully exhales. Characteristically radiates to the carotids. Slow rising carotid pulse and quiet A₂ are markers of severity.

Pulmonary stenosis (PS): An ejection systolic murmur loudest during inspiration at the left upper sternal border.

Mitral regurgitation (MR): A pan-systolic murmur, loudest at the mitral region and can be accentuated by the patient lying on their left (which brings the apex towards the chest wall and stethoscope).

Tricuspid regurgitation (TR): A pan-systolic murmur, loudest at the left lower sternal border with radiation towards the left upper sternal border.

Atrial septal defect (ASD): A flow murmur can sometimes be heard, loudest at the left upper sternal border, due to the increased volume of blood from LA to RA then flowing via PV.

Ventricular septal defect (VSD): A pan-systolic murmur loudest at the lower sternal border due to blood flow from LV to RV.

Diastolic murmurs

Aortic regurgitation (AR): An early diastolic, decrescendo murmur, loudest at the mid-lower left sternal edge with the patient sat forwards on expiration.

Pulmonary regurgitation (PR): An early diastolic, decrescendo murmur, loudest at the pulmonary area.

Mitral stenosis (MS): A diastolic, low-pitched (hence using the bell of the stethoscope), rumbling, murmur at the apex, amplified when the patient lies on their left side during expiration. The left ventricle must achieve a greater pressure to exceed the increased left atrial pressure in MS, this causes a delayed S₁ (closure of the MV), because it takes longer to achieve that pressure, as well as a pre-systolic accentuation. There may also be an opening snap.

Tricuspid stenosis (TS): A rare, diastolic, decrescendo murmur, loudest at the left lower sternal border.

Additional murmurs

Patent ductus arteriosus (PDA): Continuous (throughout systole and diastole) machine-like murmur, loudest immediately inferior to the left clavicle, radiating to the back.

Coarctation of the aorta: A continuous machinery murmur, loudest during systole and best heard in the infraclavicular region.

Table 3: Common causes of cardiac murmurs

Systolic				
Disease	Aortic Stenosis	Mitral Regurgitation	Pulmonary Stenosis	Tricuspid Regurgitation
Aetiology	Bicuspid AoV	Chronic Atrial Fibrillation	Congenital PS	Chronic Atrial Flutter
	Calcific Degeneration	Endocarditis	Carcinoid Syndrome	Carcinoid Syndrome
	Congenital AS	LV Dilation	Fallot Tetralogy	Ebstein Anomaly
	Radiotherapy	Marfan Syndrome	Noonan Syndrome	TV Endocarditis
	Rheumatic Heart Disease	Papillary Muscle Rupture	Williams Syndrome	RV Dilation
	Sub-aortic membrane	MV Prolapse	Sub-valvar membrane	Myocardial Infarction
	Williams Syndrome	Rheumatic Heart Disease	Supra-valvar membrane	Pulmonary Embolus
Diastolic				
Disease	Aortic Regurgitation	Mitral Stenosis	Pulmonary Regurgitation	Tricuspid Stenosis
Aetiology	Aortitis or Arteritis	Atrial Myxoma	Absent Valve	Atrial Myxoma
	AoV Endocarditis	Cor Triatriatum	Carcinoid Syndrome	Carcinoid Syndrome
	Ankylosing Spondylitis	Double Orifice MV	PV Endocarditis	Cardiac Surgery
	Aortic Dilation	Mucopolysaccharidoses	Fallots Tetralogy	Lupus
	Aortic Dissection	Mitral Atresia	Pulmonary Hypertension	Radiotherapy
	Bicuspid AoV	Radiotherapy	Prosthetic Valve	Rheumatic Heart Disease
	Calcific Degeneration	Rheumatic Heart Disease	PV Valvuloplasty	Triscupid Atresia

Key: AoV = aortic valve, AS = aortic stenosis, LV = left ventricle, PV = pulmonary valve, PS = pulmonary stenosis, MV = mitral valve, RV = right ventricle, TV = tricuspid valve.

Investigation

After a 12-lead ECG, a trans-thoracic echocardiogram should be performed. This assesses myocardial and valvular structure and function and will often reveal the underlying aetiology, such as a bicuspid AoV leading to AS or papillary muscle dysfunction following a myocardial infarction leading to secondary MR. This will guide subsequent investigation, such as cardiac MRI, trans-oesophageal echocardiogram or invasive cardiac catheterisation.

Conclusions

Cardiac auscultation remains a key skill for all doctors, to corroborate the working diagnosis considered in the wider context of the patient's presentation. It is an oft-examined part of post-graduate qualifications, requiring not only a structured approach but also the use of manoeuvres to exploit differences in murmur characteristics.

Key Points.

- 1) Auscultation should first consider the heart sounds
- 2) A pathological heart murmur is usually caused by either an incompetent or stenotic valve.
- 3) The most commonly examined murmurs are aortic stenosis and mitral regurgitation.
- 4) It is important to appreciate and analyse murmurs fully, not just detect them.

References

Harvey W (1889). *On the motion of the heart and blood in animals*. George Bell & Sons, London.

Levine SA, Freeman AR (1933). *Clinical significance of systolic murmurs: Study of 1000 consecutive "noncardiac" cases*. Ann Intern Med (Internet). (Cited December 2018) ; 6 (11).
Available from: <http://annals.org>