



Deposited via The University of Sheffield.

White Rose Research Online URL for this paper:

<https://eprints.whiterose.ac.uk/id/eprint/143999/>

Version: Accepted Version

---

**Article:**

Mariño-Crespo, Ó., Cuevas-Álvarez, E., Harding, A.L. et al. (2019) Haptoglobin expression in human colorectal cancer. *Histology and Histopathology*, 34 (8). pp. 953-963. ISSN: 0213-3911

<https://doi.org/10.14670/HH-18-100>

---

© Servicio de Publicaciones, Universidad de Murcia, 2019. This is an author produced version of a paper subsequently published in *Histology and Histopathology*. Uploaded in accordance with the publisher's self-archiving policy. Article available under the terms of the CC-BY-NC-ND licence (<https://creativecommons.org/licenses/by-nc-nd/4.0/>).

**Reuse**

This article is distributed under the terms of the Creative Commons Attribution-NonCommercial-NoDerivs (CC BY-NC-ND) licence. This licence only allows you to download this work and share it with others as long as you credit the authors, but you can't change the article in any way or use it commercially. More information and the full terms of the licence here: <https://creativecommons.org/licenses/>

**Takedown**

If you consider content in White Rose Research Online to be in breach of UK law, please notify us by emailing [eprints@whiterose.ac.uk](mailto:eprints@whiterose.ac.uk) including the URL of the record and the reason for the withdrawal request.

# HISTOLOGY AND HISTOPATHOLOGY

ISSN: 0213-3911  
e-ISSN: 1699-5848

Submit your article to this Journal (<http://www.hh.um.es/Instructions.htm>)

## **Upregulation of glucose and amino acid transporters in micropapillary carcinoma**

**Authors:** Kanae Nosaka, Karen Makishima, Tomohiko Sakabe, Yohei Yurugi, Makoto Wakahara, Yasuaki Kubouchi, Yasushi Horie and Yoshihisa Umekita

DOI: 10.14670/HH-18-099

Article type: ORIGINAL ARTICLE

Accepted: 2019-03-11

Epub ahead of print: 2019-03-11

# **Upregulation of glucose and amino acid transporters in micropapillary carcinoma**

Kanae Nosaka<sup>1,2,\*</sup>, Karen Makishima<sup>2</sup>, Tomohiko Sakabe<sup>1</sup>, Yohei Yurugi<sup>3</sup>, Makoto Wakahara<sup>3</sup>, Yasuaki Kubouchi<sup>3</sup>, Yasushi Horie<sup>2</sup>, Yoshihisa Umekita<sup>1,2</sup>

<sup>1</sup>Division of Organ Pathology, Department of Pathology, Faculty of Medicine, Tottori University, Tottori, Japan

<sup>2</sup>Department of Pathology and <sup>3</sup>Department of General Thoracic Surgery, Tottori University Hospital, Tottori, Japan

**Running title:** Transporters in micropapillary carcinoma

**\*Corresponding author:** Dr. Kanae Nosaka, Division of Organ Pathology, Department of Pathology, Faculty of Medicine, Tottori University, 86 Nishi-cho, Yonago, Tottori 683-8503, Japan. Email: knosaka@tottori-u.ac.jp

## Summary

Micropapillary carcinoma (MPC), a relatively rare histologic carcinoma observed in various organs, is associated with vascular invasion, nodal metastasis, and poor prognosis. MPC is different from papillary carcinoma as it has no fibrovascular core and is thus considered essentially hypovascular. MPCs are known to upregulate glucose transporter 1 (GLUT1) via the activation of a transcription factor, hypoxia-inducible factor (HIF)-1. Here we evaluated the expression of nutrient transporters in MPCs to gain a better understanding of the system used by MPCs to compensate for their intrinsic poor vascularity. We immunohistochemically evaluated 29 MPCs including breast (n=14), lung (n=8), gastrointestinal tract (n=5), and urinary tract cancers (n=2) and compared them with non-micropapillary control cancers (n=32) regarding the expression of amino acid (ASCT1, ASCT2, LAT1, and SNAT1) and glucose (GLUT1, GLUT2) transporters. Each section was scored by the staining intensity (0–3) multiplied by the occupying area (0–10), with a possible range 0–30. The average scores of the MPC and control groups were compared by Student's or Welch's t-test according to the homoscedasticity. The MPC group showed markedly and significantly higher scores for ASCT1 ( $p=0.007$ ), ASCT2 ( $p=0.001$ ), GLUT1 ( $p<0.001$ ), and GLUT2 ( $p<0.001$ ), whereas no significant between-group difference was observed in the LAT1 and SNAT1 scores. In conclusion, MPC could be associated with the upregulation of several nutrient transporters, which may contribute to the malignant potential by supporting the survival of cancer cells.

**Key words:** micropapillary carcinoma, GLUT1, GLUT2, ASCT1, ASCT2, LAT1, SNAT1,

hypoxia

HISTOLOGY AND HISTOPATHOLOGY  
(non-edited manuscript)

## **Introduction**

Since the first report by Luna-Moré et al. in 1994, micropapillary carcinoma (MPC) or micropapillary components in several cancers have been a well-known risk factor for blood and/or lymph vessel invasion, lymph node metastasis, and mortality (Nagano et al., 2010; Willis et al., 2014; Lee et al., 2015; Liu et al., 2015). MPCs have been documented in the breast, the lung, the gastrointestinal (GI) tract, and the urothelial cancers, where the presence of MPC is nearly always a sign of poor prognosis (Guzińska-Ustymowicz et al., 2014; Zhang et al., 2015). By definition, an MPC forms delicate papillary tufts devoid of central fibrovascular cores, which makes these papillary tufts different from "true" papillae with cores. Micropapillae are occasionally floating in the lacunar-like space in the fibrous stroma with their apical surfaces outwards; this is known as the "inside-out" growth pattern (Troxell, 2014).

For cancers to progress, vascularity within or around the tumor is thought to be important, since proliferating cancer cells need large amounts of nutrients (Carmeliet and Jain, 2000). MPCs are suspected to be always under a condition of poor nutrition and hypoxia due to their lack of a fibrovascular core (Nagano et al. 2010). However, MPCs are a highly aggressive cancer, and their massive necrosis is rarely observed. We speculated that MPCs have evolved some compensatory system(s) against the poor blood and nutrition supply, and that such compensatory system(s) may contribute to the aggressive behavior and poor prognosis of MPCs.

Glucose transporter 1 (GLUT1), a major glucose transporter of somatic cells, has been shown to be upregulated in MPCs via the activation of the transcription factor hypoxia-inducible factor (HIF)-1 (Nagano et al., 2010; Koh et al., 2017). HIF-1 controls the angiogenesis and accommodation of various cellular activities to hypoxia (Wang and Semenza, 1993; Carmeliet and Jain, 2000). GLUT1 is a representative HIF-1 target gene product. An upregulation of GLUT1 can substantially improve the uptake of glucose, and it supports energy production via accelerated glycolysis. Proliferating cancer cells also require building blocks such as amino acids and lipids other than sugar and oxygen, and several amino acid transporters are known to be upregulated in various cancers (Yanagida et al., 2001; Fuchs and Bode, 2005; Kaira et al., 2009; Fan et al., 2010).

However, the differences in amino acid transporter expression among different carcinoma histologic subtypes have not been fully examined. We hypothesized that MPCs may compensate for their poor vascularity via upregulations of amino acid and sugar transporters such as alanine/serine/cysteine/threonine transporter 1 (ASCT1), ASCT2, L-type amino acid transporter 1 (LAT1), sodium-coupled neutral amino acid transporter 1 (SNAT1), GLUT1, and GLUT2 with more significant augmentation compared to non-MPC cancers, which leads to the MPCs' aggressiveness.

## **Materials and Methods**

### *Case selection*

We retrospectively analyzed surgically resected specimens that had been histologically diagnosed as MPCs or as carcinomas with MPC components at the Department of Pathology, Tottori University Hospital (Yonago, Japan) during the years 2004–2016, regardless of the patients' age, sex or tumor stage (Table 1). Small cancers with an invasion diameter <1 cm and mixed MPC component <10% were excluded. Cases with suspicious antigen degeneration (e.g., insufficient staining of inner positive controls in an immunohistochemical procedure) were also excluded. The final total of 29 MPC cases included 14 breast cancers, 8 lung cancers, 5 gastrointestinal (GI) cancers, and 2 urothelial cancers. Five of the breast cancers were pure MPCs, and the remaining 24 MPCs were mixed cancers with conventional histological subtypes. We also selected 32 control cases from the above-mentioned organs. Control cases of lung adenocarcinoma were selected in order to not deviate from the specific histological subtype.

Written informed consent for their materials to be used was obtained from each patient, and the study was approved by the Ethics Committee of the Faculty of Medicine, Tottori University (approval no. 1707A071; July 13, 2017).

### *Immunohistochemistry and scoring*

The primary antibodies used in this study are listed in Table 2. The upregulation of all of the target transporters in cancers has been reported. Paraffin-embedded formalin-fixed tissue of the cancers were cut into 4- $\mu$ m slices and placed on silane-coated glass slides. After being baked at 70°C for 30 min, the sections were deparaffinized and hydrated in xylene and a concentration-gradient ethanol-water system. Endogenous peroxidase activity was quenched in 30% aqueous H<sub>2</sub>O<sub>2</sub> with methanol (10% v/v). Sections were heated to 95°C in pH 6.0 citrate buffer for 20 min for antigen retrieval, then cooled to room temperature. After blocking with Block Ace solution (4 g/100 ml; DS Pharma Biomedical, Osaka, Japan), the sections were incubated with each primary antibody at 4°C overnight.

After being washed with phosphate-buffered saline (PBS) containing Tween, the slides were incubated with secondary antibody (EnVision Dual link system; Dako, Glostrup, Denmark) for 30 min. Antigen-antibody complex was visualized by a Liquid DAB+ Substrate Chromogen System (Dako), then counterstained with hematoxylin.

For a quantitative evaluation of the expression of each transporter, every slide was scored based on its average staining intensity (1: weak, 2: moderate, 3: strong) multiplied by the positive ratio per tumor area (0: 0%, 1: 1%–10%, 2: 11%–20%, 3: 21%–30%, 4: 31%–40%, 5: 41%–50%, 6: 51%–60%, 7: 61%–70%, 8: 71%–80%, 9: 81%–90%, 10: 91%–100%), resulting in a score from 0 to 30. For the MPC cases, only the MPC components were evaluated, and for the non-MPC cases (CONT), all the cancer areas were evaluated. Two

pathologists (KN and KM) scored the slides individually, and the similarity of the scores by the two observers was statistically confirmed. KM was blinded to the purpose of this study while scoring.

### *Statistical analyses*

We first examined the homoscedasticity of the score distribution in the MPC and control groups by using the Levine test. If the score distribution was found to be homoscedastic, the average scores of the MPC versus control cases were compared with Student's t-test. When the distribution was not homoscedastic, the average scores were compared with Welch's t-test. The difference was considered significant when  $p < 0.05$ . The Statistical Package for Social Sciences ver. 24 (IBM SPSS Statistics; IBM, Armonk, NY) was used in all statistical analyses.

## **Results**

### *The staining patterns of the transporters*

Representative staining patterns of the respective transporters are shown in Figure 1. ASCT1 showed a linear staining pattern on the basolateral membrane. Weak to moderate cytoplasmic staining was often observed. Plasma cells served as inner positive controls. ASCT2 showed fine granular cytoplasmic staining with faint membranous staining. Adipocytes served as inner positive controls.

GLUT1 showed intense membranous staining. Erythrocytes served as inner positive controls. GLUT2 showed only a finely granular cytoplasmic staining pattern, in contrast to the membranous staining of hepatocytes in our examination determining the optimal conditions for staining. LAT1 showed a linear staining pattern along the basolateral membrane. Vascular smooth muscle cells served as inner positive controls. SNAT1 showed a coarse granular cytoplasmic staining pattern. In the breast cancers, non-neoplastic ductal epithelium served as inner positive controls.

*The staining scores of the MPC vs. control cases in the respective organs*

The staining scores of the MPCs and control cases are summarized in Table 3. The ASCT1, ASCT2, GLUT1, and GLUT2 scores were significantly higher in the MPC group. No significant difference was revealed in the LAT1 or SNAT1 scores (Fig. 2).

**Discussion**

GLUT1 upregulation was predictable considering MPCs' intrinsic hypoxia due to a structural factor. Higher GLUT1 expression in MPCs was histologically confirmed in lung adenocarcinomas (Nagano et al., 2010; Koh et al., 2017), and a facilitated uptake of 2-<sup>18</sup>fluoro-deoxy-D-glucose (<sup>18</sup>FDG) by lung MPCs on positron emission tomography has also been reported (Nakamura et al., 2015). Our present findings indicate that the augmented expression of GLUT1 in MPC is an almost universal event, not restricted to lung cancer.

GLUT2 is a glucose and fructose transporter with high capacity and low affinity that is thought to act as a glucose sensor molecule of hepatocytes and islet  $\beta$  cells of the pancreas. GLUT2 is also thought to facilitate glucose absorption at the small intestine when the glucose level is significantly elevated, e.g., after a meal (Mueckler and Thorens, 2013). GLUT2 is also known to act as a glucosamine transporter (Uldry et al., 2002), but it is unclear whether this role is beneficial to MPC. Although GLUT2 upregulation in pancreatic and liver cancers is well known, its overexpression in cancers in extra-hepatobiliary organs has not been well investigated (Godoy et al., 2006; Kim et al., 2017). It is intriguing that GLUT2 is usually detected in the cancer cell cytoplasm and not as the membranous staining of normal control cells such as human hepatocytes. It is reported that insulin internalizes membrane-bound GLUT2 to the cytosol (Tobin et al., 2008). Whether this membrane-to-cytoplasm translocation of GLUT2 has some relation to cancer activities remains to be solved.

Several amino acid transporters such as ASCT2 and LAT1 are often upregulated in cancers (Yanagida et al., 2001; Fuchs and Bode, 2005; Kaira et al., 2009; Fan et al., 2010; Wang et al., 2013). In fact, in the present study the scores for the ASC transporters (ASCT1, ASCT2) were markedly higher in the MPC group. ASCT2, a gene product of *SLC1A5*, is a member of the ASC system which transports neutral amino acids such as Ala, Ser, Cys, and glutamine (Fuchs and Bode, 2005). This transporter is thought to be controlled by another hypoxia-sensing factor (HIF2 $\alpha$ ) to some extent, via a transduction pathway using lactate as a signal molecule (Pérez-Escuredo et al., 2016). ASCT2 upregulation may thus be reasonable in

hypoxic and presumably glycolysis-dependent MPCs.

LAT1 is known to be overexpressed in many cancers (Yanagida et al., 2001; Kaira et al., 2009; Fan et al., 2010), and its overexpression correlates with worse prognosis. However, no significant difference in the expression of LAT1 was demonstrated in the present study. Although SNAT1 is thought to have a critical role in cancers (Wang et al., 2013), no significant difference in the SNAT1 score was demonstrated herein. These transporters' overexpression may be related to the cancer activity itself and have no association with MPCs' structure or their compensatory system.

Our present findings suggest that MPCs can efficiently compensate for their hypoxia and poor nutrition by upregulating several nutrient transporters, and the hypoxia itself can be quite beneficial for the MPCs' utilization of nutrients from the environment. In addition, the cell division of MPCs has been suggested to be less active compared to other histological subtypes (Ishii et al., 2011; Zhang et al., 2015), which may make MPCs more "economic," enabling them to survive severe conditions until they reach a more suitable field for tumor growth. However, an immunohistochemical analysis is merely a subjective assessment, and we examined a relatively small number of cases in the present study. Objective evaluations using molecular biological approaches with larger collections of MPC cases are needed.

In conclusion, this is the first study to investigate the difference in the metabolic state of cancers, focusing on MPC, a specific histological subtype. We speculate that respective histological subtypes may differ not only in proliferation and/or invasion activity, but also in

oxygenation, nutrition, and secondary compensatory systems. Our present findings also demonstrate an example of cancer cell accommodation to the environment. Closer investigations of the relationship between histological subtypes and metabolic states will lead us to a better understanding of complex cancer behavior and more effective anti-cancer strategies.

### **Acknowledgements**

We thank Dr. Takashi Ohno, Dr. Yoshiteru Kidokoro, and Dr. Taichi Kadonaga (Tottori University Hospital, Japan) for providing surgical and clinical knowledge. We also thank Ms. Yuko Urakami for her excellent technical assistance with the pathological specimens' processing.

### **Author contributions**

KN designed the study. KM and TS conducted the validation analysis. YY and MW reviewed the cases and provided the clinical information. YK prepared recent specimens for this study.

All pre-2014 cases were diagnosed by YH. KN and YU analyzed the data and wrote the manuscript. All authors read the manuscript and approved its submission.

## Conflict of interest

The authors confirm that there are no conflicts of interest.

## References

Carmeliet P. and Jain R.K. (2000). Angiogenesis in cancer and other diseases. *Nature*. 407, 249-257.

Fan X., Ross D.D., Arakawa H., Ganapathy V., Tamai I. and Nakanishi T. (2010). Impact of system L amino acid transporter 1 (LAT1) on proliferation of human ovarian cancer cells: A possible target for combination therapy with anti-proliferative aminopeptidase inhibitors. *Biochem. Pharmacol.* 80, 811-818.

Fuchs B.C. and Bode B.P. (2005). Amino acid transporters ASCT2 and LAT1 in cancer: Partners in crime? *Semin. Cancer Biol.* 15, 254-266.

Godoy A., Ulloa V., Rodríguez F., Reinicke K., Yañez A.J., García Mde L., Medina R.A., Carrasco M., Barberis S., Castro T., Martínez F., Koch X., Vera J.C., Poblete M.T., Figueroa C.D., Peruzzo B., Pérez F. and Nualart F. (2006). Differential subcellular distribution of glucose transporters GLUT1-6 and GLUT9 in human cancer: Ultrastructural localization of GLUT1 and GLUT5 in breast tumor tissues. *J. Cell. Physiol.* 207, 614-627.

Guzińska-Ustymowicz K., Niewiarowska K. and Pryczynicz A. (2014). Invasive micropapillary carcinoma: A distinct type of adenocarcinomas in the gastrointestinal

tract. *World J. Gastroenterol.* 20, 4597-4606.

Ishii S., Ohbu M., Toomine Y., Nishimura Y., Hattori M., Yokoyama M., Toyonaga M.,

Kakinuma H. and Matsumoto K. (2011). Immunohistochemical, molecular, and clinicopathological analyses of urothelial carcinoma, micropapillary variant. *Pathol. Int.* 61, 723-730.

Kaira K., Oriuchi N., Imai H., Shimizu K., Yanagitani N., Sunaga N., Hisada T., Ishizuka T.,

Kanai Y., Nakajima T. and Mori M. (2009). Prognostic significance of L-type amino acid transporter 1 (LAT1) and 4F2 heavy chain (CD98) expression in stage I

pulmonary adenocarcinoma. *Lung Cancer.* 66, 120-126.

Kim Y.H., Jeong D.C., Pak K., Han M.E., Kim J.Y., Liangwen L., Kim H.J., Kim T.W., Kim

T.H., Hyun D.W. and Oh S.O. (2017). SLC2A2 (GLUT2) as a novel prognostic factor for hepatocellular carcinoma. *Oncotarget.* 8, 68381-68392.

Koh Y.W., Lee S.J., Park S.Y. (2017). Differential expression and prognostic significance of

GLUT1 according to histologic type of non-small-cell lung cancer and its association with volume-dependent parameters. *Lung Cancer.* 104, 31-37.

Lee G., Lee H.Y., Jeong J.Y., Han J., Cha M.J., Lee K.S., Kim J. and Shim Y.M. (2015).

Clinical impact of minimal micropapillary pattern in invasive lung adenocarcinoma: prognostic significance and survival outcomes. *Am. J. Surg. Pathol.* 39, 660-666.

Liu F., Yang M., Li Z., Guo X., Lin Y., Lang R., Shen B., Pringle G., Zhang X. and Fu L.

(2015). Invasive micropapillary mucinous carcinoma of the breast is associated with

poor prognosis. *Breast Cancer Res. Treat.* 151, 443-451.

Luna-Moré S., Gonzalez B., Acedo C., Rodrigo I. and Luna C. (1994). Invasive micropapillary carcinoma of the breast. A new special type of invasive mammary carcinoma. *Pathol. Res. Pract.* 190, 668-674.

Mueckler M. and Thorens B. (2013). The SLC2 (GLUT) family of membrane transporters. *Mol. Aspects Med.* 34, 121-138.

Nagano T., Ishii G., Nagai K., Ito T, Kawase A., Takahashi K., Nishimura Y., Nishiwaki Y. and Ochiai A. (2010). Structural and biological properties of a papillary component generating a micropapillary component in lung adenocarcinoma. *Lung Cancer.* 67, 282-289.

Nakamura H., Saji H., Shinmyo T., Tagaya R., Kurimoto N., Koizumi H. and Takagi M. (2015). Close association of IASLC/ATS/ERS lung adenocarcinoma subtypes with glucose-uptake in positron emission tomography. *Lung Cancer.* 87, 28-33.

Pérez-Escuredo J., Dadhich R.K., Dhup S., Cacace A., Van Hée V.F., De Saedeleer C.J., Sboarina M., Rodriguez F., Fontenille M.J., Brisson L., Porporato P.E. and Sonveaux P. (2016). Lactate promotes glutamine uptake and metabolism in oxidative cancer cells *Cell Cycle.* 15, 72-83.

Tobin V., Le Gall M., Fioramonti X., Stolarczyk E., Blazquez A.G., Klein C., Prigent M., Serradas P., Cuif M.H., Magnan C., Leturque A. and Brot-Laroche E. (2008). Insulin internalizes GLUT2 in the enterocytes of healthy but not insulin-resistant mice.

Diabetes. 57, 555-562.

Troxell M.L. (2014). Reversed MUC1/EMA polarity in both mucinous and micropapillary breast carcinoma. *Hum. Pathol.* 45, 432-434.

Uldry M., Ibberson M., Hosokawa M. and Thorens B. (2002). GLUT2 is a high affinity glucosamine transporter. *FEBS Lett.* 524, 199-203.

Wang G.L. and Semenza G.L. (1993). General involvement of hypoxia-inducible factor 1 in transcriptional response to hypoxia. *Proc. Natl. Acad. Sci. USA.* 90, 4304-4308.

Wang K., Cao F., Fang W., Hu Y., Chen Y., Ding H. and Yu G. (2013). Activation of SNAT1/SLC38A1 in human breast cancer: Correlation with p-Akt overexpression. *BMC Cancer.* 13, 343.

Willis D.L., Flaig T.W., Hansel D.E., Milowsky M.I., Grubb R.L., Al-Ahmadie H.A., Plimack E.R., Koppie T.M., McConkey D.J., Dinney C.P., Hoffman V.A., Droller M.J., Messing E. and Kamat A.M. (2014). Micropapillary bladder cancer: Current treatment patterns and review of the literature. *Urol. Oncol.* 32, 826-832.

Yanagida O., Kanai Y., Chairoungdua A., Kim D.K., Segawa H., Nii T, Cha S.H., Matsuo H., Fukushima J., Fukasawa Y., Tani Y., Taketani Y., Uchino H., Kim J.Y., Inatomi J., Okayasu I., Miyamoto K., Takeda E., Goya T. and Endou H. (2001). Human L-type amino acid transporter 1 (LAT1): Characterization of function and expression in tumor cell lines. *Biochim. Biophys. Acta.* 1514, 291-302.

Zhang Q., Ming J., Zhang S., Li B., Yin L. and Qiu X. (2015). Micropapillary component in

gastric adenocarcinoma: An aggressive variant associated with poor prognosis. *Gastric Cancer*. 18, 93-99.

HISTOLOGY AND HISTOPATHOLOGY  
(non-edited manuscript)

**Table 1.** Clinicopathological characteristics of the MPC and control cases

	Case No.	M/F	Age, yrs	Cases with positive LN metastasis (%)
<b>Breast</b>	<b>29</b>	0/29	64.1/60±15.6	10/29 (34.5)
MPC	14	0/14	66.1/67±16.9	8/14 (57.1)
Control	15	0/15	62.3/59±14.5	2/15 (13.3)
<b>Lung</b>	<b>15</b>	10/5	68.5/70±8.1	5/15 (33.3)
MPC	8	6/2	68.4/71±7.5	2/8 (25)
Control	7	4/3	68.7/70±10	3/7 (42.9)
<b>GI</b>	<b>10</b>	7/3	68.3/67±7.3	6/10 (60.0)
MPC	5	4/1	66.0/66±6.7	4/5 (80)
Control	5	3/2	70.6/68±7.8	2/5 (40)
<b>Urothelial</b>	<b>7</b>	5/2	73.2/74.5±7.2	2/7 (28.6)
MPC	2	1/1	69.4/71±5.9	1/2 (50.0)
Control	5	4/1	77.0/76±6.8	1/5 (20.0)

GI, gastrointestinal; LN, lymph node; M/F, male/female; MPC, micropapillary carcinoma. Patient ages are presented as the mean/median ± std. dev.

**Table 2.** Primary antibodies used

<b>Target</b>	<b>Product name</b>	<b>Species/type</b>	<b>Source</b>	<b>Dilution</b>
ASCT1	ab204348	Rabbit/poly	Abcam*	1:40
ASCT2	ab84903	Rabbit/poly	Abcam	1:800
GLUT1	ab15309	Rabbit/poly	Abcam	1:200
GLUT2	ab85715	Mouse/mono	Abcam	1:50
LAT1	Anti-Human LAT1 Polyclonal Antibody	Rabbit/poly	Transgenic**	1:50
SNAT1	ab60145	Rabbit/poly	Abcam	4 µg/ml

\*Abcam, Cambridge, UK. \*\*Transgenic, Kumamoto, Japan.

**Table 3.** Comparison of respective transporters' scores in the MPC and control cases

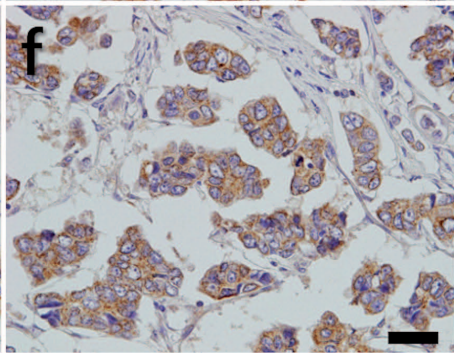
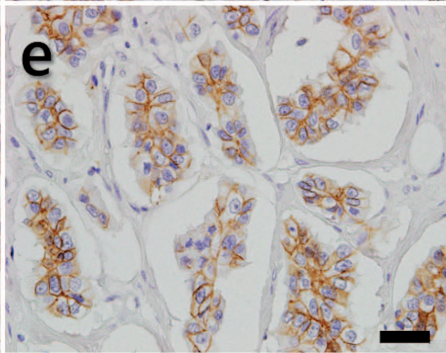
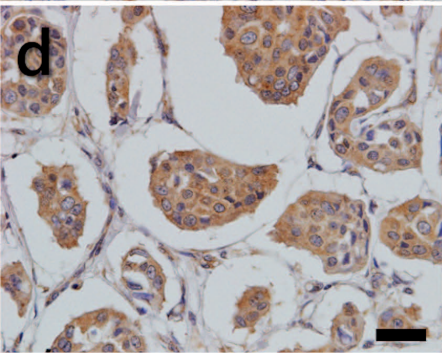
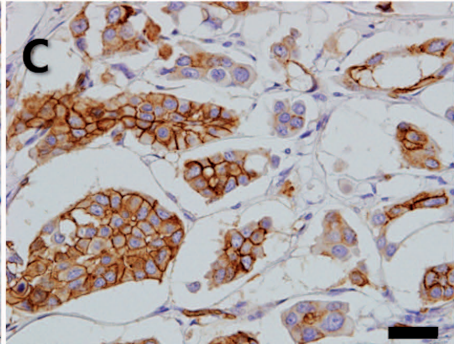
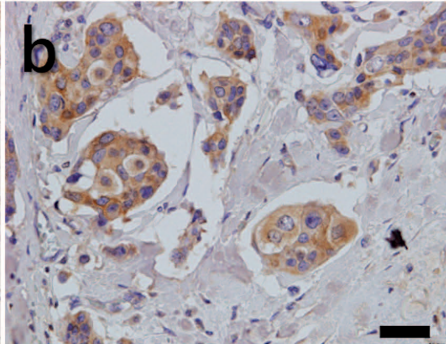
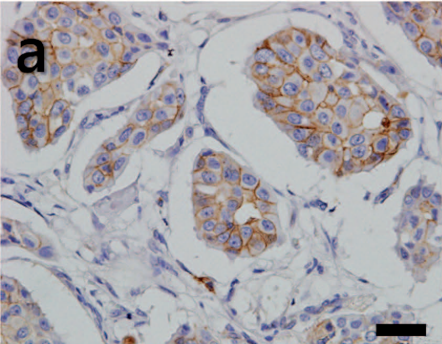
Transporter	Type	Mean	SD*	SE** of the mean	p-value
ASCT1	MPC	5.31	6.404	1.189	0.007
	CONT	1.66	2.404	0.425	
ASCT2	MPC	6.69	5.245	0.974	0.001
	CONT	2.50	3.302	0.584	
GLUT1	MPC	12.86	7.120	1.322	<0.001
	CONT	5.28	5.069	0.896	
GLUT2	MPC	11.10	6.472	1.202	<0.001
	CONT	5.16	5.131	0.907	
LAT1	MPC	4.14	6.828	1.268	0.211
	CONT	2.34	3.525	0.623	
SNAT1	MPC	9.28	6.708	1.246	0.106
	CONT	6.59	6.069	1.073	

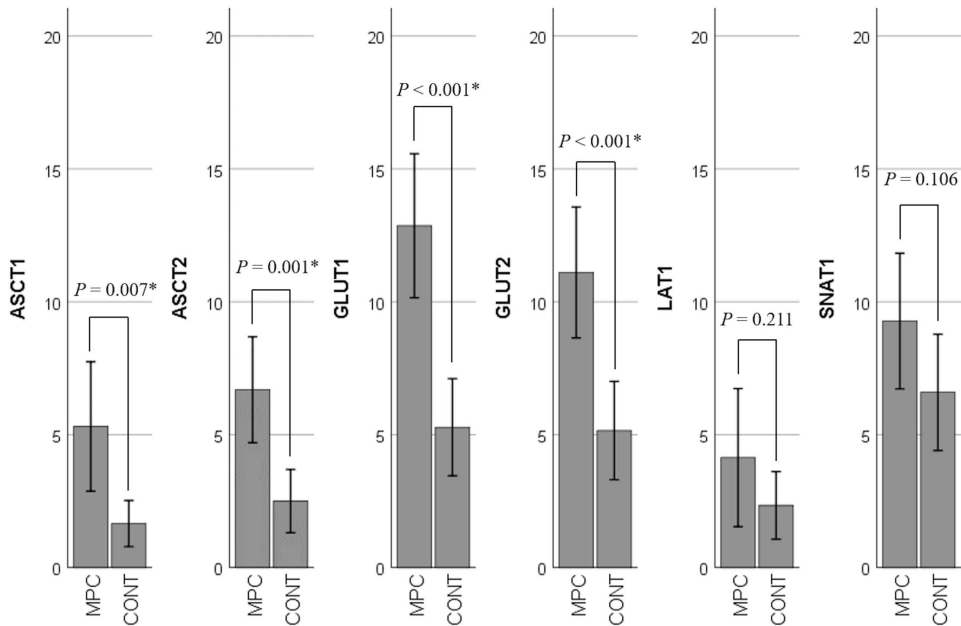
Frequency: MPC = 29, CONT = 32. \* Standard deviation. \*\* Standard error.

## Figure Legends

**Fig. 1.** The staining patterns of the transporters. Invasive MPCs with positive staining are shown (original magnification; 400 $\times$ , scale bar = 40  $\mu$ m). **a:** ASCT1: Linear staining along the basolateral membrane and faint cytoplasmic stain. **b:** ASCT2: Faint granular cytoplasmic stain. **c:** GLUT1: Intense membranous stain. **d:** GLUT2: Fine granular cytoplasmic stain. **e:** LAT1: Linear basolateral membranous stain. **f:** SNAT1: Coarse granular cytoplasmic stain.

**Fig. 2.** Comparison of transporter scores of the MPCs and non-MPCs. The average transporter score of each group was compared using Student's t-test or Welch's t-test, according to the homoscedasticity of the data. \* $p < 0.01$ .





\* :  $P < 0.01$