



Figure 4




Figure 5

DISCUSSION

This technique can be applied to any cabling system. Variables to consider include bone diameter, presence of a plate, tensioner design and initial length of cable. This simple technique requires no extra effort and can save on cost and operative time.

'Reverse guide wire' technique for placement of anterior column/superior pubic ramus screw in pelvis and acetabular surgery

TH Tosounidis, PV Giannoudis

NIHR Leeds Musculoskeletal Biomedical Research Unit, Leeds General Infirmary, Leeds, UK

CORRESPONDENCE TO

Theodoros Tosounidis, E: ttosounidis@yahoo.com
doi 10.1308/rcsann.2017.0198

We present a novel technique for placement of an antegrade anterior column/superior pubic ramus screw. After identification of the entry point, the guide wire is inserted into the iliac bone to a depth of 2–3 mm using the obturator outlet and the inlet fluoroscopic views (Fig 1).¹ It is then withdrawn and reversed so the blunt end functions as the leading end, and reinserted. It is subsequently advanced with light hammering (Fig 2). The risks of cortex penetration and injury of the surrounding structures are minimized since the blunt end can bounce to the cortical bone and is self-redirected into the canal.

Reference

1. Bishop JA, Routt ML Jr. Osseous fixation pathways in pelvic and acetabular fracture surgery: osteology, radiology, and clinical applications. *J Trauma Acute Care Surg* 2012; **72**(6): 1,502–1,509.

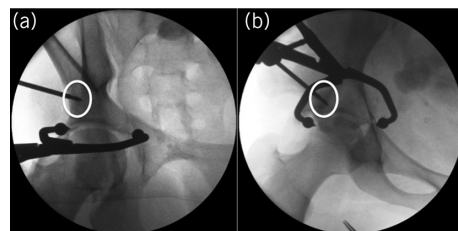


Figure 1 (a) Obturator oblique and (b) inlet intraoperative fluoroscopic views demonstrating the insertion of the guide wire at the entry point for the fixation of the anterior column of a transverse and posterior wall acetabular fracture. The guide wire is advanced only for 2–3 mm

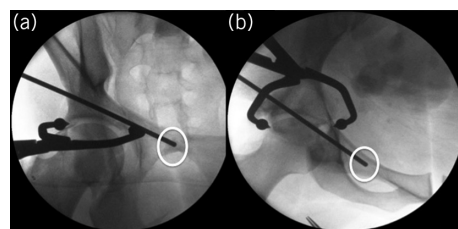


Figure 2 The guide wire is then reversed and, using the same views (a and b), is advanced using light hammering to the superior anterior column/superior pubic ramus