



Deposited via The University of York.

White Rose Research Online URL for this paper:

<https://eprints.whiterose.ac.uk/id/eprint/117367/>

Version: Accepted Version

Article:

Waddell, Keith M, Kagame, Kenneth, Ndamira, Andrew et al. (2015) Clinical features and survival among children with retinoblastoma in Uganda. British Journal of Ophthalmology. pp. 387-390. ISSN: 1468-2079

<https://doi.org/10.1136/bjophthalmol-2014-305564>

Reuse

Items deposited in White Rose Research Online are protected by copyright, with all rights reserved unless indicated otherwise. They may be downloaded and/or printed for private study, or other acts as permitted by national copyright laws. The publisher or other rights holders may allow further reproduction and re-use of the full text version. This is indicated by the licence information on the White Rose Research Online record for the item.

Takedown

If you consider content in White Rose Research Online to be in breach of UK law, please notify us by emailing eprints@whiterose.ac.uk including the URL of the record and the reason for the withdrawal request.

Clinical features and survival among children with retinoblastoma in Uganda

Keith M Waddell,^{1,2} Kenneth Kagame,^{1,2} Andrew Ndamira,² Amos Twinamasiko,² Susan V Picton,³ Ian G Simmons,³ W Tom Johnston,⁴ Robert Newton^{4,5,6}

¹Ruharo Eye Hospital, Mbarara, Uganda

²Departments of Ophthalmology and Paediatrics, Mbarara University of Science and Technology, Mbarara, Uganda

³Departments of Ophthalmology and Paediatric Oncology, Leeds Teaching Hospitals NHS Trust, Leeds, UK

⁴Epidemiology and Cancer Statistics Group, Department of Health Sciences, University of York, York, UK

⁵Medical Research Council/Uganda Virus Research Institute (MRC/UVRI) Research Unit on AIDS, Entebbe, Uganda

⁶International Agency for Research on Cancer, Lyon, France

Correspondence to

Dr Robert Newton, MRC/UVRI Research Unit on AIDS, PO Box 49, Entebbe, Uganda; rob.newton@ecsg.york.ac.uk

RN is a Senior Visiting Scientist at the WHO International Agency for Research on Cancer, Lyon, France.

Received 20 May 2014

Revised 22 August 2014

Accepted 28 August 2014

ABSTRACT

Aims To characterise the clinical features, treatment and outcome of children diagnosed with retinoblastoma in Uganda.

Methods The study comprised a 6-year nationwide enrolment with follow-up.

Results In total, 282 cases were enrolled, 26% (72) were bilateral; 6% were lost to follow-up. Almost all diagnoses in the first affected eye were International Classification of Retinoblastoma group E or worse. Histology was available for 92%; of those, 45%, had extraocular tumour at diagnosis. Enucleation of the first eye was done for 271; 94 received radiotherapy to the socket and in the last 2 years, 70 children received chemotherapy. At close of study, 139 children had died. Survival, as determined in a proportional hazards model adjusted for age, sex, laterality and treatment era (pre or post introduction of chemotherapy), varied by extent of the tumour ($p<0.001$); children with only intraocular involvement were 80% less likely to die (HR=0.21, 95% CI 0.12 to 0.35) compared with children with extraocular involvement.

Conclusions Diagnostic delay results in relatively high mortality among children with retinoblastoma in Uganda. There is an urgent need for more effective treatment modalities, particularly chemotherapy, and nationwide efforts to encourage earlier access to medical care.

INTRODUCTION

Retinoblastoma is reported to be commoner in tropical countries than in the developed world, but population-based studies are few.^{1–3} Retinoblastoma also has worse outcome with high mortality, but follow-up in most studies is limited.⁴ In Uganda, enucleation had been the only treatment available for most cases, a minority also receiving radiotherapy. Chemotherapy as part of initial treatment had not been introduced when this study began. To characterise cases diagnosed in Uganda, we did a 6-year nationwide study documenting current practice, histology and outcomes. A home visiting team obtained near complete follow-up. It became evident that mortality was unacceptably high and so, in the final 2 years of the study, with the aim of improving survival, we introduced a programme of neoadjuvant and adjuvant chemotherapy in one referral centre in southwestern Uganda. Details of this programme and its impact is the subject of another report. Here, we describe disease characteristics at presentation and subsequent survival of children with retinoblastoma in Uganda.

MATERIALS AND METHODS

Starting in January 2006, ophthalmologists in Uganda were invited to enter cases into the study

whilst retaining management; recruitment ended in December 2011. A standard form documented demography, clinical features, treatment and follow-up. Staging was according to the International Classification of Retinoblastoma (ICRB).⁵ Counsellors, using vernacular, gave information about the disease, its treatment and the study, and parents signed or thumb-printed they understood and consented. A brief lifestyle and health questionnaire was used. Data were entered and stored on a database using EPI-INFO software (CDC.gov). When possible, blood was taken during anaesthesia and tumour specimens collected and put into RNAlater (Ambion, Inc; techserv@ambion.com) and then transferred to the Uganda Virus Research Institute and stored at -80° . Some patients received radiotherapy at Mulago Hospital, Kampala, with the country's sole machine (cobalt 60; dose 39 Gy in 13 fractions). A few with metastases were referred to the Uganda Cancer Institute for late chemotherapy. The team responsible for follow-up of children made extensive use of mobile phones and home visits to track progress.

The impact of various factors on survival was initially described using Kaplan–Meier plots and life-table methods. Further analyses using proportional hazards regression were conducted to examine the impact on survival of factors, such as laterality, extent, sex and age at diagnosis. Appropriate tests of the proportional hazards assumption were carried out.

The study was approved by the Ethics Committee of Mbarara University (Ruharo is affiliated) and by the Uganda National Council for Science and Technology. We certify that all applicable institutional and governmental regulations concerning the ethical use of human volunteers were followed during this research.

RESULTS

In 6 years, 282 cases were enrolled (144 (51%) boys and 138 (49%) girls). Seventy-two (26%) were bilateral and seven had family histories (five families) of retinoblastoma. The median age at diagnosis of unilateral cases was 33 months (IQR 23–48; range 4–130), and of bilateral 17.5 months (IQR 9.5–25; range 1–72). Follow-up beyond treatment was obtained for 265 of 282 children (94%), which was to the end of study (May 2013) or death for 257 (91%). Median follow-up for those alive was 35 months (IQR 25–53.5; range 3–86); for those who died, it was 7 months (IQR 5–14; range 1–58).

Some case descriptions received from ophthalmologists in the nationwide study were incomplete,

To cite: Waddell KM, Kagame K, Ndamira A, et al. *Br J Ophthalmol* Published Online First: [please include Day Month Year] doi:10.1136/bjophthalmol-2014-305564

Clinical science

but nearly all diagnoses in the first affected eye were group E or already extraocular, with none below group D, except for two with group C. All cases, except the two group C, were offered enucleation, which was done for 271 (96%), 31 bilaterally; others declined or died soon after. Histology was accessed for 249 of 271 operated cases (92%) and was retinoblastoma for 234. Diktyoma was suggested for 13 cases because of palisading of cells, but clinically these were advanced retinoblastoma, so were treated and analysed as such. No tumour was reported for two cases after chemotherapy but they were clinically definite. When tumour extent was reported as part of histology, 86 of 191 (45%) had optic nerve or orbital involvement. Radiotherapy was given to sockets of 94 children after enucleation (eight bilaterally) and to three intact globes. A further 18 received radiotherapy for recurrence, some following surgical de-bulking. Late chemotherapy for metastasis was given to 19 children at the Uganda Cancer Institute. Among bilateral cases, the stages at diagnosis of tumour in the second eye ranged from A to E or extraocular, so treatment varied; for 20 of these, treatment was either declined or the child died before it was initiated. In the final 2 years of the study, 70 children received chemotherapy during initial management.

At latest follow-up, 132 children were alive. There were 125 confirmed deaths and 14 presumed dead having uncontrolled tumour at last contact, giving 139 dead in total; 11 were lost to follow-up. Among children diagnosed before the introduction of chemotherapy, survival at 36 months was 45% (95% CI 37% to 53%). Table 1 shows survival of 166 children with known outcome treated before the introduction of chemotherapy, stratified by tumour extent and radiotherapy. In the absence of radiotherapy, none of the children with extraocular spread at diagnosis survived; with radiotherapy, 34% survived. Among those cases judged to be still intraocular at diagnosis, a quarter died irrespective of whether they received radiotherapy. Overall, survival, as determined in a proportional hazards model adjusted for age, sex, laterality and treatment era (pre or post introduction of chemotherapy), varied by extent of the tumour ($p < 0.001$, figure 1). Children with intraocular involvement only, had an 80% lower risk of dying (HR=0.21, 95% CI 0.12 to 0.35) compared with children with extraocular involvement.

Table 1 Survival of 166 children with known outcome treated prior to the introduction of chemotherapy, by tumour extent and radiotherapy

Tumour extent	Intraocular Number (%)	Extraocular Number (%)	Undetermined Number (%)	Total Number (%)
Radiotherapy given				
Alive	12 (75)	11 (34)	11 (58)	34 (51)
Died	4 (25)	21 (66)	8 (42)	33 (49)
Total	16	32	19	67
No radiotherapy				
Alive	25 (74)	0 (0)	14 (52)	39 (39)
Died	9 (26)	38 (100)	13 (48)	60 (61)
Total	34	38	27	99
Total cases	50	70	46	166

Extraocular: optic nerve or sclera involved or orbital tumour present at diagnosis; either eye if bilateral.
 Intraocular: none of the above or optic disc visibly uninvolved; both eyes if bilateral.
 Extent undetermined: not reported or histology not available.
 Radiotherapy: to the socket after enucleation during initial treatment, excluding recurrence.

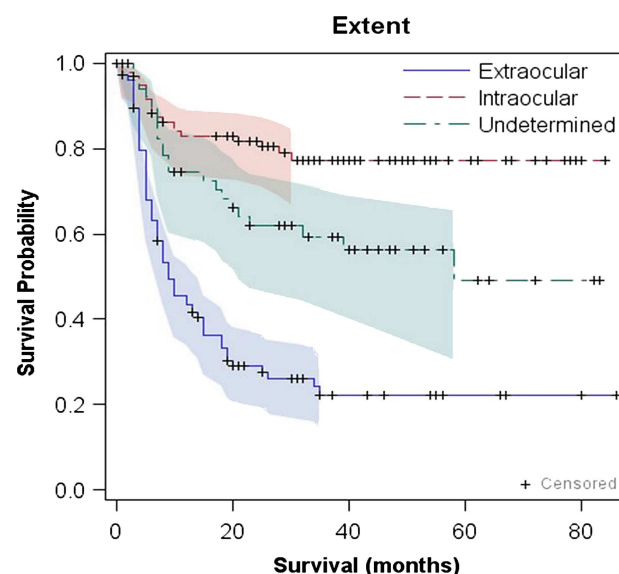


Figure 1 Kaplan–Meier survival estimates (with 95% confidence limits) for 270 children with retinoblastoma, irrespective of treatment given, stratified by extent of the tumour. Extraocular extent: optic nerve or sclera involved or orbital tumour present at diagnosis; either eye if bilateral. Intraocular extent: none of the above or optic disc visibly uninvolved; both eyes if bilateral. Extent undetermined: histology not reported or not accessed.

Macroscopic orbital tumour occurred in 72 children (27 at enucleation, 45 at recurrence); 71 died even if given radiotherapy and chemotherapy (67 confirmed dead and 5 presumed dead having uncontrolled tumour). The one survivor had an early recurrence and is currently alive 33 months after diagnosis, following chemotherapy and radiotherapy. When proptosis was recorded, 7 of 48 were alive at last follow-up (14–43 months after diagnosis). Thirteen had other surgery before the correct diagnosis; survival was none of four after evisceration, one of four after trabeculectomy, and four of five after cataract. No survivors are known of 19 having late chemotherapy for metastasis at the Uganda Cancer Institute.

For many children included in the study, the precise mode of death is uncertain. Orbital fungation was common without radiotherapy but only one case was known after radiotherapy, so it was palliative. The common sites of metastasis were skull, or spine with paraplegia. There was one known case of hepatic metastasis and one with local lymph node involvement. One bilateral heritable case died with primary sarcoma of the femur. Five children died in remission after short febrile illnesses, apparently unrelated infections. However, the mode of death is known for the 20 who received chemotherapy as part of initial treatment. Fifteen had extraocular extension (seven with macroscopic orbital tumour) and most died with apparent intracranial extension, following headache, convulsions or unconsciousness.

DISCUSSION

Diagnostic delay results in relatively high mortality among children with retinoblastoma in Uganda. Nearly half of tumours were already extraocular at the time of diagnosis; among the 94% of 282 cases in whom outcome data were available, 56% had died after 36 months of follow-up. Indeed, prior to chemotherapy, even among cases with intraocular disease, mortality was 25% with radiotherapy and 26% without it. This emphasises the need for additional treatment modalities (such as

chemotherapy) and for nationwide education campaigns with the aim of down-staging tumours at diagnosis. Furthermore, retinoblastoma masquerading as other conditions is relatively common and a high index of suspicion should be maintained for every child presenting with other ocular features.

Recruitment of 282 children with retinoblastoma in 6 years confirms the relatively high frequency of this malignancy in Uganda compared with Western populations, although only an unknown fraction of the totality of cases occurring was enrolled. However, it remains unclear if the true incidence of disease is higher, since the proportion of children among the population is higher in a country such as Uganda, than for example in the UK. Data from the population-based cancer registry, in Kampala, indicate that incidence of retinoblastoma may be three to four times higher than Western countries, but the figure is based on relatively few cases and uncertainty remains.^{6 7} The proportion of all cases that were bilateral was 26% and their ages at diagnosis younger than unilateral cases, often being congenital; this percentage may underestimate the true figure given the high probability of the first tumour being fatal. Only five families were identified with more than one child affected, perhaps indicating that most were new mutations. It is uncertain if this heritable portion differs from the West before it was inflated there by improved survival. The aetiological significance of these figures is under investigation and a concurrent case-control study will consider potential environmental causes.

The diagnosis of retinoblastoma can often be confidently made by inspection, but opacities may obscure visualisation. Ultrasound showing tumour with calcification helps but was not available everywhere. Bilateral cases were often congenital and diagnosis after 6 years of age was rare, although the oldest case was 10 years. Many presented with other features, notably uveitis, but also cataract, buphthalmos, staphyloma, endophthalmitis, orbital cellulitis, hyphaema or phthisis, risking delayed enucleation, or inappropriate surgery spreading tumour, as occurred for 13 children. Evisceration for mistaken endophthalmitis was always fatal. This retinoblastoma masquerade must be considered in every child with other diagnoses. Even with ultrasound, necrotic tumour causing uveitis or phthisis was difficult to detect. CT scanning and cerebrospinal fluid cytology would be ideal to detect intracranial extension but were impractical or impossible in this setting and would not affect outcome.⁸ Fine needle aspiration was not attempted in case it spread tumour cells, though it has some advocates.

Despite some incomplete documentation, it is clear that almost all children presented having the first eye filled with tumour and with no prognosis for useful vision (stage E); around half already had extraocular extension. Many parents had long been aware and previously refused enucleation. When bilateral, the second eye was often earlier stage allowing possible control, thereby saving sight. To improve outcome, earlier diagnosis is essential. Counselling must also aim to reduce refusal of enucleation while still curable. Programmes have started in East Africa alerting parents to come as soon as something white is seen in the eye; not only would this improve survival from retinoblastoma, but would also improve cataract outcome.

Histology was accessed for most (92%) leaving few clinical diagnoses. It came from various sources (none of the pathologists involved had specialist training in relation to retinoblastoma); some were detailed but others gave only diagnosis without extent, hence the 'extent undetermined' group. Thirteen cases were reported consistent with diktyoma because of palisading of cells, but clinically were advanced tumours filling the eye or uveitic, not resembling textbook ciliary body

diktyomas, so were managed as retinoblastoma. Unexpectedly even if the nerve was reported uninvolved, the mortality was high (25%, [table 1](#)). This may have been because of limited sampling, but radiotherapy made no difference so it seems early haematogenous metastasis may occur. For informed management decisions, detailed histology of intraocular extent and full nerve length are needed. A regional retinoblastoma histology service is being established in Kenya, but permits are needed for tissue to cross borders. Local specialist training is needed.

Follow-up was near complete with home-visiting and mobile telephones (94%; median 35 months for survivors). This contrasts with other African series and allows firm conclusions about outcome. Also in striking contrast to Western countries it confirmed high mortality.^{9 10} This was expected with extraocular extension, but high mortality when still intraocular (as far as could be assessed from limited histology) was one reason for introduction of chemotherapy.

The literature has little guidance for clinicians in Africa on management or prognosis of retinoblastoma, though each ophthalmologist can expect to see several cases every year. Preoperative assessment was often limited and enucleation considered the only option, the length and state of the optic nerve not being noted. Adjuvant treatments may not be considered and histology not accessed. Examination of the fellow eye for curable tumours using indirect ophthalmoscopy with indentation may be omitted. Follow-up till at least age 7 years, watching for reactivated disease and for siblings, is sporadic.¹¹ This needs to be changed but even with the best will, the prolonged management required is difficult with the limited resources in Africa, and adverse socioeconomic factors are known indicators of poor outcome.¹² Management could be better coordinated if one or a few hospitals were designated national referral centres for all cases.

Radiotherapy is best avoided because of facial disfigurement, socket contracture and risk of later malignancy in the irradiated field.¹³ However, radiotherapy seems unavoidable with optic nerve invasion, though it is unknown if it could be omitted if this does not reach the resection margin. At present, Uganda has only one radiotherapy machine (cobalt 60) serving the entire population, so access is congested and introduction of conformal radiotherapy for all cancers is urgent. Many cases with extraocular extension did not receive radiotherapy and inevitably died. The study sponsored many children to access radiotherapy, but even then, on its own it saved only 34%. With uninvolved optic nerve, radiotherapy is unnecessary because mortality was 25% with and 26% without this treatment; if used, all then suffer its disadvantages. With orbital tumour, it prevents fungation but rarely (one case out of 72) saves life. Introduction of chemotherapy may change the indications for use of radiotherapy.

In summary, the main obstacle to reducing mortality from retinoblastoma in Uganda is delayed presentation. Once a safe and effective treatment programme is in place, using a range of modalities, there is an urgent need in Uganda and other countries in sub-Saharan Africa, to address diagnostic delay, with national education campaigns encouraging people to come forward with affected children earlier. However, there is little point in initiating such schemes in the absence of effective treatment.

Acknowledgements We thank colleagues for referring cases, the pathologists for histology, Dr J Kigula-Mugambe for radiotherapy, Mr J Kwehangana for follow-up, the nurses—especially Sr G Kemugisha and Mr C Bidwell—for care of the children and chemotherapy, and Cancer Research UK, Yorkshire Eye Research and Children with Cancer for financing it.

Contributors All authors contributed at all stages of this study, from conception to the preparation of the manuscript.

Competing interests None.

Patient consent Obtained.

Ethics approval Uganda Council for Science and Technology and the Ethics Committee of Mbarara Hospital.

Provenance and peer review Not commissioned; externally peer reviewed.

REFERENCES

- 1 Stiller C, Parkin D. Geographic and ethnic variations in incidence of childhood cancer. *Br Med Bull* 1996;52:682–703.
- 2 Wessels G, Hesselting P. Incidence and frequency rates of childhood cancer in Namibia. *S Afr Med J* 1997;87:885–9.
- 3 Boubacar T, Fatou S, Foussenyi T, *et al*. A 30-month prospective study on the treatment of retinoblastoma in the Gabriel Touré Teaching Hospital, Bamako, Mali. *Br J Ophthalmol* 2010;94:467–9.
- 4 Bowman R, Mafwiri M, Luthert P, *et al*. Outcome of retinoblastoma in east Africa. *Paediatr Blood Cancer* 2008;50:160–2.
- 5 Shields C, Shields J. Basic understanding of current classification and management of retinoblastoma. *Curr Opin Ophthalmol* 2006;17:228–34.
- 6 Wabinga H, Parkin D, Wabwire-Mangen F, *et al*. Trends in cancer incidence in Kyadondo County, Uganda, 1960–1997. *Br J Cancer* 2000;82:1585–92.
- 7 Kivelä T. The epidemiological challenge of the most frequent eye cancer: retinoblastoma, an issue of birth and death. *Br J Ophthalmol* 2009;93:1129–31.
- 8 Cozza R, De Ioris M, Ilari I, *et al*. Metastatic retinoblastoma: single institution experience over two decades. *Br J Ophthalmol* 2009;93:1163–6.
- 9 Sanders B, Draper G, Kingston J. Retinoblastoma in Great Britain 1969–1980: incidence, treatment and survival. *Br J Ophthalmol* 1988;72:576–83.
- 10 MacCarthy A, Birch J, Draper G, *et al*. Retinoblastoma: treatment and survival in Great Britain 1963 to 2002. *Br J Ophthalmol* 2009;93:38–9.
- 11 Rothschild P-R, Lévy D, Savignoni A, *et al*. Familial retinoblastoma: fundus screening schedule impact and guideline proposal. *Eye* 2011;25:1555–61.
- 12 Canturk S, Qaddoumi I, Khetan V, *et al*. Survival of retinoblastoma in less-developed countries. Impact of socioeconomic health-related indicators. *Br J Ophthalmol* 2010;94:1432–6.
- 13 Woo K, Harbour J. Review of 676 second primary tumours in patients with retinoblastoma: association between age of onset and tumor type. *Arch Ophthalmol* 2010;128:865–70.



Clinical features and survival among children with retinoblastoma in Uganda

Keith M Waddell, Kenneth Kagame, Andrew Ndamira, et al.

Br J Ophthalmol published online September 12, 2014

doi: 10.1136/bjophthalmol-2014-305564

Updated information and services can be found at:

<http://bjo.bmj.com/content/early/2014/09/12/bjophthalmol-2014-305564.full.html>

These include:

References

This article cites 13 articles, 7 of which can be accessed free at:
<http://bjo.bmj.com/content/early/2014/09/12/bjophthalmol-2014-305564.full.html#ref-list-1>

P<P

Published online September 12, 2014 in advance of the print journal.

Email alerting service

Receive free email alerts when new articles cite this article. Sign up in the box at the top right corner of the online article.

Topic Collections

Articles on similar topics can be found in the following collections

[Paediatrics](#) (327 articles)
[Epidemiology](#) (903 articles)

Notes

Advance online articles have been peer reviewed, accepted for publication, edited and typeset, but have not yet appeared in the paper journal. Advance online articles are citable and establish publication priority; they are indexed by PubMed from initial publication. Citations to Advance online articles must include the digital object identifier (DOIs) and date of initial publication.

To request permissions go to:

<http://group.bmj.com/group/rights-licensing/permissions>

To order reprints go to:

<http://journals.bmj.com/cgi/reprintform>

To subscribe to BMJ go to:

<http://group.bmj.com/subscribe/>