



UNIVERSITY OF LEEDS

This is a repository copy of *Development and reliability of a preliminary Foot Osteoarthritis Magnetic Resonance Imaging Score*.

White Rose Research Online URL for this paper:
<http://eprints.whiterose.ac.uk/113779/>

Version: Accepted Version

Article:

Halstead, J, Martín-Hervás, C, Hensor, EMA et al. (4 more authors) (2017) Development and reliability of a preliminary Foot Osteoarthritis Magnetic Resonance Imaging Score. *Journal of Rheumatology*, 44 (8). pp. 1257-1264. ISSN 0315-162X

<https://doi.org/10.3899/jrheum.160617>

© 2017. This is a pre-copy-editing, author-produced PDF of an article accepted for publication in *The Journal of Rheumatology* following peer review. The definitive publisher-authenticated version Halstead, J, Martín-Hervás, C, Hensor, EMA et al. (4 more authors) (2017) Development and reliability of a preliminary Foot Osteoarthritis Magnetic Resonance Imaging Score. *Journal of Rheumatology*, 44 (8). pp. 1257-1264 is available online at: <http://dx.doi.org/10.3899/jrheum.160617>

Reuse

Items deposited in White Rose Research Online are protected by copyright, with all rights reserved unless indicated otherwise. They may be downloaded and/or printed for private study, or other acts as permitted by national copyright laws. The publisher or other rights holders may allow further reproduction and re-use of the full text version. This is indicated by the licence information on the White Rose Research Online record for the item.

Takedown

If you consider content in White Rose Research Online to be in breach of UK law, please notify us by emailing eprints@whiterose.ac.uk including the URL of the record and the reason for the withdrawal request.



eprints@whiterose.ac.uk
<https://eprints.whiterose.ac.uk/>

Figure 3

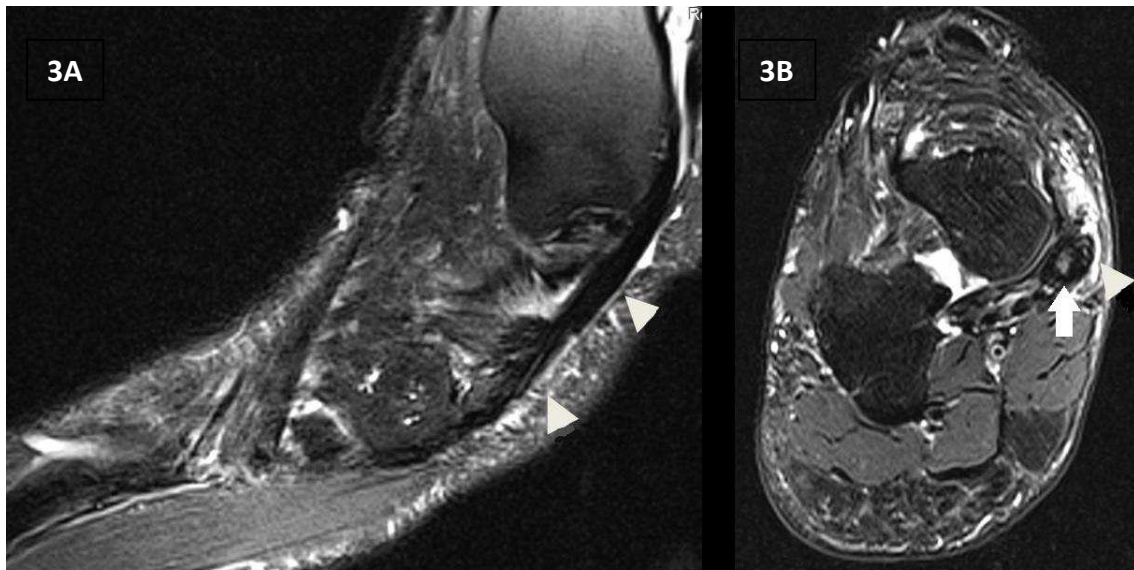


Figure 3: A and B show fat saturated T2w images in the sagittal and axial plane respectively. Tenosynovitis of tibialis posterior defined high signal on T2-weighted in a region of the tendon (white arrow) and the enclosing tendon sheath (white arrow head) in two planes was shown. This was scored as grade 2 (>2 and <5 mm peritendinous effusion and/or thickening and high intra-tendinous signal intensity).