



UNIVERSITY OF LEEDS

This is a repository copy of *Development and reliability of a preliminary Foot Osteoarthritis Magnetic Resonance Imaging Score*.

White Rose Research Online URL for this paper:
<http://eprints.whiterose.ac.uk/113779/>

Version: Accepted Version

Article:

Halstead, J, Martín-Hervás, C, Hensor, EMA et al. (4 more authors) (2017) Development and reliability of a preliminary Foot Osteoarthritis Magnetic Resonance Imaging Score. *Journal of Rheumatology*, 44 (8). pp. 1257-1264. ISSN 0315-162X

<https://doi.org/10.3899/jrheum.160617>

© 2017. This is a pre-copy-editing, author-produced PDF of an article accepted for publication in *The Journal of Rheumatology* following peer review. The definitive publisher-authenticated version Halstead, J, Martín-Hervás, C, Hensor, EMA et al. (4 more authors) (2017) Development and reliability of a preliminary Foot Osteoarthritis Magnetic Resonance Imaging Score. *Journal of Rheumatology*, 44 (8). pp. 1257-1264 is available online at: <http://dx.doi.org/10.3899/jrheum.160617>

Reuse

Items deposited in White Rose Research Online are protected by copyright, with all rights reserved unless indicated otherwise. They may be downloaded and/or printed for private study, or other acts as permitted by national copyright laws. The publisher or other rights holders may allow further reproduction and re-use of the full text version. This is indicated by the licence information on the White Rose Research Online record for the item.

Takedown

If you consider content in White Rose Research Online to be in breach of UK law, please notify us by emailing eprints@whiterose.ac.uk including the URL of the record and the reason for the withdrawal request.



eprints@whiterose.ac.uk
<https://eprints.whiterose.ac.uk/>

Figure 1

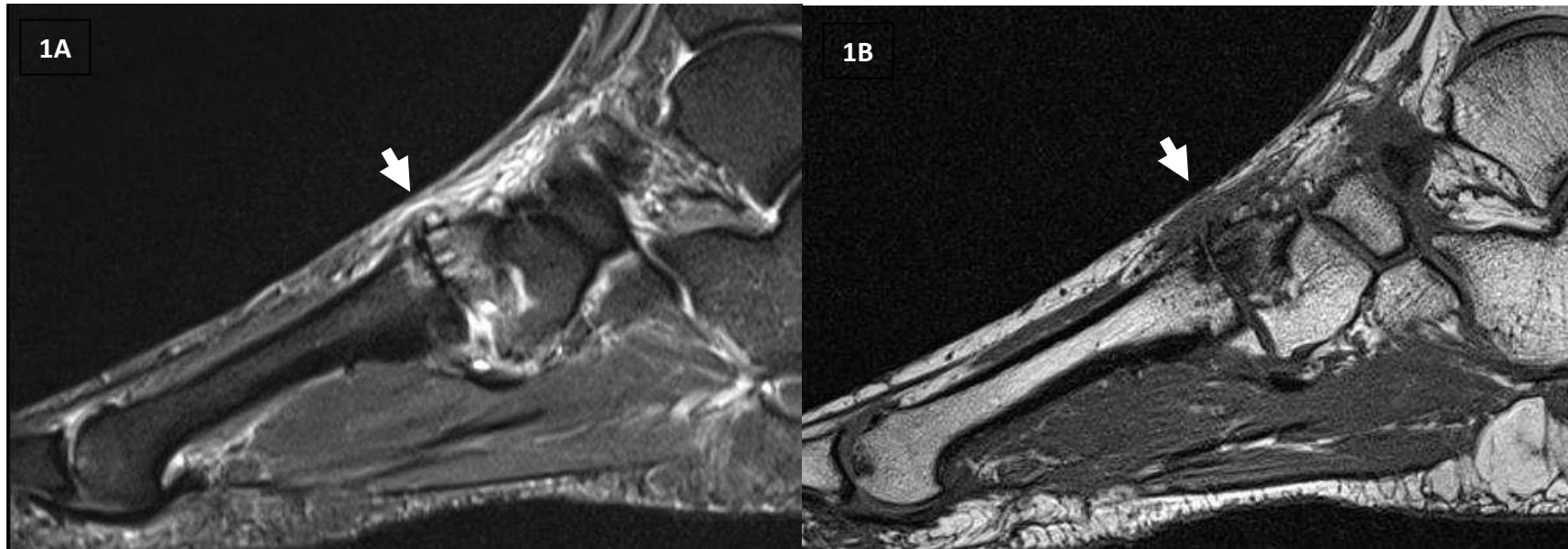


Figure 1: A and B show T1w and fat saturated T2w sagittal images. Short white arrow shows the second tarsometatarsal joint, scored as a grade 2 (partial thickness or focal loss) for joint space narrowing (JSN), grade 2 (moderate) osteophyte, the presence of effusion/synovitis, the presence of cysts, grade 2 (34%-66%) bone marrow lesion (BML) at the intermediate cuneiform and grade 1 (1%-33%) in the base of the second metatarsal. The second metatarsophalangeal joint was scored as a grade 2 for JSN, grade 2 osteophytes, in addition to grade 1 BML at the head of the second metatarsal.